

# Traditional T1-S1 Measurement of the Spinal Length on X-ray Images Does Not Correlate With the True Length of the Spine

Christoph Heidt, Thomas Angst, Philippe Büchler, Carol-Claudius Hasler and Daniel Studer

*Int J Spine Surg* 2022, 16 (5) 921-927

doi: <https://doi.org/10.14444/8353>

<https://www.ijssurgery.com/content/16/5/921>

This information is current as of September 26, 2024.

---

**Email Alerts** Receive free email-alerts when new articles cite this article. Sign up at:  
<http://ijssurgery.com/alerts>

# Traditional T1-S1 Measurement of the Spinal Length on X-ray Images Does Not Correlate With the True Length of the Spine

CHRISTOPH HEIDT, MD<sup>1</sup>; THOMAS ANGST<sup>1</sup>; PHILIPPE BÜCHLER, PhD<sup>2</sup>; CAROL-CLAUDIUS HASLER, MD<sup>1</sup>; AND DANIEL STUDER, MD<sup>1</sup>

<sup>1</sup>Department of Orthopedics, University Children's Hospital Basel: Universitäts Kinderspital beider Basel, Basel, Switzerland; <sup>2</sup>Computational Bioengineering Group, Institute for Surgical Technology and Biomechanics, University of Bern, Bern, Switzerland

## ABSTRACT

**Background:** The T1-S1 distance to evaluate spinal length is traditionally measured as a straight line on an anteroposterior radiograph. However, this method may not reflect the true 3-dimensional (3D) spinal length. The objective of the study was to evaluate the difference between the traditional T1-S1 measurement and a 3D reconstruction from standard x-ray imaging.

**Methods:** Radiological assessment and 3D reconstruction of spinal length in pediatric patients with various spine deformities. The 3D reconstruction derived from standard biplanar spine x-ray images using a specialized but free available software and calibration device. Direct comparison of length, intraobserver variance for repeated measurements, as well as interobserver correlation for both measurement methods and between different levels of training were evaluated. Furthermore, the influence on spinal length by the degree of spinal deformity as well as other factors was analyzed.

**Results:** A total of 39 x-ray images from 35 patients at a mean age of 15.4 years (8.9–26.8 years) were evaluated. There was excellent agreement for intra- and interobserver correlation for both measurement techniques. Spinal length assessed using 3D reconstruction was significantly longer compared with the traditional T1-S1 distance, on average 2.7 cm (0.5–6.1 cm). There was also a significant positive correlation between the maximum extent of the deformity and the difference in spinal length.

**Conclusions:** Traditional T1-S1 distance significantly underestimates the true length of the spine. A 3D measurement reflects the real length of the spine more adequately.

**Clinical Relevance:** Such information is relevant to the treating spine surgeon when planning or assessing therapeutic measures, especially in advanced deformities.

**Level of Evidence:** 4.

New Technology

Keywords: adolescent idiopathic scoliosis, T1-S1 distance, spinal length, spine growth, 3-dimensional reconstruction

## INTRODUCTION

Monitoring of spinal growth, by assessing the length of the spine, is essential when treating pediatric spinal deformities. Patients with early onset scoliosis, for example, are at high risk to develop a thoracic insufficiency syndrome<sup>1</sup> and restrictive pulmonary disease.<sup>2</sup> In these patients, the spinal length is regularly monitored, as this parameter has been shown to highly correlate with pulmonary function.<sup>3</sup> Furthermore, approaches have been made to monitor sitting height as an indicator for curve progression in adolescent idiopathic scoliosis (AIS).<sup>4</sup>

Due to the 3-dimensional (3D) deformation of the spine, scoliosis leads to a reduction of the patient's trunk and therefore body height. Growth further drives the deformity, so external body height measurements do not allow for a true assessment of length gained,

especially during the growth spurt periods. Knowledge about the 3D shape of the spine is also essential to plan and monitor growth preserving/promoting surgical interventions such as traditional or motorized growing rods or vertical expandable prosthetic titanium rib systems. Recent studies evaluating new growth guiding systems have confirmed that the length of the spine improves during these treatments.<sup>5</sup>

Traditionally, spinal length is assessed on an anteroposterior (AP) x-ray image by simply measuring the distance from the center of the upper endplate of T1 and the center of the upper endplate of S1, the so-called T1-S1 distance. Previous studies aimed to calculate and estimate the true spinal length using mathematical algorithms based on Cobb angle measurements.<sup>6</sup> However, such calculations were shown to be quite inaccurate.<sup>4</sup> Computed tomography (CT) provides detailed information of the deformity<sup>7</sup> but the high exposure to ionizing

radiation cannot be neglected in this vulnerable age group.<sup>8</sup> Additionally, supine imaging usually underestimates the extent of the deformity due to missing gravity.<sup>9</sup> Low-dose standing biplanar imaging systems can overcome these disadvantages<sup>10</sup> but such devices are expensive and mainly available in highly specialized centers.

We recently introduced an easy-to-use 3D calibration device<sup>11</sup> and software to reliably assess the true spinal length using any conventional x-ray system.<sup>12</sup> The aim of this study is to objectify the differences in spinal length measurements when using the traditional T1-S1 approach in comparison with the 3D reconstruction software in patients with different spinal deformities. We hypothesized that the traditional T1-S1 distance does not correlate with the true 3D length of the spine, and that the difference will depend on the degree of the deformity. Furthermore, the usability of the software was evaluated by comparing intra- and interobserver reliability of the measurements.

## METHODS

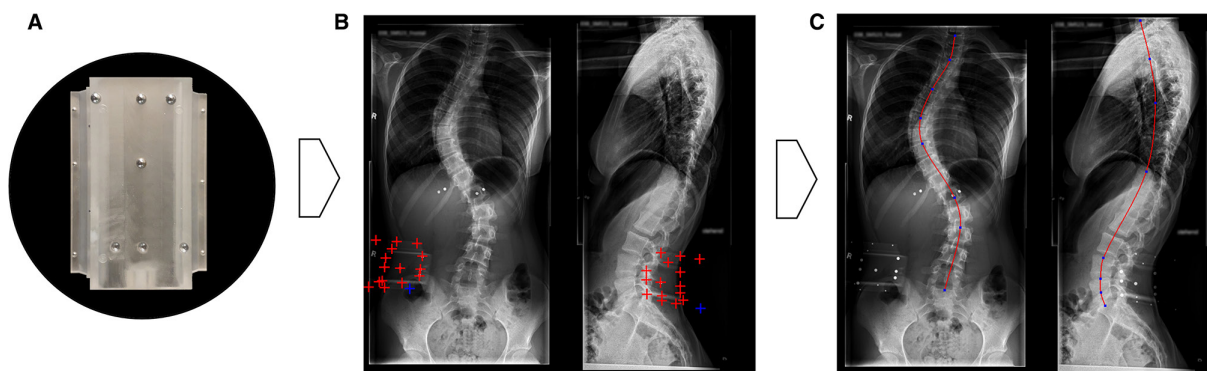
Ethical approval was obtained from the responsible ethics committee (Req. 2018-01546). All etiologies of pediatric spinal deformities (eg, idiopathic, neurogenic, syndrome-related, and congenital) and patients who have had spinal surgery (eg, posterior instrumented spinal fusion or distraction-based growth guiding implants) at our specialized outpatient clinic were considered for inclusion in the present study. AP and lateral whole-spine x-ray images were obtained as part of routine follow-up, and patients were asked to wear a calibration device<sup>11</sup> during image acquisition. The development and validation of the calibration device and the Spinal Measurement Software (SMS) were described previously.<sup>11,12</sup>

Measurements were performed using the most current, freely available version SMS v1.2.<sup>13</sup> On deidentified images exported from the hospital Picture Archiving and Communication System, the observer manually marks the calibration device. On both projections, the upper endplates of T1 and S1 are marked in correspondence with the endpoints of the traditional T1-S1 distance measurement. The curvature of the spine is adjusted manually by additional flexpoints on the ruler for adequate spinal midline placement. Once adjusted, the software computes the 3D reconstruction, and the true spinal length is calculated (Figure 1a–c).

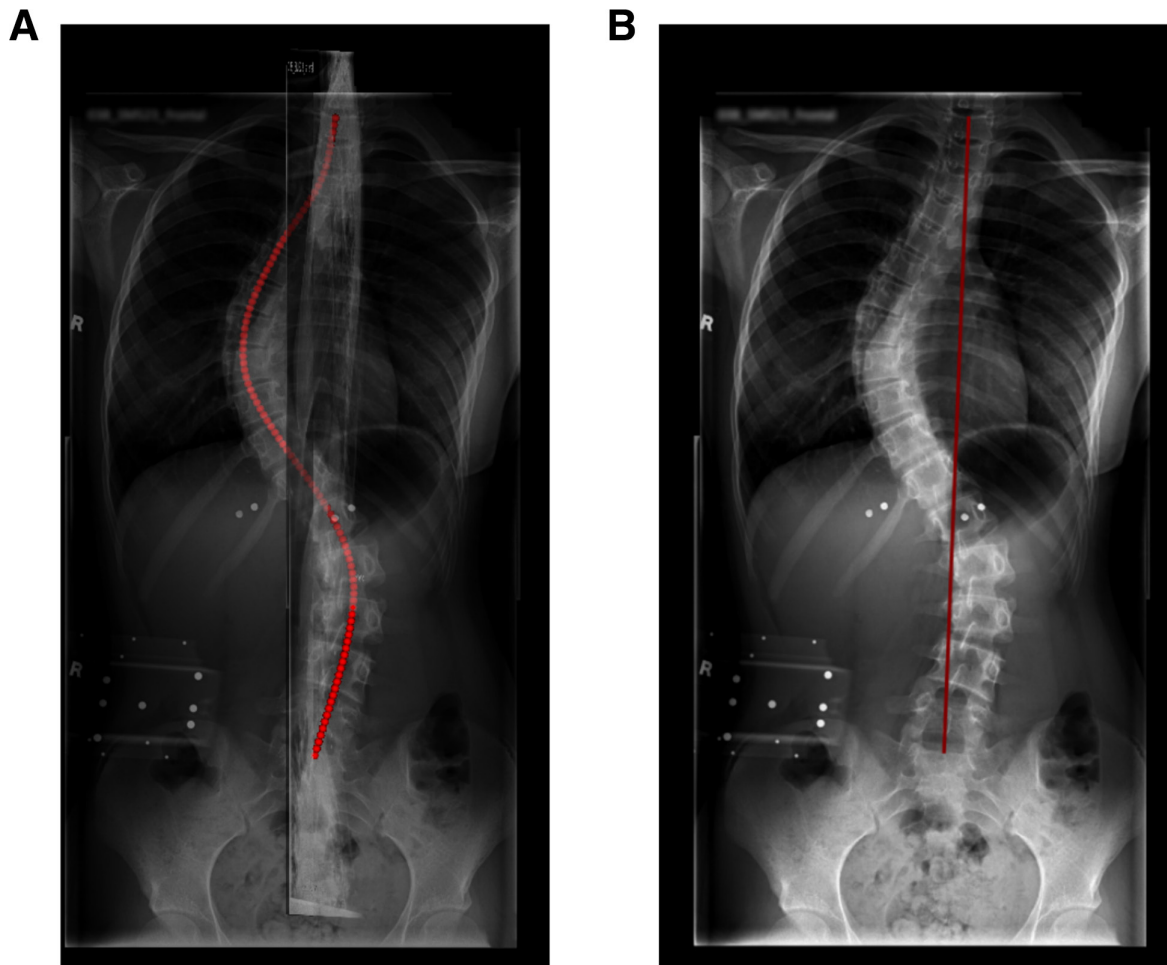
For comparison, traditional T1-S1 distance was measured on a standard DICOM viewer (Synedra View, Synedra information technologies GmbH, Innsbruck, Austria). Images were calibrated according to the magnification factor of standard x-ray images (Figure 2a & b).

To test the intra- and inter-rater reliability, measurements were conducted by 3 investigators (TA, CH, DS) with different levels of experience and training (medical student, fellow, and consultant spine surgeon). All available images were measured 3 times with at least 2 weeks in-between to reduce bias.<sup>14</sup> To quantify the extent of the deformity, standard coronal and sagittal Cobb angle measurements were performed.<sup>15</sup> To allow a single parameter that represents the full degree of deformity, both the coronal and sagittal profile—all Cobb angles measured were added up to create a single value (see below). Curves were defined in standardized measure PT (proximal thoracic), TH (thoracic or main thoracic), and TL/L (Thoracolumbar, lumbar). Thoracic kyphosis was measured from TH2 to T12 and lumbar lordosis from S1 to L1.

$$\begin{aligned} \text{Max } \sum \text{Cobb angle}_{\text{coronal}} &= \sum \text{Cobb}_{\text{PT-curve}} + \\ &\text{Cobb}_{\text{TH-curve}} + \text{Cobb}_{\text{TL/L-curve}} \end{aligned}$$



**Figure 1.** Spinal Measurement Software workflow: (a) calibration device (to be worn on a radiolucent belt), (b) manual and automatic reference points placement/selection ( $n = 16$ ), and (c) definition of the curvature on both planes.



**Figure 2.** Comparison of the Spinal Measurement Software 3-dimensional reconstruction on matched images, 41.1 cm (a) and the traditional T1-S1 measurement, 38.5 cm (b).

$$\begin{aligned}
 \text{Max } \sum \text{Cobb angle}_{\text{sagittal}} &= \sum \text{Cobb angle}_{\text{TH-kypnosis}} + \\
 &\quad \text{Cobb angle}_{\text{L-lordosis}} \\
 \text{Max } \sum \text{Cobb angle}_{\text{coronal}} + \text{Max } \sum \text{Cobb angle}_{\text{sagittal}} \\
 &= \sum \text{of deformity}(\text{Max 3D deformity})
 \end{aligned}$$

### Statistical Methods

All analyses were performed using IBM SPSS software, version 24 (IBM Corporation, Armonk, NY, USA);  $P$  values  $<0.05$  were considered statistically significant for all analyses. Descriptive data are presented as means and ranges for continuous variables and as frequency (%) for categorical variables. Intraobserver correlation for repeated measurements and interobserver correlation for each level of training and type of measurement (traditional vs 3D) was analyzed and tested for significance using analysis of variance. Pearson correlation was used to evaluate body size and total spinal length. The average spinal length measured for both measurement modalities was compared using a  $t$  test.

Furthermore, the difference in length measurements was expressed in percentage, as well as in relation to the body height. Correlations between length and degree of the deformity were calculated for Cobb measurements in both planes.

### RESULTS

In total, 40 standing whole-spine AP and lateral x-ray images were available for analysis. One of the images was excluded due to unsolvable repetitive errors during the calibration procedure, which occurred for every observer, leaving 39 x-ray images from 35 patients. In 12 patients (34.3%), the calibration device was incompletely displayed (maximum 2 calibration balls missing), which did not affect the calibration due to the automated marker placement option. Patient age was between 8.9 and 26.8 years, with a mean of 15.4 years. Fifteen patients had undergone spinal surgery, resulting in 19 (48.7%) postoperative images. Instrumentation



**Table 1.** Coronal and sagittal deformity.

Overall Coronal Alignment		
Location	n	Cobb Angle, Mean (Range)
PTroximal thoracic	6	36.8 (24.8–63.8)
Thoracic	17	35.6 (17.1–64.7)
Thoracolumbar/lumbar	7	30.2 (10.5–42.3)
Neutral (Cobb <11°)	9	5.6 (0.00–11.4)

Overall Sagittal Alignment	
Sagittal Alignment	Cobb Angle, Mean (Range)
Kyphosis	34.8 (14.7–73.0)
Lordosis	55.6 (35.1–73.50)

did not interfere with the accuracy of the measurements. Average body height was 163.9 cm, range 130 to 189 cm, with 2 missing values. There was a significant positive correlation between body size and spinal length for both measurement modalities. Descriptions of the coronal and sagittal deformity can be found in Table 1.

The Pearson intraclass correlation for the traditional T1-S1 distance was 0.86 ( $P < 0.0001$ ) and for the 3D measurement was 0.88 ( $P < 0.0001$ ), respectively. The intraobserver variance for both types of measurements did not show a significant difference. The intraclass correlation coefficient was excellent for repeated measurement with both the traditional measurement and the SMS software, as well as for interobserver correlations (Table 2).

Using the traditional T1-S1 distance, the overall mean length of the spine measured 40.4 cm (range 27.5–51.4), accounting for 24.6% (95% CI 24.1–25.1) of the total body length. This was significantly lower ( $P < 0.0001$ ) compared with the 3D SMS measurement with a mean length of 43.2 cm (range 28.9–53.8), representing 26.3% (95% CI 25.8–26.8) of total body length. The absolute difference between the 2 measurement methods averaged 2.8 cm (6.3%) with a range from 0.5 to 6.1 cm (Figure 3).

There was a significant positive correlation between the total extend of the deformity (see above) and the length difference between the traditional and the 3D measurement (Figure 3). The mean of the combined sagittal Cobb angle (Max Sum Cobb Angle<sub>sagittal</sub>) measured significantly higher than the mean of the

combined coronal Cobb angle (Max Sum Cobb Angle<sub>coronal</sub>), 89.5°<sub>sagittal</sub> vs 59.9°<sub>coronal</sub>, respectively ( $P < 0.001$ ). The sagittal profile had therefore a larger impact on the correlation with the length (coronal profile  $R^2 = 0.319$ , sagittal profile  $R^2 = 0.561$ ) (Figure 4).

## DISCUSSION

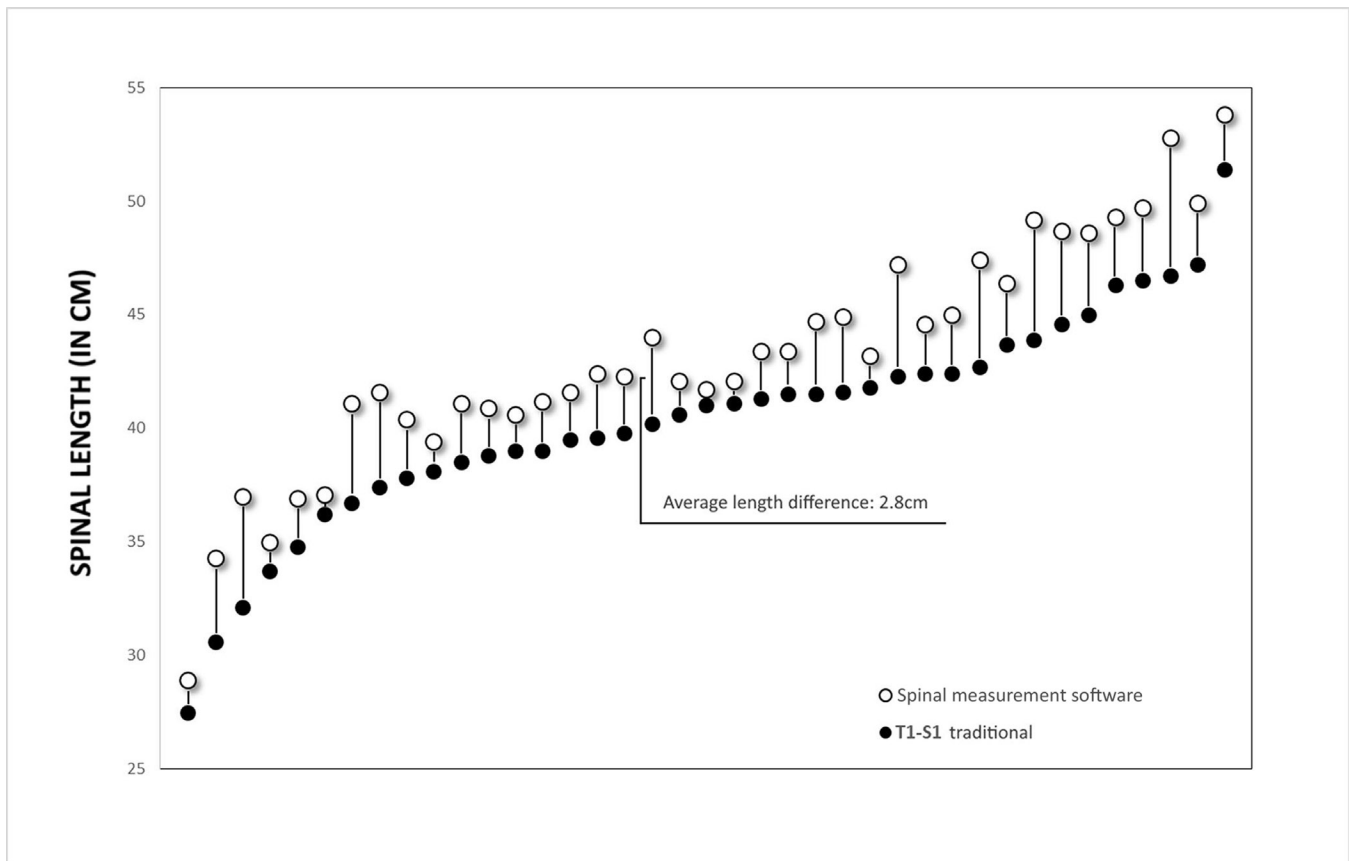
In this study, we were able to show that standard 2-dimensional measurements on x-ray images underestimate the true extent of the deformity and therefore the length of the spine. The real 3D length of the spine is significantly longer than it is measured by the traditional approach. The measured difference correlates positively with the extent of the deformity.

As spinal length and growth are important parameters, this has a significant impact on decision-making and the treatment plan when caring for pediatric patients with spinal deformities. The development of restrictive pulmonary disease, for example, is a major threat for patients with PT deformity who require fusion of more than 4 segments. Measurement of the spinal length and/or T1-T12 distance<sup>2</sup> combined with thorax size<sup>1</sup> serves as guides when to plan the definitive fusion. This raises the discussion of whether such planning should rely rather on 3D length than on uniplanar assessments. Also when using growth guiding systems, monitoring of spinal growth is more accurate. The choice between operative and conservative treatment especially in young children methods can be supported.<sup>16</sup>

The SMS and calibration device offer the possibility to merge standard radiographic images and allow 3D reconstruction. The software is a validated, easy-to-use program that permits measurements even on compressed images, such as jpeg format files. The accuracy of the measurements was proven to be high, with an error below 5 mm when comparing the reconstruction to CT images.<sup>12</sup> We were now able to show an excellent inter-rater agreement for the measurements, for different levels of training. This tool could therefore be helpful to pediatric orthopedic spine surgeons.

**Table 2.** Inter- and intraobserver correlations.

Measure	Repeated Measurements, ICC (95% CI)		Interobserver, ICC (95% CI)	
3-Dimensional length	Junior	0.993 (0.988–0.996)	Junior/fellow	0.980
	Fellow	0.983 (0.971–0.990)	Fellow/senior	0.972
	Senior	0.954 (0.919–0.975)	Senior/junior	0.974
			Average	0.989 (0.978–0.995)
Traditional	Junior	0.997 (0.987–0.999)	Junior/fellow	0.988
	Fellow	0.991 (0.984–0.995)	Fellow/senior	0.988
	Senior	0.999 (0.988–0.999)	Senior/junior	0.993
			Average	0.995 (0.989–0.998)



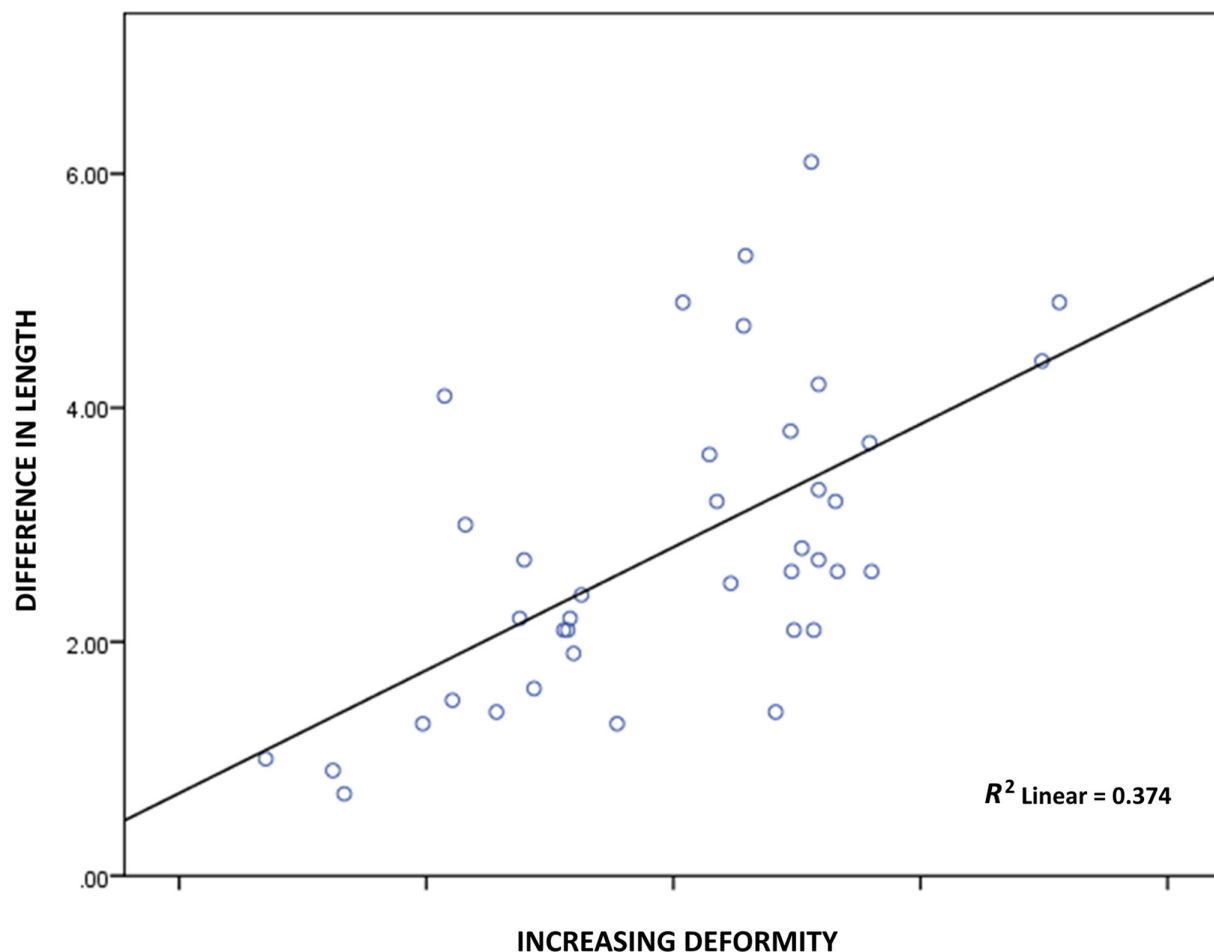
**Figure 3.** Visual representation of each spinal length measurement, comparing the traditional T1-S1 measurement (black circles) to the Spinal Measurement Software 3-dimensional measurement (white circles).

Other applications might also serve patient care. For example, the estimation of gain in body height after surgical correction in patients with AIS remains unclear. Based on a mathematical model, Shi et al showed that the effect of surgical lengthening in patients with posterior spinal fusion for AIS correction was strongly dependent on the severity of the Cobb angle.<sup>17</sup> However, calculations of curve progression based on loss of body height and Cobb angle were shown to be inadequate to monitor the true length of the spine.<sup>4</sup> We were also able to show that the difference of the traditional T1-S1 distance compared with the true 3D appearance correlated significantly with the increasing extent of the deformity. Interestingly, the sagittal profile had a higher impact on the true length. However, the sagittal profile will be relatively untouched by surgical correction, except in patients with hyperkyphosis correction. The length gain in AIS correction mainly depends on the coronal Cobb angle. The majority of cases in our cohort were patients with main thoracic curves ( $n = 17$ ). The mean length difference between the traditional and 3D measurements was 2.8 cm. In a large series of over a 100

AIS patients undergoing spinal fusion, Spencer et al found a similar gain in spinal length of average 2.7 cm.<sup>18</sup>

The SMS reconstruction further allows a visual representation of the spinal deformity in 3D, without the need for a CT image. This gives a better impression of the curve formation, as the true magnitude of the curve might be underestimated on standard films due to the rotational component.<sup>19</sup> Such reconstructions and visualizations help the surgeon to better understand the deformity and plan the correction. New low-dose biplanar imaging solutions also offer and advertise this possibility.<sup>10</sup> However, such technologies are expensive, and software solutions like the one presented in this study could offer a valid alternative also for surgeons and in areas where such new x-ray technologies are not yet available or affordable.

In the future, the data from the software might also be included and correlated with further biomechanical analysis and evaluation of stiffness and/or curve flexibility. Those features might be integrated in recently emerging 3D classification systems for AIS.<sup>20</sup> However, at this time those remain more scientific in nature.



**Figure 4.** Scatter plot and Pearson correlation of difference in length (between the 3-dimensional [3D] Spinal Measurement Software and the traditional measurement) over the deformity (3D).

There are limitations to our study and the software. First, the software is not approved for medical use according to the medical device regulation. Additional measurement options, such as direct Cobb angles measurements on the 3D reconstruction are still under development. Furthermore, our sample size was relatively low, which limited the feasibility of subgroup analysis. Calibration of the images (ie, markers placement) is the most critical part of the measurement. The automated marker placement option supports the observer, but manual fine-tuning is critical to accurately merge the images.

## CONCLUSION

The traditional T1-S1 distance significantly underestimates the true length of the spine, and the degree of the deformity correlates with the length difference. The 3D reconstruction gives a more accurate impression of the true shape of the spine. Such reconstruction from standard radiographs could be useful to better plan and

evaluate treatment outcomes in pediatric patients with spinal deformities, for example, to evaluate active or passive growth preserving surgical techniques or when assessing the evolution of conservatively treated pediatric spinal deformities. Furthermore, simple visualization of the actual 3D shape of the spine can play a role in establishing new 3D classifications, and objectification of the actual length of the spine may aid in improving outcomes after scoliosis surgery.

## REFERENCES

1. Campbell RM, Smith MD. Thoracic insufficiency syndrome and exotic scoliosis. *J Bone Joint Surg Am.* 2007;89 Suppl 1:108–122. doi:10.2106/JBJS.F.00270
2. Karol LA, Johnston C, Mladenov K, Schochet P, Walters P, Browne RH. Pulmonary function following early thoracic fusion in non-neuromuscular scoliosis. *J Bone Joint Surg Am.* 2008;90(6):1272–1281. doi:10.2106/JBJS.G.00184
3. Fletcher ND, Bruce RW. Early onset scoliosis: current concepts and controversies. *Curr Rev Musculoskelet Med.* 2012;5(2):102–110. doi:10.1007/s12178-012-9116-0

4. Tyrakowski M, Kotwicki T, Czubak J, Siemionow K. Calculation of corrected body height in idiopathic scoliosis: comparison of four methods. *Eur Spine J*. 2014;23(6):1244–1250. doi:10.1007/s00586-014-3275-1
5. Studer D, Heidt C, Büchler P, Hasler CC. Treatment of early onset spinal deformities with magnetically controlled growing rods: a single centre experience of 30 cases. *J Child Orthop*. 2019;13(2):196–205. doi:10.1302/1863-2548.13.180203
6. Bjure J, Grimby G, Nachemson A. Correction of body height in predicting spirometric values in scoliotic patients. *Scand J Clin Lab Invest*. 1968;21(2):191–192. doi:10.3109/00365516809084283
7. Yahara Y, Seki S, Makino H, et al. Three-dimensional computed tomography analysis of spinal canal length increase after surgery for adolescent idiopathic scoliosis: a multicenter study. *J Bone Joint Surg Am*. 2019;101(1):48–55. doi:10.2106/JBJS.18.00531
8. Presciutti SM, Karukanda T, Lee M. Management decisions for adolescent idiopathic scoliosis significantly affect patient radiation exposure. *Spine J*. 2014;14(9):1984–1990. doi:10.1016/j.spinee.2013.11.055
9. Adam CJ, Askin GN, Percy MJ. Gravity-induced torque and intravertebral rotation in idiopathic scoliosis. *Spine (Phila Pa 1976)*. 2008;33(2):E30–E37. doi:10.1097/BRS.0b013e318160460f
10. Pedersen PH, Petersen AG, Østgaard SE, Tvedebrink T, Eiskjær SP. EOS micro-dose protocol: first full-spine radiation dose measurements in anthropomorphic phantoms and comparisons with EOS standard-dose and conventional digital radiology. *Spine*. 2018;43(22):E1313–E1321. doi:10.1097/BRS.0000000000002696
11. Schumann S, Thelen B, Ballestra S, Nolte L-P, Büchler P, Zheng G. X-ray image calibration and its application to clinical orthopedics. *Med Eng Phys*. 2014;36(7):968–974. doi:10.1016/j.medengphys.2014.04.001
12. Berger S, Hasler C-C, Grant CA, Zheng G, Schumann S, Büchler P. A software program to measure the three-dimensional length of the spine from radiographic images: validation and reliability assessment for adolescent idiopathic scoliosis. *Comput Methods Programs Biomed*. 2017;138:57–64. doi:10.1016/j.cmpb.2016.10.012
13. Biomechanics IfSTa 2019 Spinal Measurement Software. [https://www.artorg.unibe.ch/research/cb/research/software/index\\_eng.html](https://www.artorg.unibe.ch/research/cb/research/software/index_eng.html).
14. Popović ZB, Thomas JD. Assessing observer variability: a user's guide. *Cardiovasc Diagn Ther*. 2017;7(3):317–324. doi:10.21037/cdt.2017.03.12
15. O'Brien M, Kuklo T, Blanke K, et al. Radiographic Measurement Manual. Medtronic Sofamor Danek, USA. 2008.
16. Senkoylu A, Riise RB, Acaroglu E, Helenius I. Diverse approaches to scoliosis in young children. *EFORT Open Rev*. 2020;5(10):753–762. doi:10.1302/2058-5241.5.190087
17. Shi B, Mao S, Xu L, et al. Factors favoring regain of the lost vertical spinal height through posterior spinal fusion in adolescent idiopathic scoliosis. *Sci Rep*. 2016;6:29115. doi:10.1038/srep29115
18. Spencer HT, Gold ME, Karlin LI, Hedequist DJ, Hresko MT. Gain in spinal height from surgical correction of idiopathic scoliosis. *J Bone Joint Surg Am*. 2014;96(1):59–65. doi:10.2106/JBJS.L.01333
19. Stagnara P, Queneau P, Archimbaud J. Examen radiologique des scolioses essentielles. *Journal de Radiologie, d'électrologie & Archives d'électricité Médicale*. 1957;38:149–157.
20. Donzelli S, Poma S, Balzarini L, et al. State of the art of current 3-D scoliosis classifications: a systematic review from a clinical perspective. *J Neuroeng Rehabil*. 2015;12(91). doi:10.1186/s12984-015-0083-8

**Funding:** The authors received no financial support for the research, authorship, and/or publication of this article.

**Declaration of Conflicting Interests:** The authors report no conflicts of interest in this work.

**Corresponding Author:** Christoph Heidt, University Children's Hospital Basel: Universitäts Kinderspital beider Basel, Spitalstrasse 33, 4056 Basel, Switzerland; christoph.heidt@web.de

Published 27 October 2022

This manuscript is generously published free of charge by ISASS, the International Society for the Advancement of Spine Surgery. Copyright © 2022 ISASS. To see more or order reprints or permissions, see <http://ijssurgery.com>.