

Posterior Fixation Without Debridement for Vertebral Body Osteomyelitis and Discitis: A 10-Year Retrospective Review

Sarah E. Lindsay, Hanne Gehling, Won Hyung A. Ryu, Jung Yoo and Travis Philipp

Int J Spine Surg 2023, 17 (6) 771-778

doi: <https://doi.org/10.14444/8541>

<http://ijssurgery.com/content/17/6/771>

This information is current as of May 9, 2024.

Email Alerts Receive free email-alerts when new articles cite this article. Sign up at:
<http://ijssurgery.com/alerts>

Posterior Fixation Without Debridement for Vertebral Body Osteomyelitis and Discitis: A 10-Year Retrospective Review

SARAH E. LINDSAY, MD¹; HANNE GEHLING, MD¹; WON HYUNG A. RYU, MD, MSc, MTM²; JUNG YOO, MD¹; AND TRAVIS PHILIPP, MD¹

¹Department of Orthopaedics and Rehabilitation, Oregon Health and Science University, Portland, OR, USA; ²Department of Neurosurgery, Oregon Health and Science University, Portland, OR, USA

ABSTRACT

Background: Surgical treatment of vertebral osteomyelitis, discitis, and epidural abscesses is indicated in the setting of failure of antibiotic therapy, neurological deficits, epidural abscess, or spinal instability/deformity. Historically, surgical treatment mandated aggressive debridement and spinal stabilization. However, there is growing evidence that direct debridement may not be necessary and may contribute to morbidity. The purpose of this study was to evaluate the efficacy of posterior instrumentation without debridement in treating spinal infections.

Methods: A retrospective medical record review was performed to identify patients treated with posterior instrumentation for spontaneous spinal infections. Success of treatment was determined based on postoperative ambulatory status, surgical complications, and need for revision surgery.

Results: Twenty-seven patients treated with posterior-only long-segmented rigid fixation without formal debridement of infected material were included. The most common indications for surgical intervention included spinal instability (67%), neurologic compromise (67%), and failure of prolonged antibiotic treatment (63%). There were no recurrent deep infections in 21 of 22 patients who had long-term follow-up. Four patients required revision surgery, and 3 additional patients requested elective hardware removal. Postoperatively, 70% were ambulatory with no assistive devices postoperatively.

Conclusions: Vertebral osteomyelitis/discitis are challenging medical problems. Single-stage long-segment fusion without formal debridement combined with antibiotics is effective in the management of spontaneous spinal infections.

Clinical Relevance: The present study suggests that acute instrumentation without anterior debridement is associated with a resolution of infection and improvements in neurologic deficits in patient with spontaneous spine infections.

Level of Evidence: 4.

Other and Special Categories

Keywords: vertebral body osteomyelitis, discitis

INTRODUCTION

Spinal infection collectively refers to infection affecting the vertebral body, the intervertebral disc, and/or the nearby soft tissues (such as the dura). These infections may occur by direct inoculation (penetrating trauma, open fractures, and surgery), by contiguous spread from local infections, or by hematogenous seeding.^{1,2} The vertebral body is the third most common anatomic site of osteomyelitis from hematogenous seeding, and the lumbar and thoracic spines are most commonly affected.^{3,4} There are considerable variations in practice patterns, and controversies exist regarding when to pursue operative vs nonoperative management and whether instrumentation is indicated in the setting of infection. In general, standard medical management usually consists of 6–8 weeks of intravenous antibiotics and can be effective in the vast majority of cases,

but surgical intervention can be indicated in persistent infection and in cases of worsening neurological deficits or bony instability.^{5–8} An estimated 10%–27% of spinal infection cases are treated with surgery.^{6,9}

Classically, surgical management of spondylodiscitis consisted of anterior debridement with or without posterior instrumentation and anterior column reconstruction.^{10–12} While the placement of the hardware in the setting of acute infection was previously controversial, it has been recognized as an acceptable part of care if there is a need to restore spinal stability and prevent the development of kyphotic deformity.^{13–17} Although the anterior debridement and instrumentation technique is effective in addressing both the infection and kyphotic deformity, circumferential or combined anterior/posterior procedures can be associated with significant morbidity.¹⁸ Posterior long-segment fusion without direct

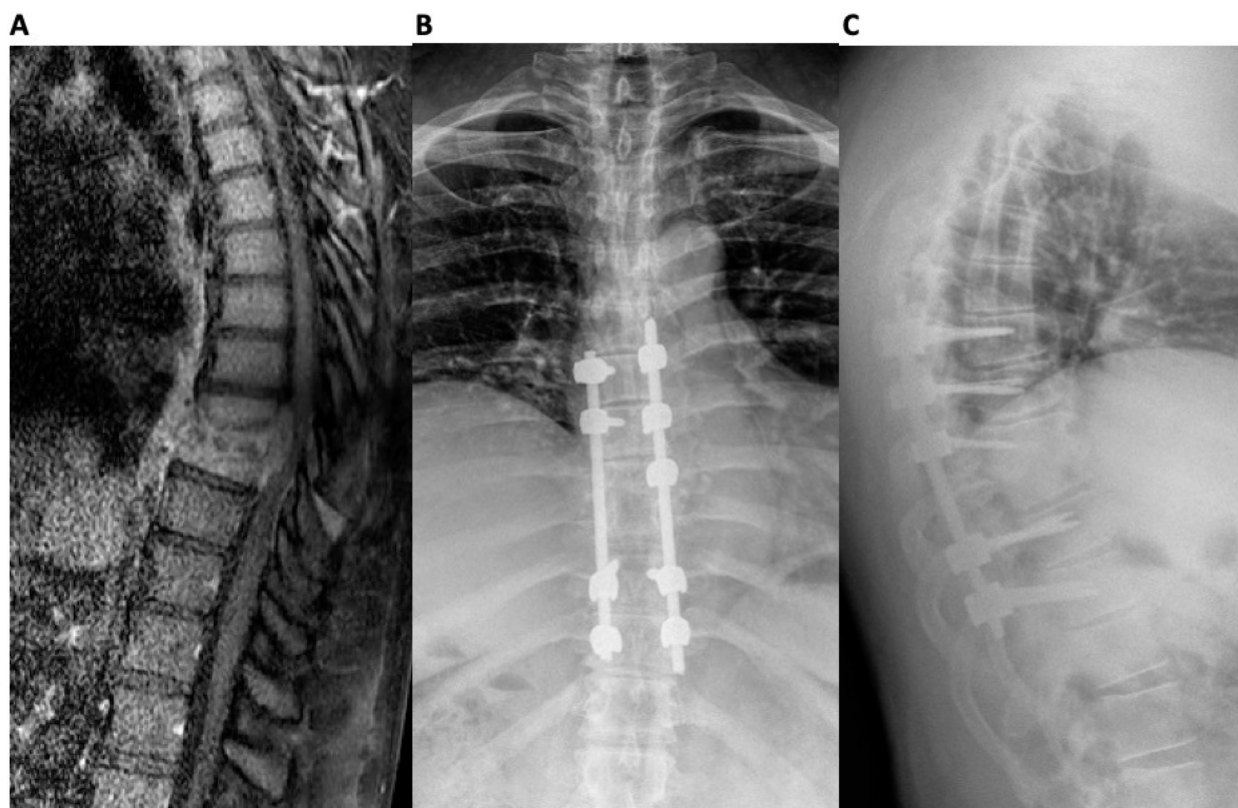


Figure. Preoperative magnetic resonance image (A) demonstrates focal T2 hyperintensity at T8–T9 consistent with discitis with an associated epidural phlegmon resulting in central stenosis. Postoperative radiographs (B and C) demonstrate a fusion of the T8 and T9 vertebral bodies 6 months after posterior fixation without debridement.

debridement of the vertebral body and disc space has been proposed as a technique to mitigate the complications associated with debridement¹⁹ (Figure).

In 2014, our center published a case series reviewing patients treated at our institution between 2007 and 2011 with posterior long-segment fusion without formal debridement for spinal infections.²⁰ None of the 15 patients treated with this technique required reoperation or recurrent antibiotic therapy for spinal infection. Despite this preliminary case series, there remains a relative lack of research investigating the efficacy of this technique. The purpose of our study was to assess the efficacy of posterior long-segment fusion without formal debridement in the treatment of spontaneous spinal infections in a larger patient cohort over a longer period (2011–2021).

METHODS

Medical Record Review

All patients treated surgically for spontaneous spinal infections at a Level 1 academic center (2011–2021) were identified via retrospective medical record review.

Inclusion criteria were patients aged 18 years or older diagnosed with vertebral osteomyelitis/discitis who underwent posterior spinal instrumentation without direct debridement of the vertebral body and/or disc space. Patients underwent posterior decompression as part of the index procedure if there was concomitant canal stenosis. Laminectomy was for epidural abscess only targeted at the epidural infection and did not include debridement of the infected vertebral body or disc space.

Exclusion criteria were patients with epidural abscesses without spinal instability who were treated with laminectomies. Spinal epidural abscess in the absence of osteodiscitis was excluded because the decision to instrument would likely have been determined by the amount of bony instability secondary to the decompression rather than as an adjunct to treatment for the infection itself. We did include patients who had decompression of spinal epidural abscess in addition to vertebral body osteomyelitis and/or discitis. We also excluded patients treated for late sequelae of osteomyelitis without active infection.

The purpose of our study was to investigate the efficacy of posterior fixation without debridement in the

setting of discitis/osteomyelitis, and, as such, patients who had undergone anterior and/or extensive debridement previously and were subsequently treated with posterior spinal instrumentation without direct debridement of the same location were excluded. We included patients who had undergone epidural abscess decompression or limited debridement previously. Patients treated for vertebral osteomyelitis/discitis secondary to postoperative infections from other spine surgeries were excluded because we were interested only in spontaneous *de novo* infections. We included patients with a remote history of spine surgery at unaffected levels.

Demographics and surgical procedure details were collected from the medical record.

Patient Care and Surgical Technique

Patients were admitted to the internal medicine service, and the inpatient infectious disease service was consulted upon patient presentation. Multidisciplinary care discussions were conducted, and the decision to treat nonoperatively vs operatively was made collectively between the care teams and the patient. Care was taken to consider patient factors including medical comorbidities, infectious burden, response to nonoperative treatment, and need for source control. Development of neurological deficits and radiographic evidence of progressive spinal instability were also considered.

When the decision was made to proceed with operative intervention and the patient was medically optimized for surgery, the patient was brought back to the operating room and positioned prone. For patients treated with open surgery (the majority of patients), a midline incision was made sharply to the level of the fascia, and subperiosteal dissection was then performed to expose the desired levels (2 levels above and below the diseased levels for stabilization). In patients undergoing percutaneous fixation, levels were localized radiographically, and small incisions were made. Instrumentation was then performed, followed by decompression (in most cases). Most patients then underwent a formal fusion, and in these patients, decorication was performed. Local autograft was used, augmented in some cases by demineralized bone matrix, allograft, or bone morphogenetic protein, to promote fusion. In all patients, the wound was then irrigated, drains were placed, and the wound was closed in a layered fashion. Postoperatively, patients remained admitted for additional intravenous antibiotics and rehabilitation.

Outcome Measures

The length of postoperative spinal follow-up was ascertained from the medical record, and treatment success was gauged by the presence of surgical complications, postoperative neurologic status/mobility, need for revision surgery, and need for hardware removal. Most patients also were followed postoperatively by infectious disease specialists. Details regarding the duration and type of intravenous and oral antibiotic regimens were collected. Recurrent positive blood cultures or repeat hospitalizations for infectious disease were reviewed and analyzed for possible treatment failure.

Statistical Analysis

Descriptive statistics including means, SDs, and frequency counts were performed to characterize the study cohort.

RESULTS

During the study period, 1210 patients at our institution were treated for osteomyelitis/discitis. Seventy-four of these patients failed nonoperative management and required surgery (rate of surgery: 6.1%), and of these patients, 27 patients (36.5% of surgical cases) met the inclusion criteria for this case series.

In our series of 27 patients, diagnoses included vertebral body osteomyelitis and discitis with or without epidural phlegmon. The most commonly affected levels were in the lower thoracic (T9–T12) and lumbar spines (L1–L4). The average patient age was 61.5 ± 11.3 years. Thirty-three percent of the patients were women. Three patients had previously had spine surgery: 1 patient had a previous (7 years prior) posterior spinal instrumented fusion 1 vertebral body above the affected levels for degenerative spine disease; 1 patient had a history of vertebral body osteomyelitis in the same location that failed isolated epidural abscess decompression and microdiscectomy with multiple rounds of intravenous antibiotics 6 months previously; and 1 patient failed treatment with a limited posterior irrigation and debridement (I&D) of soft tissues but not spinal elements 5 months previously.

Almost all patients in our cohort underwent a trial of nonoperative management first. Nonoperative management was effective in the majority of patients who received care at our institution (93.9%). The most common indications for operative intervention were the development of a neurological deficit, which occurred in 18 patients (67%), and spinal instability with progressive collapse or pathological fracture of at least one

vertebral body, which was present in 18 patients (67%). Seventeen patients (63%) had documented failure of medical management (antibiotics). Ten patients (37%) had persistent bacteremia and were indicated for surgery for source control. Patients who did not undergo a trial of nonoperative management initially were taken to the operating room urgently due to significant neurological deficits in the setting of spinal compression.

All patients were treated with posterior-only long-segmented rigid fixation without debridement of the disc or vertebral body. Most patients had formal posterolateral fusions, though 2 patients underwent percutaneous fixation. Most patients (67%) had at least 2 levels of fixation above the affected levels, while a minority (33%) had just 1 level of fusion above the affected level. Twenty patients (74%) had either at least 2 levels of fixation below the affected levels or were fused to the pelvis. Neurological decompression was performed in all but 5 cases. Local autograft was the most commonly used bone graft material; bone morphogenetic protein was used in only 3 patients. Mean operative time was 206 ± 86.7 min. Mean blood loss was 730 ± 364 mL. One patient experienced a dural tear, and 2 patients died of cardiac arrest in the acute postoperative period. All other immediate perioperative courses were uncomplicated.

The most commonly isolated microorganism was methicillin-resistant *Staphylococcus aureus* (MRSA; 8 patients) followed by methicillin-susceptible *Staphylococcus aureus* (MSSA; 5 patients). Twenty-three patients were treated with intravenous (IV) antibiotics postoperatively for an mean of 6.7 ± 2.9 weeks. One patient was not compliant with recommended intravenous ceftriaxone and self-discontinued infusions at 4 weeks (antibiotics were ordered for 8 weeks). The remainder of patients were compliant with recommended intravenous antibiotic regimens, and once cultures were finalized and antibiotics were narrowed, no changes to initial recommendations were made. Of those treated for bacterial infections, 15 (63%) were started on oral antibiotics at the conclusion of IV treatment, and 10 were instructed to continue these oral antibiotics for life (Table 1).

Three patients who were not treated with prolonged IV antibiotics had cultures that were notable for *Candida albicans*; these patients were instead administered oral fluconazole. One patient had no growth on intraoperative cultures. Given the fact that this patient had received 6 weeks of vancomycin preoperatively, had significant medical comorbidities, and demonstrated improvement postoperatively without signs of

active infection, the decision was made to not administer additional antibiotics (Table 1).

The median follow-up length was 9 months (range: 0–39 months). Ten patients were followed for at least 1 year. Three patients did not follow-up. There were no recurrent deep infections in 21 of 22 patients who had long-term follow-up. One patient who was initially treated with percutaneous stabilization required revision surgery with an anterior discectomy due to persistent infection. One patient experienced wound dehiscence, which was successfully treated with local wound care.

Significant neurological improvement was found postoperatively in the majority of our cases. 70% were ambulatory with no assistive devices postoperatively (Table 2).

Four patients required revision surgery. One year postoperatively, 1 patient had a recurrent paraspinal abscess with subsequent hardware loosening, which was successfully managed with irrigation and debridement and hardware removal. One patient developed radiculopathy 4 months after the index procedure and required a repeat decompression. One patient initially underwent T9–L2 posterior instrumented fusion for the management of discitis at T11–T12 and subsequently developed severe kyphoscoliosis and required a revision anterior/posterior fusion with a longer construct (T3 to pelvis). The cause for the failure of fusion in this patient was thought to be secondary to extensive bony destruction. One patient required a revision iliac screw due to rod/screw dissociation after a fall. Three patients elected to have their hardware removed (Table 2).

DISCUSSION

Our study retrospectively reviewed all patients treated at our institution between 2011 and 2021 who underwent posterior long-segment fusion without anterior debridement of vertebral body and/or disc. This was a follow-up study to a 2014 study at our institution that reviewed 15 patients treated between 2007 and 2011. Our study in a larger cohort corroborates previous findings: acute instrumentation without anterior debridement was associated with the resolution of infection in almost all cases.

There is evidence in the literature that the incidence of vertebral osteomyelitis/discitis is increasing, particularly in older patients and in those with medical comorbidities such as diabetes, renal failure, and immunosuppression.²¹ Many surgical techniques have been described in the literature for the management of spinal infections. Spinal infections typically affect the anterior spine; therefore, an anterior surgical approach

Table 1. Diagnosis and management details of patients with vertebral body osteomyelitis and discitis treated with long-segment fusion in the absence of formal debridement.

Case	Indication for Surgery	Prior Treatment	Levels of Disc Space and Bone Involvement	Levels of Fixation Above	Levels of Fixation Below	Organism	IV Antibiotic Type and Duration	Oral Antibiotic Type and Duration
1	Osteomyelitis/discitis and bony instability	IV antibiotics	T11–T12	2	2	No growth on cultures	None	None
2	Osteomyelitis/discitis, neurological deficit, and bony instability	IV antibiotics	L4–L5	2	1 (to pelvis)	No growth on cultures	Daptomycin and Zosyn, 4 wk	Doxycycline, Life
3	Epidural abscess and neurological deficit	Laminectomy	L3–L5	2	1 (to pelvis)	<i>Streptococcus mitis</i>	Ceftriaxone, 6 wk	Not available
4	Epidural abscess, discitis, neurological deficit, and bony instability	None	T8–T9	2	4	MRSA	Nafcillin, 6 wk	Not available
5	Epidural abscess, neurological deficit, and bony instability	None	T5–T6	2	2	MRSA	Vancomycin, 12 wk	Doxycycline, Life
6	Osteomyelitis, epidural abscess, neurological deficit, and bony instability	Oral fluconazole	L1–L3	4	3	<i>Candida</i>	None	Fluconazole and Clindamycin, lost to follow-up
7	Discitis and bony instability	IV antibiotics and laminectomy	L5–S1	1	1 (to pelvis)	MRSA	Vancomycin and Daptomycin, 12 wk	Doxycycline, Life
8	Osteomyelitis/discitis	IV antibiotics	L2–L3	1	1	MSSA	Ceftriaxone, 4 wk	Not available
9	Osteomyelitis, neurological deficit, and bony instability	IV antibiotics	L5–S1	1	1 (to pelvis)	MSSA	Vancomycin, 8 wk	Not available
10	Osteomyelitis/discitis and bony instability	None	T7–T8	2	2	MRSA	Vancomycin, 8 wk	Doxycycline, Life
11	Osteomyelitis/discitis and neurological deficit	Bracing	L2–L3	1	1	<i>Streptococcus anginosus</i>	Ceftriaxone, 6 wk	Amoxicillin, Life
12	Osteomyelitis and bony instability	IV antibiotics	L2–L3	2	2	MSSA	Cefazolin, 6 wk	Doxycycline, Life
13	Epidural abscess, neurological deficit, and bony instability	None	T9–T10	3	3	No growth on cultures	Vancomycin and ceftriaxone, 2 wk	None
14	Osteomyelitis/discitis and bony instability	IV antibiotics	T9–T10	3	2	MRSA	Vancomycin, 8 wk	Doxycycline, Life
15	Epidural abscess and neurological deficit	None	T9–T10	3	3	MRSA	Daptomycin, 8 wk	Doxycycline, Life
16	Osteomyelitis/discitis, neurological deficit, and bony instability	None	T9–T10	2	3	<i>Candida</i>		Fluconazole, 24 wk
17	Osteomyelitis, neurological deficit, and bony instability	IV antibiotics	T11–T12	2	2	<i>Corynebacterium</i>	Vancomycin	Amoxicillin, Life
18	Osteomyelitis/discitis and bony instability	IV antibiotics	L3–L4	1	2 (to pelvis)	MSSA	Ceftriaxone	Doxycycline, Life
19	Discitis and epidural abscess	IV antibiotics and computed tomography-guided psoas drainage	L1–L4	1	1	MRSA	Ceftaroline, Vancomycin	Doxycycline, Life
20	Epidural abscess and neurological deficit	IV antibiotics	T6–T7	1	1	MSSA	Cefazolin	Not available
21	Osteomyelitis, epidural abscess, and neurological deficit	None	T11–L1	1	1	<i>Streptococcus anginosus</i>	Penicillin, Vancomycin	Amoxicillin, 24 wk
22	Discitis and neurological deficit	IV antibiotics	T9–T11	3	1	<i>Escherchia coli</i>	Ceftriaxone	Not available
23	Discitis, epidural abscess, neurological deficit, and bony instability	IV antibiotics	L4–L5	2	1 (to pelvis)	<i>Klebsiella</i>	Ertapenem, Vancomycin	Clindamycin, 52 wk
24	Discitis, neurological deficit, and bony instability	None	T9–T10	2	2	<i>Aggregobacter aphrophilus</i>	CTX	Levofloxacin, 52 wk
25	Discitis and bony instability	IV antibiotics, oral fluconazole, irrigation, and debridement	T11–T12	2	2	<i>Candida</i>		Fluconazole, 24 wk
26	Osteomyelitis/discitis, neurological deficit, and bony instability	IV antibiotics	L2–L3	1	2	<i>Peptostreptococcus</i>	Ertapenem	Not available
27	Osteomyelitis and neurological deficit	IV antibiotics	T11–T12	2	2	MRSA	Ceftaroline	Bactrim, lost to follow-up

Abbreviations: IV, intravenous; MRSA, methicillin-resistant *Staphylococcus aureus*; MSSA, methicillin-susceptible *Staphylococcus aureus*.

was traditionally favored to facilitate access to infected tissues for debridement. Posterior fusion is necessary in addition to debridement to provide stability and reduce the risk of pseudarthrosis and the development of kyphotic deformity. However, combined anterior

debridement with posterior fusion is associated with longer operative times and increased blood loss.^{22,23}

To mitigate these risks, particularly in unstable patients, Fukuta and colleagues described a 2-stage surgery to address spinal infections in which posterior

Table 2. Outcomes and follow-up for case series cohort.

Case	Preoperative Neurological Deficit	Preoperative Frankel Grade	Postoperative Frankel Grade	Ambulatory Status at Final Follow-Up	Intraoperative Complications	Postoperative Complications and Revision Surgery	Hardware Removal
1	No	D (baseline)	C	Wheelchair	None	First surgery was percutaneous stabilization; required revision anterior discectomy due to persistent infection	Yes
2	Yes	D	E	Ambulatory	None	Patient fell and required revision left iliac screw due to screw/rod dissociation	Yes
3	Yes	E	E	Ambulatory	Dural tear (conversion from a laminectomy to a PSIF with repeat surgical decompression)	None	No
4	Yes	E	E	Ambulatory	None	None	No
5	Yes	C	D	Walker	None	None	No
6	Yes	E	E	Ambulatory	None	None	No
7	No	E	E	Ambulatory	None	None	No
8	No	E	E	Ambulatory	None	1 y postoperatively, the patient presented with available abscess after not taking antibiotics and loose hardware. I&D and hardware removal was performed.	Yes
9	Yes	E	E	Ambulatory	None	None	No
10	No	E	E	Ambulatory	None	None	No
11	Yes	D	E	Ambulatory	None	None	No
12	No	C (baseline)	C	Nonambulatory (baseline)	None	None	No
13	Yes	D	C	Nonambulatory (deceased)	None	Deceased 1 wk postoperatively due to hypoxia/cardiac arrest	No
14	No	E	E	Ambulatory	None	None	No
15	Yes	A	B	Nonambulatory (baseline)	None	Wound dehiscence successfully treated by local wound care	No
16	Yes	D	E	Ambulatory	None	None	No
17	Yes	D	E	Ambulatory	None	Patient developed severe kyphoscoliosis and required revision posterior/anterior with longer fusion construct	No
18	No	E	E	Ambulatory	None	None	No
19	No	D	E	Ambulatory	None	None	No
20	Yes	B	Not assessed	Not assessed	None	Deceased 9 d postoperatively due to cardiac arrest, anoxic brain injury	No
21	Yes	C	C	Nonambulatory	None	None	No
22	Yes	E	C	Ambulatory	None	None	No
23	Yes	D	E	Ambulatory	None	None	No
24	Yes	A	C	Stands with walker	None	None	No
25	No	E	E	Ambulatory, deceased	None	Pain and radiculopathy postoperatively requiring L4/5 decompression	No
26	Yes	D	E	Ambulatory	None	None	No
27	Yes	D	E	Ambulatory	None	None	No

Abbreviations: I&D, irrigation and debridement; PSIF, posterior spinal instrumentation and fusion.

spinal instrumentation was performed first followed later by anterior debridement and bone grafting.²⁴ Anterior debridement was done 10 to 12 weeks after posterior fusion, and the authors reported successful eradication of infection in all patients. The success of this technique prompted the same research group to investigate the efficacy of posterior fusion alone, and in 2012, Fushimi et al described the successful treatment of 6 patients with spinal infections treated with posterior fusion alone.¹⁹

Several additional case series have been published describing the successful management of spinal infections with single-stage long-segment fusion without formal debridement.^{20,25–28} A 2021 systematic review and meta-analysis by Elmajee et al reviewed a total of 102 patients published in case series reports and found improvements in neurological deficits, improvements

in functional outcomes, and successful management of spinal infections without the need for revision surgery in patients treated with single-stage long-segment fusion without formal debridement.²⁹ The authors suggested that stabilization across infected spinal segments may lead to better vascularity and thus improved antibiotic penetration. Single-stage long-segment fusion without formal debridement is proposed as an alternative treatment modality in older patients or those with comorbidities, but an anterior approach is recommended in younger patients based on faster recovery, as found by Aljawadi et al.²⁷

Our study corroborates these findings. In our review of 27 patients, we found a resolution of infection in almost our entire cohort. The one patient who required a revision surgery for persistent deep infection initially underwent percutaneous stabilization, suggesting that

more investigation is needed regarding the percutaneous technique as a method by which to treat spinal infections. The other postoperative complications in our cohort included wound dehiscence, symptomatic hardware, and hardware failure in the setting of trauma—all complications associated with routine spinal fusion surgery. Patients who required revision surgery did not differ in terms of age, gender, or fusion construct length from the remainder of the cohort.

We recognize that deciding between operative and nonoperative treatment can be challenging and that some indications remain controversial. At our institution, indications for operative intervention include neurological deficit secondary to spinal cord compression, progression collapse or instability, and need for source control in the setting of bacteremia. Instrumentation is indicated in the setting of radiographic signs of collapse or instability.

We utilize long-segment fixation constructs (fixation of 2 levels above and below) for involved disc space(s)/vertebrae in patients with collapse or instability. Our goal is to immobilize the involved disc space(s) and vertebrae, and long-segment fixation facilitates control of compressive and rotational forces and increases the stiffness across the stabilized segment.

Our treatment outcomes were consistent with those published at our center in 2014. Similar to 2014, the most commonly isolated microorganisms were MRSA and MSSA. Postoperatively, patients with bacterial infections in both cohorts were started on prolonged IV antibiotic therapy. In the 2014 cohort, there were no recurrent deep spinal infections; in the present cohort, only one patient had a recurrent deep spinal infection. On initial preoperative evaluation, 10 of 15 patients (67%) in the 2014 cohort presented with neurological deficits and 9 of 15 (60%) were nonambulatory. On final postoperative evaluation, 8 of 15 patients (53%) were ambulatory with no assistive devices, 6 were ambulatory with assistive devices, and 1 remained nonambulatory. In our cohort, 18 of 27 patients (67%) presented with preoperative neurological deficits, and 7 of 27 (26%) were nonambulatory. On final postoperative evaluation, 19 of 27 (70%) were ambulatory with no assistive devices, 2 were ambulatory with assistive devices, 4 remained nonambulatory, and 2 patients died shortly after surgery secondary to cardiovascular events.

There are several limitations to our study. Our study is a retrospective case series and is therefore limited in generalizability. We do not have a control population, and it is therefore not possible given the constraints of our study design to compare differences in outcomes based on treatment. Our cohort is relatively small due to the relatively uncommon nature of the diagnoses (vertebral osteomyelitis

and discitis) and the procedure. The indications for single-stage long-segment fusion without formal debridement are narrow, and success is contingent on the selection of an appropriate patient. Given these strict parameters in the setting of the relative rarity of this condition, conducting a randomized controlled trial would be challenging. Given the complex, heterogeneous, and nuanced nature of spontaneous spinal infections, performing a matched cohort analysis would also be challenging. Thus, we felt that a larger case series over a longer period of time provided valuable insight into the efficacy of this treatment strategy. Our study includes all patients treated with single-stage long-segment fusion without formal debridement at our institution over a 10-year period and represents an extension of our initial case series published in 2014.

The follow-up in our study is somewhat inconsistent. While the majority of patients were followed for at least 9 months, only 10 patients were followed for more than 1 year. Several patients discontinued either orthopedic or infectious disease follow-up; therefore, we are missing information on some individuals. Additionally, laboratory data were not collected in a consistent manner, and we were therefore unable to follow objective measurements such as erythrocyte sedimentation rate and c-reactive protein to assess resolution of the infection. These data could provide valuable insights in future studies.

CONCLUSIONS

Single-stage long-segment fusion without formal debridement combined with antibiotics is effective in the management of spontaneous spinal infections.

REFERENCES

1. Wiley AM, Trueta J. The vascular anatomy of the spine and its relationship to pyogenic vertebral osteomyelitis. *J Bone Joint Surg Br.* 1959;41-B:796–809. doi:10.1302/0301-620X.41B4.796
2. Calhoun JH, Manring MM. Adult osteomyelitis. *Infect Dis Clin North Am.* 2005;19(4):765–786. doi:10.1016/j.idc.2005.07.009
3. Waldvogel FA, Medoff G, Swartz MN. Osteomyelitis: a review of clinical features, therapeutic considerations and unusual aspects. *N Engl J Med.* 1970;282(4):198–206. doi:10.1056/NEJM197001222820406
4. Jaramillo-de la Torre JJ, Bohinski RJ, Kuntz C. Vertebral osteomyelitis. *Neurosurg Clin N Am.* 2006;17(3):339–351. doi:10.1016/j.nec.2006.05.003
5. Roblot F, Besnier JM, Juhel L, et al. Optimal duration of antibiotic therapy in vertebral osteomyelitis. *Semin Arthritis Rheum.* 2007;36(5):269–277. doi:10.1016/j.semarthrit.2006.09.004
6. Butler JS, Shelly MJ, Timlin M, Powderly WG, O'Byrne JM. Nontuberculous pyogenic spinal infection in adults: a 12-year experience from a tertiary referral center. *Spine (Phila Pa 1976).* 2006;31(23):2695–2700. doi:10.1097/01.brs.0000244662.78725.37

7. Bettini N, Girardo M, Dema E, Cervellati S. Evaluation of conservative treatment of non specific spondylodiscitis. *Eur Spine J*. 2009;18(Suppl 1):143–150. doi:10.1007/s00586-009-0979-8
8. Cornett CA, Vincent SA, Crow J, Hewlett A. Bacterial spine infections in adults: evaluation and management. *J Am Acad Orthop Surg*. 2016;24(1):11–18. doi:10.5435/JAAOS-D-13-00102
9. Cheung WY, Luk KDK. Pyogenic spondylitis. *Int Orthop*. 2012;36(2):397–404. doi:10.1007/s00264-011-1384-6
10. Lener S, Hartmann S, Barbagallo GMV, Certo F, Thomé C, Tschugg A. Management of spinal infection: a review of the literature. *Acta Neurochir (Wien)*. 2018;160(3):487–496. doi:10.1007/s00701-018-3467-2
11. Duarte RM, Vaccaro AR. Spinal infection: state of the art and management algorithm. *Eur Spine J*. 2013;22(12):2787–2799. doi:10.1007/s00586-013-2850-1
12. Guérado E, Cerván AM. Surgical treatment of spondylodiscitis. An update. *Int Orthop*. 2012;36(2):413–420. doi:10.1007/s00264-011-1441-1
13. Zarghooni K, Rölinghoff M, Sobottke R, Eysel P. Treatment of spondylodiscitis. *Int Orthop*. 2012;36(2):405–411. doi:10.1007/s00264-011-1425-1
14. Rayes M, Colen CB, Bahgat DA, et al. Safety of instrumentation in patients with spinal infection. *J Neurosurg Spine*. 2010;12(6):647–659. doi:10.3171/2009.12.SPINE09428
15. Sanda M, Singleton A, Yim J, Rahmani R, Sheffels E, Andreshak T. The effect of instrumentation staging on patient outcomes in pyogenic vertebral osteomyelitis: a systematic review. *N Am Spine Soc J*. 2021;8:100083. doi:10.1016/j.xnsj.2021.100083
16. Verla T, North R, Simpson V, Ropper AE. Osteomyelitis-discitis at the thoracolumbar junction and the development of post-infectious spinal deformity: a surgical case series. *Int J Spine Surg*. 2020;14(4):552–558. doi:10.14444/7073
17. Bydon M, De la Garza-Ramos R, Macki M, et al. Spinal instrumentation in patients with primary spinal infections does not lead to greater recurrent infection rates: an analysis of 118 cases. *World Neurosurg*. 2014;82(6):e807–e814. doi:10.1016/j.wneu.2014.06.014
18. Hempelmann RG, Mater E, Schön R. Septic hematogenous lumbar spondylodiscitis in elderly patients with multiple risk factors: efficacy of posterior stabilization and interbody fusion with iliac crest bone graft. *Eur Spine J*. 2010;19(10):1720–1727. doi:10.1007/s00586-010-1448-0
19. Fushimi K, Miyamoto K, Fukuta S, Hosoe H, Masuda T, Shimizu K. The surgical treatment of pyogenic spondylitis using posterior instrumentation without anterior debridement. *J Bone Joint Surg Br*. 2012;94(6):821–824. doi:10.1302/0301-620X.94B6.28632
20. Mohamed AS, Yoo J, Hart R, et al. Posterior fixation without debridement for vertebral body osteomyelitis and discitis. *Neurosurg Focus*. 2014;37(2):E6. doi:10.3171/2014.6.FOCUS14142
21. Thavarajasingam SG, Subbiah Ponniah H, Philipps R, et al. Increasing incidence of spondylodiscitis in England: an analysis of the national health service (NHS) hospital episode statistics from 2012 to 2021. *Brain Spine*. 2023;3:101733. doi:10.1016/j.bas.2023.101733
22. Krödel A, Krüger A, Lohscheidt K, Pfahler M, Refior HJ. Anterior debridement, fusion, and extrafocal stabilization in the treatment of osteomyelitis of the spine. *J Spinal Disord*. 1999;12(1):17–26.
23. Kao F-C, Tsai T-T, Niu C-C, Lai P-L, Chen L-H, Chen W-J. One-stage posterior approaches for treatment of thoracic spinal infection: transforaminal and costotransversectomy, compared with anterior approach with posterior instrumentation. *Medicine (Baltimore)*. 2017;96(42):e8352. doi:10.1097/MD.00000000000008352
24. Fukuta S, Miyamoto K, Masuda T, et al. Two-stage (posterior and anterior) surgical treatment using posterior spinal instrumentation for pyogenic and tuberculous spondylitis. *Spine (Phila Pa 1976)*. 2003;28(15):E302–E308. doi:10.1097/01.BRS.0000083318.40123.5E
25. Mazur MD, Ravindra VM, Dailey AT, McEvoy S, Schmidt MH. Rigid posterior lumbopelvic fixation without formal debridement for pyogenic vertebral diskitis and osteomyelitis involving the lumbosacral junction: technical report. *Front Surg*. 2015;2:47. doi:10.3389/fsurg.2015.00047
26. Dobran M, Iacoangeli M, Nasi D, et al. Posterior titanium screw fixation without debridement of infected tissue for the treatment of thoracolumbar spontaneous pyogenic spondylodiscitis. *Asian Spine J*. 2016;10(3):465–471. doi:10.4184/asj.2016.10.3.465
27. Aljawadi A, Sethi G, Imo E, et al. Medium-term outcome of posterior surgery in the treatment of non-tuberculous bacterial spinal infection. *J Orthop*. 2019;16(6):569–575. doi:10.1016/j.jor.2019.06.021
28. Lin C-P, Ma H-L, Wang S-T, Liu C-L, Yu W-K, Chang M-C. Surgical results of long posterior fixation with short fusion in the treatment of pyogenic spondylodiscitis of the thoracic and lumbar spine: a retrospective study. *Spine (Phila Pa 1976)*. 2012;37(25):E1572–E1579. doi:10.1097/BRS.0b013e31827399b8
29. Elmajee M, Munasinghe C, Aljawadi A, Elawady K, Shuweihe F, Pillai A. Posterior stabilisation without formal debridement for the treatment of non-tuberculous pyogenic spinal infection in frail and debilitated population - a systematic review and meta-analysis. *J Clin Orthop Trauma*. 2021;15:9–15. doi:10.1016/j.jcot.2020.11.009

Funding: The authors received no financial support for the research, authorship, and/or publication of this article.

Declaration of Conflicting Interests: The authors report no conflicts of interest in this work.

Ethical Review Committee Statement: Approval was obtained from the Institutional Review Board of the study university for a retrospective medical record review. This study was performed in accordance with the 1964 Declaration of Helsinki and US Health Insurance Portability and Accountability Act (HIPAA) regulations.

Corresponding Author: Sarah E. Lindsay, Oregon Health & Science University, 3181 Sam Jackson Park Rd L597, Portland, OR 97239, USA; lindsayse@ohsu.edu

Published 16 August 2023

This manuscript is generously published free of charge by ISASS, the International Society for the Advancement of Spine Surgery. Copyright © 2023 ISASS. To see more or order reprints or permissions, see <http://ijssurgery.com>.