

Measurement of occlusion of the spinal canal and intervertebral foramen by intervertebral disc bulge

Mathieu Cuchanski, Daniel Cook, Donald M. Whiting and Boyle C. Cheng

Int J Spine Surg 2011, 5 (1) 9-15

doi: <https://doi.org/10.1016/j.esas.2010.09.004>

<https://www.ijssurgery.com/content/5/1/9>

This information is current as of May 1, 2025.

Email Alerts Receive free email-alerts when new articles cite this article. Sign up at:
<http://ijssurgery.com/alerts>

Biomechanics

Measurement of occlusion of the spinal canal and intervertebral foramen by intervertebral disc bulge

Mathieu Cuchanski, BS ^{a,*}, Daniel Cook, MS ^{b,c}, Donald M. Whiting, MD ^d,
Boyle C. Cheng, PhD ^{b,c}

^a Department of Neuroscience, University of Pittsburgh, Pittsburgh, PA

^b Department of Bioengineering, University of Pittsburgh, Pittsburgh, PA

^c Department of Neurological Surgery, University of Pittsburgh, Pittsburgh, PA

^d Department of Neurosurgery, Drexel University College of Medicine, Pittsburgh, PA

Abstract

Background: Disc protrusion has been proposed to be a possible cause of both pain and stenosis in the lower spine. No previous study has described the amount of disc occlusion of the spinal canal and intervertebral foramen that occurs under different loading conditions. The objective of this study was to quantitatively assess the percent occlusion of the spinal canal and intervertebral foramen by disc bulge under different loading conditions.

Methods: Spinal canal depth and foraminal width were measured on computed tomography-scanned images of 7 human lumbar spine specimens. In vitro disc bulge measurements were completed by use of a previously described method in which single functional spinal units were subjected to 3 separate load protocols in a spine test machine and disc bulge was recorded with an optoelectric motion system that tracked active light-emitting diodes placed on the posterior and posterolateral aspects of the intervertebral disc. Occlusion was defined as percentage of encroachment into area of interest by maximum measured disc bulge at corresponding point of interest (the spinal canal is at the posterior point; the intervertebral foramen is at the posterolateral point).

Results: The mean spinal canal depth and mean foraminal width were 19 ± 4 mm and 5 ± 2 mm, respectively. Mean spinal canal occlusion under a 250-N axial load, ± 2.5 Nm of flexion/extension, and ± 2.5 Nm of lateral bend was $2.5\% \pm 1.9\%$, $2.5\% \pm 1.6\%$, and $1.5\% \pm 0.8\%$, respectively. Mean intervertebral foramen occlusion under a 250-N axial load, ± 2.5 Nm of flexion/extension, and ± 2.5 Nm of lateral bend was $7.8\% \pm 4.7\%$, $9.5\% \pm 5.7\%$, and $11.3\% \pm 6.2\%$, respectively.

Conclusion: Percent occlusion of the spinal canal and intervertebral foramen is dependent on magnitude and direction of load. Exiting neural elements at the location of the intervertebral foramen are the most vulnerable to impingement and generation of pain.

© 2011 SAS - The International Society for the Advancement of Spine Surgery. Published by Elsevier Inc. All rights reserved.

Keywords: Disc bulge; Spine biomechanics

Bulging of the intervertebral discs during normal motion of the spine has been proposed as a potential cause of pain through either compression of the spinal cord or impingement of exiting neural elements.^{1–5} Intervertebral disc protrusion might have a particularly significant impact in patients with pathologic conditions that result in the narrowing of the central spinal canal, lateral spinal canals, or intervertebral foramen. In certain patients, disc bulge has been

attributed to be the main cause of spinal stenosis and spinal claudication.³

It is well known that clinical nerve compression syndromes are the result of spinal canal or foraminal narrowing due to bony or soft-tissue compression. The reported incidence of lumbar radiculopathy is 0.7% to 9.6%.⁶ The pathophysiology of radiculopathy is a function of both direct compression and chemical irritation, with compression being the more severe factor and therefore our area of interest. Degenerative disc disease is the primary culprit. This is a multifactorial phenomenon that includes annular bulging due to disc dehydration, disc bulging or herniation, and eventually, osteophyte formation. Lateral bending, flexion/extension, and axial load can cause or exacerbate neural

Disclaimer: The authors do not report any conflict of interest concerning the materials or methods used in this study or the findings specified in this paper.

* Corresponding author: Mathieu Cuchanski, BS, 83 Cliveden Dr, Newtown, PA 18940. Tel: 215-380-6401; Fax: 412-359-3886.

E-mail address: mcuchanski@gmail.com

element compression, and subsequently, an understanding of what forces result in bulging in which specific areas of the disc can lead to a better understanding of both the pathophysiology and the treatment of radiculopathy.

As discussed in a previous study,⁷ to analyze a possible correlation between disc bulge and compression of neural structures occurring concurrently with the onset of pain, methods are first needed that can accurately estimate the amount of disc bulge occurring during normal motion of the spine. Numerous *in vitro* and finite element model (FEM) studies have been conducted that have assessed both quantitative and qualitative aspects of disc bulge.^{1,2,4,5,8-14} Reported results from these studies have widely varied with regard to both amount and location of disc bulge. Methods and techniques to measure disc bulge have also varied across the spectrum of anatomic and FEM studies that have been conducted over the years.

In a previous study,⁷ a new method of measuring intervertebral disc bulge *in vitro* using optoelectric tracking of active light-emitting diodes (LEDs) with 0.1 mm accuracy¹⁵⁻¹⁷ was developed that we believe provides a precise estimate of disc bulge. Single human cadaveric lumbar spine segments were tested under 3 different load protocols, and disc bulge was determined at 3 specific points of interest on the disc: posterior, posterolateral, and lateral. Disc bulge was defined as radial displacement from the established center of the intervertebral disc. Results from the previous study showed that disc bulge does not occur uniformly at all 3 sites on the disc under all 3 modes of load. The results also suggested that the exiting nerve roots at the location of the intervertebral foramen (the posterolateral point of the disc) are the most vulnerable to impingement and generation of pain. Under flexion/extension and lateral-bend modes of load, the greatest mean disc bulge occurred at the posterolateral point of the disc.

The purpose of this study was to measure the percent occlusion of the spinal canal and the intervertebral foramen by the bulging intervertebral disc under various dynamic loading conditions. The anterior-posterior diameter of the spinal canal (spinal canal depth) and the width of the intervertebral foramen (foraminal width) were measured on computed tomography (CT)-scanned images of specimens used in the previous disc bulge study. The dimensions of the spinal structures measured in this study correspond well with measurements reported by past morphometric studies.^{3,18-21} Disc bulge results from the previously described study were used to assess percent occlusion of the spinal canal and intervertebral foramen. A null hypothesis was formed that no significant differences in percent occlusion at a particular region (spinal canal or intervertebral foramen) would be detected among the 3 different load protocols used in the study.

Materials and methods

Seven human lumbar spine specimens underwent CT scanning and were imported into a DICOM (Digital Imag-

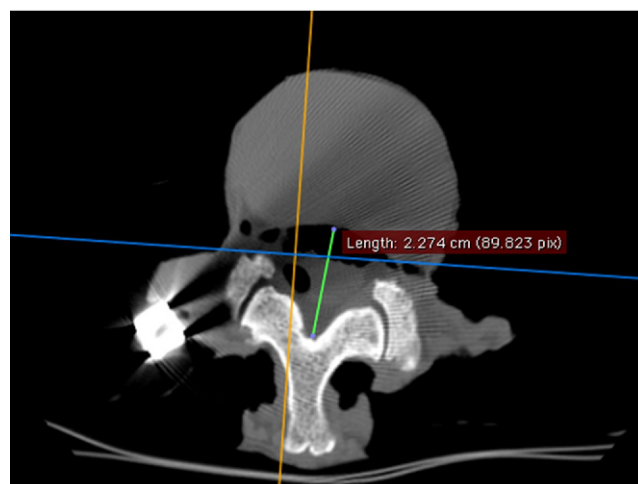


Fig. 1. Measurement of spinal canal depth using eFilm Workstation.

ing and Communications in Medicine) image viewing software program (eFilm Workstation; Merge Healthcare, Milwaukee, Wisconsin). The lumbar specimens were separated into single functional spinal units (FSUs) consisting of 2 vertebral bodies and the disc connecting them. The 15 single FSUs used for this study were carefully prepared, cleaned, and stored at -20°C .

Measurements of the depth of the spinal canal and width of the intervertebral foramen were taken by use of a reoriented gantry angle parallel to the intervertebral disc. The software-based virtual measurement tool allowed a precision of 0.1 mm on measurements of the CT-scanned DICOM images (eFilm Workstation). The spinal canal depth was defined as the distance between the posterior border of the mid-disc body and the junction of the margins of the laminae of the midline of the spinous process (Fig. 1). The foraminal width was defined as the distance between the posterolateral intervertebral disc border (at the mid-disc level) and the border of the superior facet of the inferior vertebral body (Fig. 2).

In vitro intervertebral disc protrusion measurements were completed by use of a previously described method⁷ in which single FSUs were subjected to 3 separate load protocols in a spine test machine, and disc bulge was recorded with an Optotrak Motion System (Optotrak Certus; Northern Digital Instruments, Waterloo, Ontario, Canada) to track active LEDs placed on the posterior, posterolateral, and lateral aspects of the intervertebral disc. The Optotrak 3020 measurement system has a reported root mean square accuracy of 0.1 mm and a resolution of 0.01 mm.¹⁵⁻¹⁷ As shown in Figs. 3 and 4, only the posterolateral and lateral points on the right side of the intervertebral disc were tracked in every specimen tested. Because of the configuration of the tracking system, it was prudent to fully capture a quadrant of the disc bulge rather than the entire 180° of the posterior half of the intervertebral disc. In addition, it is assumed that the intervertebral disc will respond symmetrically to the input loads. Before testing, the location of 4

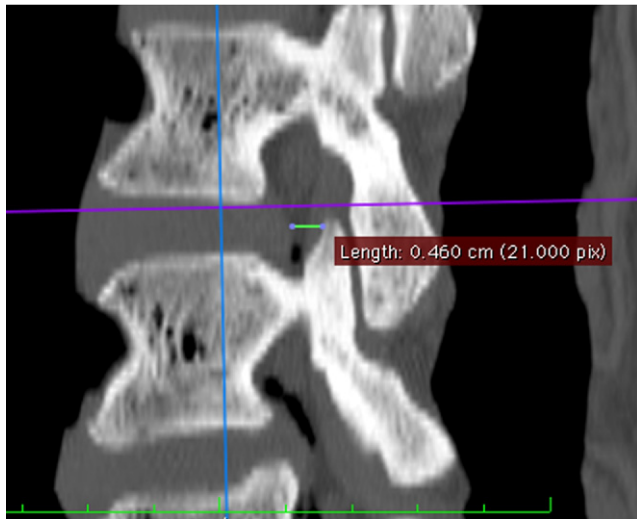


Fig. 2. Measurement of foraminal width using eFilm Workstation.

points on each vertebral body approximating the lateral-most, anterior-most, and posterior-most points on both the inferior and superior aspects of the disc was digitized with respect to their associated rigid body flag so that their location could be virtually tracked throughout the test (Fig. 3). The center of the disc was calculated as the centroid of these 8 digitized points, and disc bulge was calculated as the deviation of each of the 3 active LEDs from their initial distance from the disc centroid (Fig. 4). The maximum disc bulge was calculated as the maximum deviation from the




Fig. 3. Single FSU loaded in spine test machine. The arrows indicate the location of 4 of the 8 digitized points that were used to estimate the center of the disc.

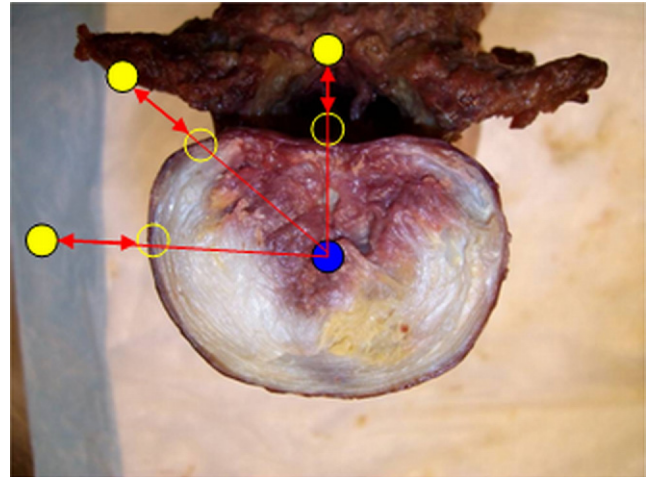


Fig. 4. Transverse section of intervertebral disc showing location of 3 active LEDs and measurement of disc bulge.

initial distance to the disc center during the third cycle of testing. For this study, only the disc bulge measurements at the posterior and posterolateral sites of the disc were of particular interest. Occlusion of the spinal canal was defined as the percentage of encroachment into the spinal canal (spinal canal depth) by maximum measured disc bulge at the posterior point of the disc (maximum measured posterior disc bulge/spinal canal depth $\times 100$). Occlusion of the intervertebral foramen was defined as the percentage of encroachment into the intervertebral foramen (foraminal width) by maximum measured disc bulge at the posterolateral point of the disc (maximum measured posterolateral disc bulge/foraminal width $\times 100$).

Statistical methods

A repeated-measures analysis of variance (ANOVA) test was used to compare the mean percent occlusion among the different modes of loading for a particular region of the intervertebral disc. A least significant difference post hoc test was used to determine which modes of load were statistically significant if a predefined significance level was reached.

Results

The donor information for the 7 lumbar specimens is tabulated in Tables 1 and 2. The anterior column grading for all levels of all 7 specimens is listed in Table 3. The spines were scored on a scale from 0 to 4 in which 0 indicates normal and 1, 2, and 3 denote mild, moderate, and severe degenerative disease, respectively. The grading of the spine specimens compiled in Table 3 shows that the vast majority of the levels tested were either normal or only mildly degenerated.

Table 4 lists the measurement results and descriptive statistics for all the specimens measured in the study. The mean spinal canal depth was 19 ± 4 mm. The range of

Table 1
Donor information of all spine specimens

Specimen	Age	Height (in)	Weight (lb)	Sex	DEXA (BMD)	Cause of death
C080570	70	67	234	F	N/A	Cardiopulmonary arrest
S080108	65	65	108	F	0.813	Respiratory failure, bacterial pneumonia
S080431	48	73	180	F	1.111	Cardiac arrhythmia
C080133	66	75	177	M	N/A	Lung cancer
S080429	34	65	205	F	0.870	Atherosclerotic coronary artery disease
C080172	66	66	145	F	0.700	Cardiopulmonary arrest, intracerebral hemorrhage
S080404	66	61	110	F	0.639	Respiratory failure

Abbreviations: DEXA, Dual Energy; X-Ray Absorptiometry; BMD, Bone Mineral Density; N/A, Not Available.

observed measurements was 12 mm, with a minimum of 13 mm and a maximum of 25 mm. The mean foraminal width was 5 ± 2 mm. The range was 7 mm, with a minimum of 2 mm and a maximum of 9 mm. Table 5 displays the spinal canal and intervertebral foramen occlusion percentages by region and load. Mean spinal canal occlusion under a 250-N axial load, ± 2.5 Nm of flexion/extension, and ± 2.5 Nm of lateral bend was $2.5\% \pm 1.9\%$, $2.5\% \pm 1.6\%$, and $1.5\% \pm 0.8\%$, respectively. Maximal spinal canal occlusion was 6.7% (occurring under a 250-N axial load) and minimal spinal canal occlusion was 0.5% (occurring under ± 2.5 Nm of flexion/extension). Mean intervertebral foramen occlusion under a 250-N axial load, ± 2.5 Nm of flexion/extension, and ± 2.5 Nm of lateral bend was $7.8\% \pm 4.7\%$, $9.5\% \pm 5.7\%$, and $11.3\% \pm 6.2\%$, respectively. Maximal intervertebral foramen occlusion was 24.4% (occurring under ± 2.5 Nm of lateral bend) and minimal intervertebral foramen occlusion was 2.1% (occurring under ± 2.5 Nm of flexion/extension).

At the posterior point of the disc, significant differences were detected only between ± 2.5 Nm of flexion/extension and ± 2.5 Nm of lateral bend ($P = .030$). No significant differences were seen among other modes of loading at the posterior point of the disc. At the posterolateral site of the disc, significant differences were detected between 250 N of axial compression and ± 2.5 Nm of flexion/extension ($P = .014$). Significant differences were also detected between 250 N of axial compression and ± 2.5 Nm of lateral bend ($P = .026$). No significant differences were found between ± 2.5 Nm of flexion/extension and ± 2.5 Nm of lateral bend. Table 6 displays the results of the repeated-measures ANOVA test (SPSS 17.0; SPSS, Chicago, Illinois).

Discussion

The aim of this study was to measure percent occlusion of the spinal canal and intervertebral foramen by disc bulge under different loading conditions. CT-scanned images of 7 human lumbar spine cadaveric specimens were used to obtain 2 measurements (spinal canal depth and foraminal width). Disc bulge at the posterior and posterolateral sites of the intervertebral disc under 3 different load protocols (axial compression, flexion/extension, and lateral bend) was measured by use of a previously described method, and the reported results were used to assess percent occlusion in the current study. No previous study has investigated and compared the amount of occlusion that occurs at a particular location (ie, spinal canal or intervertebral foramen) by the intervertebral disc under various dynamic loading conditions.

The overall mean anterior-posterior spinal canal diameter (spinal canal depth) measured in this study (19 ± 4 mm) was slightly greater than measurements reported by most previous studies. In a morphometric study of 443 adult Negroid and Caucasoid skeletons, Eisenstein¹⁹ found the mean anterior-posterior spinal canal diameter to be 15 mm, with an overall range of 12 to 21 mm. In a morphometric study of 121 adult Italian and Indian skeletons, Postacchini et al.²⁰ found the midsagittal diameter of the spinal canal to range from 11.5 to 20 mm (depending on ethnicity, spinal level, and location of measurement). Ullrich et al.²¹ reported normal anterior-posterior diameters of the spinal canal to range from 15 to 25 mm in a study that assessed the dimensions of the spinal canal using CT. Panjabi et al.²² found the anterior-posterior spinal canal diameter (referred

Table 2
DEXA summary

	Specimen						
	C080570	S080108	S080431	C080133	S080429	C080172	S080404
Region							
L1	N/A	0.721	1.074	N/A	0.847	0.652	0.563
L2	N/A	0.830	1.126	N/A	0.856	0.746	0.653
L3	N/A	0.848	1.131	N/A	0.901	0.739	0.647
L4	N/A	0.839	1.108	N/A	0.874	0.661	0.678
Mean	N/A	0.813	1.111	N/A	0.870	0.700	0.639

Abbreviations: DEXA, Dual Energy; X-Ray Absorptiometry; N/A, Not Available.

Table 3
Anterior column grading*

Level	Specimen						
	C080133	C080172	C080570	S080431	S080404	S080429	S080108
L1-2	0	2	0	0	0	0	1
L2-3	0	3	0	0	0	0	1
L3-4	1	1	1	0	0	0	0
L4-5	1	2	1	1	0	0	0
L5-S1	1	0	1	1	1	0	0

* Graded on a scale from 0 to 4, where 0 indicates normal, 1 indicates mild degenerative disease, 2 indicates moderate degenerative disease, and 3 indicates severe degenerative disease.

to as “spinal canal depth” in their study) to range on average from 17.5 ± 0.53 mm to 19.7 ± 0.49 mm depending on lumbar vertebral level.¹⁴ Spinal canal depth in this study was observed to be narrowest at L3 (17.5 ± 0.53 mm) and greatest at L5 (19.7 ± 0.49 mm).²² The overall mean mid-sagittal spinal canal diameter values measured in our study closely agree with the values reported by Panjabi et al. Varol et al.²³ reported mean spinal canal depths to range from 13.33 to 16.31 mm (SDs ranging from ± 1.88 mm to ± 2.52 mm) depending on spinal level and sex on CT images of 100 patients having low-back pain. On CT images in a control group of 40 individuals with no history of low-back pain, Varol et al. reported mean spinal canal depths to range from 17.15 to 18.68 mm (SDs ranging from ± 1.82 mm to ± 2.23 mm) depending on spinal level and sex.²³ In a study investigating intervertebral foramen di-

mensions, Cinotti et al.¹⁸ found the mean minimal foraminal width to be 4.5 mm, with a range of 2.5 to 5 mm. The anterior-posterior spinal canal diameter (spinal canal depth) and the foraminal width measured in our study are within the range of results reported by Eisenstein, Postacchini et al., Ullrich et al., Panjabi et al., Varol et al., and Cinotti et al. The slightly greater mean measurements we observed may be explained by the far smaller sample size and the location of the measurements in this study. Measurements of the anterior-posterior spinal canal diameter in this study were taken by use of CT scans at mid-disc level, at an angle parallel to the intervertebral disc. Measurements of the anterior-posterior spinal canal diameter in previous studies, however, were performed at locations either defined where the anterior-posterior spinal canal diameter is reported to be narrowest⁷ or within the parameters of the vertebral body^{20,22,23} instead of at the level of the intervertebral disc.

The results of the repeated-measures ANOVA test provide significant evidence against our null hypothesis. There were significant differences that were observed in percent occlusion for a given location among the 3 different loading conditions. In the spinal canal, greater occlusion was seen to occur under a 250-N axial load and ± 2.5 Nm of flexion/extension than during ± 2.5 Nm of lateral bend. At the intervertebral foramen, greater occlusion was observed during ± 2.5 Nm of flexion/extension and ± 2.5 Nm of lateral bend than during a 250-N axial compressive load. Compared with past studies of the intervertebral disc, lower loads (250-N axial load, ± 2.5 Nm of flexion/extension, and ± 2.5 Nm of lateral bend) were applied in this study because of the relative instability of testing only the vertebral bodies with intervertebral discs. Furthermore, it would be difficult to determine whether high loads, such as 7.5 Nm, would necessarily be physiologic, and it was our aim to remain below a threshold load level that would be traumatic to the partial motion segment.

Maximal and overall occlusion percentages were greatest at the intervertebral foramen. These results support the conclusion from our previous study that disc bulge (and thus disc occlusion) for a given site on the intervertebral disc is dependent on magnitude of load, direction of applied load, and location on the intervertebral disc. Furthermore, the results of this study support the proposal that exiting neural

Table 4
Spinal canal depth and foraminal width measurements

		Posterior (spinal canal depth) (mm)	Posterolateral (foraminal width) (mm)**
Level			
Specimen			
C080570	L1-2	24	6
C080570	L3-4	23	5
C080570	L5-S1	16	5
S080404	L1-2	18	5
S080404	L3-4	18	5
S080404	L5-S1	16	5
S080429	L1-2	25	6
S080429	L3-4	22	6
S080429	L5-S1	16	7
S080108	L1-2	21	9
S080108	L3-4	19	4
S080108	L5-S1	13	4
C080133	L1-2	25	9
C080133	L3-4	20	8
C080133	L5-S1	17	4
S080431	L1-2	24	6
S080431	L3-4	22	5
S080431	L5-S1	21	5
C080172	L1-2	19	5
C080172	L3-4	17	4
C080172	L5-S1	13	2
Mean		19 ± 4	5 ± 2
Maximum		25	9
Minimum		13	2

Table 5
Summary of descriptive statistics by region and mode of load

		Posterior (spinal canal depth)			Posterolateral (foraminal width)		
	Level	250 N comp	± 2.5 Nm FE	± 2.5 Nm LB	250 N comp	± 2.5 Nm FE	± 2.5 Nm LB
Specimen							
C080570	L1-2	1.1	3.6	0.6	4.4	10.7	8.2
C080570	L3-4						
C080570	L5-S1	6.0	4.8	0.6	5.6	4.1	4.7
S080404	L1-2	1.4	3.1	2.3	5.9	5.8	24.4
S080404	L3-4						
S080404	L5-S1						
S080429	L1-2	2.0	1.6	1.8	10.1	12.5	13.7
S080429	L3-4	1.4	1.8	0.6	7.3	9.0	6.5
S080429	L5-S1	2.5	1.9	2.1	5.2	7.0	7.0
S080108	L1-2	1.1	1.1	0.8	3.0	4.4	4.7
S080108	L3-4	1.9	2.4	1.4	15.7	18.5	23.6
S080108	L5-S1	6.7	6.7	2.2	17.8	20.8	14.2
C080133	L1-2	2.3	1.5	1.8	3.9	5.7	9.0
C080133	L3-4	3.3	1.8	0.9	10.2	10.7	13.0
C080133	L5-S1						
S080431	L1-2	0.6	1.6	1.0	3.7	5.3	4.5
S080431	L3-4	1.5	0.5	1.4	5.3	2.1	10.6
S080431	L5-S1						
C080172	L1-2	1.4	1.6	1.4	5.8	7.8	13.9
C080172	L3-4	3.6	3.5	3.3	13.5	17.7	11.2
C080172	L5-S1						
Mean		2.5 ± 1.9	2.5 ± 1.6	1.5 ± 0.8	7.8 ± 4.7	9.5 ± 5.7	11.3 ± 6.2
Maximum		6.7	6.7	3.3	17.8	20.8	24.4
Minimum		0.6	0.5	0.6	3.0	2.1	4.5

Abbreviations: comp, compression; FE, Flexion/Extension; LB, Lateral Bend.

Reported values are percent occlusion of specified region under 250-N axial compression, ± 2.5 Nm of flexion/extension, and ± 2.5 Nm of lateral bend.

elements at the location of the intervertebral foramen are the most vulnerable to impingement and generation of pain. In the context of this study, pain generation is defined as stimulation of pain nerve fibers by mechanical compression. Stimulation of the nerve fibers in this fashion may or may not lead to a subjective feeling of pain. Nevertheless, disc bulge encroaching and compressing neural elements (whether in the spinal canal or exiting through the intervertebral foramen) will cause stimulation of pain nerve fibers that potentially could generate a subjective feeling of pain.

There are several limitations of this study because of the test setup. Removal of the posterior elements to measure disc bulge is arguably the most significant limitation. Overall stability of the FSUs tested is in all likelihood decreased because of excision of the posterior column. One can expect increased range of motion and decreased stability with the elimination of the facet joints, which have a major impact on extension and lateral-bend movement, and the removal of the lamina and other parts of the posterior column, which are important in axial torsion or resistance to axial torsion.

Table 6
Repeated-measures ANOVA test results*

				95% confidence interval for difference	
	Mean difference	SE	<i>P</i> value†	Lower bound	Upper bound
Posterior (spinal canal occlusion)					
1 and 3‡	0.973	0.456	.051	−0.004	1.950
2 and 1	0.046	0.277	.870	−0.548	0.640
2 and 3	1.019	0.421	.030	0.116	1.922
Posterolateral (intervertebral foramen occlusion)					
1 and 2	−1.637	0.580	.014	−2.880	−0.393
1 and 3	−3.458	1.389	.026	−6.439	−0.478
2 and 3	−1.822	1.619	.280	−5.295	1.651

* Mean difference is significant at the .05 level.

† A least significant difference post hoc test was used to adjust for multiple comparisons.

‡ A 1 indicates 250 N of axial compression; 2, ± 2.5 Nm of flexion/extension; and 3, ± 2.5 Nm of lateral bend.

When measurement techniques that do not require line-of-site visibility during controlled loading procedures are developed, the need for removal of the posterior elements will be mitigated. Furthermore, because of the removal of the posterior column, we are unable to comment on the effect of aspects of the posterior column, such as the ligamentum flavum, on spinal canal occlusion. According to a study by Hansson et al.,²⁴ bulging of the ligamentum flavum due to applied external load was responsible for 50% to 85% of spinal canal narrowing measured in their study. Unfortunately, we can only account for occlusion of the spinal canal caused by bulging of the intervertebral disc in this study. At best, occlusion due to ligamentum flavum intrusion may be estimated by the amount of posterior disc bulge given a reasonable accounting for the ligamentum flavum thickness. Nevertheless, despite the limitations of the test setup, we believe that the results of the study have clinical ramifications regarding how a bulging intervertebral disc, in response to applied external load, might compress nerves exiting the intervertebral foramen and potentially cause pain.

References

- Brinckmann P, Grootenboer H. Change of disc height, radial disc bulge, and intradiscal pressure from discectomy. An in vitro investigation on human lumbar discs. *Spine* 1991;16:641–6.
- Lin HS, Liu YK, Adams KH. Mechanical response of the lumbar intervertebral joint under physiological (complex) loading. *J Bone Joint Surg Am* 1978;60:41–55.
- Schonstrom NS, Bolender NF, Spengler DM. The pathomorphology of spinal stenosis as seen on CT scans of the lumbar spine. *Spine* 1985;10:806–11.
- Stokes IA. Bulging of lumbar intervertebral discs: Non-contacting measurements of anatomical specimens. *J Spinal Disord* 1988;1:189–93.
- Wenger KH, Schlegel JD. Annular bulge contours from an axial photogrammetric method. *Clin Biomech (Bristol, Avon)* 1997;12:438–44.
- Younes M, Béjia I, Aguir Z, Letaief M, Hassen-Zrou S, Touzi M, Bergaoui N. Prevalence and risk factors of disk-related sciatica in an urban population in Tunisia. *Joint Bone Spine* 2006;73:538–42.
- Cuchanski M, Cook D, Jegapragasan M, Whiting D, Cheng B. Measurement of disc bulge of the intervertebral disc: an in vitro study using human cadaver lumbar spine segments. *Argospine News J* 2010;22:73–80.
- Brinckmann P, Horst M. The influence of vertebral body fracture, intradiscal injection, and partial discectomy on the radial bulge and height of human lumbar discs. *Spine* 1985;10:138–45.
- Brown T, Hansen RJ, Yorra AJ. Some mechanical tests on the lumbosacral spine with particular reference to the intervertebral discs; a preliminary report. *J Bone Joint Surg Am* 1957;39:1135–64.
- Heuer F, Schmidt H, Wilke H. The relation between intervertebral disc bulging and annular fiber associated strains for simple and complex loading. *J Biomech* 2008;41:1086–94.
- Heuer F, Schmidt H, Wilke H. Stepwise reduction of functional spinal structures increase disc bulge and surface strains. *J Biomech* 2008;41:1953–60.
- Shah JS, Hampson WG, Jayson MI. The distribution of surface strain in the cadaveric lumbar spine. *J Bone Joint Surg Br* 1978;60:246–51.
- Shirazi-Adl SA, Shrivastava SC, Ahmed AM. Stress analysis of the lumbar disc-body unit in compression. A three-dimensional nonlinear finite element study. *Spine* 1984;9:120–34.
- Wang S, Xia Q, Passias P, Wood K, Li G. Measurement of geometric deformation of lumbar intervertebral discs under in-vivo weightbearing condition. *J Biomech* 2009;42:705–11.
- Optotrak Certus Motion Capture System: technical specifications. NDI Research-Grade Motion Capture. Published 2008. Available from: URL: <http://www.ndigital.com/lifesciences/certus-techspecs.php>. Accessed March 2, 2009.
- Barnes PJ, Baldock C, Meikle SR, Fulton RR. Benchmarking of a motion sensing system for medical imaging and radiotherapy. *Phys Med Biol* 2008;53:5845–57.
- Maletsky LP, Sun J, Morton NA. Accuracy of an optical active-marker system to track the relative motion of rigid bodies. *J Biomech* 2007;40:682–5.
- Cinotti G, De Santis P, Nofroni I, Postacchini F. Stenosis of lumbar intervertebral foramen: Anatomic study on predisposing factors. *Spine* 2002;27:223–9.
- Eisenstein S. The morphometry and pathological anatomy of the lumbar spine in South African negroes and caucasoids with specific reference to spinal stenosis. *J Bone Joint Surg Br* 1977;59:173–80.
- Postacchini F, Ripani M, Carpano S. Morphometry of the lumbar vertebrae. An anatomic study in two caucasoid ethnic groups. *Clin Orthop Relat Res* 1983;172:296–303.
- Ullrich CG, Binet EF, Sanecki MG, Kieffer SA. Quantitative assessment of the lumbar spinal canal by computed tomography. *Radiology* 1980;134:137–43.
- Panjabi MM, Goel V, Oxland T, Takata K, Duranceau J, Krag M, Price M. Human lumbar vertebrae. Quantitative three-dimensional anatomy. *Spine* 1992;17:299–306.
- Varol T, Iyem C, Cezayirli E, Erturk M, Kayalioglu G, Hayretoglu C. Comparative morphometry of the lower lumbar vertebrae: Osteometry in dry bones and computed tomography images of patients with and without low back pain. *J Int Med Res* 2006;34:316–30.
- Hansson T, Suzuki N, Hebelka H, Gaulitz A. The narrowing of the lumbar spinal canal during loaded MRI: The effects of the disc and ligamentum flavum. *Eur Spine J* 2009;18:679–86.