

## Arthroscopic discectomy and interbody fusion of the thoracic spine: A report of ipsilateral 2-portal approach

Said G. Osman, Jeremy A. Schwartz and E. B. Marsolais

*Int J Spine Surg* 2012, 6 () 103-109

doi: <https://doi.org/10.1016/j.ijsp.2012.02.004>

<https://www.ijssurgery.com/content/6/103>

This information is current as of May 17, 2025.

---

**Email Alerts** Receive free email-alerts when new articles cite this article. Sign up at:  
<http://ijssurgery.com/alerts>



# Arthroscopic discectomy and interbody fusion of the thoracic spine: A report of ipsilateral 2-portal approach

Said G. Osman, MD, FRCSEd(Ortho)<sup>a,\*</sup>, Jeremy A. Schwartz, MD<sup>b</sup>,  
E. B. Marsolais, MD, PhD<sup>c</sup>

<sup>a</sup> American Spine Center, Frederick, MD

<sup>b</sup> Lee Memorial Hospital, Fort Myers, FL

<sup>c</sup> University Hospitals of Cleveland, Cleveland, OH

## Abstract

**Background:** The standard approach to the thoracic disc is through thoracotomy. The video-assisted thoracoscopic approach has been used as an alternative to the open approach for nearly 20 years, and more recently, extracavitary, posterolateral approaches have been introduced. Both the transthoracic procedures involve deflating the lung for access to the spine, and postoperative thoracic drainage is necessary; postoperative morbidity can be significant. The retropleural procedures are in their infancy, but the published results are promising. The purpose of this study is to introduce the posterolateral arthroscopic thoracic decompression and fusion procedure, which is extrapleural, less disruptive to normal anatomy, and cost-effective.

**Methods:** Fifteen consecutive patients who underwent arthroscopic decompression and interbody fusion of the thoracic spine were prospectively studied according to the hospital's institutional review board protocol. The Short Form 36 and visual analog scale questionnaires were completed preoperatively and postoperatively. Paired *t* tests were used for statistical analysis. The patient was placed in the prone position on a radiolucent table, and instrumentation was performed under fluoroscopic control. Two portals were developed ipsilaterally (one for the arthroscope and the other for instruments) on the side of disc herniation, and a single portal was used on the contralateral side. Various instruments were used for disc excision and exploration of the spinal canal. Fusion was accomplished with bilateral corticocancellous dowels obtained from the iliac crests. Infiltration of the access channel and facet injections of the contiguous joints were performed with bupivacaine, for immediate postoperative pain control.

**Results:** Fifteen patients with a mean age of 54 years were followed up for 28 months postoperatively. The overall back pain score decreased from 7.2 (SD, 1.5) to 3 (SD, 2) after the procedure ( $P < .005$ ). Eleven patients were satisfied with their current lifestyle postoperatively as opposed to one preoperatively. Two patients had recurrences. Hospital stay averaged 18.5 hours. The operating room cost and the cost of hospital stay was 51.9% of the cost of anterior open discectomy.

**Conclusions:** The extrapleural, biportal, ipsilateral arthroscopic approach for the decompression and interbody fusion of the thoracic spine is feasible, cost-effective, less traumatic, and associated with minimal complications. The best results were obtained in patients with single-level thoracic disc herniation. The technique is applicable for most thoracic disc herniations.

© 2012 ISASS - International Society for the Advancement of Spine Surgery. Published by Elsevier Inc. All rights reserved.

**Keywords:** Posterolateral; Endoscopic; Retropleural; Discectomy; Bone dowels; Fusion

Thoracic disc herniation is a challenging entity clinically. The clinical presentation is often vague and may mimic other syndromes.<sup>1,2</sup> The literature also illustrates a 20- to 24-month delay in treatment, mostly because of vague presentation, difficulty in clinical diagnosis, and concern about morbidity associated with current surgical treatment options.<sup>3</sup> A literature review shows that the incidence of thoracic disc herniation ranges from 0.15% to 4% of all symp-

tomatic disc protrusions. Thoracic discectomies account for 0.2% to 1.8% of all discectomies of symptomatic herniations.<sup>4–6</sup> The standard treatment has, hitherto, been transthoracic discectomy.<sup>1,7</sup> The alternative method with comparable results is costotransversectomy.<sup>3,8,9</sup>

Over the last couple of decades, a less invasive approach, video-assisted thoracoscopic discectomy, has gained increasing application.<sup>10–12</sup> Although the surgical trauma is not as severe as with the open approach, the potential for intrathoracic complications is similar to the thoracotomy approach.<sup>13</sup> More recently, an extracavitary, posterolateral technique has been reported with encouraging results.<sup>14</sup> The posterolateral arthroscopic microdiscectomy technique has

\* Corresponding author: Said G. Osman, MD, FRCSEd(Ortho), 1050 Key Parkway, Suite 103, Frederick, MD 21702; Tel: 240-629-3939; Fax: 240-715-9670.

E-mail address: [gotoaila@gmail.com](mailto:gotoaila@gmail.com)

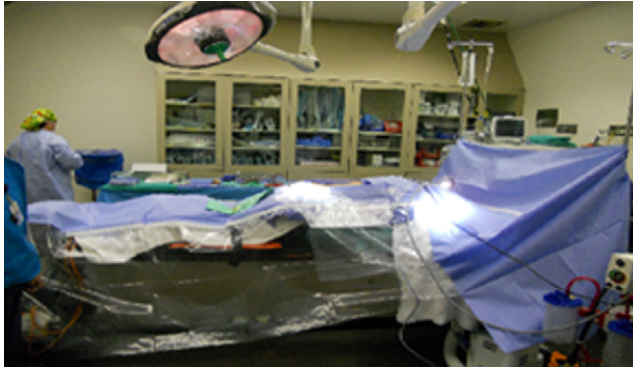


Fig. 1. Operating room set-up, note the laterally transparent drape. This allows the surgical team see foot pedals on the floor, and the fluoroscope as it is placed in the lateral position.

been used in the lumbar spine to treat herniated discs for more than 20 years and has proven to be a less invasive technique and is associated with minimal morbidity because of the relatively minor surgical trauma associated with the procedure.<sup>15</sup> We previously studied the posterolateral endoscopic approach to the thoracic disc in a cadaveric experiment.<sup>16</sup> The access channels are posterior to the rib neck and head, with the 2 acting as barriers against penetration into the retropleural space and the thoracic cavity, thus minimizing trauma to the lungs and the major vessels. Preliminary clinical results of this approach showed satisfactory outcomes.<sup>16,17</sup>

We hypothesized that by avoiding the thoracic cavity or violation of the retropleural space, it is possible to perform the described procedure on an outpatient or short hospital stay basis. The purpose of the study is to determine whether this procedure can address the pathology while minimally disrupting the normal anatomy, deliver an outcome equivalent to or better than that of the alternative procedures, reduce the cost of care of surgical management of the herniated thoracic disc, and facilitate return to productive pre-morbid activities and help regain a satisfactory quality of life.

## Methods

This is a prospectively studied case series of 15 consecutive patients (9 men and 6 women) who were treated between 1995 and 1998 for symptomatic thoracic disc herniations. All patients had thoracic back pain and radicular symptoms, and comprehensive nonoperative measures, including activity modifications, pain medication, nonsteroidal anti-inflammatory medications, physical therapy, and therapeutic injections, had failed. These patients were enrolled in the study after providing informed consent and were managed according to the protocol approved by the hospital's institutional review board. Diagnosis was made based on clinical findings and confirmed with imaging studies, including magnetic resonance imaging. Each patient completed the Short Form 36 and visual analog scale questionnaires preoperatively and postoperatively. A preoperative axial computed tomography (CT) scan of the thorax

was taken at the level of the target disc, with the patient in a prone position (Fig. 1). The distance of the instrument portal from the midline and the angle of the instrument insertion were then measured from the CT image. These measurements were used for intraoperative placement of the access channels. The outcomes of interest to evaluate response to the procedure were level of satisfaction with the quality of life, salaried employment status preoperatively and postoperatively, whether the patient was taking pain medication, severity of pain, length of hospital stay, cost of hospital treatment, and documentation of complications. The paired *t* test was used for data analysis.

## Procedure

The patient was placed under general endotracheal anesthesia before being placed in the prone position on a Kambin or Wilson frame, on a radiolucent table (Fig. 2). Somatosensory evoked potential recordings were performed routinely. Sequential compression devices were used for deep venous thrombosis prophylaxis. The level of target disc was marked on the skin, and after infiltration of the access track with 0.25% bupivacaine, a 6-mm stab incision was made at the portal site and an 18-gauge spinal needle was inserted into the posterolateral corner of the disc, at a predetermined angle to the coronal plane, aiming for the mid interpedicular line in both anteroposterior and lateral fluoroscopic projections. For the more medial herniations, the medial interpedicular line was used as a guide for instrumentation. This path was used for disc and foraminal instrumentation. A second needle was inserted cephalad to the first needle and triangulated on it in the foraminal canal. Once the needle positions were confirmed to be satisfactory, the stylets were removed and the guidewires were inserted through the needles (Fig. 3). After placement of the guidewires, the needles were removed.

The guidewires were inserted such that both tips entered the foremen and remained lateral to the medial interpedicular line at all times, to avoid injury to the spinal cord. Dull-tipped

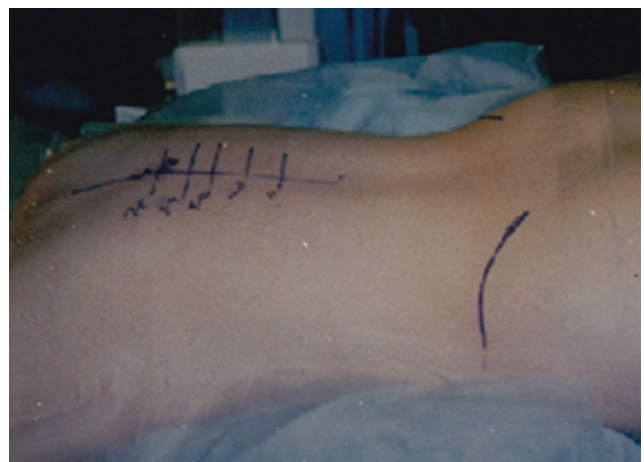


Fig. 2. Patient in prone position on the operating table. Note skin markings indicating spinal levels and iliac crests, prior to skin preparation and sterile draping.

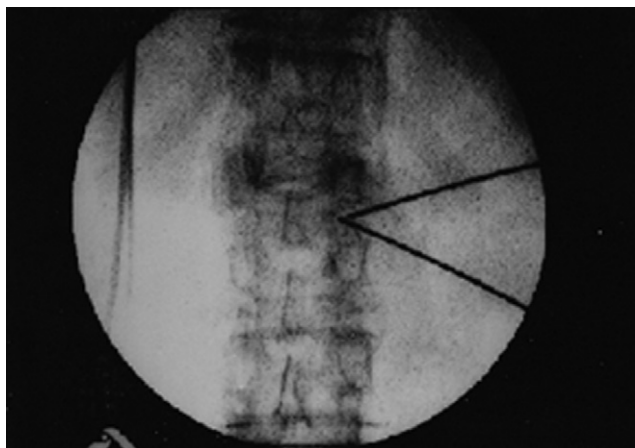


Fig. 3. Intra-operative, anteroposterior fluoroscopic view of guide wires triangulating in the foraminal canal of the target motion-segment.

guidewires were used for insertions through the soft tissue. However, in situations where the rib articulated with the disc, a sharp-tipped guidewire was used and driven through the rib neck or head, depending on which was obstructing the path of foraminal instrumentation. A 5-mm-diameter blunt cannulated obturator was inserted over the caudal wire until it contacted the annulus. The access cannula was inserted over the obturator until it just entered the foramen. The smaller (4-mm-diameter) cannula was similarly inserted in the rostral (cephalad) portal, triangulating on the first cannula in the dorsal half of the foraminal space (Fig. 4).

The rostral cannula was used for arthroscopy, and the caudal cannula was used for instrumentation of the foramen and disc. If partial excision of the posterior aspect of the rib neck and head was required to gain access to the posterolateral disc, the obturator was inserted over the guidewire that had previously been driven through the bone. The access cannula was inserted over the obturator until it contacted the rib neck or head. A trephine of appropriate diameter was inserted into the cannula, and excision of the




Fig. 4. Illustration of unilateral, bi-portal approach to a thoracic foramen. Note in this illustration the arthroscopy is the rostral cannula.

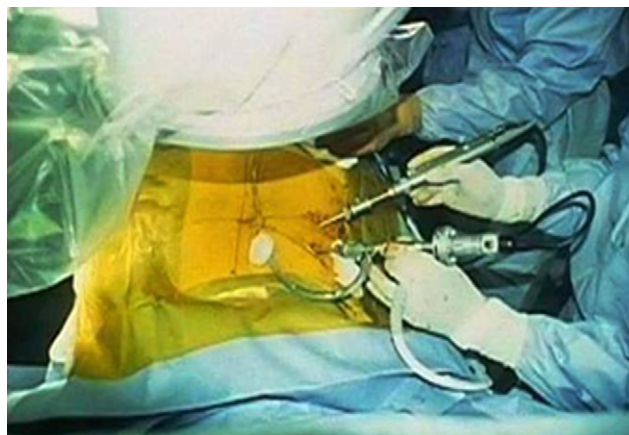

Fig. 5. Unilateral bi-portal arthroscopic approach to the thoracic spine. Note the arthroscopy and the instrument in the surgeon's left, and the right hand, respectively.

obstructing bone was carried out under fluoroscopic control. The plug of bone so obtained was removed, and the bullet-ended obturator was advanced through the cannula until the tip was at, or lateral to, the medial interpedicular line. The cannula was then advanced to triangulate with the arthroscope cannula in the dorsal half of the foramen, and the obturator was removed. During the procedure, it is important to note that the rostral cannula (cephalad, arthroscope) remains in the foraminal canal throughout the decompression and fusion procedures to monitor the safety of the cord and nerve roots. The instrument cannula (caudal) may or may not be docked into the disc space depending on the pathology being addressed. When there is a calcified disc herniation, shavers, burs, and trephines may be used through the cannula without docking it into the disc to decompress the spinal canal. Docking of the instrument cannula is necessary during bone grafting.

The arthroscope was introduced through the rostral (4-mm-diameter) cannula into the foraminal space and triangulated on a probe that was introduced through the instrument (6-mm-outer diameter) cannula (Fig. 5). The posterolateral annulus was exposed with a modified Penfield No. 4 probe. Epidural fat was removed with the aid of a shaver or liposuction at low pressure.

Annulotomy was performed with a trephine under arthroscopic control, followed by excision of the disc nucleus with grasping forceps (Fig. 6) and shaver-blades. Alternatively, in calcified herniations, the shaver or shielded bur would be used to debulk the bulging disc. Decompression of the disc was performed in the anteromedial direction. After excision of the herniation, an attempt was made to visualize the dura. A trephine and curettes of various designs were used for endplate preparation. After thus clearing the disc space, the Penfield No. 4 probe was carefully insinuated between the dorsum of the disc and the dura under arthroscopic control to reduce any residual bulging into the disc space (Fig. 7). The material so reduced into the disc

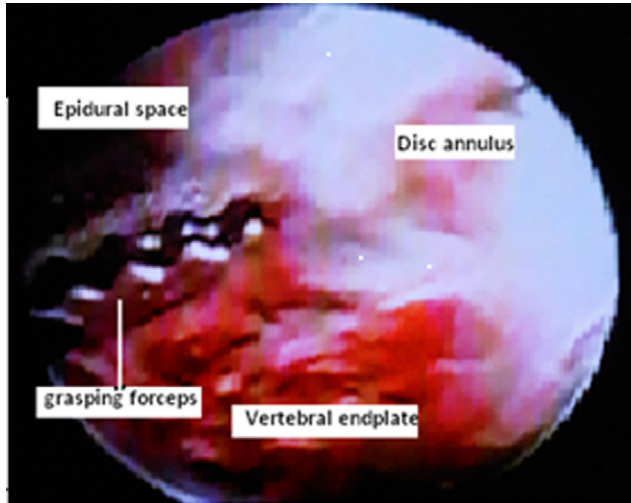


Fig. 6. Arthroscopic view of the grasping forceps in the disc space.

was then retrieved with grasping forceps. At this point, the dural sac should be clearly visualized (Fig. 8).

After the decompression of the disc interior and the epidural space, the obturator was reintroduced through the cannula, into the disc space under lateral fluoroscopic control. The cannula was advanced over the obturator and docked into the disc to a depth of 3 to 5 mm. At this point, the arthroscope cannula was removed. A second intradiscal cannula was inserted from the contralateral side and docked into the disc after annulotomy. Nuclear excision was performed as described earlier. Preliminary transforaminal decompression was not necessary on the contralateral side for unilateral herniation. For central herniation, however, removal of nuclear material might be performed with rigid and flexible graspers while one is arthroscopically visualizing from the contralateral portal. Endplate preparation was performed as described earlier. The adequacy of endplate preparation was confirmed

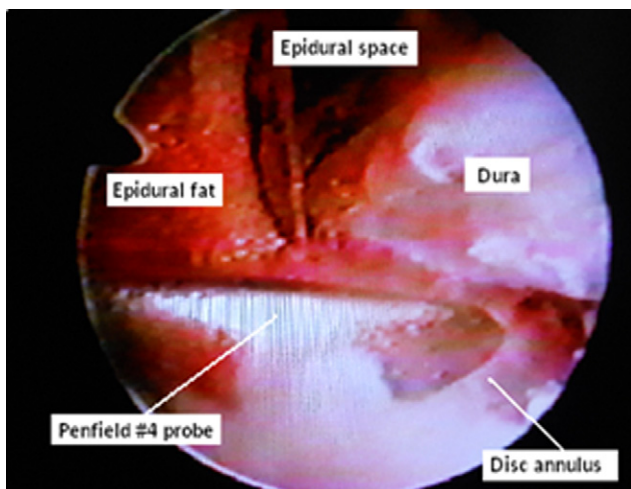


Fig. 7. After excision of a large calcified herniated disc material from within the disc space, a Penfield #4 probe is inserted between the posterior annulus and the dura, to decompress the epidural space.

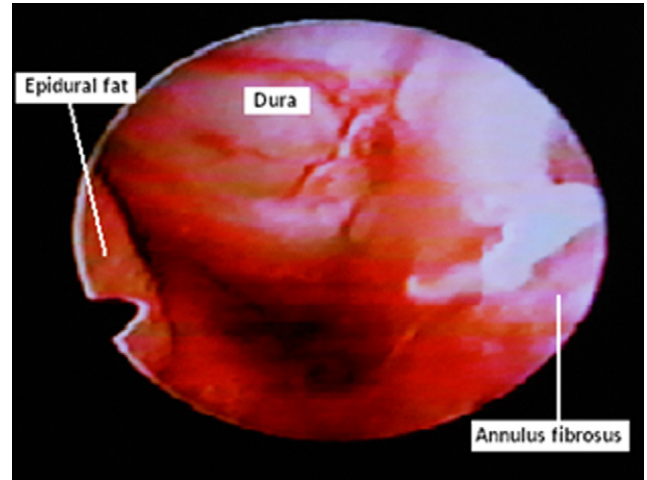


Fig. 8. Arthroscopic view of the dura, after excision of a large herniated and calcified intervertebral disc.

arthroscopically through 2 portals, and further decortications were carried out as necessary.

Bicortico-cancellous bone dowels were obtained from the iliac crest, through stab incisions, with a trephine of appropriate size. One bone dowel was inserted through each cannula under fluoroscopic control and placed anteriorly in the disc space (Fig. 9). The instruments were removed and the portals closed with absorbable subcuticular suture. The access track was infiltrated with bupivacaine with epinephrine to reduce postoperative bleeding and control immediate postoperative pain.

## Results

Between 1995 and 1998, 15 patients (9 men and 6 women) underwent posterolateral arthroscopic decompression and interbody fusion with autogenous bicorticocancellous bone graft ob-

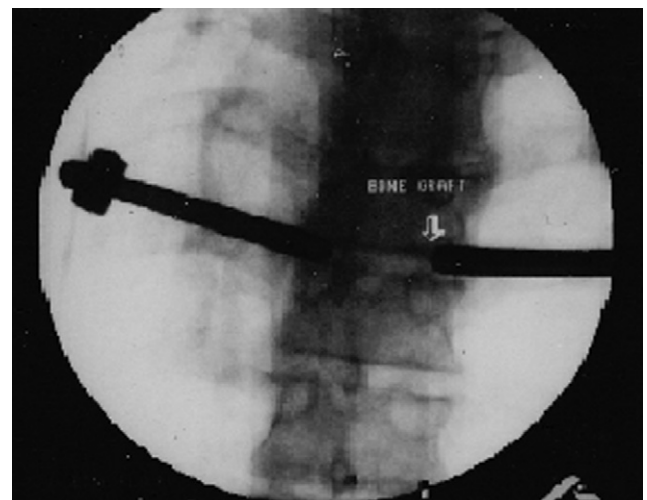


Fig. 9. Anteroposterior fluoroscopic view of bone dowel being place in the intervertebral disc space, through one of the cannulas.

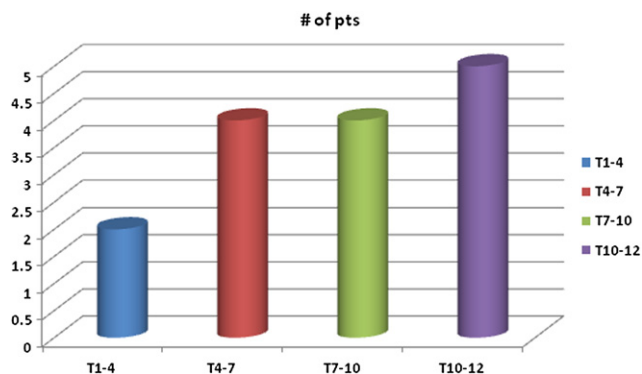


Fig. 10. Thoracic levels of degeneration/herniation which were operated on.

tained from the iliac crests. The mean age was 54 years (range, 38–88 years). Seven patients were involved in workers’ compensation processes, and 2 patients were retired. The duration of back-related symptoms was more than 1 year in 14 patients. One patient had symptoms for 3 months.

Eighteen discs were decompressed and fused: 13 patients had single-level fusion, 1 had 2-level fusion, and 1 had a 3-level procedure. Ten patients had symptomatic cervical and lumbar degeneration in addition to the more troublesome thoracic disc herniations. Most herniations were between T6 and T12 (Fig. 10).

The mean back pain score on the visual analog scale decreased from 7.2 ( $\pm 1.5$ ) preoperatively to 3 ( $\pm 2$ ) postoperatively ( $P \leq .005$ ) overall (Fig. 11). In patients with single-level disease, the pain score improved from 6 to 2 ( $P \leq .005$ ), as compared with those who had multilevel disease in the thoracic and other regions of the spine, with improvement from 7 ( $\pm 2$ ) to 4 ( $\pm 2$ ) ( $P \leq .025$ ). Eleven patients were satisfied with the quality of their lives postoperatively compared with one patient who was satisfied preoperatively (Fig. 12).

Preoperatively, only 3 patients were able to work for wages for at least 40 hours per week whereas 8 were unable

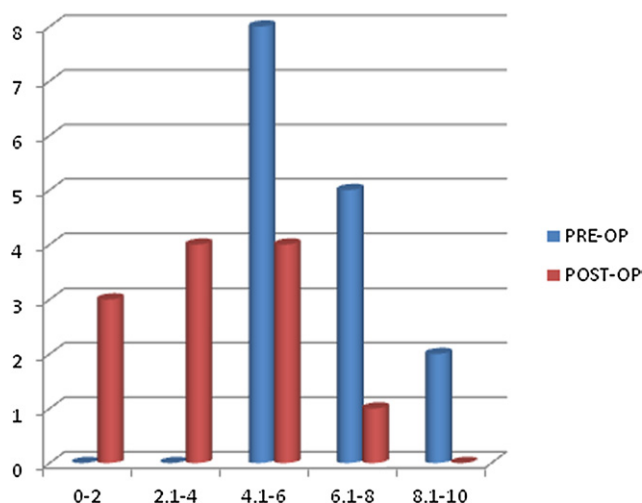


Fig. 11. Overall pain severity score preoperatively and postoperatively. The difference was statistically significant ( $P \leq .005$ ).

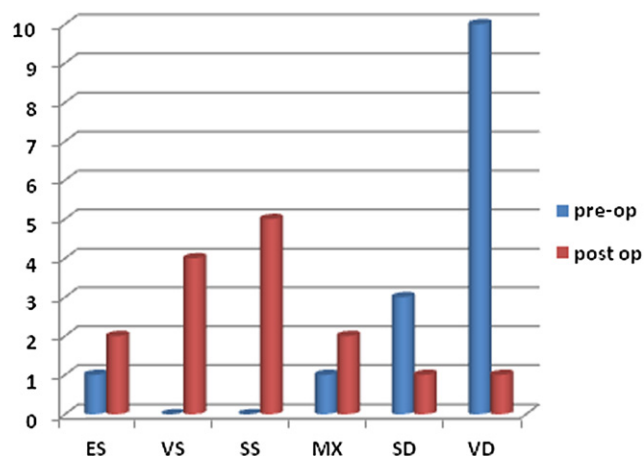


Fig. 12. Preoperative and postoperative level of satisfaction with life as a result of spine-related symptoms. The difference was statistically significant ( $P \leq .005$ ). ES, extremely satisfied; MX, mixed reaction; SD, somewhat dissatisfied; SS, somewhat satisfied; VD, very dissatisfied; VS, very satisfied.

to work because of back pain and 4 were either retired or were unable to work because of reasons not related to back pain. Postoperatively, 7 patients were able to work for wages for at least 40 hours per week and 4 were unable to work because of back pain (Fig. 13).

Preoperatively, patients regularly took 2 types of pain medication, and postoperatively, patients took 1 type or no pain medication at all. Two patients had recurrence of symptoms: one after 3 months, after heavy lifting, and the other after 4 months, without provocation. The first patient underwent a second operation to replace the partially extruded bone graft and has remained asymptomatic after the second surgery. The second patient’s symptoms resolved without intervention with successful fusion and without residual neurologic deficit. The length of hospital stay averaged 18.5 hours (range, 6–23 hours). The operating room cost and cost of hospital stay averaged \$8,208.20 (range,

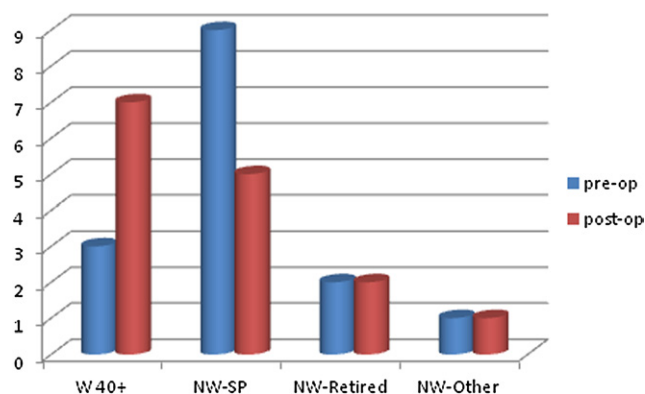


Fig. 13. Preoperative and postoperative salaried work status, showing the number of hours patients were able to work per week as a result of spine-related symptoms. (NW-Other, not working for non-spine-related reason; NW-Retired, not working because of retirement; NW-SP, not working because of spine-related symptoms; W 40, working 40 hours per week.)

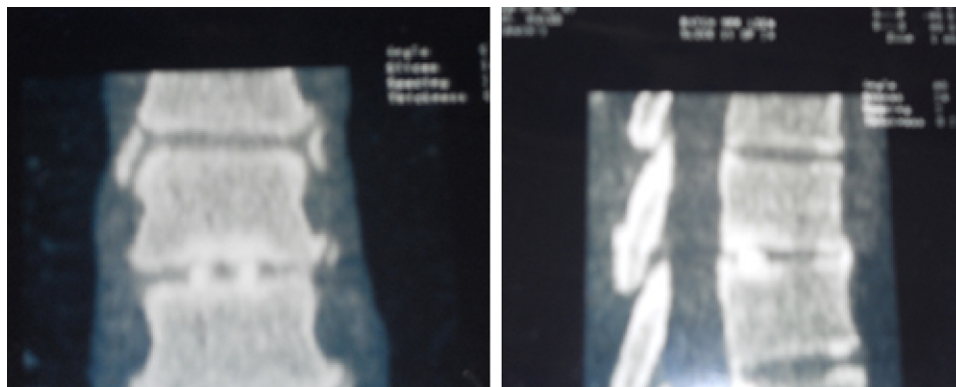


Fig. 14. 4 months post-operative CT Scan of interbody fusion of the thoracic spine.

\$6,054.20–\$9,366.79). The cost of treating patients with thoracotomy during the same period averaged \$15,849.69. Postoperative imaging studies, including CT scans, taken at least 4 months postoperatively showed successful fusion in all patients (Fig. 14). There were no complications other than those mentioned earlier.

## Discussion

Historically, a review of the literature shows that thoracic disc herniations account for 0.15% to 4% of all symptomatic herniations.<sup>4–6</sup> However, with the advent of magnetic resonance imaging, thoracic disc herniation is being diagnosed more frequently. A large proportion of these herniations are asymptomatic, but a herniated thoracic disc may mimic syndromes of several organ systems.<sup>1,2</sup> Arce and Dohrmann<sup>8</sup> reported that only 57% of patients with thoracic disc herniations initially had complaints of pain, 24% had sensory disturbances, and only 17% had motor disturbance. However, at the time of the diagnosis, 90% had symptoms of spinal cord compression. Brown et al.<sup>18</sup> found that only 67% of patients with thoracic disc herniations had the classic “band-like” chest pain. They also noted that, like lumbar spine herniations, most thoracic disc herniations resolve without surgical intervention. The fact that the average time from symptomatic onset to treatment is 20 to 24 months, a finding supported by our own data, points to the difficulty of diagnosis and treatment of thoracic disc herniation.

In light of catastrophic complications that have occurred in patients who underwent thoracic laminectomies for thoracic disc herniations,<sup>19,20</sup> as well as complications associated with transthoracic approaches to the spine, there was justifiable hesitation to operate on the thoracic disc in the past, unless of course there was imminent danger of paralysis. Other less destabilizing and extrathoracic approaches include costotransversectomy and the retropleural approach. Bohlman and Zdeblick<sup>7</sup> reviewed 22 patients who underwent transthoracic decompression and costotransversectomy and showed that 16 patients had excellent or good results. Currier et al.<sup>21</sup> reviewed 19 patients who underwent transthoracic decompression and fusion. Twelve had excellent or good results.

In an effort to minimize complications related to surgical trauma, in the last 20 years, there has been a shift toward less invasive procedures. Thoracoscopic discectomy has reduced some of the complications associated with thoracotomy, notably chronic chest pain and shoulder stiffness.<sup>10–12</sup> However, the procedure, though reducing the size of the incision and related pain, still relies on the deflation of the lungs and rib excision to access the discs; the risk of intrathoracic complications is not eliminated. Furthermore, there is a need for intrathoracic drainage tubes postoperatively until the lung reinflates, and monitoring in the intensive care unit is often necessary until the patient is deemed out of danger. McAfee et al.<sup>13</sup> reviewed 100 patients who had video-assisted thoracoscopic surgery of the spine and reported that, on average, patients had chest tubes in place for 1.44 days, 32% of the patients needed intensive care unit monitoring, and the length of hospital stay was 5 days. Simpson et al.<sup>3</sup> noted that the mean length of hospital stay was 6.8 days.

More recently, Khoo et al.<sup>14</sup> described a posterolateral approach using a 20-mm-diameter tubular access channel docked at the junction of the transverse process and the facet joint. Decompression of the disc and fusion were carried out without violation of the pleural cavity. Thirteen patients who had myelopathy due to 15 noncalcified thoracic disc herniations underwent the procedures. The short operating time and minimal blood loss are impressive. The mean length of hospital stay was 3.1 days. One dural leak, 4 transient paresthesias, and 1 case of abdominal wall weakness occurred.

The procedure comprising posterolateral arthroscopic decompression and interbody fusion of the thoracic spine, as shown in this study and with our experience over a period of 16 years, has produced satisfactory results. All patients had decompression and interbody fusions to address symptoms of radiculopathy and thoracic back pain, respectively. An ipsilateral biportal approach was used, with a small (4-mm) cannula for the arthroscope and a 6-mm-outer-diameter cannula for instrumentation. The purpose of using this approach is to facilitate maneuverability of the instruments independent of the arthroscope, as well as to accommodate larger instruments, such as shavers, burs, curettes, and trephines to remove hard discs. In this regard, the evolution of

this technique mirrors the evolution of knee arthroscopy from a uniportal operating arthroscope to current independent arthroscope and instrument portals. Maintaining the intraforaminal location of the arthroscope cannula permits monitoring of the safety of the spinal cord and nerve roots during the decompression procedure with the instruments described in this article. Because the thoracic discs are normally narrow compared with the lumbar discs, and even narrower in the degenerated state, and because the rib cage imparts stability to the thoracic spine, it was believed that interbody fusion without instrumentation was adequate. The result of this small series seems to support this assumption, although a larger prospective series will be needed to confirm this. The patients are able to go home regularly at less than 24 hours postoperatively. Blood loss has been consistently minimal, and the surgical trauma is minimal. The access to the disc is often through the soft tissue, but—as described by Osman and Marsolais<sup>16</sup> in their cadaveric study—at T5-6, T6-7, and T7-8, the rib heads tend to articulate with the discs, obstructing access to the posterolateral corner of the disc. In this situation, instead of walking or tilting the instruments more medially and risking injury to the cord, the dorsal part of the rib head and neck is reamed out with a trephine to gain access to the disc. This leaves the angle of the rib and rib neck as a protection against penetration into the pleural cavity or retropleural space. Another important anatomic finding from the cadaveric study is the posterolateral and rostral course the nerve root takes as it approaches the costal groove of the rib. This is in contradistinction to the lumbar nerve root, which courses ventrolaterally and caudally. These courses of the nerves make the former less likely to undergo injury by a small-diameter cannula and the latter more vulnerable to compression by the instrumentation. This study, as noted earlier, was carried out between 1995 and 1998, and an attempt was made to publish this work in 1999. However, in light of the state of the technology at the time, we decided to wait until the spine community was more receptive to such concepts. The first author (S.G.O.) has regularly performed the procedure over the last 12 years and will publish a much longer follow-up than this study. The learning curve is reasonably short, and a competent surgeon should be comfortable performing the procedure after 10 to 15 cases.

## Conclusion

This study clearly shows that the posterolateral arthroscopic thoracic decompression–interbody fusion procedure is a viable, less invasive, and cost-effective way of treating thoracic disc pathology on a short–hospital stay basis. The unilateral biportal approach permits use of the instruments independent of the constraints of the operating arthroscope, thereby permitting foraminoplasties and excision of discs with complex pathologic anatomy. The use of small-diameter access cannulas ensures less compression on vulnerable structures, such as the nerve roots. As an alter-

native to the bone dowels, morselized graft can be inserted into the disc space in a pouch. In addition, the interbody fusion may be supplemented with a percutaneous pedicle screw, as has been performed by us after the completion of this study, to stabilize the larger lower thoracic disc fusion.

## References

1. Epstein JA. The syndrome of herniation of the lower thoracic intervertebral discs with nerve root and spinal cord compression: a presentation of four cases with a review of the literature, methods of diagnosis, and treatment. *J Neurosurg* 1954;11:525–38.
2. Tahmouresie A. Herniated thoracic intervertebral disc—an unusual presentation. Case report. *Neurosurgery* 1980;7:623–25.
3. Simpson JM, Silveri CP, Simone FA. Thoracic disc herniation. Re-evaluation of the posterior approach using a modified costotransversectomy. *Spine* 1993;13:1872–77.
4. Abbott KH, Retter RH. Protrusions of thoracic intervertebral disks. *Neurology* 1956;6:1–10.
5. Alvarez O, Roque CT, Pampati M. Multilevel thoracic disc herniations: CT and MRI studies. *J Comput Assist Tomogr* 1988;12:649–52.
6. Arce CA, Dohrmann GJ. Herniated thoracic discs. Improved diagnosis with computed tomographic studies and review of the literature. *Surg Neurol* 1985;23:356–61.
7. Bohlman HH, Zdeblick TA. Anterior excision of herniated thoracic discs. *J Bone Joint Surg Am* 1988;70:1038–47.
8. Arce CA, Dohrmann GJ. Herniated thoracic discs. *Neurol Clin* 1985; 3:383–92.
9. Benson MKD, Byrnes DP. The clinical syndromes and surgical treatment of thoracic disc prolapse. *J Bone Joint Surg Br* 1975;57:471–7.
10. Regan JJ, Mack MJ. Endoscopic anterior thoracic discectomy: a prospective evaluation of the first thirty-six cases. Presented at the 10th North American Spine Society Annual Meeting, Seattle, WA, October 18–21, 1995.
11. Regan JJ, Mack MJ, Picetti GD. A technical report on video-assisted thoracoscopy in thoracic spinal surgery. Preliminary description. *Spine* 1995;20:831–37.
12. Rosenthal D, Rosenthal R, de Simone. Removal of a protruded thoracic disc using microsurgical endoscopy. A new technique. *Spine* 1994;19:1087–91.
13. McAfee PC, Regan JR, Zdeblick T, et al. The incidence of complications in endoscopic anterior thoracolumbar spinal reconstructive surgery. A prospective multicenter study comprising the first 100 consecutive cases. *Spine* 1995;20:1624–32.
14. Khoo LT, Smith ZA, Asgarzadie F, et al. Minimally invasive extracavitary approach for thoracic discectomy and interbody fusion: 1-year clinical and radiographic outcomes in 13 patients compared with a cohort of traditional anterior transthoracic approaches. *J Neurosurg Spine* 2011;14:250–60.
15. Kambin P. Arthroscopic microdiscectomy of the lumbar spine. *Clin Sports Med* 1993;12:143–50.
16. Osman GO, Marsolais EB. Posterolateral arthroscopic discectomies of the thoracic and lumbar spine. *Clin Orthop Relat Res* 1994;304:122–29.
17. Osman GO, Marsolais EB. Posterolateral endoscopic discectomies and fusion of the thoracic spine. Presented at the 12th North American Spine Society Annual Meeting, New York, October 22–25, 1997.
18. Brown CW, Deffer PA, Akmakjian J, Donaldson DH, Brugman JL. The natural history of thoracic disc herniation. *Spine* 1992;17:S97–102.
19. Fisher RG. Protrusions of thoracic disc. The factor of herniation through the dura mater. *J Neurosurg* 1965;22:591–93.
20. Logue V. Thoracic intervertebral disc prolapsed with spinal cord compression. *J Neurol Neurosurg Psychiatry* 1952;15:227–42.
21. Currier BL, Eismont JF, Green BA. Transthoracic disc excision and fusion for herniated thoracic discs. *Spine* 1994;19:323–8.