

## **Pedicle screw instrumentation of thoracolumbar burst fractures: Biomechanical evaluation of screw configuration with pedicle screws at the level of the fracture**

Michael J. Bolesta, Troy Caron, Suresh R. Chinthakunta, Pedram Niknam Vazifeh and Saif Khalil

*Int J Spine Surg* 2012, 6 () 200-205  
doi: <https://doi.org/10.1016/j.ijsp.2012.09.002>  
<https://www.ijssurgery.com/content/6/200>

This information is current as of May 16, 2025.

---

**Email Alerts** Receive free email-alerts when new articles cite this article. Sign up at:  
<http://ijssurgery.com/alerts>



## Pedicle screw instrumentation of thoracolumbar burst fractures: Biomechanical evaluation of screw configuration with pedicle screws at the level of the fracture

Michael J. Bolesta, MD <sup>a</sup>, Troy Caron, DO <sup>b</sup>, Suresh R. Chinthakunta, MSc <sup>c,\*</sup>,  
Pedram Niknam Vazifeh, BS <sup>c</sup>, Saif Khalil, PhD <sup>c</sup>

<sup>a</sup> *The University of Texas Southwestern Medical Center, Dallas, TX*

<sup>b</sup> *St John's Orthopedic Clinic, Springfield, MO*

<sup>c</sup> *Globus Medical, Inc., Audubon, PA*

### Abstract

**Background:** Posterior fixation alone may not be adequate to achieve and maintain burst fracture reduction. Adding screws in the fractured body may improve construct stiffness. This *in vitro* study evaluates the biomechanical effect of inserting pedicle screws in the fractured body compared with conventional short- and long-segment posterior fixation.

**Methods:** Stable and unstable L2 burst fractures were created in 8 calf spines (aged 18 weeks). Constructs were tested at 8 Nm in the intact state and then with instrumentation consisting of long- and short-segment posterior fixation with and without screws in the fractured L2 vertebral body after (1) stable burst fracture and (2) unstable burst fracture. Range of motion was recorded at L1-3 for flexion-extension, lateral bending, and axial rotation. Statistical analysis was performed with repeated-measures analysis of variance, with significance set at  $P < .05$ . The data were normalized to the intact state (100%).

**Results:** Both long- and short-segment constructs with screws in the fractured body significantly reduced motion compared with the stable and unstable burst fracture in flexion-extension and lateral bending. Fracture screws enhanced construct stability by 68% (on average) relative to conventional short-segment posterior fixation and were comparable to long-segment posterior fixation.

**Conclusions:** Screws at the fracture level improve construct stiffness. Short-segment constructs may suffice for stable burst fractures. More severe injuries may benefit from fracture screws and can be considered as an alternative treatment to long-segment constructs.

© 2012 ISASS - International Society for the Advancement of Spine Surgery. Published by Elsevier Inc. All rights reserved.

**Keywords:** Thoracolumbar fractures; Posterior fixation; Fracture screws; Index level screw

The choice of treatment for thoracolumbar burst fractures remains controversial. The ideal operative approaches are also disputed<sup>1,2</sup>; however, a common surgical goal is to obtain the most stable fixation with fusion of the fewest segments possible. Short-segment constructs (short-seg-

ment posterior fixation [SSPF]) are the most common treatment for thoracolumbar burst fractures.<sup>1,3,4</sup> Short-segment constructs consist of transpedicular screws, 1 level above and below the fractured vertebra, with interconnected rods. Reports on the use of SSPF for burst fractures describe high rates of failure of fixation and kyphotic collapse.<sup>1,3–7</sup> The primary causes of the failure include poor fixation because of osteoporosis, inadequate anterior column support, and insufficient points of fixation.<sup>7</sup> Increasing the fixation level decreases the stress on each pedicle screw and lowers the chance of failure. This may be achieved by using long-segment constructs (long-segment posterior fixation [LSPF]) connecting 2 or 3 levels above and below the fractured vertebra. Although lower failure rates have been reported with this technique,<sup>1,3,8</sup> LSPF may result in potentially extraneous instrumentation and increased risk of complications.<sup>1,3,4</sup>

Portions of this work were presented in abstract form/in poster form/as proceedings at the 2011 Annual Meeting of the Lumbar Spine Research Society, May 5–6, 2011, Chicago, Illinois.

Funding for this project was provided by Globus Medical, Inc., in the form of research engineer salaries, and the study was conducted using machines and other equipment within its research department.

\* Corresponding author: Suresh R. Chinthakunta, MSc, Globus Medical, Inc., 2560 General Armistead Ave, Audubon, PA 19403; Tel: 610-930-1800 (extension 2502); Fax: 610-930-2042.

E-mail address: [schinthakunta@globusmedical.com](mailto:schinthakunta@globusmedical.com)

Additional anterior column stabilization using strut grafting, mesh cage plates, body augmenters,<sup>1,9</sup> and transpedicular bone grafting in conjunction with vertebroplasty/kyphoplasty with calcium phosphate cement or polymethyl methacrylate<sup>1,10</sup> has also been used in an effort to lower failure rates. An alternative treatment is placement of pedicle screws at the fracture site (SF) to share the load while limiting the number of motion segments fused.<sup>3,4</sup>

Reinforcement with SF has been shown to provide better kyphosis correction and immediate stability in patients with thoracolumbar burst fractures.<sup>4</sup> This theoretically minimizes the number of fused motion segments, but the stability offered by such constructs compared with conventional LSPF and SSPF constructs and those with additional anterior column augmentation is yet to be determined. A few biomechanical studies have evaluated the stability offered by placement of pedicle screws at the fracture level.<sup>3,11</sup> These studies, however, did not compare the stability offered by this type of construct with that of conventional LSPF. Other studies have compared the biomechanics of either LSPF versus SSPF or SSPF with anterior column augmentation but did not include a fracture screw combination.<sup>10,12</sup> In this study we determined the difference in biomechanical stability offered by conventional LSPF versus SSPF with screws at the fracture site. Two different degrees of burst fractures were created to simulate stable and unstable burst fractures. It was hypothesized that fracture-level screws combined with SSPF provide stability comparable to conventional LSPF.

## Methods

### Specimen preparation

Eight fresh-frozen calf thoracolumbar spines (T12-L5, aged 18 weeks) were used in the study. The spines underwent radiography in the anteroposterior and lateral planes to ensure the absence of any major anatomic abnormalities. We dissected the specimens by carefully denuding the paravertebral musculature, avoiding disruption of spinal ligaments, joints, and discs. Each spine was potted rostrally at T12 and caudally at L5 in a 2:1 mixture of Bondo auto body filler (Bondo MarHyde Corp., Atlanta, Georgia) and fiberglass resin (Home Solutions All Purpose; Bondo MarHyde Corp.). It must be noted that unlike human spines, there are 13 thoracic and 6 lumbar vertebrae in a calf spine (Fig. 1).

### Flexibility testing

Each spine was fixed to the load frame of a custom-built 6-*df* spine simulator, and a pure moment was applied to the construct through servomotors.<sup>13</sup> The design of the load frame enables unconstrained motion of the spine in response to an applied load. There was no compressive preload applied to the specimen. Three infrared light-emitting diodes, mounted non-collinearly on a Plexiglas plate, were rigidly attached to the anterior aspect of each vertebral body (ex-

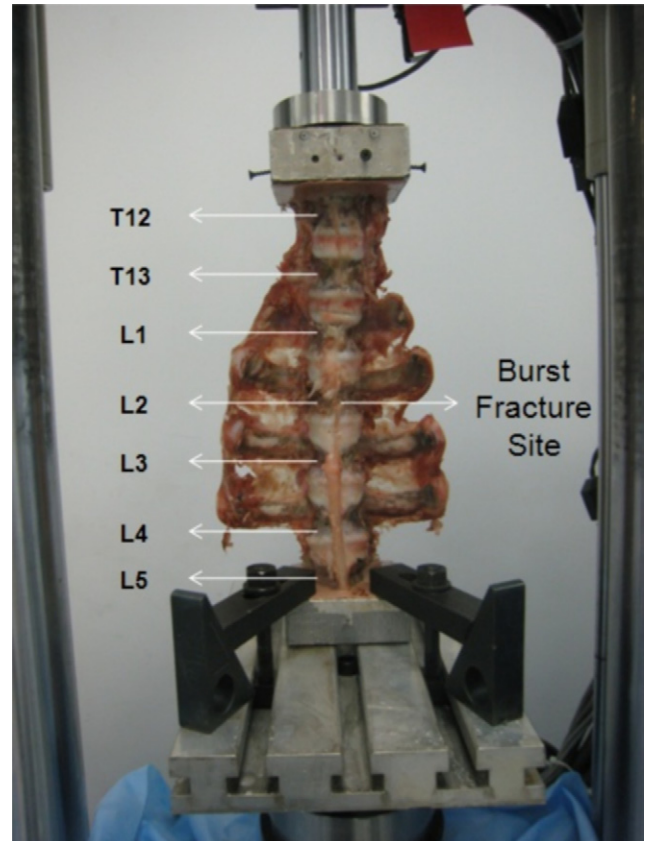


Fig. 1. Specimen mounted on test machine for burst fracture creation.

cept for L2) and served as points for motion measurement. Three-dimensional motion was tracked with a motion analysis system (Optotrak Certus NDI, Inc., Waterloo, Ontario, Canada). Each of the test constructs was subjected to 2 load-unload cycles in each of the physiological planes, generating flexion-extension (FE), right-left lateral bending (LB), and right-left axial rotation (AR) load-displacement curves. A load control protocol<sup>14</sup> was used to apply a maximum moment of 8 Nm at a rate of 1°/s.<sup>15</sup> The 3-dimensional intervertebral rotation was obtained from the motion analysis data files in the form of Euler angles (degrees) about the X, Y, and Z axes, with  $R_x$ / $-R_x$ ,  $R_y$ / $-R_y$ , and  $R_z$ / $-R_z$  denoting FE, AR, and LB range of motion (ROM), respectively.<sup>13</sup>

### Burst fracture creation

To create a burst fracture at L2, multiple drill holes were created at the anterior and lateral cortex of the L2 vertebral body to ensure reproducible fracture at L2. Then, each vertebral body was compressed at 50 mm/min<sup>8</sup> in a material testing machine (MTS Bionix, Eden Prairie, Minnesota) (Fig. 1). Visual observation of the test was conducted to check for sudden changes in the load-displacement curves generated by initiation of the fracture. A sudden increase in flexibility indicated a burst fracture. The axial load required to observe this sudden increase was, on average, 4501 ± 255 N (Fig. 2). The procedure was repeated until disruption

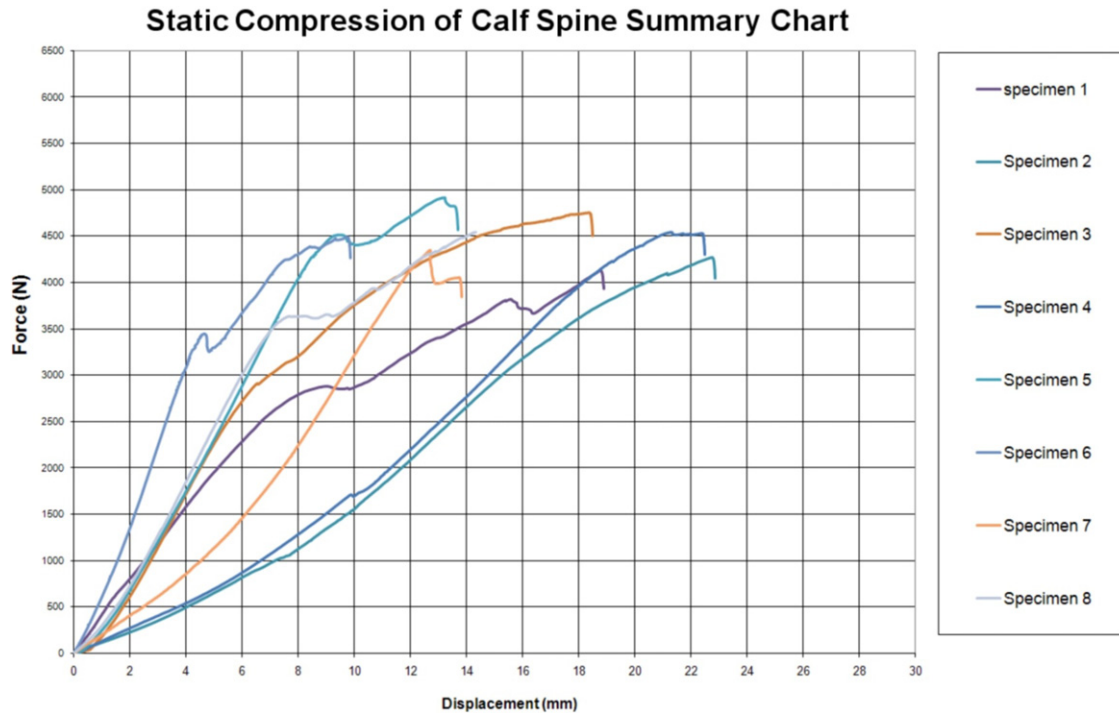


Fig. 2. Static compression summary chart of the 8 calf specimens tested.

of the anterior and middle columns of the vertebral body was seen on lateral X-rays, confirming creation of a burst fracture (BF I) (Fig. 3). Posterior elements (except pedicles) were disrupted by use of a scalpel, and the posterior column was subsequently disrupted following a procedure similar to BF I creation, producing an unstable burst fracture (BF II). The pedicles were left intact intentionally, to facilitate placement of pedicle screws into the fractured vertebra.

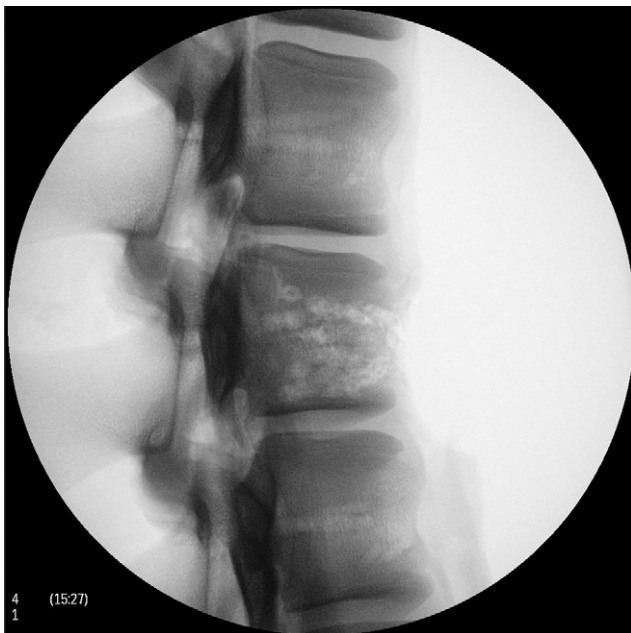

Fig. 3. Lateral radiographs of a sample specimen after fracture creation (L1).

#### Stabilization of fracture

Stabilization of the fractured vertebral body was achieved with bilateral pedicle screw and rod constructs (REVERE; Globus Medical, Inc., Audubon, Pennsylvania). LSPF and SSPF with and without screws at the L2 level (SF) (Fig. 4) were compared for stability after BF I and BF II.

#### Study design

Each spine was tested for stability at L1-3 in the intact condition to obtain baseline values. After intact testing, constructs were stabilized using LSPF, as well as SSPF with and without screws at L2 (SF), and were tested for flexibility after (1) BF I and (2) BF II. In each tested condition, the specimens were subjected to pure moments of 8 Nm in FE, LB, and AR. The data were normalized to the intact condition (100%).

#### Data analysis

Statistical analysis was performed on raw data by use of a repeated-measures analysis of variance for independent samples followed by Tukey post hoc analysis for multiple comparison procedures. Significance was set at  $P < .05$ .

#### Results

All constructs were examined after testing, and none showed any visible signs of damage, loosening, or breakage. The means and standard deviations for ROM in FE, LB, and AR are presented in Table 1. The results in Table 1 are presented in the sequence in which they were tested.

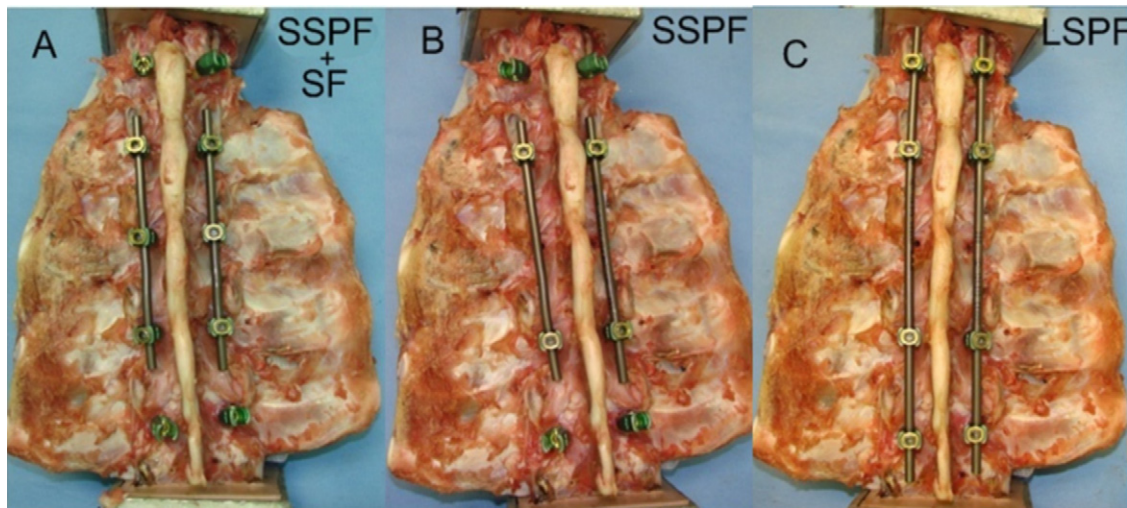


Fig. 4. The 3 different instrumented constructs that were compared for stabilization after burst fracture (BF I or BF II) and with and without pedicle screws at the level of the fracture. A, SSPF with screw at fractured level (SSPF + SF). B, SSPF. C, LSPF.

#### Flexion-extension

Comparative ROM values for the various surgical constructs are shown in Fig. 5 and Table 1. ROM was significantly reduced for all instrumented constructs compared with BF I and BF II conditions. Adding screws at L2 improved construct stability by 41% and 33% over conventional SSPF after stable (BF I) and unstable (BF II) burst fractures, respectively. The SSPF construct with screws at L2 provided comparable stability to conventional LSPF after stable and unstable burst fractures.

#### Lateral bending

Comparative ROM values for different surgical constructs are shown in Fig. 5 and Table 1. As with FE, mean ROM was significantly reduced in LB for all instrumented constructs compared with BF I and BF II conditions. A trend similar to FE was observed, with long-segment con-

structs providing increased stability compared with short-segment constructs. The addition of screws at L2 improved construct stability by 48% and 5% over conventional SSPF after stable and unstable burst fractures, respectively. The SSPF constructs with screws at L2 provide improved stability over conventional SSPF. However, the conventional LSPF constructs were stiffer than SSPF constructs with fracture screws.

#### Axial rotation

Comparative ROM values for tested surgical constructs are shown in Fig. 5 and Table 1. Unlike FE and LB, instrumented constructs did not significantly reduce mean ROM after stable burst fractures (BF I). The addition of screws at L2 restored motion close to intact, and motion decreased by 29% and 27% over conventional SSPF after stable (BF I) and unstable (BF II) burst fractures, respectively. The reduction in motion with conventional LSPF (BF I + LSPF) was similar to that obtained with SSPF with screws at L2 (BF I + SSPF + SF). Pedicle screws at L2 in combination with SSPF showed equivalent biomechanical stability compared with conventional LSPF.

Table 1  
Mean ROM at L1-3 in FE, LB, and AR

Test condition	Mean ROM (SD) (°)		
	FE	LB	AR
Intact	7.7 (1.4)	12.8 (5.2)	3.6 (1.1)
BF I	14.6 (2.3)*	19.9 (5.4)*	7.4 (1.4)
BF I + SSPF + SF	1.7 (0.4)*	1.6 (0.7)*	3.4 (1)
BF I + SSPF	2.8 (1)	3.2 (1.8)*	4.8 (0.8)
BF I + LSPF	1.4 (0.4)*	0.4 (0.2)*	3.9 (1)
BF II	18.4 (8.4)*	23.8 (6.9)*	15 (5.5)*
BF II + SSPF + SF	3.4 (1)	4.6 (3.9)*	6.9 (2.5)*
BF II + SSPF	5.1 (2.4)	4.8 (4.7)*	9.2 (4.9)
BF II + LSPF	3.1 (1.7)	1.1 (1.1)*	7 (3.5)

NOTE. All of the instrumented constructs significantly reduced the mean ROM compared with stable (BF I) and unstable (BF II) constructs in FE and LB. No significant differences were found within the instrumented constructs in any of the loading conditions.

\* Significant compared with intact condition.

#### Discussion

Increasing the fixation level is hypothesized to decrease the stress on each pedicle screw and lower the chance of failure.<sup>3,4</sup> This may be achieved by use of long-segment constructs, but this requires fusing of multiple motion segments and larger incisions, with an increased risk of complications. An alternative method is to include screws at the level of the fracture. Supplemental screws may have a protective effect on the fractured vertebral body by indirectly supporting the anterior column.<sup>4</sup> In this study a short-segment construct with pedicle screws at the fracture site (L2) showed equivalent biomechanical stability compared

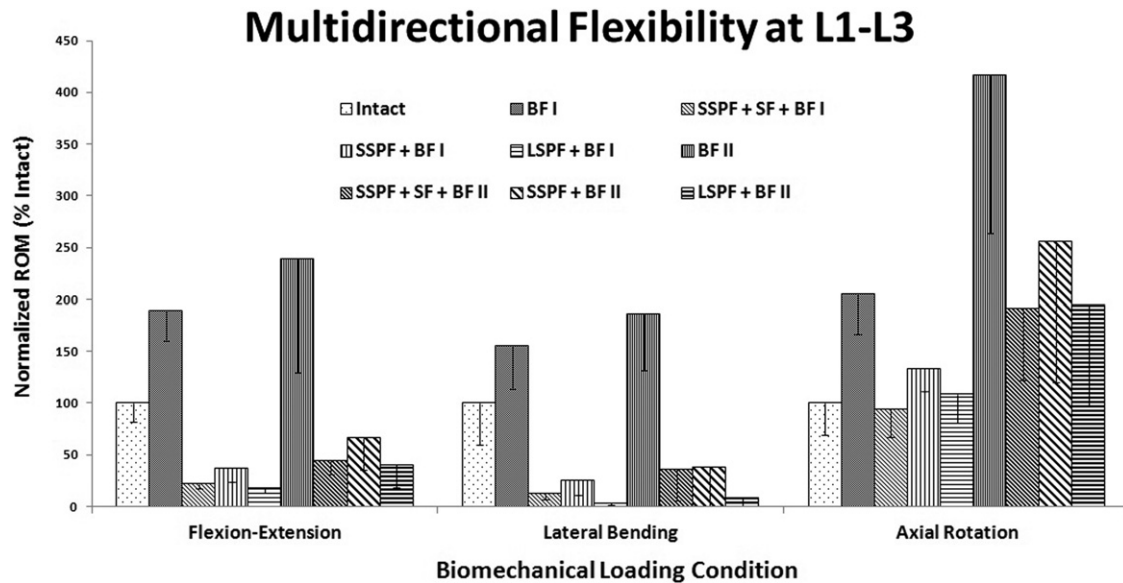


Fig. 5. L1-L3 ROM in FE, LB, and AR for different surgical constructs tested, expressed as percentage of intact ROM.

with a conventional long-segment construct in any of the loading conditions. It also showed improved stability compared with a conventional short-segment construct in all loading conditions. Previous studies have shown the benefits of pedicle screws for maximum stabilization over the length of the entire construct.<sup>16–19</sup> Similar trends were observed in FE and LB in an *in vitro* biomechanical study conducted by Mahar et al<sup>4</sup> comparing short fusion constructs with and without screws at the level of the fracture. The study also reported that the construct stiffness was significantly higher in AR with use of screws at the fracture level. The difference in results could be because of different specimens and the nature of the simulated burst fracture in these studies. In another biomechanical study, Baaj et al<sup>11</sup> also reported that adding screws at the fracture level of short-segment constructs significantly improved stability during flexion and LB. In addition, the study showed that the stability provided by a short-segment construct was less than that provided by a long-segment construct with or without screws at the fracture site. In a prospective randomized clinical study consisting of 72 patients, Guven et al<sup>3</sup> reported that reinforcement with fracture-level screws provided better kyphosis correction and immediate stability in patients with thoracolumbar burst fracture. The use of screws at the level of the fracture in short-segment constructs may thus be used as an alternative to long fusion constructs.

One limitation of our study is the calf spine model. Previous biomechanical and anatomic studies showed similarities between calf and lumbar spines with regard to physical and mechanical properties, establishing the suitability of calf spines as substitutes for human spines for *in vitro* studies.<sup>20,21</sup> Moreover, it has been shown previously that the use of calf spines as models for human spines in flexibility testing may be valid if the parameter of primary

interest is ROM.<sup>15</sup> The study is also limited by not accounting for fatigue from cyclical loading or the effect of graft healing that may be observed *in vivo*. Our results warrant further investigation.

Burst fracture is one of the most frequent thoracolumbar injuries; however, the definition of a thoracolumbar burst fracture is dependent on the choice of fracture classification used by the treating physician. In this study 2 types of burst fracture were created, BF I and BF II. In BF I the posterior elements were preserved, thereby simulating a stable injury as described by Holdsworth.<sup>22</sup> To simulate a more severe burst fracture (BF II), the posterior column and the posterior elements were disrupted, obtaining an unstable burst fracture as described by Whitesides<sup>23</sup> and Denis.<sup>24</sup> Furthermore, the fractures created in this study had 30% to 60% comminution of the body and 2 mm of displacement of fracture fragments or greater in over 50% of the cross-sectional area, which corresponded to a 5-point score according to the load-sharing classification of McCormack et al.<sup>25</sup>

In our study all instrumented constructs improved stability of the burst fracture segments beyond that of the intact state in FE and LB but not in AR. The burst fracture segments showed the most instability in AR, even for the instrumented segments. Additional fixation and/or anterior column augmentation did not restore the stiffness to the intact level in AR. Our results are consistent with those of Slosar et al<sup>26</sup> and Mann et al,<sup>27</sup> who found that posterior instrumentation increased stability beyond that of the intact spine only in flexion and LB while showing that the surgical construct was less stable than the intact spine in AR. Chang et al<sup>28</sup> reported similar observations in an L3 corpectomy model with a 3-level transpedicular fixation system. It was further noted in our study that unstable burst fractures (3-column burst fractures, BF II) were significantly less stiff than stable burst fractures (2-column burst fractures, BF I)

after instrumentation, and this effect was more pronounced in AR. Similar results were reported by Slosar et al. Previous authors have shown that the use of cross-linkage in spinal fusion constructs increases torsional stiffness.<sup>29</sup> In our study short-segment constructs with screws at the fracture level alone brought the mean ROM back to intact. Thus rotationally unstable fractures may require cross-links or additional fixation for stiffness reconstruction.

## Conclusions

Long fusion constructs provided better immediate stability than short fusion constructs. Insertion of pedicle screws at the level of the fracture increased construct stability. Short fusion constructs may suffice for stable-type injuries; however, more severe injuries and rotationally unstable burst fractures may require additional fixation. The technique of using shorter fusion constructs with additional fixation points at the level of the fracture, where applicable, may be a viable option for treatment of thoracolumbar burst fractures that would otherwise prompt anterior column reconstruction or long posterior fusion constructs.

## Acknowledgments

The authors acknowledge Brandon Bucklen, Manasa Gudipally, and Aditya Muzumdar for their assistance during testing.

## References

- Altay M, Ozkurt B, Aktekin CN, Ozturk AM, Dogan O, Tabak AY. Treatment of unstable thoracolumbar junction burst fractures with short- or long-segment posterior fixation in Magerl type a fractures. *Eur Spine J* 2007;16:1145–55.
- Panjabi MM, Oxland TR, Lin RM, McGowen TW. Thoracolumbar burst fracture. A biomechanical investigation of its multidirectional flexibility. *Spine* 1994;19:578–85.
- Güven O, Kocaoglu B, Bezer M, Aydın N, Nalbantoglu U. The use of screw at the fracture level in the treatment of thoracolumbar burst fractures. *J Spinal Disord Tech* 2009;22:417–21.
- Mahar A, Kim C, Wedemeyer M, et al. Short-segment fixation of lumbar burst fractures using pedicle fixation at the level of the fracture. *Spine* 2007;32:1503–7.
- Kramer DL, Rodgers WB, Mansfield FL. Transpedicular instrumentation and short-segment fusion of thoracolumbar fractures: a prospective study using a single instrumentation system. *J Orthop Trauma* 1995;9:499–506.
- Alanay A, Acaroglu E, Yazici M, Oznur A, Surat A. Short-segment pedicle instrumentation of thoracolumbar burst fractures: does transpedicular intracorporeal grafting prevent early failure? *Spine* 2001;26:213–7.
- McLain RF, Sparling E, Benson DR. Early failure of short-segment pedicle instrumentation for thoracolumbar fractures. A preliminary report. *J Bone Joint Surg Am* 1993;75:162–7.
- Tezeren G, Kuru I. Posterior fixation of thoracolumbar burst fracture: short-segment pedicle fixation versus long-segment instrumentation. *J Spinal Disord Tech* 2005;18:485–8.
- Chen HH, Wang WK, Li KC, Chen TH. Biomechanical effects of the body augmentor for reconstruction of the vertebral body. *Spine* 2004;29:382–7.
- Khanna AJ, Lee S, Villarraga M, Gimbel J, Steffey D, Schwardt J. Biomechanical evaluation of kyphoplasty with calcium phosphate cement in a 2-functional spinal unit vertebral compression fracture model. *Spine J* 2008;8:770–7.
- Baaj AA, Reyes PM, Yaqoobi AS, et al. Biomechanical advantage of the index-level pedicle screw in unstable thoracolumbar junction fractures. *J Neurosurg Spine* 2011;14:192–7.
- Lazaro BC, Deniz FE, Brasiliense LB, et al. Biomechanics of thoracic short versus long fixation after 3-column injury. *J Neurosurg Spine* 2011;14:226–34.
- Daftari TK, Chinthakunta SR, Ingalhalikar A, Gudipally M, Hussain M, Khalil S. Kinematics of a selectively constrained radiolucent anterior lumbar disc: comparisons to hybrid and circumferential fusion. *Clin Biomech (Bristol, Avon)* 2012;27:759–65.
- Goel VK, Panjabi MM, Patwardhan AG, Dooris AP, Serhan H, American Society for Testing and Materials. Test protocols for evaluation of spinal implants. *J Bone Joint Surg Am* 2006;88(Suppl 2):103–9.
- Wilke HJ, Wenger K, Claes L. Testing criteria for spinal implants: recommendations for the standardization of in vitro stability testing of spinal implants. *Eur Spine J* 1998;7:148–54.
- Louis R. Fusion of the lumbar and sacral spine by internal fixation with screw plates. *Clin Orthop Relat Res* 1986;18–33.
- Luque ER. Interpeduncular segmental fixation. *Clin Orthop Relat Res* 1986;54–7.
- Roy-Camille R, Saillant G, Mazel C. Internal fixation of the lumbar spine with pedicle screw plating. *Clin Orthop Relat Res* 1986;7–17.
- Steffee AD, Biscup RS, Sitkowski DJ. Segmental spine plates with pedicle screw fixation. A new internal fixation device for disorders of the lumbar and thoracolumbar spine. *Clin Orthop Relat Res* 1986:45–53.
- Cotterill PC, Kostuik JP, D'Angelo G, Fernie GR, Maki BE. An anatomical comparison of the human and bovine thoracolumbar spine. *J Orthop Res* 1986;4:298–303.
- Swartz DE, Wittenberg RH, Shea M, White AA, Hayes WC. Physical and mechanical properties of calf lumbosacral trabecular bone. *J Biomech* 1991;24:1059–68.
- Holdsworth F. Fractures, dislocations, and fracture-dislocations of the spine. *J Bone Joint Surg Am* 1970;52:1534–51.
- Whitesides TE. Traumatic kyphosis of the thoracolumbar spine. *Clin Orthop Relat Res* 1977:78–92.
- Denis F. The three column spine and its significance in the classification of acute thoracolumbar spinal injuries. *Spine* 1983;8:817–31.
- McCormack T, Karaikovic E, Gaines RW. The load sharing classification of spine fractures. *Spine (Phila Pa 1976)* 1994;19:1741–4.
- Slosar PJ Jr, Patwardhan AG, Lorenz M, Havey R, Sartori M. Instability of the lumbar burst fracture and limitations of transpedicular instrumentation. *Spine* 1995;20:1452–61.
- Mann KA, McGowan DP, Fredrickson BD, Falahee M, Yuan HA. A biomechanical investigation of short segmental spinal fixation for burst fractures with varying degrees of posterior disruption. *Spine* 1990;15:470–8.
- Chang KW, Dewei Z, McAfee PC, Warden KE, Farey ID, Gurr KR. A comparative biomechanical study of spinal fixation using the combination spinal rod-plate and transpedicular screw fixation system. *J Spinal Disord* 1988;1:257–66.
- Lynn G, Mukherjee DP, Kruse RN, Sadasivan KK, Albright JA. Mechanical stability of thoracolumbar pedicle screw fixation. The effect of crosslinks. *Spine* 1997;22:1568–72.