

Cervical total disc replacement using a novel compressible prosthesis: Results from a prospective Food and Drug Administration–regulated feasibility study with 24-month follow-up

Carl Lauryssen, Domagoj Coric, Thomas Dimmig, David Musante, Donna D. Ohnmeiss and Harrison A. Stubbs

Int J Spine Surg 2012, 6 () 71-77

doi: <https://doi.org/10.1016/j.ijsp.2012.02.001>

<https://www.ijssurgery.com/content/6/71>

This information is current as of May 2, 2025.

Email Alerts Receive free email-alerts when new articles cite this article. Sign up at:
<http://ijssurgery.com/alerts>

Cervical total disc replacement using a novel compressible prosthesis: Results from a prospective Food and Drug Administration–regulated feasibility study with 24-month follow-up

Carl Lauryssen, MD ^{a,*}, Domagoj Coric, MD ^b, Thomas Dimmig, MD ^c,
David Musante, MD ^c, Donna D. Ohnmeiss, PhD ^d, Harrison A. Stubbs, PhD ^e

^a Institute for Advanced Spinal Research in California, Beverly Hills, CA

^b Carolina Neurosurgery and Spine Associates, Charlotte, NC

^c Triangle Orthopaedic Associates, Durham, NC

^d Texas Back Institute Research Foundation, Plano, TX

^e Oakland, CA

Abstract

Background: Anterior cervical fusion, an established procedure to treat cervical radiculopathy, sacrifices the natural function of the disc, while placing increased stresses on adjacent spinal levels. In contrast, the cervical total disc replacement (cTDR) maintains motion and decreases adjacent-level stresses. The purpose of this study was to investigate the safety and effectiveness of a next-generation cTDR device in patients with symptomatic cervical radiculopathy.

Methods: This is a multicenter Food and Drug Administration–regulated feasibility study to evaluate safety and effectiveness of the M6-C Artificial Cervical Disc for the treatment of patients with symptomatic cervical radiculopathy at 1 or 2 levels from C3 to C7. Neck Disability Index (NDI), visual analog scales (VAS) assessing neck and arm pain, Short Form 36 Health Survey (SF-36), safety, and radiographic outcomes were assessed preoperatively, at 6 weeks and 3, 6, 12, and 24 months postoperatively.

Results: Thirty patients were enrolled at 3 clinical sites. Patients were implanted at either 1 or 2 levels. Mean NDI improved from 67.8 to 20.8 ($P < .0001$) at 24 months. Significant improvement was also observed through 24-month follow-up in neck and arm pain VAS ($P < .0001$) and in physical ($P < .005$) and mental component scores of the SF-36 at 3, 6, and 12 months ($P < .008$). There were no serious adverse events related to the device or procedure as adjudicated by an independent clinical events committee. Radiographically, disc space height increased more than 50% with a correlative increase in the postoperative disc angle. Range of motion decreased slightly from baseline during early follow-up but increased slightly and were maintained throughout the follow-up period.

Conclusions: The M6-C cervical artificial disc represents a new generation of cTDR design. Results of this study found the M6-C device to produce positive clinical and radiographic outcomes similar to other cTDRs, warranting further investigation.

© 2012 Published by Elsevier Inc. on behalf of ISASS - International Society for the Advancement of Spine Surgery.

Keywords: Cervical total disc replacement; Cervical radiculopathy; M6-C artificial cervical disc; Fusion

Primary symptoms of cervical radiculopathy are neck and arm pain, as well as neurologic symptoms, including motor, reflex, and sensory changes. Anterior cervical fusion (ACF) is a well-accepted surgical procedure to treat acute cervical radiculopathy resistant to nonsurgical treatment. However, a paradigm change from fusion to motion preservation is occurring in the treatment of a subset of patients

with symptomatic cervical radiculopathy. The practical advantages of cervical total disc replacement (cTDR) include maintenance of intervertebral motion and decreased adjacent-level stresses, with the theoretic advantage of reduction of adjacent-level clinical and radiographic degeneration.^{1–5} It has been estimated that as many as 90% of fusion-treated patients will have new-onset or progressive degenerative changes at adjacent levels, with approximately 25% of these patients exhibiting symptoms within 10 years.⁶ The incidence of symptomatic adjacent-level disease after ACF requiring further intervention is generally quoted as 2% to 3% annually.^{6–8}

* Corresponding author: Carl Lauryssen, MD, Institute for Advanced Spinal Research in California, 8670 Wilshire Boulevard, Suite 202, Beverly Hills, CA 90210; Tel: 310-770-6849; Fax: 310-657-6342.

E-mail address: clauryssen@gmail.com

The clinical outcomes of previously published prospective, randomized cTDR studies have been positive.^{4,9–14} In these studies comparing total disc replacement (TDR) with ACF, the results have been consistent and have found that both groups improved significantly compared with their preoperative condition, with cTDR equivalent or superior to ACF in overall success rates.¹⁵ To date, all of these devices have produced motion through a ball-and-socket-type design, with some incorporating a sliding mobile core into the design. Next-generation cTDR devices have been designed to produce and preserve motion through compression of the prosthetic core. The purpose of this study was to investigate the safety and therapeutic effectiveness of 1 such device in a US Food and Drug Administration (FDA)–regulated pilot study in patients with symptomatic cervical radiculopathy with 24-month follow-up.

Methods

Device description and surgical technique

The M6-C Artificial Cervical Disc (Spinal Kinetics, Sunnyvale, California) is a novel, next-generation artificial disc designed to replicate the anatomic, physiological, and biomechanical characteristics of the native disc. The core is composed of a polycarbonate urethane polymeric material that is surrounded by a polyethylene woven-fiber construct. The compressible polymer core is designed to simulate the stiffness and function of the nucleus, and the fibers are designed to simulate the annulus. The fiber annulus is an assembly of high-tensile strength, ultrahigh-molecular-weight polyethylene fibers wound in multiple redundant layers around the polymer nucleus, providing progressive resistance to motion. The core construct is attached to titanium alloy endplates to form the cervical disc prosthesis. This design enables the device to have all 6 *df*, including axial compression with independent angular motions in flexion-extension, lateral bending, and axial rotation, allowing independent translations along the 3 anatomic axes.

The prosthetic disc also has a polymer sheath encasing the core and fiber construct to inhibit any tissue ingrowth as well as capture any potential wear debris. The endplates are attached to the vertebral body by 3 low-profile keels on the superior and inferior surfaces. The endplates and keels are coated with porous titanium to promote bone-contact surface area and osseointegration (Fig. 1).

The surgical implantation of the disc consists of a straightforward 3-step process: (1) trialing, where a footprint template and trial implant are used to determine the appropriate size and position of the implant as well as for midline verification; (2) keel cutting, where a chisel is used to create keel tracks into the superior and inferior vertebral bodies; and (3) implant insertion, where an implant inserter is used to place the artificial disc into the desired position within the intervertebral space. Access to the disc space is accomplished through a standard anterior approach with anterior discectomy and decompression being performed. Fluoroscopic guidance is used during artificial disc placement.




Fig. 1. Cutaway view of single-piece M6-C compressible prosthesis.

Study Rationale and Design

This is an FDA-regulated Investigational Device Exemption feasibility study conditionally approved for initiation in the United States in December 2007 with final approval received on March 12, 2008 (G050254/S003). The primary study objective was to evaluate the initial safety and effectiveness of the M6-C artificial cervical disc in the treatment of patients with symptomatic cervical radiculopathy at 1 or 2 levels from C3 to C7 requiring surgery. The study was a multicenter, prospective single-arm investigation. Thirty patients were enrolled at 3 clinical sites. Data were collected preoperatively, in the operating room, and at 6 weeks and 3, 6, 12, and 24 months postoperatively.

Inclusion/exclusion criteria

All patients were skeletally mature (21–75 years old) with intractable cervical radiculopathy with or without spinal cord compression (Nurick classification ≤ 2) at 1 or 2 levels from C3 to C7. Patients had cervical root compression visualized on magnetic resonance imaging; concordant symptoms and signs of cervical root–related dysfunction, pain, or both; and persistent pain despite nonoperative management for at least 6 weeks.

Patient population

Patients were enrolled in the study according to specific inclusion/exclusion criteria typical for patients presenting with symptomatic cervical radiculopathy. All patients signed a study-specific institutional review board–approved informed consent form before participation. Thirty patients entered the study, and 28 (93%) completed the 24-month follow-up. One patient, incarcerated sometime after the 3-month visit, was removed from the study as recommended by the reviewing institutional review board. One patient chose to discontinue participation before the 24-month visit.

Table 1
Perioperative data for 1- and 2-level disc replacements

Operative parameters	1 Level (n = 12)	2 Levels (n = 18)
Estimated blood loss (mL)	33.7 ± 17.4	66.8 ± 24.9
Operative time (min)	67.1 ± 21.4	128.6 ± 31.8
Hospital stay (d)	1.1 ± 0.3	1.4 ± 0.8

NOTE. Values are mean ± standard deviation.

Clinical outcomes

Clinical effectiveness measures included the Neck Disability Index (NDI), neck and arm pain visual analog scales (VASs), and Short Form 36 (SF-36) Health Survey. The NDI measures neck pain, function, and disability; scores were calculated as a percentage ranging from 0% to 100%.¹⁶

Neck pain intensity and arm pain intensity were evaluated separately using VASs. The VAS is a 10-cm horizontal line anchored on the left by the words “no pain” and on the right by the words “worst possible pain.” Patients were presented with 3 VASs, 1 each for neck pain, right arm pain, and left arm pain. Patients were asked to place a mark on the line at the point that indicated their current pain intensity. The SF-36 Health Survey is a validated quality-of-life assessment.¹⁷ The physical and mental component scores (physical component summary [PCS] and mental component summary [MCS]) were calculated.

Safety assessment

Patients were monitored for the occurrence of adverse events intraoperatively and throughout follow-up. All adverse events, including implant and/or fiber breakage, sheath dislodgement, subsidence, migration, expulsion, and additional surgical procedures, including supplemental fixation, revision, and device removal, were documented. Serious adverse events (SAEs) related to the implantation procedure or to the device were captured on a continuous basis and reviewed and adjudicated by an independent clinical events committee composed of 3 spine surgeons who were not participating in the study as investigators.

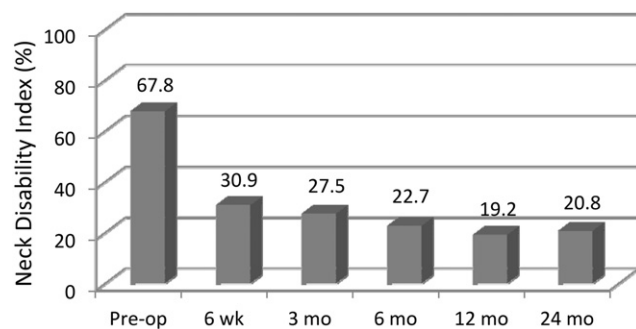


Fig. 2. Mean NDI through 24-month follow-up. (Pre-op, preoperatively.)

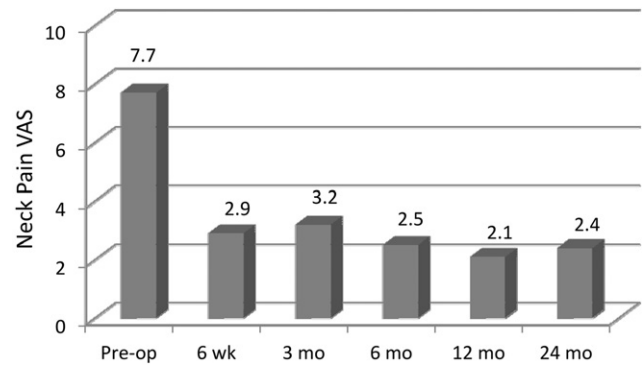


Fig. 3. Mean VAS scores for neck pain through follow-up. (Pre-op, preoperatively.)

Subject overall success

Overall subject study success was defined as (1) no device or implantation procedure-related SAEs; (2) no additional surgical intervention at the operative level, including supplemental fixation, revision, and/or device removal; and (3) minimum 15-point improvement in NDI scores.

Radiographic outcomes

Standard radiographs (anteroposterior, lateral, flexion, extension, and left and right lateral bending) were taken preoperatively and at all scheduled follow-up visits. A core radiographic laboratory (Medical Metrics, Inc., Houston, TX) performed a radiographic assessment according to a radiographic evaluation protocol. Primary radiographic outcomes include disc height, disc angle, index-level range of motion (ROM), global ROM (C2-6), and degree of lateral bending.

Statistical methods

Significance values for change from baseline for continuous measures such as VAS scores and NDI were based on the paired *t* test, and between-group (1 vs 2 levels treated) comparisons for such measures were based on the 2-sample *t* test. Between-group comparison of overall success was

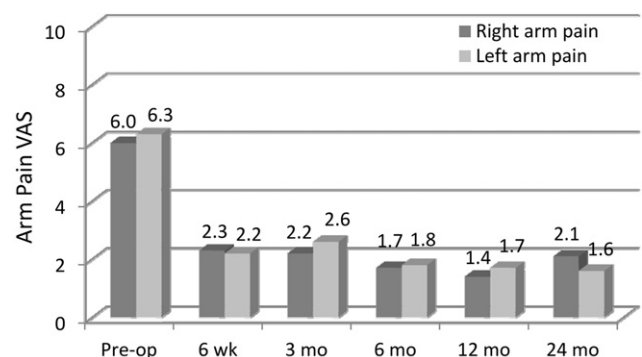


Fig. 4. Mean VAS scores for right and left arm pain. (Pre-op, preoperatively.)

Table 2
SF-36 Health Survey scores with preoperative versus postoperative comparisons

Time point	SF-36 component score	No. of patients	Mean	SD	<i>P</i> value (preoperatively vs postoperatively)
Preoperatively	PCS score	30	30.40	9.05	
	MCS score	30	40.06	12.56	
6 wk	PCS score	9	40.82	8.43	.0138
	MCS score	9	50.50	10.14	.126
3 mo	PCS score	30	41.90	10.34	<.0001
	MCS score	30	47.23	13.32	.0145
6 mo	PCS score	28	46.59	9.41	<.0001
	MCS score	28	48.05	14.22	.0136
12 mo	PCS score	28	48.75	9.45	<.0001
	MCS score	28	49.11	14.20	.0118
24 mo	PCS score	28	47.74	11.04	<.0001
	MCS score	28	46.30	13.34	.1364

performed with the Fisher exact test. All significance values presented are 2 tailed. All statistical results were obtained using SAS, version 9.1 (SAS Institute Inc., Cary, NC). A normal distribution was assumed for the radiographic outcomes, and analysis of variance with post hoc Bonferroni comparisons was conducted between subgroups.

Results

There were 19 men and 11 women enrolled in the study. The mean age was 45.1 years, and the mean symptom duration before surgery was 2.4 years. The mean body mass index was 28.3 kg/m². As indicated previously, patients were implanted at either 1 (*n* = 12) or 2 (*n* = 18) levels from C3 to C7 depending on their presenting condition. The majority of implants involved the C5-6 level (56.2%), with the remainder at C6-7 (29.2%) or C4-5 (14.6%).

Surgery outcomes

Estimated blood loss, surgery duration, and length of hospital stay for 1- and 2-level cases are shown in Table 1.

Clinical outcomes

Compared with the mean preoperative value, the mean NDI scores were significantly improved by 6 weeks' follow-up and

remained so throughout the 24-month follow-up (*P* < .001) (Fig. 2). Figures 3 and 4 show the improvement in the mean preoperative VAS scores compared with the postoperative mean scores for both neck and arm pain. The improvements in neck and arm pain VAS were significant (*P* < .01) throughout follow-up. The PCS and MCS scores on the SF-36 were significantly improved from baseline at all follow-up evaluations with the exception of the MCS at 24-month follow-up (Table 2).

Though not a primary part of the study, results for 1- versus 2-level TDRs were compared (Table 3). At the 24-month follow-up visit, there were no significant differences between 1- and 2-level patients for change from baseline for NDI (*P* = .26), right arm pain (*P* = .97), left arm pain (*P* = .81), SF-36 PCS score (*P* = .41), and SF-36 MCS score (*P* = .091). However, 2-level patients had a significantly greater improvement in reduction in the neck pain VAS score than 1-level patients: 6.3 versus 3.9 (*P* = .033).

Radiographic outcomes

Anterior and posterior disc height increased postoperatively (Fig. 5) and was maintained throughout the 24-month follow-up. The larger increase in anterior disc height contributed to the significant increase in postoperative disc angle (*P* < .0001) (Fig. 6).

Table 3
One- and two-level clinical outcomes

	1 Level		2 Level		<i>P</i> value
	Preoperatively	Postoperatively	Preoperatively	Postoperatively	
No. of patients	12	12	18	16	
NDI	73.7 ± 13.1	31.7 ± 19.3	63.9 ± 13.7	13.4 ± 13.2	.26
VAS for neck pain	8.0 ± 2.2	4.0 ± 3.2	7.5 ± 2.0	0.8 ± 1.1	.03
VAS for right arm pain	7.0 ± 2.0	3.2 ± 2.9	5.4 ± 3.4	0.9 ± 1.5	.97
VAS for left arm pain	7.2 ± 2.6	2.6 ± 2.9	5.6 ± 3.5	0.5 ± 1.1	.81
SF-36 PCS	25.3 ± 9.7	40.6 ± 10.4	33.8 ± 7	53.1 ± 8.3	.41
SF-36 MCS	41.3 ± 13.3	39.8 ± 14.6	39.2 ± 12.3	51.1 ± 10.3	.09

NOTE. Values are mean ± standard deviation; *P* values represent the comparison of the 2 groups based on the change from baseline to 24-month follow-up.

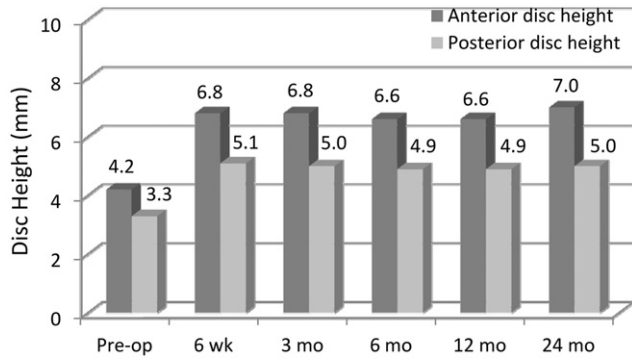


Fig. 5. Mean anterior and posterior disc space heights. (Pre-op, preoperatively.)

Global and index-level ROM decreased slightly from baseline, but ROM was maintained throughout follow-up (Fig. 7). Lateral bending was also maintained throughout follow-up and was near baseline at 24 months (Fig. 8). Flexion and extension radiographs showing motion of the device are shown in Fig. 9.

Safety outcomes

There were no SAEs related to the device or procedure as adjudicated by the independent clinical events committee. However, 1 subject underwent reoperation for removal of retained wound drain.

Subject overall success

At 12- and 24-month follow-up, 23 subjects (82%) and 24 subjects (89%), respectively, had overall success, with no patients having device removals or revisions, supplemental fixation, or device- or procedure-related SAEs. At 24 months of follow-up, patients with 1-level disc replacement achieved 83.3% success and patients with 2-level replacement achieved 93.3% overall success.

Discussion

The M6-C disc represents a new generation of cTDR design. The compressible core was designed to mimic the

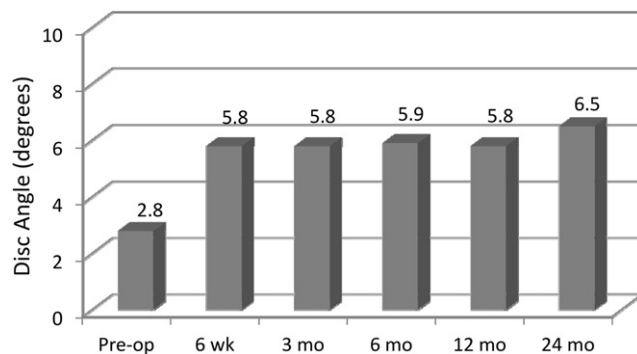


Fig. 6. Mean disc angle preoperatively through follow-up.

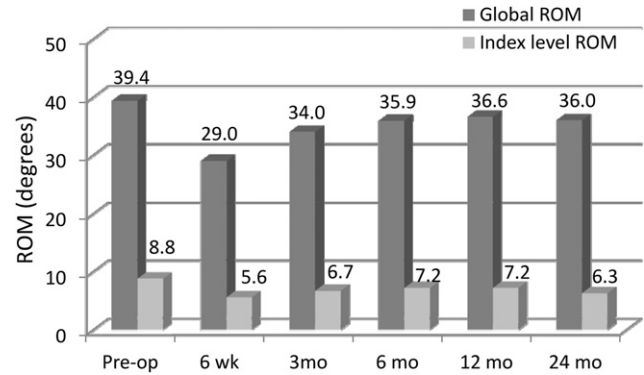


Fig. 7. Mean global and index-level ROM. (Pre-op, preoperatively.)

compressibility of the natural disc and allows motion with 6 *df*. Biomechanical testing of this implant found that the kinematic response of the device approximated the response of the intact specimen in flexion-extension.¹⁸ It was noted that positioning the implant in the middle versus posteriorly in the sagittal plane did not affect the ROM; however, when the prosthesis was aligned within 1 mm of the disc midline, the center of rotation was most similar to that of the intact spine. The clinical implications of these findings are yet to be defined.

It has been documented through biomechanical testing that maintenance of motion at an implanted segment reduces stresses at adjacent levels.^{19,20} Though intuitive, it remains theoretical that this motion results in decreased clinical adjacent-level degeneration. A recent nonrandomized study found no difference in the adjacent segment when comparing cTDR with ACF.²¹ Other recent prospective randomized studies reported through radiographic evaluation that cTDR reduces the rate of adjacent-segment degeneration compared with ACF.^{10,22,23} These studies investigated artificial discs with a sliding mobile core and domed superior surface. Although such devices should allow more natural motion than a ball-and-socket design, they do not allow motion with 6 *df*, in contrast to the compressible device in this study.^{18,24} Determining whether qualita-

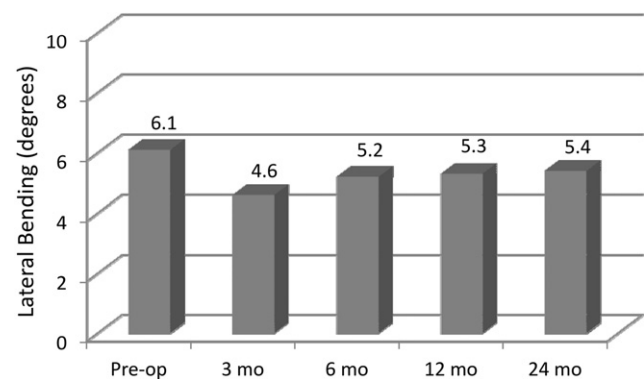


Fig. 8. Mean left/right lateral bending of implanted level. (Pre-op, preoperatively.)

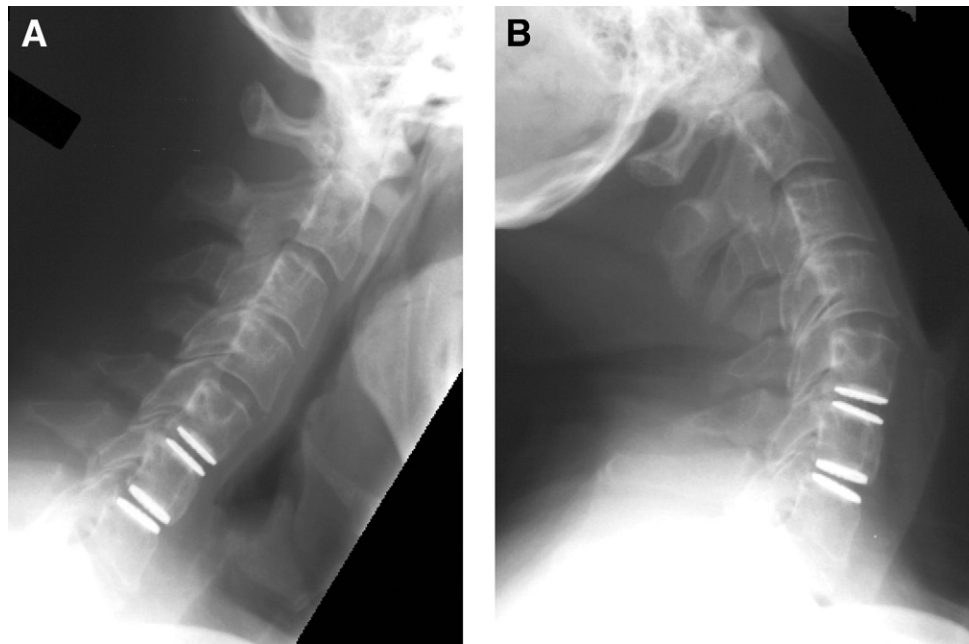


Fig. 9. Flexion (A) and extension (B) radiographs of TDRs at C5-6 level with 8.4° of motion and at C6-7 level with 12.4°. The global motion was 39.6°.

tive motion to more closely mimic natural motion would meaningfully reduce the rate of adjacent-segment degeneration will require a much larger sample size than used in this pilot study.

The results of this prospective FDA-regulated pilot study found that the compressible TDR was associated with significantly reduced neck and arm pain, improved self-reported disability as assessed by the NDI, and improved quality of life as shown by SF-36 Health Survey scores. These results were similar to those reported in a previous study performed outside of the United States using the same device, in which 25 patients with 24-month follow-up showed significant improvement in the NDI, VAS neck and arm pain scores, and the Physical Component Score of the SF-36 Health Survey.²⁵ The NDI scores were also similar to results reported in multiple FDA Investigational Device Exemption trials for other cTDR devices using this same outcome assessment.¹⁵ Overall success through 2-year follow-up was achieved in 89% of the patients with no incidences of device- or procedure-related adverse events and no device removal, revision, or supplemental fixation.

With respect to radiographic results, although there was variation in the preoperative and postoperative values in the various studies, the decrease in ROM in early follow-up with increasing values later seen in our study has been noted in another TDR trial.⁴

In this study 18 patients underwent TDR at 2 levels. The outcomes were not significantly different from the single-level cases with the exception of greater improvement in neck pain noted in the 2-level group. There are few prospective data published on 2-level cervical disc replacement. Interestingly, in a prospective, randomized study

comparing TDR with ACF in patients with 2-level cervical pathology, both groups improved significantly, with the TDR group having significantly greater improvement in NDI scores.²⁶ To date, only 2 cTDR devices (Prestige LP [Medtronic Sofamor Danek Inc., Minneapolis, MN] and Mobi-C [LDR Spine, Troyes, France]) evaluating 2-level symptomatic disc disease have completed US FDA prospective, randomized studies.^{13,27}

Limitations of this early-phase feasibility study include a relatively low number of patients without a control group. However, patient selection criteria for this study were very similar to other larger TDR studies, as were the outcomes.

The results of this US FDA-regulated feasibility study suggest that the device studied produced results comparable with other cTDRs. Additional prospective investigation with a larger number of patients and longer follow-up is warranted to establish whether quality of motion with a novel compressible core improves clinical outcome and reduces adjacent-level disease.

References

1. Coric D, Finger F, Boltes P. Prospective randomized controlled study of the Bryan cervical disc: early clinical results from a single investigational site. *J Neurosurg Spine* 2006;4:31–5.
2. Goffin J, Van Calenbergh F, van Loon J, et al. Intermediate follow-up after treatment of degenerative disc disease with the Bryan cervical disc prosthesis: single-level and bi-level. *Spine* 2003;28:2673–8.
3. Hunter LY, Braunstein EM, Bailey RW. Radiographic changes following anterior cervical fusion. *Spine* 1980;5:399–401.
4. Mummaneni PV, Burkus JK, Haid RW, Traynelis VC, Zdeblick TA. Clinical and radiographic analysis of cervical disc arthroplasty compared with allograft fusion: a randomized controlled clinical trial. *J Neurosurg Spine* 2007;6:198–209.

5. Puttlitz CM, Rousseau MA, Xu Z, Hu S, Tay BK, Lotz JC. Intervertebral disc replacement maintains cervical spine kinetics. *Spine* 2004; 29:2809–14.
6. Hilibrand AS, Carlson GD, Palumbo MA, Jones PK, Bohlman HH. Radiculopathy and myelopathy at segments adjacent to the site of a previous anterior cervical arthrodesis. *J Bone Joint Surg Am* 1999;81: 519–28.
7. Coric D, Cassis J, Carew JD, Boltes MO. Prospective study of cervical arthroplasty in 98 patients involved in 1 of 3 separate investigational device exemption studies from a single investigational site with a minimum 2-year follow-up. Clinical article. *J Neurosurg Spine* 2010; 13:715–21.
8. Dmitriev AE, Cunningham BW, Hu N, Sell G, Vigna F, McAfee PC. Adjacent level intradiscal pressure and segmental kinematics following a cervical total disc arthroplasty: an in vitro human cadaveric model. *Spine* 2005;30:1165–72.
9. Burkus JK, Haid RW, Traynelis VC, Mummaneni PV. Long-term clinical and radiographic outcomes of cervical disc replacement with the prestige disc: results from a prospective randomized controlled clinical trial. *J Neurosurg Spine* 2010;13:308–18.
10. Coric D, Nunley PD, Guyer RD, et al. Prospective, randomized, multicenter study of cervical arthroplasty: 269 patients from the KineflexiC artificial disc investigational device exemption study with a minimum 2-year follow-up: clinical article. *J Neurosurg Spine* 2011; 15:348–58.
11. Delamarter RB, Murrey D, Janssen ME, et al. Results at 24 months from the prospective, randomized, multicenter investigational device exemption trial of ProDisc-C versus anterior cervical discectomy and fusion with 4-year follow-up and continued access patients. *SAS J* 2010;4:122–8.
12. Hacker RJ. Cervical disc arthroplasty: a controlled randomized prospective study with intermediate follow-up results. Invited submission from the joint section meeting on disorders of the spine and peripheral nerves, March 2005. *J Neurosurg Spine* 2005;3:424–8.
13. Hisey M, Bae HW, Davis R, et al. Multi-center, prospective, randomized, controlled investigational device exemption study comparing Mobi-C® cervical artificial disc to anterior discectomy and fusion in the treatment of symptomatic degenerative disc disease in the cervical spine. Presented at the Annual Meeting of the International Society for the Advancement of Spine Surgery, Las Vegas, NV, April 26–30, 2011.
14. Murrey D, Janssen M, Delamarter R, et al. Results of the prospective, randomized, controlled multicenter food and drug administration investigational device exemption study of the ProDisc-C total disc replacement versus anterior discectomy and fusion for the treatment of 1-level symptomatic cervical disc disease. *Spine J* 2009;9:275–86.
15. Guyer RD, Samocha Y, Ohnmeiss DD. Cervical total disc replacement vs. anterior cervical fusion: data from four prospective, randomized, multicenter trials. Presented at the Annual Meeting of the International Meeting on Advanced Spine Techniques, Copenhagen, Denmark, July 13–16, 2011.
16. Vernon H, Mior S. The neck disability index: a study of reliability and validity. *J Manipulative Physiol Ther* 1991;14:409–15.
17. Ware JE, Jr. SF-36 health survey update. *Spine* 2000;25:3130–9.
18. Patwardhan AG, Tzermiadianos MT, Tsitsopoulos PP, et al. Primary and coupled motions after cervical total disc replacement using a compressible six-degree-of-freedom prosthesis. *Eur Spine J* 2009.
19. Chang UK, Kim DH, Lee MC, Willenberg R, Kim SH, Lim J. Changes in adjacent-level disc pressure and facet joint force after cervical arthroplasty compared with cervical discectomy and fusion. *J Neurosurg Spine* 2007;7:33–9.
20. Wigfield CC, Skrzypiec D, Jackowski A, Adams MA. Internal stress distribution in cervical intervertebral discs: the influence of an artificial cervical joint and simulated anterior interbody fusion. *J Spinal Disord Tech* 2003;16:441–9.
21. Maldonado CV, Paz RD, Martin CB. Adjacent-level degeneration after cervical disc arthroplasty versus fusion. *Eur Spine J* 2011;20(Suppl 3):403–7.
22. Hisey MS, Bae H, Davis R, et al. Does total disc replacement reduce the incidence of adjacent segment degeneration: results of a multicenter, prospective, randomized, controlled trial comparing Mobi-C cervical artificial disc to anterior cervical fusion. Presented at the Annual Meeting of the North American Spine Society, Chicago, IL, November 2–5, 2011.
23. Matsunaga S, Kabayama S, Yamamoto T, Yone K, Sakou T, Nakaniishi K. Strain on intervertebral discs after anterior cervical decompression and fusion. *Spine* 1999;24:670–5.
24. Sears WR, McCombe PF, Sasso RC. Kinematics of cervical and lumbar total disc replacement. *Semin Spine Surg* 2006;18:117–29.
25. Reyes-Sanchez A, Miramontes V, Olivarez LMR, et al. Initial clinical experience with a next-generation artificial disc for the treatment of symptomatic degenerative cervical radiculopathy. *SAS J* 2010;4:9–15.
26. Cheng L, Nie L, Zhang L, Hou Y. Fusion versus Bryan cervical disc in two-level cervical disc disease: a prospective, randomised study. *Int Orthop* 2009;33:1347–51.
27. Peng CW, Yue WM, Basit A, et al. Intermediate results of the Prestige LP cervical disc replacement: clinical and radiological analysis with minimum two-year follow-up. *Spine* 2011;36:E105–11.