

An in vivo kinematic comparison of dynamic lumbar stabilization to lumbar discectomy and posterior lumbar fusion using radiostereometric analysis

Soo-An Park, Amir H. Fayyazi, Kenneth S. Yonemura, Bruce E. Fredrickson and Nathaniel R. Ordway

Int J Spine Surg 2012, 6 () 87-92
doi: <https://doi.org/10.1016/j.ijsp.2012.02.003>
<https://www.ijssurgery.com/content/6/87>

This information is current as of May 17, 2025.

Email Alerts Receive free email-alerts when new articles cite this article. Sign up at:
<http://ijssurgery.com/alerts>



An in vivo kinematic comparison of dynamic lumbar stabilization to lumbar discectomy and posterior lumbar fusion using radiostereometric analysis

Soo-An Park, MD, PhD ^a, Amir H. Fayyazi, MD ^b, Kenneth S. Yonemura, MD ^c,
Bruce E. Fredrickson, MD ^d, Nathaniel R. Ordway, MS ^{e,*}

^a Spine Center, Seoul St Mary's Hospital, The Catholic University of Korea, College of Medicine, Seoul, South Korea

^b VSAS Orthopaedics, Institute for Advanced Healthcare, Allentown, PA

^c Wasatch Neurological Surgery, Bountiful, UT

^d Department of Orthopedics, Syracuse VA Medical Center, Syracuse, NY

^e Department of Orthopedic Surgery, SUNY Upstate Medical University, Syracuse, NY

Abstract

Background: Biomechanical studies have shown that dynamic stabilization restores the neutral zone and stabilizes the motion segment. Unfortunately, there are limitations to clinical measurement of lumbar motion segments when using routine radiographs. Radiostereometric analysis is a 3-dimensional technique and can measure the spinal motion segment more accurately than techniques using plain film radiographs. The purpose of this study was measure and compare the range of motion after dynamic stabilization, posterior lumbar fusion (PLF), and lumbar discectomy.

Methods: Four patients who underwent lumbar decompression and dynamic stabilization (Dynesys; Zimmer Spine, Inc., Warsaw, Indiana) for treatment of lumbar spondylosis were compared with 4 patients with a similar diagnosis who were treated by PLF and pedicle screw fixation (PLF group) and 8 patients who had undergone lumbar microdiscectomy (discectomy group) for treatment of radiculopathy. During the surgical procedure, 3 to 5 tantalum beads were placed into each of the operative segments. The patients were followed up postoperatively at 1 month, 1 year, and 2 years. At each follow-up time point, segmental motions (flexion, extension, and total sagittal range of motion [SROM]) were measured by radiostereometric analysis.

Results: Flexion, extension, and SROM measured $1.0^\circ \pm 0.9^\circ$, $1.5^\circ \pm 1.3^\circ$, and $2.3^\circ \pm 1.2^\circ$, respectively, in the Dynesys group; $1.0^\circ \pm 0.6^\circ$, $1.1^\circ \pm 0.9^\circ$, and $1.5^\circ \pm 0.6^\circ$, respectively, in the PLF group; and $2.9^\circ \pm 2.4^\circ$, $2.3^\circ \pm 1.5^\circ$, and $4.7^\circ \pm 2.2^\circ$, respectively, in the discectomy group. No significant difference in motion was seen between the Dynesys and PLF groups or between the Dynesys and discectomy groups in extension. Significant differences in motions were seen between the PLF and discectomy groups and between the Dynesys and discectomy groups in flexion ($P = .007$) and SROM ($P = .002$). There was no significant change in the measured motions over time.

Conclusions: In this study a significantly lower amount of motion was seen after dynamic stabilization and PLF when compared with discectomy. A future study with a larger cohort is necessary to examine what effect, if any, these motions have on clinical outcomes.

© 2012 ISASS - International Society for the Advancement of Spine Surgery. Published by Elsevier Inc. All rights reserved.

Keywords: Spine surgery; RSA; Range of motion; Kinematics

Advances in fusion techniques have increased the fusion rates in the lumbar spine.¹⁻⁶ This increase in fusion rates has not resulted in an equivalent improvement in successful clinical outcomes. Fusion rates have been reported to be as

high as 100% with some techniques.^{1,4,5} The clinical success rate, on the other hand, is significantly lower and can range from 60% to 80%.^{1,4-6} Recent literature has criticized lumbar fusion when used to treat lumbar degenerative disc disease.⁷⁻¹¹ This criticism is based on the efficacy of lumbar fusion when treating low-back pain and on the developing adjacent-segment disease.

Lumbar spine dynamic stabilization systems have been developed as an alternative to lumbar fusion. These devices will theoretically allow motion in the instrumented surgical segments and achieve lumbar stability without bone graft-

Partially supported by Zimmer Spine, Inc. (Warsaw, Indiana) and by DePuy Spine, Inc. (Raynham, Massachusetts).

* Corresponding author: Nathaniel R. Ordway, MS, Department of Orthopedic Surgery, SUNY Upstate Medical University, 750 E Adams St, Syracuse, NY 13210; Tel: 315-464-6462; Fax: 315-464-6638.

E-mail address: ordwayn@upstate.edu

ing. Although the clinical outcomes have been variable in the literature, *in vitro* studies have shown dynamic stabilization to restore the neutral zone of the injured spine to a magnitude less than that of the intact spine.¹² Posterior dynamic stabilization is based on the premise that the devices can restore functional stability while maintaining some or all of the intersegmental motion. By allowing motion, these devices are intended to reduce or eliminate the incidence of adjacent-segment degeneration.¹³

The Dynesys system (Zimmer Spine, Inc., Warsaw, IN) was designed with the intention to neutralize abnormal forces and restore painless function to the spinal segments while protecting adjacent segments. In elderly patients with spinal stenosis and degenerative spondylolisthesis, the Dynesys system has shown favorable clinical and radiologic results.^{7,10,14,15} However, few studies have evaluated the kinematics of dynamic stabilization with the Dynesys system *in vivo*. Radiostereometric analysis (RSA) is an accurate *in vivo* measurement technique and has been used to examine spinal kinematics in 3 dimensions.^{16,17}

The purpose of this study was to examine the *in vivo* kinematics of a dynamically stabilized segment over time in comparison with the other common posterior lumbar procedures, such as posterior lumbar fusion (PLF) and lumbar discectomy using RSA. We hypothesized that the postoperative sagittal kinematics of a dynamically stabilized motion segment was different from a postdiscectomy segment and a rigidly instrumented segment.

Methods

Patient selection

This study enrolled 4 patients (2 men and 2 women; mean age, 63.5 ± 11.3 years) with lumbar spondylosis with or without instability to undergo dynamic stabilization with the Dynesys system and decompression at L3-4, L4-5, and/or L5-S1 (dynamic stabilization group). Another 4 patients (2 men and 2 women; mean age, 64.8 ± 8.3 years) with the same diagnostic criteria were enrolled to undergo PLF and pedicle screw fixation with decompression at L2-3, L3-4, and/or L4-5 (PLF group). Finally, 8 patients (4 men and 4 women; mean age, 40.9 ± 5.7 years) with lumbar disc herniation at either L4-5 or L5-S1 were enrolled to undergo lumbar discectomy (discectomy group). The institutional review board and the radiation safety board approved the study before patient enrollment. In addition, informed consent was obtained from each subject.

Operative procedures

Standard surgical technique was followed in this study population by 3 of the authors. In the discectomy group, a mini-open technique was used. After unilateral exposure of the posterior elements, hemilaminotomy, medial facetectomy, and foraminotomy were performed. The facet capsule was protected in each case. Less than 50% of the facet was

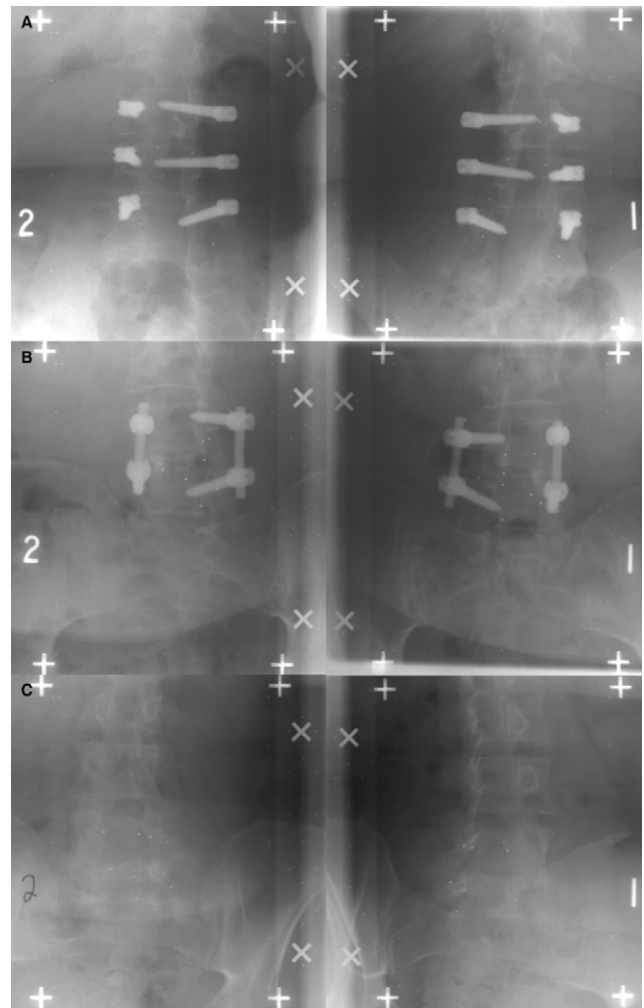


Fig. 1. Selected examples of biplanar radiographic images for RSA of lumbar dynamic stabilization (A), posterolateral fusion and instrumentation (B), and discectomy (C).

resected. The extruded disc material was removed, followed by removal of additional loose nucleus from within the disc. In the PLF and dynamic stabilization groups, wide laminectomy was performed, followed by medial facetectomy and foraminotomy. Less than 50% of the facet was resected on each side. The operated level was instrumented in a routine fashion. The position of the hardware was examined intraoperatively with fluoroscopy.

During the surgical procedure, 3 to 5 tantalum beads (0.8 or 1.0 mm diameter) were implanted into the adjacent vertebrae at the operated levels (Fig. 1). There were three 2-level cases in the PLF group, two 2-level cases in the dynamic stabilization group, and 8 single-level cases in the discectomy group (Table 1). The bead sizes used were 1.0 mm for the single-level cases and 0.8 and 1.0 mm for the 2-level cases (with the 0.8-mm beads between levels). The beads were implanted into the vertebrae by use of the appropriate insertion tool (RSA Biomedical Innovations AB, Umeå, Sweden). Beads oriented in this manner during a posterior approach have been shown to have an accuracy of

Table 1
Demographic data

	Sex	Age (y)	Level	n
Dynamic stabilization	2 men and 2 women	63.5 ± 11.3	L2-3-4	1
			L4-5	2
			L4-5-S1	1
PLF	2 men and 2 women	64.8 ± 8.3	L2-3-4	1
			L3-4-5	2
			L4-5	1
Discectomy	4 men and 4 women	42.8 ± 6.2	L4-5	2
			L5-S1	6

less than 0.1 mm and 0.5° for translational and rotational measurements, respectively.¹⁸

Radiostereometric analysis

The patients were followed up postoperatively at 1-month, 1-year, and 2-year intervals. For the RSA examination, simultaneous biplanar standing radiographic films were collected (Fig. 1). Each pair of radiographs was obtained with the roentgen tubes at 40° at the level of the lumbar spine. A wall-mounted Plexiglas calibration cage with tantalum beads was placed between the subject and the films (RSA Biomedical Innovations AB). The cage defined the 3-dimensional coordinate system and was used to calculate the position of the roentgen foci and subsequent locations of the beads in each vertebra. The roentgen tubes were 1.6 m from the film, and the beams of both tubes were collimated to the 2 grids on the cage.

At each postoperative follow-up, biplanar radiographs were obtained in the standing neutral position (N) and during forward bending (FB) and backward bending (BB). A standardized protocol for positioning and movements was performed by all subjects and overseen by a single investigator. Subjects were instructed to maximize the motion of the lumbar spine, and each position was performed 3 times before film collection.

Radiation exposure varied for each subject depending on body habitus. The primary objective of the radiographic examination was to identify the tantalum markers; therefore anatomic resolution and contrast were less important than for conventional radiographic skeletal examination. To reduce the radiation dose, at the expense of contrast in the radiograph, exposure was performed using high-voltage techniques (high kilovolt, low ampere). High-speed screens that allow less radiation were also used. A typical exposure technique for the examination in this study was 8 mAs (milliampere-second) at 150 kVp (kilovolt-peak).

The biplanar images were digitized and analyzed by use of UmRSA 6.0 software (RSA Biomedical Innovations AB). The 3-dimensional locations of beads were calculated, and the segmental motions (based on the bead clusters) were calculated for the neutral, flexed, and extended positions. Instability of the tantalum beads between positions and over time points was evaluated with a mean error of rigid body fitting parameter, and any data with an error greater than 0.3

mm were discarded from the analysis. Segmental motions were calculated based on the relative motion of the superior vertebra to the inferior vertebra. Sagittal plane rotation was calculated for flexion (N to FB), extension (N to BB), and sagittal range of motion (SROM) (BB to FB).

Radiographic and clinical evaluations

The clinical radiographs obtained 1 year and 2 years postoperatively were reviewed by multiple observers for the presence of pseudarthrosis or hardware failure. The patients were clinically assessed at the preoperative visit and at each follow-up visit using the visual analog scale (VAS) (range, 0 to 100) for low-back pain and Oswestry Disability Index (ODI) (range, 0 to 100).

Statistical analysis

All statistical tests were performed with SPSS 13.0 for Windows (SPSS Inc., Chicago, Illinois). A 3 (operations: dynamic stabilization, PLF, and discectomy) × 3 (postoperative time points: 1 month, 1 year, and 2 years) analysis of variance was performed for each dependent variable (flexion, extension, and SROM). VAS and ODI scores at each follow-up time point were submitted to 2 different repeated-measures analyses of variance in each group. A priori, the α level was set at .05 for all statistical procedures.

Results

We evaluated 16 patients (8 women and 8 men; mean age, 53.4 ± 13.4 years) representing 21 motion segments for this study. Of the 21 treated levels, 6 were treated with the dynamic stabilization system, 7 underwent PLF and instrumentation, and 8 underwent lumbar discectomy. There were no complications regarding the presence of pseudarthrosis or hardware failure in the enrolled subjects at either the 1- or 2-year time point.

In the Dynesys group, the motion of the instrumented segments did not significantly change over the follow-up time points in any direction (flexion, $P = .483$; extension, $P = .329$; SROM, $P = .471$). There was also no significant difference in the range of motion (ROM) of the posterolateral fusion group or the lumbar discectomy group over the follow-up time points. A significant difference was present when we compared the PLF and discectomy groups. The flexion (2.9° ± 2.4°) and SROM (4.7° ± 2.2°) of the discectomy group were significantly greater than those of the PLF group (1.0° ± 0.6° [$P = .023$] and 1.5° ± 0.6° [$P < .001$], respectively) and dynamic stabilization group (1.0° ± 0.9° [$P = .007$] and 2.3° ± 1.2° [$P = .002$], respectively). In extension, the discectomy group (2.3° ± 1.5°) showed significantly greater motion than the PLF group (1.1° ± 0.9°, $P = .036$); a significant difference was not seen when compared with the Dynesys group (1.7° ± 1.2°, $P = .257$) (Table 2, Fig. 2).

A significant difference was not shown in the clinical outcomes, VAS ($P = .215$; power, 0.296) and ODI ($P =$

Table 2
Radiostereometric segmental rotations in sagittal plane over time after dynamic stabilization with Dynesys, PLF, and discectomy

Motions	Time	Dynamic stabilization (mean ± SD) (°)		Discectomy (mean ± SD) (°)
			PLF (mean ± SD) (°)	
Flexion	1 mo	1.2 ± 0.7	1.3 ± 0.3	3.3 ± 2.6
	1 y	0.7 ± 0.9	1.3 ± 0.5	2.7 ± 2.8
	2 y	1.0 ± 1.1	0.2 ± 0.2	1.7 ± 0.2
	Mean	1.0 ± 0.9*	1.0 ± 0.6*	2.9 ± 2.4
Extension	1 mo	2.3 ± 1.6	1.1 ± 0.9	2.7 ± 1.8
	1 y	1.0 ± 0.4	1.2 ± 1.1	1.8 ± 1.3
	2 y	1.7 ± 1.4	0.7 ± 0.3	1.8 ± 0.3
	Mean	1.5 ± 1.2	1.1 ± 0.9*	2.3 ± 1.5
SROM	1 mo	2.9 ± 0.4	1.5 ± 1.1	4.8 ± 1.9
	1 y	1.8 ± 1.0	1.8 ± 0.3	5.1 ± 3.2
	2 y	2.3 ± 1.7	0.9 ± 0.0	3.4 ± 0.0
	Mean	2.3 ± 1.2*	1.5 ± 0.6*	4.7 ± 2.2

* Significantly different compared with discectomy group.

.457; power, 0.161), among the 3 groups. The VAS and ODI scores were significantly decreased in each group after the surgical procedure and were maintained over the follow-up period (Table 3). Revision of the surgical procedure was not performed in any of the groups.

Discussion

The spine is subjected to a combination of forces and moments originating from muscles and external loads with unknown magnitudes. Although in vitro biomechanical evaluation of an instrumentation system is essential, the result may not represent the in vivo environment. Therefore it is crucial to analyze the biomechanical properties in vivo. Cakir et al.¹⁹ reported 4.1° of SROM for the index level of Dynesys stabilization using the Cobb technique at their final follow-up (mean, 37.5 months) and did not find any difference when compared with the preoperative films. Kim et al.¹⁰ reported 3.9° of SROM for the Dynesys-stabilized segment at their final follow-up (mean, 29 months); however, this was significantly decreased (69.5% reduction) from the preoperative radiographs. In our study there was

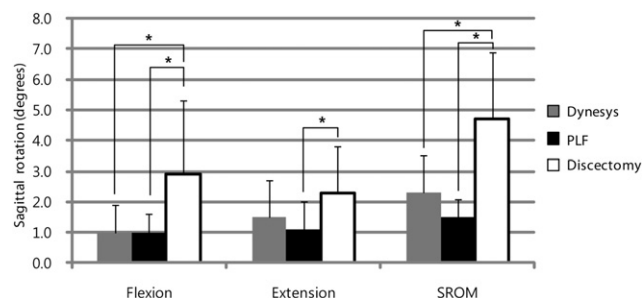


Fig. 2. Differences of postoperative sagittal plane rotation after lumbar dynamic stabilization, posterolateral fusion and instrumentation, and discectomy. Asterisks denote statistical significance ($P < .05$).

Table 3
Changes of VAS for low-back pain and ODI for each group

	Preoperative	Postoperative		
		1 mo	1 y	2 y
VAS				
Dynamic stabilization	67 ± 8	20 ± 22*	4 ± 4	15 ± 20
PLF	75 ± 18	26 ± 15*	30 ± 25	35 ± 18
Discectomy	74 ± 14	31 ± 31*	39 ± 30	35 ± 28
ODI				
Dynamic stabilization	56 ± 18	21 ± 18*	11 ± 16*	24 ± 14
PLF	49 ± 2	32 ± 8*	22 ± 18	28 ± 8
Discectomy	58 ± 11	31 ± 18*	25 ± 15	28 ± 18

NOTE. The range on both scales is 0 to 100, and values listed are mean ± SD.

* Significantly changed from immediately last time point.

2.3° of SROM with dynamic stabilization over the 24-month follow-up. The most likely explanation for the discrepancy between the data of Cakir et al. or Kim et al. and the current study is the greater error of measurement present when using the Cobb technique in comparison with the RSA technique.

The segmental motions after dynamic lumbar stabilization were significantly smaller than those of lumbar discectomy and were slightly greater than those of the fusion group. Dynamic stabilization resulted in 2.3° of SROM, representing a 51% reduction with significance compared with the discectomy group. In addition, Dynesys instrumentation resulted in 1.5° of extension measured in our study, which represented a 35% reduction when compared with the discectomy group and a 36% increase when compared with the PLF group. Segmental extension after dynamic stabilization was approximately half of the motion between the discectomy and the PLF groups.

There are other studies that have attempted to quantify the motion after Dynesys instrumentation in an in vitro setting (Table 4). Schulte et al.²⁰ reported 2.0° of SROM after Dynesys stabilization, representing 75% and 68% reductions from the decompressed and intact spines, respectively. Cheng et al.²¹ reported 1.3° of SROM after Dynesys stabilization, representing 80% and 75% reductions from the decompressed and intact spines, respectively. The sagittal ROMs in these 2 in vitro studies were tested by use of pure moments (5–6 Nm). In a preclinical evaluation in a primate model, Cunningham et al.²² showed a reduction in SROM of 27% of the intact motion after Dynesys spinal stabilization in the acute period after surgery, and this reduction increased to 56% and 70% after 6 and 12 months, respectively. In the current in vivo study, there were no significant changes in the SROM over time.

Dynesys instrumentation has been shown to affect segmental motions in the coronal and axial planes. Cheng et al.²¹ have noted 2.0° of lateral bending and 4.2° of axial rotation for the index level after Dynesys stabilization, representing 62% and 61% reductions of lateral bending and a 16% reduction and 2.4% increase of axial rotation from the

Table 4
Comparison with literature of SROM after dynamic stabilization

	Motion (SD) (°)			Tests	Levels measured	Measurement	Loads
	Flexion-extension	Flexion	Extension				
Current study	2.1 (1.3)	1.0 (0.9)	1.5 (1.3)	In vivo	L2-L3, L3-L4, L4-L5, L5-S1	RSA	Physiological maximal
Cakir et al. ¹⁹	4.1 (3.7)			In vivo	L4-L5	Clinical radiograph	Physiological maximal
Kim et al. ¹⁰	3.9 (5)			In vivo	L2-L3, L3-L4, L4-L5, L5-S1	Clinical radiograph	Physiological maximal
Schulte et al. ²⁰	2.0 (0.8)	1.0 (0.4)	1.0 (0.4)	In vitro	L1-L2, L2-L3, L3-L4, L4-L5	Positioning sensor	5 Nm
Cheng et al. ²¹	1.28 (0.42)			In vitro	L3-L4	Optoelectronic cameras	6 Nm
Freudiger et al. ²³		4.3 (0.9)		In vitro	L3-L4, L4-L5	Magnetic field-based system	18.3 Nm
Niosi et al. ¹²		0.5 (0.4): short spacer	1.1 (0.9)	In vitro	L3-4	Optoelectronic cameras	12.5 Nm
		1.0 (0.6): standard	0.5 (0.3)				7.5 Nm
		1.0 (0.5): long	1.1 (0.7)				
			1.3 (0.9)				

decompressed and intact spines, respectively. Schulte et al.²⁰ reported 2.2° of lateral bending and 3.3° of axial rotation, representing 72% and 70% reductions of lateral bending and 23% and 15% reductions of axial rotation from the decompressed and intact spines, respectively.

When the clinical data available in the literature are compared, significant differences are seen. Cakir et al.¹⁹ compared the ROM after Dynesys instrumentation with instrumented fusion cases and noted a significant difference between the groups. In the fused group, a decrease in segmental ROM was seen in most cases, whereas in the dynamically stabilized patients, there was no change in the segmental ROM postoperatively. On the other hand, Cheng et al.²¹ reported that the ROM after Dynesys stabilization in vitro was not significantly different from that after fixation with rigid rod constructs, although both significantly reduced the mean ROM at the index levels compared with the intact and destabilized conditions. Schmoelz et al.¹³ noted that the Dynesys fixation and rigid fixation both reduced the ROM and neutral zone below the magnitude of the intact spine for lateral bending and flexion. In extension, the rigid fixation was stiffer than the Dynesys fixation, with the ROM of the Dynesys fixation being in the range of the intact spine. In our study no significant differences between the dynamic stabilization and PLF groups suggested that the kinematics after dynamic stabilization is not significantly different when compared with rigid fixation under the physiological movements.

The magnitude of segmental motion after dynamic stabilization can be affected by several factors: the external loads applied, the level of motion segment, the length of the spacer, and the measurement techniques.¹² The ROM after dynamic stabilization instrumentation is highly dependent on the size of the spacer among these factors. A 4-mm increase in spacer length led to an average intersegmental

motion increase of 23% in extension. In this study we did not assess the effect of the spacer size. Given the small sample size in this study, this analysis could not be performed. In each case distraction was applied before placement of the spacer according to the instrumentation technique.

It is also important to note that this was not a clinical, randomized study and the demographics between the discectomy group and the instrumented groups (PLF and dynamic stabilization) were not similar. This could have had a potential influence on the ROM measures. The discectomy group was on average younger and was treated surgically for alleviation of radiculopathy. The PLF group and dynamic stabilization group were treated for claudication and spinal stenosis. Although we did not categorize the degree of degenerative disc disease, the degree of degenerative disc disease was more prominent in the PLF and dynamic stabilization groups. Finally, there are limitations associated with the RSA technique. Although RSA is very sensitive in measuring motion and displacement after the surgical procedure, it cannot be used to measure preoperative motion. Therefore those values are not available in terms of comparing the sagittal kinematics between groups preoperatively.

Although the statistical power with respect to the clinical scores in this study was low because of the small sample size of each group, both the VAS and the ODI were significantly improved in each group. However, the review of the literature on Dynesys dynamic stabilization shows contradictory results. Schaeren et al.¹⁴ investigated 26 patients with a mean age of 71 years who underwent Dynesys stabilization with minimum 4-year follow-up and showed significant improvements in the pain scale from 80 to 25 and in walking distance from 250 m to greater than 1000 m. Patient satisfaction remained high, and 95% of the individ-

uals declared that they would undergo the same operative procedure for the same condition again. On the other hand, Grob et al.⁷ reported less favorable 2-year results and a high reoperation rate in 50 consecutive patients with different indications. The mean age of the patients was 50 years, and only half of the patients declared that the operation had helped and had improved their overall quality of life. Kim et al.¹⁰ reviewed 21 patients after Dynesys stabilization. The mean age of the patients was 61 years, and the minimum follow-up period was longer than 4 years. The ODI and VAS were significantly improved and disc heights were maintained at final follow-up in both single- and multiple-level cases. However, the authors reported retrolisthesis on adjacent segments above index level only in multiple-level patients.

The premise behind dynamic stabilization is to control the spinal motions, to restore physiological load transmission to relieve painful structures and prevent adjacent-segment disease. In this study there were significant differences in immediate postoperative ROM between the Dynesys and PLF groups compared with the discectomy group, and these differences were maintained throughout a 2-year follow-up period. The most preserved motion was extension when compared against the motion after a discectomy procedure. However, there were no significant differences in postoperative ROM between the dynamic stabilization and PLF groups. A future study with a larger cohort is necessary to examine what effect, if any, these motions have on clinical outcomes.

References

- Burkus JK, Gornet MF, Schuler TC, Kleeman TJ, Zdeblick TA. Six-year outcomes of anterior lumbar interbody arthrodesis with use of interbody fusion cages and recombinant human bone morphogenetic protein-2. *J Bone Joint Surg Am* 2009;91:1181–9.
- Agrillo U, Panagiotopoulos K, Corbino L, Schettini G, Puzzilli F. Lateral lumbar interbody fusion via a unilateral true percutaneous approach associated with minimally invasive pedicle screw fixation for degenerative disc disease and lumbar instability. A technical note. *J Neurosurg Sci* 2010;54:65–9.
- Lad SP, Nathan JK, Boakye M. Trends in the use of bone morphogenetic protein as a substitute to autologous iliac crest bone grafting for spinal fusion procedures in the United States. *Spine (Phila Pa 1976)* 2011;36:E274–81.
- Karikari IO, Isaacs RE. Minimally invasive transforaminal lumbar interbody fusion: a review of techniques and outcomes. *Spine (Phila Pa 1976)* 2010;35:S294–301.
- Patil SS, Lindley EM, Patel VV, Burger EL. Clinical and radiological outcomes of axial lumbar interbody fusion. *Orthopedics* 2010;33:883.
- Li J, Dumonski ML, Liu Q, et al. A multicenter study to evaluate the safety and efficacy of a stand-alone anterior carbon I/F Cage for anterior lumbar interbody fusion: two-year results from a Food and Drug Administration investigational device exemption clinical trial. *Spine (Phila Pa 1976)* 2010;35:E1564–70.
- Grob D, Benini A, Junge A, Mannion AF. Clinical experience with the Dynesys semirigid fixation system for the lumbar spine: surgical and patient-oriented outcome in 50 cases after an average of 2 years. *Spine (Phila Pa 1976)* 2005;30:324–31.
- Sengupta DK. Dynamic stabilization devices in the treatment of low back pain. *Orthop Clin North Am* 2004;35:43–56.
- Kfer W, Reichel H, Mattes T, et al. Adjacent segment mobility after rigid and semirigid instrumentation of the lumbar spine. *Spine (Phila Pa 1976)* 2009;34:1287–91.
- Kim CH, Chung CK, Jahng TA. Comparisons of outcomes after single or multilevel dynamic stabilization: effects on adjacent segment. *J Spinal Disord Tech* 2011;24:60–7.
- Harrop JS, Youssef JA, Maltenfort M, et al. Lumbar adjacent segment degeneration and disease after arthrodesis and total disc arthroplasty. *Spine (Phila Pa 1976)* 2008;33:1701–7.
- Niosi CA, Zhu QA, Wilson DC, Keynan O, Wilson DR, Oxland TR. Biomechanical characterization of the three-dimensional kinematic behaviour of the Dynesys dynamic stabilization system: an in vitro study. *Eur Spine J* 2006;15:913–22.
- Schmoelz W, Huber JF, Nydegger T, Claes L, Wilke HJ. Dynamic stabilization of the lumbar spine and its effects on adjacent segments: an in vitro experiment. *J Spinal Disord Tech* 2003;16:418–23.
- Schaeren S, Broger I, Jeanneret B. Minimum four-year follow-up of spinal stenosis with degenerative spondylolisthesis treated with decompression and dynamic stabilization. *Spine (Phila Pa 1976)* 2008;33:E636–42.
- Schnake KJ, Schaeren S, Jeanneret B. Dynamic stabilization in addition to decompression for lumbar spinal stenosis with degenerative spondylolisthesis. *Spine (Phila Pa 1976)* 2006;31:442–9.
- Park SA, Ordway NR, Fayyazi AH, Fredrickson BE, Yuan HA. Comparison of Cobb technique, quantitative motion analysis, and radiostereometric analysis in measurement of segmental range of motions after lumbar total disc arthroplasty. *J Spinal Disord Tech* 2009;22:602–9.
- Fayyazi AH, Ordway NR, Park SA, Fredrickson BE, Yonemura K, Yuan HA. Radiostereometric analysis of postoperative motion after application of Dynesys dynamic posterior stabilization system for treatment of degenerative spondylolisthesis. *J Spinal Disord Tech* 2010;23:236–41.
- Brooks D, Sacks JM, Ordway NR, Fredrickson BE. Evaluation of the accuracy and reliability of radiostereometric analysis in lumbar and cervical spine surgery. In: Transactions of the 49th Annual Meeting of the Orthopaedic Research Society, New Orleans, LA, February 2–5, 2003. Chicago, IL: Orthopaedic Research Society; 2003:1077.
- Kakir B, Carazzo C, Schmidt R, Mattes T, Reichel H, Käfer W. Adjacent segment mobility after rigid and semirigid instrumentation of the lumbar spine. *Spine (Phila Pa 1976)* 2009;34:1287–91.
- Schulte TL, Hirschler C, Haversath M, et al. The effect of dynamic, semi-rigid implants on the range of motion of lumbar motion segments after decompression. *Eur Spine J* 2008;17:1057–65.
- Cheng BC, Gordon J, Cheng J, Welch WC. Immediate biomechanical effects of lumbar posterior dynamic stabilization above a circumferential fusion. *Spine (Phila Pa 1976)* 2007;32:2551–7.
- Cunningham BW, Dawson JM, Hu N, Kim SW, McAfee PC, Griffith SL. Preclinical evaluation of the Dynesys posterior spinal stabilization system: a nonhuman primate model. *Spine J* 2010;10:775–83.
- Freudiger S, Dubois G, Lorrain M. Dynamic neutralisation of the lumbar spine confirmed on a new lumbar spine simulator in vitro. *Arch Orthop Trauma Surg* 1999;119:127–32.