

INTERNATIONAL  
JOURNAL  
of  
SPINE  
SURGERY

## Overtightening of halo pins resulting in intracranial penetration, pneumocephalus, and epileptic seizure

Alexander W. Glover, Rasheed Zakaria, Paul May and Chris Barrett

*Int J Spine Surg* 2013, 7 () e42-e44

doi: <https://doi.org/10.1016/j.ijsp.2013.01.004>

<https://www.ijssurgery.com/content/7/e42>

This information is current as of May 17, 2025.

---

**Email Alerts** Receive free email-alerts when new articles cite this article. Sign up at:  
<http://ijssurgery.com/alerts>

## Overtightening of halo pins resulting in intracranial penetration, pneumocephalus, and epileptic seizure

Alexander W. Glover, BSc, MBChB (Hons)\*, Rasheed Zakaria, MBChB, Paul May, MBBS, FRCS, Chris Barrett, MBChB (Hons)

*The Walton Centre NHS Foundation Trust, Liverpool, UK*

**Abstract** A 60-year-old man sustained an undisplaced type III odontoid fracture following a fall down a full flight of stairs. His medical history was remarkable for a partial pancreatectomy and splenectomy in 2006 for chronic pancreatitis. This had rendered him diabetic, on insulin, and he required long-term administration of penicillin V.

The fracture was treated with a halo vest, and, unknowing of its potentially serious consequences, the patient continued to tighten the halo pins himself.

He presented 1 month later following a witnessed seizure. A computed tomography scan was performed, which demonstrated 2 cranial perforations, with the halo pins penetrating the cranium and resultant pneumocephalus.

He was started on antiepileptic medication and was placed in a pinless halo system. He had no further seizures and has made an uneventful neurological recovery. This paper serves to highlight the potential complications which may arise from the use of a halo vest. Proper patient education is essential to avoid these serious yet avoidable events, and patients with low bone density and the immunosuppressed should be monitored closely.

© 2013 ISASS – The International Society for the Advancement of Spine Surgery. Published by Elsevier Inc. All rights reserved.

**Keywords:** Odontoid fractures; Halo pin penetration; Seizure

Halo vests are frequently used in the treatment of unstable cervical spine fractures. In use in its current form since 1959, the halo vest comprises a titanium ring held firmly to the cranium by means of 4 titanium pins. This is then attached to a polythene “vest” by carbon fiber rods, thereby immobilizing the cervical spine. This leaves the mandible free, in contrast to traditional hard collars, and is less intrusive to the patient.

As with any surgical procedure, there are a number of recognized complications of halo placement. Of these, the most common are pin loosening, pin site infection, pressure sores, respiratory tract infections, cosmetic scarring, and pin site discomfort.<sup>1,2</sup> To our knowledge, intracranial penetration of the pins causing epileptic seizures has been reported infrequently in the literature,<sup>3–7</sup> as has pneumocephalus.<sup>8</sup>

Proper patient education is essential to facilitate early recognition and treatment of the potential complications in a bid to avert disastrous complications.

We report the case of a patient who was treated by means of a halo vest for an undisplaced type III odontoid fracture, who began tightening the pins himself at home. This resulted in cranial vault perforation, an epileptic seizure and pneumocephalus. (Fig. 1A and B).

### Case report

A 60-year-old retired engineer presented to a local A and E department with severe neck pain following a fall down the stairs. His medical history was remarkable for a cholecystectomy, partial pancreatectomy, and splenectomy in 2006 for chronic pancreatitis. As a direct consequence of this, he was diabetic (on insulin) and required prophylactic long-term administration of penicillin V.

There were no sinister features to the fall, and a thorough head-to-toe examination revealed no other injuries. There was no focal neurological deficit, and sphincter function was normal. A subsequent computed tomography (CT) scan revealed an undisplaced type III odontoid peg fracture.

Given his good functional status, it was decided to treat this injury by means of a DP Medical PMT halo system with the standard (Fig. 2A–D) titanium pins. This was tightened to

\* Corresponding author: A.W. Glover, The Walton Centre NHS Foundation Trust, Liverpool, UK.

E-mail address: [alexander.w.glover@me.com](mailto:alexander.w.glover@me.com)

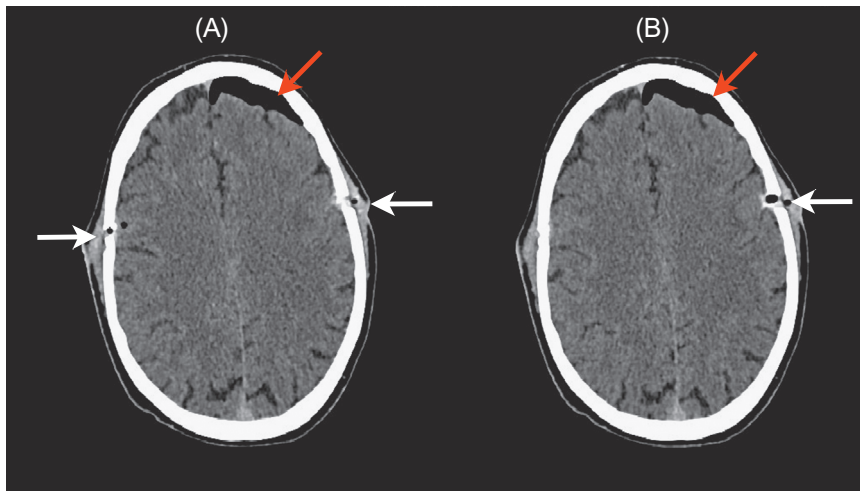


Fig. 1. (A and B) Axial computed tomography (CT) head demonstrating full-thickness cranial vault perforations (white arrow) and left-sided, pneumocephalus (red arrow). (Color version of figure is available online.)

0.9 N m of torque using the supplied torque wrench, and was checked at 24 h postapplication, and every 2 weeks thereafter.

On his first 2 follow-up appointments, it was noted the frontal pin sites had become loose, and were therefore resited. There were no signs of pin site infection and the patient was neurologically and systemically well. He presented 2 weeks later having sustained a witnessed, generalized seizure while out walking with his daughter. There was no history of seizures.

The patient asserted that, following his first follow-up appointment, he was keen to avoid having the halo pins resited for a third time. When the pins became loose days after his appointment, and confident in his ability as an engineer, he proceeded to tighten the screws himself. This happened on 3 occasions prior to presentation.

On examination, he was afebrile with a blood pressure of 136/80. A finger-prick glucose measurement was within normal limits. A cardiorespiratory examination was

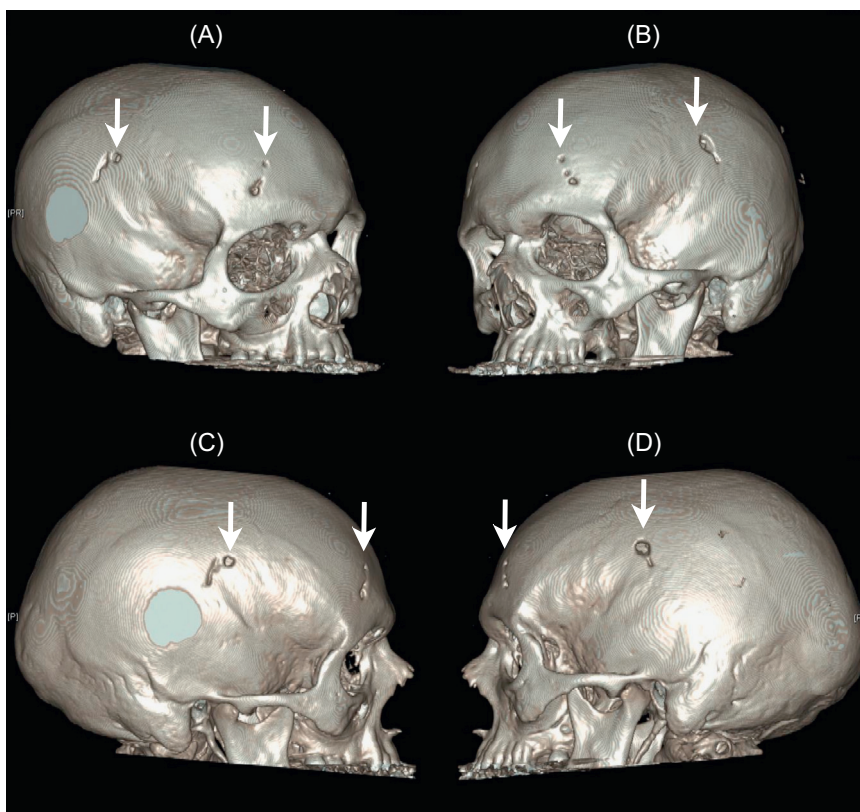


Fig. 2. (A–D) Reconstructed 3-D CT images demonstrating sites of cranial penetration of halo pins.

unremarkable, as were cranial nerves and peripheral nervous system. The parietal pin sites were erythematous, offensive smelling, and were now loose.

Routine blood tests including full blood count, renal profile, inflammatory markers, and calcium and magnesium levels were normal. An electrocardiogram showed normal sinus rhythm.

A contrast-enhanced CT scan of the brain and cervical spine was performed. This demonstrated full-thickness skull perforations with a large left-sided pneumocephalus. There was neither midline shift nor deep collection.

He was commenced on 6 hourly IV benzylpenicillin and flucloxacillin 1 g and loaded with IV 1 g phenytoin. His halo was removed and replaced with an Aspen collar. Wound swabs were all negative and 2 sets of blood cultures revealed no other evidence of infection. Over the next 15 days, he experienced a further 2 seizures that terminated with benzodiazepines. Given the intercurrent infection and operative risks associated with his diabetes and splenectomy, it was decided to continue immobilization in a Lurman noninvasive halo system.

Once his antiepileptic medication levels had stabilized he was allowed to go home.

At 6-month follow-up, he had been seizure free since his admission, and was neurologically intact, ambulatory, and continent. A CT scan demonstrated bony union of his odontoid peg fracture, and the pinless halo system was no longer required.

## Discussion

Halo vests are frequently used in the management of subaxial cervical spine fractures but they may be associated with a variety of complications.<sup>1,2</sup> Cranial penetration of the halo pins, although rare,<sup>6</sup> is a serious complication, which is preventable.

The pins used in halo devices require tightening owing to physiological osteolysis around the tip of the pin.<sup>6</sup> Late loosening is typical of pin site infection, and the significance of this must be stressed to the patient.

This case serves as a reminder to consider intracranial complications—seizure in this instance—as a cause of new peripheral neurological signs in patients with a halo device. Of further interest in this case is the cause of the recurrent pin loosening in this patient. One possibility is that they had become infected. There were numerous risk factors for this; the patient had both undergone splenectomy and was diabetic. Classically, splenectomy increases risk of infection by encapsulated pathogens; namely *Haemophilus influenzae*, *Neisseria meningitidis*, *Streptococcus pneumoniae*, and group B *Streptococcus*.<sup>9</sup> Diabetes has long been a known risk factor for the development of cellulitis. Did the patient's immunosuppression contribute to pin loosening? This raises the question if immunosuppressed patients should receive more frequent observation when they have halo systems fitted.

The alternative would be due to decreased bone density—we feel more likely in this instance given all microbiological swabs and cultures were negative, and there was no evidence of bony destruction on the CT scan. Diabetes and chronic

pancreatitis are both risk factors for the development of osteoporosis.<sup>10,11</sup> Medhkour et al.<sup>12</sup> highlights the importance of recognizing poor bone density as a risk factor for pin site loosening and intracranial penetration of halo pins. It should be important therefore to recognize those at risk for the condition, arrange appropriate further tests, and keep more careful observation on this patient group.

## Conclusion

Proper patient education is an essential part of treatment with a halo vest. The aims are to increase awareness and responsiveness to minor complications to avert their potentially catastrophic consequences. Specific advice should be given with regard to tightening the pins without medical guidance. Patients with immunosuppression may be at higher risk of halo-related complications. Osteoporosis may also increase the patients' risk of pin site loosening and intracranial penetration of halo pins. Recognizing these patient groups and remaining vigilant against these complications is therefore recommended.

## References

1. Glaser JA, Whitehill R, Stamp WG, Jane JA. Complications associated with the halo-vest. A review of 245 cases. *J Neurosurg* 1986;65(6):762–9.
2. Strohm PC, Muller CHA, Kostler W, Reising K, Sudkamp NP. Halo-fixator vest—indications and complications. *Zentralbl Chir* 2007;132(1):54–9.
3. Nottmeier EW, Bondurant CP. Delayed onset of generalized tonic-clonic seizures as a complication of halo orthosis. Case report. *J Neurosurg* 2000;92(2 Suppl):233–5.
4. Papagelopoulos PJ, Sapkas GS, Kateros KT, Papadakis SA, Vlamis ME, Falagas ME. Halo pin intracranial penetration and epidural abscess in a patient with a previous cranioplasty: Case report and review of the literature. *Spine* 2001;26(19):E463–7.
5. Gelalis ID, Christoforou G, Motsis E, Arnaoutoglou C, Xenakis T. Brain abscess and generalized seizure caused by halo pin intracranial penetration: Case report and review of the literature. *Eur Spine J* 2009;18(2 Suppl):172–5.
6. Kingma R, Peters JM, Coene LN. Intracranial penetration of a halo pin causing an epileptic seizure. *J Bone Joint Surg Br* 2006;88(12):1654–5.
7. Male KR, Guha A, James S, Ahuja S. Intracranial halo pin penetration causing brain injury secondary to poor halo care technique: A case report and literature review. *Cases J* 2008;1(1):380.
8. Hashimoto Y, Doita M, Hasuda K, Korosue K. Intracerebral pneumocephalus and hemiparesis as a complication of a halo vest in a patient with multiple myeloma. Case report. *J Neurosurg* 2004;100(4 Suppl Spine):367–71.
9. Jirillo E, Mastronardi ML, Altamura M, et al. The immunocompromised host: Immune alterations in splenectomized patients and clinical implications. *Curr Pharm Des* 2003;9(24):1918–23.
10. Duggan SN, O'Sullivan M, Hamilton S, Feehan SM, Ridgway PF, Conlon KC. Patients with chronic pancreatitis are at increased risk for osteoporosis. *Pancreas* 2012;41(7):1119–24.
11. Xia J, Zhong Y, Huang G, Chen Y, Shi H, Zhang Z. The relationship between insulin resistance and osteoporosis in elderly male type 2 diabetes mellitus and diabetic nephropathy. *Ann Endocrinol* 2012;73(6):546–51.
12. Medhkour A, Massie L, Horn M. Acute subdural hematoma following halo pin tightening in a patient with bilateral vertebral artery dissection. *NeuroChirurgie* 2012;58(6):386–90.