

## Endoscopic Foraminal Decompression for Failed Back Surgery Syndrome under local Anesthesia

Anthony Yeung and Satishchandra Gore

*Int J Spine Surg* 2014, 8 ()

doi: <https://doi.org/10.14444/1022>

<https://www.ijssurgery.com/content/8/22>

This information is current as of May 17, 2025.

---

**Email Alerts** Receive free email-alerts when new articles cite this article. Sign up at:  
<http://ijssurgery.com/alerts>

INTERNATIONAL  
JOURNAL  
*of*  
SPINE  
SURGERY

This article generously published free of charge by the International Society for the Advancement of Spine Surgery.



INTERNATIONAL  
SOCIETY *for the* ADVANCEMENT *of*  
SPINE SURGERY

# Endoscopic Foraminal Decompression for Failed Back Surgery Syndrome under local Anesthesia

---

Anthony Yeung, MD,<sup>1</sup> Satishchandra Gore, MD<sup>2</sup>

<sup>1</sup>Desert Institute for Spine Care, Phoenix, AZ, USA <sup>2</sup>Prime Surgical Centre, Pune, India

---

## Abstract

### Background

The most common causes of failed back surgery are residual or recurrent herniation, foraminal fibrosis and foraminal stenosis that is ignored, untreated, or undertreated. Residual back ache may also be from facetal causes or denervation and scarring of the paraspinal muscles.<sup>1,2,3,4,5,6</sup> The original surgeon may advise his patient that nothing more can be done on the basis of his opinion that the nerve was visually decompressed by the original surgery, supported by improved post-op imaging and follow-up studies such as EMG and conduction velocity studies. Post-op imaging or electrophysiological assessment may be inadequate to explain all the reasons for residual or recurrent symptoms. Treatment of Failed back surgery by repeat traditional open revision surgery usually incorporates more extensive decompression causing increased instability and back pain, therefore necessitating fusion. The authors, having limited their practice to endoscopic MIS surgery over the last 15-20 years, report on their experience gained during that period to relieve pain by endoscopically visualizing and treating unrecognized causative patho-anatomy in FBSS.<sup>7</sup>

### Methods

Thirty consecutive patients with FBSS presenting with back and leg pain that had supporting imaging diagnosis of lateral stenosis and /or residual / recurrent disc herniation, or whose pain complaint was supported by relief from diagnostic and therapeutic injections (Figure 1), were offered percutaneous transforaminal endoscopic discectomy and foraminoplasty over a repeat open procedure. Each patient sought consultation following a transient successful, partially successful or unsuccessful open translaminal surgical treatment for disc herniation or spinal stenosis. Endoscopic foraminoplasty was also performed to either decompress the bony foramen for foraminal stenosis, or foraminoplasty to allow for endoscopic visual examination of the affected

---

---

traversing and exiting nerve roots in the axilla, also known as the "hidden zone" of Macnab (Figure 2).<sup>8,9</sup> The average follow up time was, average 40 months, minimum 12 months. Outcome data at each visit included Macnab, VAS and ODI.

---

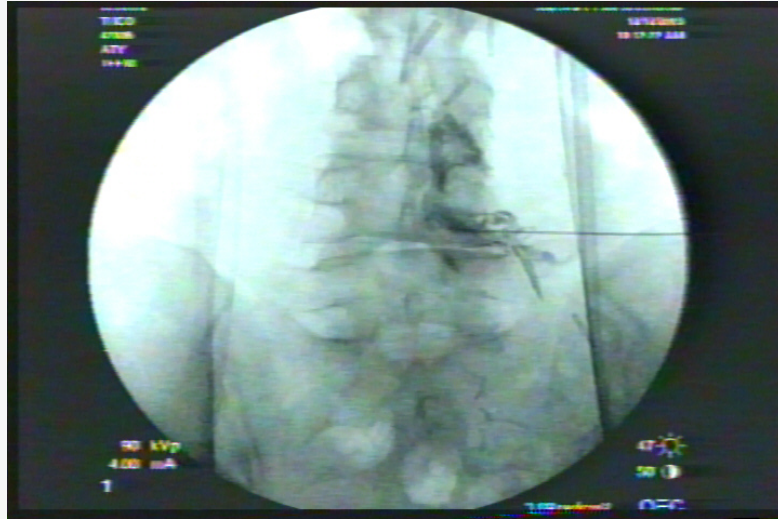


Fig. 1. A diagnostic and therapeutic epidural gram may help identify unrecognized lateral recess stenosis underestimated by MRI. An excellent result from a therapeutic block lends excellent prognosis for a more lasting and “permanent” result from transforaminal endoscopic lateral recess decompression.

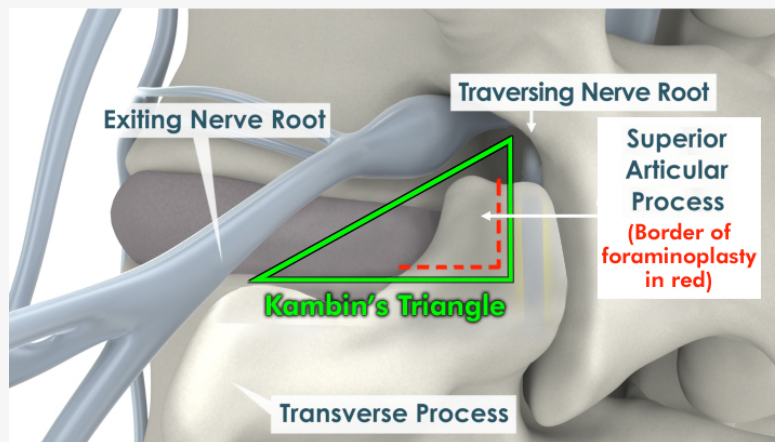


Fig. 2. Kambin's Triangle provides access to the “hidden zone” of Macnab by foraminoplasty. The foramen and lateral recess is decompressed by removing the ventral aspect and tip of the superior articular process to gain access to the axilla between the traversing and exiting nerve. FBSS contains patho-anatomy in the axilla between the traversing and exiting nerve that hides the pain generators of FBSS.

## Results

The average pre-operative VAS improved from 7.2 to 4.0, and ODI 48% to 31%. While temporary dysesthesia occurred in 4 patients in the early post-operative period, all were happy, as all received additional relief of their pre-op symptoms. They were also relieved to be able to avoid "open" decompression or fusion surgery.

---

## Conclusions / Level of Evidence 3

The transforaminal endoscopic approach is effective for FBSS due to residual/recurrent HNP and lateral stenosis. Failed initial index surgery may involve failure to recognize patho-anatomy in the axilla of the foramen housing the traversing and the exiting nerve, including the DRG, which is located cephalad and near the tip of SAP.<sup>10</sup> The transforaminal endoscopic approach effectively decompresses the foramen and does not further destabilize the spine needing stabilization.<sup>11</sup> It also avoids going through the previous surgical site.

## Clinical Relevance

Disc narrowing as a consequence of translaminar discectomy and progressive degenerative narrowing and spondylolisthesis (Figure 3) as a natural history of degenerative disc disease can lead to central and lateral stenosis. The MRI may underestimate the degree of stenosis from a bulging or a foraminal disc protrusion and residual lateral recess stenosis. Pain can be diagnosed and confirmed by evocative discography and by clinical response to transforaminal diagnostic and therapeutic steroid injections.<sup>12</sup> Foraminal endoscopic decompression of the lateral recess is a MIS technique that does not “burn bridges” for a more conventional approach and it adds to the surgical armamentarium of FBSS.

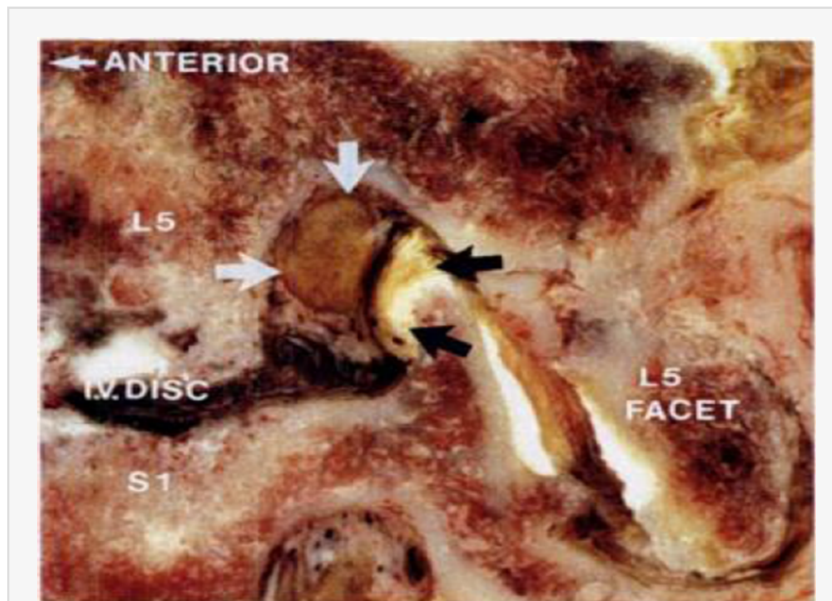


Fig. 3. Cadaver Illustration of Foraminal Stenosis (courtesy of Wolfgang Rauschnig). As the disc narrows, the superior articular process impinges on the exiting nerve and DRG, creating lateral recess stenosis, lumbar spondylosis, and facet arthrosis.

---

**keywords:**

Failed Back Surgery Syndrome(FBSS), Hidden zone, Foraminal decompression, Recurrent herniation, Lateral stenosis, Foraminal osteophyte

Volume 8 Article 22 - Endoscopic & Percutaneous Special Issue doi: 10.14444/1022

# Introduction

The most effective treatment of patients with FBSS depends on a precise and accurate diagnosis of the altered anatomy and physiology. With a careful history, examination, imaging studies, psychological evaluation and diagnostic injections, a diagnosis can be reached in over 90% of patients. More precise methods including pain blocks may be needed to answer where is the pain coming from and why is it persisting?

The most common diagnoses are foraminal stenosis (25% to 29%), painful disc (20% to 22%), pseudarthrosis (14%), neuropathic pain (10%), recurrent disc herniation (7% to 12%), facet joint pain (3%) and sacroiliac joint (SIJ) pain (2%). Psychological factors present in patients and may help or hinder. Common psychological diagnoses include depression, anxiety disorder and substance abuse disorder. Diagnostic injections are very useful for facet joint pain, SIJ pain and discogenic pain; they may also be used to confirm these anatomic structures as a cause of pain.<sup>3</sup>

The diagnoses may be confirmed with diagnostic procedures such as intra-articular injections, medial branch blocks, or transforaminal foraminal and nerve root blocks. Once an etiology is determined, a multidisciplinary approach to treatment is most effective.<sup>13</sup>we should use specific diagnostic tests, e.g., nerve blocks or facet injections, in an effort to localize specific sources of pain; recognize that prognosis is adversely affected by a shotgun approach to additional surgery; and so avoid "exploratory" operations.

The challenge of failed back surgery is in the decision of when to operate and how to do it competently. Repeat interlaminar approach may have several limitations. One source of failure in first surgery is a "battered root syndrome" and arachnoiditis, which may follow limited or inadequate interlaminar exposure. Even with adequate interlaminar exposure, hemostasis may be difficult if preoperative positioning of the patient to diminish intra-abdominal pressure has not been performed. Bleeding can obscure the operative field and the surgeon's ability to visualize and deal with the problem at hand.<sup>2</sup>

In one study of 178 patients who had undergone laminectomies 2-5 years earlier, 14 patients with good recovery and 21 patients with poor recovery but no evidence of restenosis on computed tomography were selected by the Oswestry index. According to radiologic, neurophysiologic, and muscle biopsy evidence most patients (13 of 15 studied) suffering from the severe postoperative failed back syndrome had dorsal ramus lesions in one or more segments covered by the scar, and local paraspinal muscle atrophy at the corresponding segments. Disturbed back muscle innervation and loss of muscular support leads to the disability and increased biomechanical strain, and might be one important cause to the failed back syndrome. It may be possible to develop operating techniques that save back muscle innervation but still take care of back pain by ablating facet innervation from the branches of the dorsal ramus.<sup>6</sup>

Hypertrophy of the superior facet of the inferior vertebra, resulting in a compression of the nerve root at the lateral foraminal exit, is a recognized cause of radicular symptoms, particularly in patients in whom previous lumbar spine surgery has failed. These lesions

present with characteristic physical findings and imaging studies that distinguish it from other causes of radiculopathy. We propose a lesion-specific, facet-sparing surgical technique.<sup>10</sup>

## Materials and Methods

The study has 30 consecutive patients with failed back surgeries after a traditional open or micro surgery. All patients elected to avoid fusion, even when it was appropriate, traditional, and recommended by surgical consultants. This included patients who presented with stable degenerative or Isthmic grade I spondylolisthesis, but wanted to avoid fusion. The grade 0-1 spondylolisthesis was considered by the initial surgeon as minor enough that in his judgment, the patient only required decompression without stabilization. We agreed with the decision to not fuse in the index surgery but felt clinically it required further studies to evaluate the need for stabilization and so performed flexion/ extension xrays on the patients . None of the patients in this study had more than 1-2 mm movement on flexion/ extension films.

All procedures were performed at an ambulatory surgical center associated with the spine group's practice setting, whose surgeons are all experienced in the transforaminal endoscopic decompressive approach. Endoscopic decompression was through the transforaminal endoscopic visualized approach.

The senior author reports on his group's experience, specific to Failed Back Surgery Syndrome (FBSS). An Independent Research Fellow, (YZ) evaluated the clinical outcome of 30 consecutive patients with FBSS in 2011 who underwent Selective Endoscopic Discectomy and foraminoplasty in our group practice. Retrospective outcome data collected included modified MacNab, VAS and ODI. Data was collected at the initial office visit, preoperative and postoperative visits, and final follow up. The average follow up time in the study period was, minimum 12 months, average 30 months. Levels in 30 patients involved were L3-4=5, L4-5=14, L5-S1=11. Surgical videos in every case were studied, demonstrating patho-anatomy between the traversing and exiting nerve in the "hidden zone" correlating well with residual pain. Unrecognized foraminal stenosis, foraminal osteophytes not apparent on MRI, compressive foraminal fibrosis, anomalous nerves, and the ingrowth of sinu-vertebral nerves through annular tears were seen. Compressive patho-anatomy such as incidental pedunculated cysts found in the foramen were also identified and surgically removed by endoscopic foraminal decompression. Videos of every surgery document compressive patho-anatomy in the foramen and around the DRG that was shown treatable by foraminal decompression, excision, ablation, and irrigation of the patho-anatomy.

We are highlighting access to medial branch of dorsal ramus for back pain relief, to the axilla of the nerve roots "hidden zone" and to lateral canal stenosis due to SAP to relieve radicular pain.

## Results

In the 30 Cases of recurrent disc herniation and /or foraminal stenosis, average VAS was 6.2, and ODI 43%. Improvement was 4.4 (6.2-1.8) and 33% respectively. Complications included dysesthesia in 4 patients within the 2 week postoperative period. Dysesthesia



resolved spontaneously in 3 patients within 2 months. One patient with moderate dysesthesia took 4 months for resolution. Three patients ultimately underwent fusion as a delayed staged procedure for residual back pain subsequent to second HNP decompression.

Patient satisfaction was still high. All were satisfied with their initial decision to avoid "open" surgery as they had pain relief. Three patients subsequently accepted and received fusion for residual back pain as a staged procedure when offered the deferred option. None were worse following endoscopic transforaminal decompression. Clinical resolution or improvement of pre-op pain was the usual result.

## Discussion

After initial recognition of spinal stenosis in 1802, a gradual understanding evolved over the next 150 years. Harris and Macnab described the importance of disc degeneration in the pathogenesis of stenosis. MacNab highlighted the lateral recess beneath the posterior facet joint. Lateral canal stenosis (Figure 4) is most often missed or undertreated in traditional surgeries.<sup>8,9</sup>

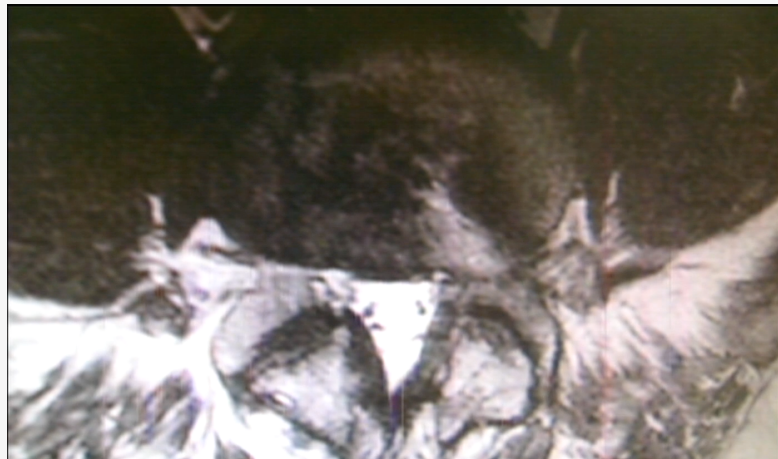

Fig. 4. MRI of FBSS following two open decompressions from midline and Wiltse approach. Patient had residual symptoms of numbness from persistent lateral stenosis.

The nerve-root canal is the semi-tubular structure through which the nerve root runs from the thecal sac to the intervertebral foramen. The proximal part of the canal, also called the subarticular or intervertebral portion, is limited anteriorly by the intervertebral disc and posterolaterally by the superior articular process and the facet joint. The distal part of the canal corresponds to the lateral recess, i.e., the lateral corner of the vertebral foramen at the level of the pedicle. The entrance and exit of the intervertebral foramen lie at the medial and lateral borders of the pedicle. Bony hypertrophy of the inferior articular process may cause narrowing of only the central portion of the spinal canal. The superior articular process contributes to the deformation of the central portion of the canal as well as the medial, sub articular, and lateral portions of the nerve-root canal. From our endoscopic decompression experience of the lateral recess, the SAP contributes frequently to residual unrecognized stenosis in many cases of failed surgery. Bony or ligamentous hypertrophy of the superior articular process produces narrowing of the

intervertebral foramen, but additional disc protrusion of any degree or region of herniation, including a flatulent annulus, will also affect the nerves in the thecal sac and foramen.

Lee and Rauschnig<sup>14</sup> have described how progressive degenerative processes affect the dorsal root ganglion, the mini brain of the nerve, and how it is affected by the disc, facet, synovium of the facet, and osteophytes in the foramen.

The anatomical description of the spinal nerve root pathway, however, is not yet clinically definitive because surgeons do not see the intricacies of the microanatomy during traditional open or even microscopically guided decompression. Burton also divided the nerve root canal into three portions separated by the pedicle in the cross-sectional plane, namely central, foraminal, and extraforaminal. This classification allows easy imaging diagnosis. Lee et al.<sup>14</sup> classified the lateral lumbar spinal canal into three zones: entrance, mild, and exit. This defined the anatomical boundaries of these zones and served as the basis for techniques of surgical decompression when clinically required.

Lumbar spinal foraminal stenosis is an important pathologic entity to recognize in patients with residual radicular symptoms. On MRI imaging, Wildermuth et al.<sup>15</sup> introduced a partially quantitative classification system for grading lumbar spinal foraminal stenosis. They focused on the degree of epidural fat obliteration but did not consider direct nerve root compression or deformity. Recently, Lee et al.<sup>16</sup> reported a new grading system for lumbar spinal foraminal stenosis. They considered the type of stenosis, the amount of fat obliteration, and also the presence of nerve root compression. Yeung and Gore have described the patho-anatomy of stenosis as seen from the foramen endoscopically. The absence of fat, vascular pulsation, scarred and fibrotic nerve roots in the axilla between the traversing and exiting nerves served as a the "hidden zone" of pathology, (Figure 5, Figure 6) and correlated well with for unrecognized symptomatic stenosis.<sup>7</sup>

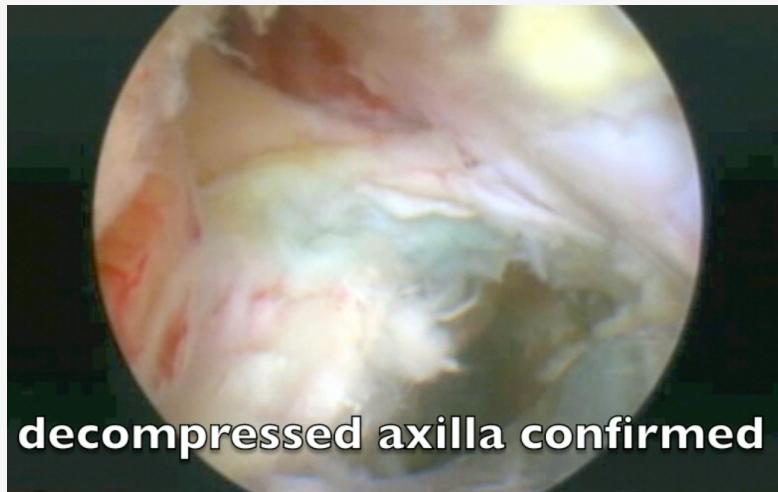


Fig. 5. The axilla between the traversing and exiting nerve is the location of missed patho-anatomy in FBSS. Image of a completely decompressed axilla will allow the surgeon to see that both exiting and traversing nerve are decompressed, and FBSS from patho-anatomy in this zone known as the "hidden zone," when decompressed, will resolve FBSS from residual/recurrent HNP and lateral recess stenosis.

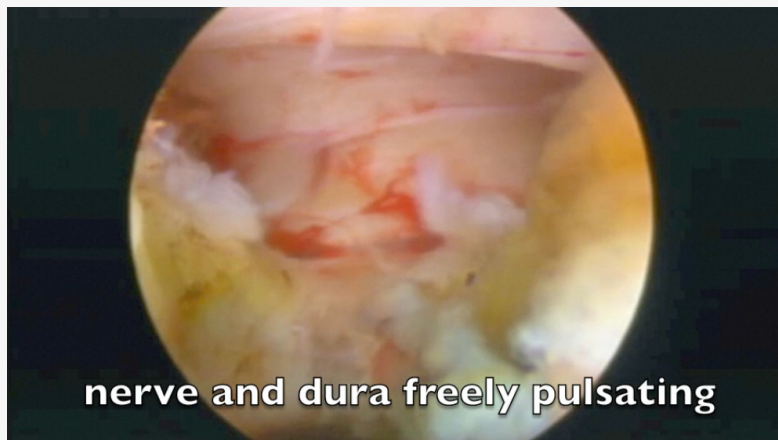

Fig. 6. View after extensive decompressing the ventral SAP after FBSS. Although medial translaminar decompression provides good access to the medial epidural space and the traversing nerve, further decompression through a transforaminal approach is sometimes, needed. Here transforaminal decompression confirms complete decompression of the nerve and the dura above, in a patient with residual sciatica following traditional decompression, but improving the patient further with by decompressing the lateral recess further to expose the lateral aspect of the foramen. A calcified annulus was also found. The medial capsule and ligamentum flavum usually protects the lateral edge of the traversing nerve and dura. Here, it was lifted up to visualize the nerve in the epidural space.

Endoscopic foraminoplasty was performed to either decompress the bony foramen for foraminal stenosis, or foraminoplasty to allow for endoscopic visual confirmation of the decompressed traversing and exiting nerve in recurrent / residual HNP. The annulus was

often just flatulent, bulging with loading and unloading of the lumbar segment, thus contributing to foraminal compression. Nerves in the foramen not seen branching from the exiting nerve were discovered to be from the dorsal ramus, and they were at least 1-2 mm in diameter, not painful to palpation, and did not cause postop dysesthesia when transected. These nerves travel along the foraminal ligament under the superior articular process, and brought axial back pain relief when ablated. Ablation of larger foraminal nerves, however, can be responsible for postop dysesthesia. We have not been able to ascertain at this time the cause of postop dysesthesia as it can happen even when these nerves are left alone. We advise the patient that this is a risk that cannot be eliminated. Fortunately, this is usually temporary, and can be mitigated by post-op transforaminal and sympathetic blocks. The axilla, accessed through foraminoplasty, is the area that is under appreciated as a location for patho-anatomy causing FBSS. The patho-anatomy is identified as foraminal stenosis, foraminal osteophytosis, compressive foraminal fibrosis, recurrent or residual HNP, and incidental finding of pedunculated facet cysts, provides clinical information that opens the door for MIS treatment of painful conditions addressing patho-anatomy of FBSS (Figure 7).

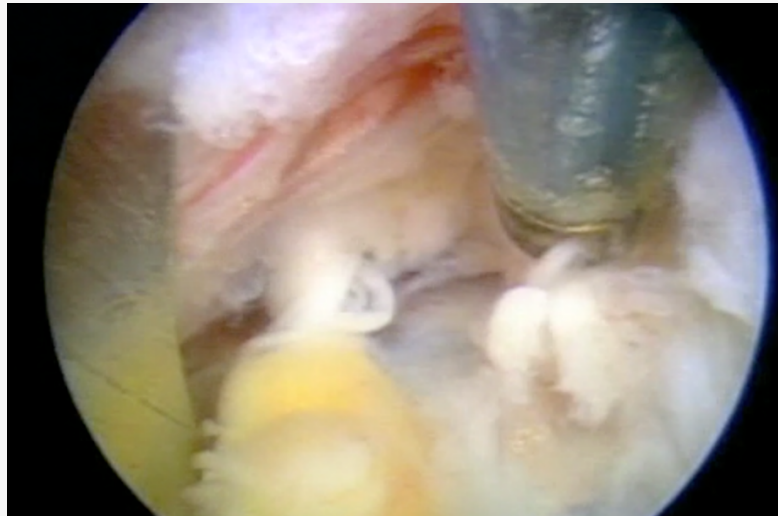


Fig. 7. The axilla contains hidden patho-anatomy such as foraminal disc protrusions, synovial cysts and in this example a rare neuroma of the dorsal ramus is visualized in the in the axilla of the foramen at the L4-5 spinal level. The dorsal ramus is easily mistaken for a furcal nerve.

In a parallel study of dorsal rhizotomy for axial back pain, It was determined that facet pain was also relieved by dorsal endoscopic (visualized) rhizotomy in lieu of fusion (Figure 8). The medial branch of the dorsal ramus, previously thought to be a furcal nerve was discovered to be a branch of the dorsal ramus that can also be ablated at the pedicle before it crosses the transverse process to innervate the disc (Figure 9).<sup>17</sup>

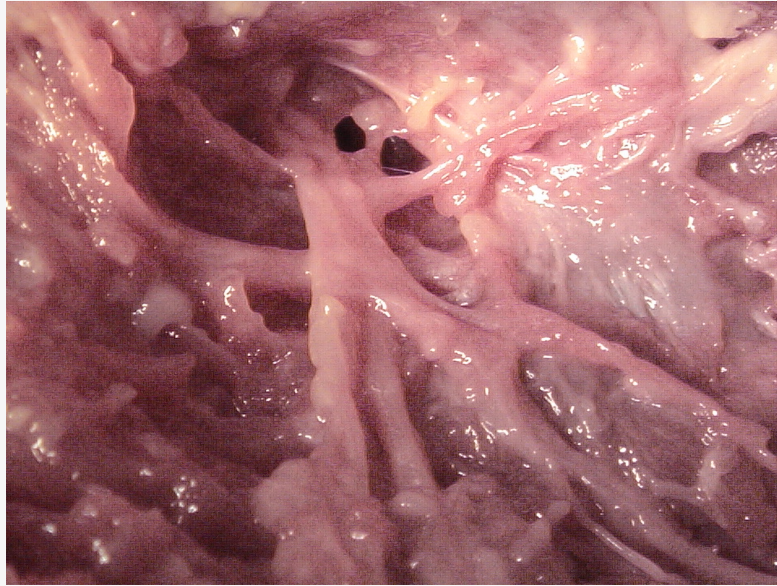


Fig. 8. Cadaver dissection of the Dorsal Ramus and its branches ventral to the intertransverse ligament. One medial branch crosses the transverse process, as does the intermediate and lateral branch. Other branches are demonstrated to reach the facet from the foramen ventral to the intertransverse ligament. Location of the branches is most consistent as described by Bogduk, but various locations and configurations are common.

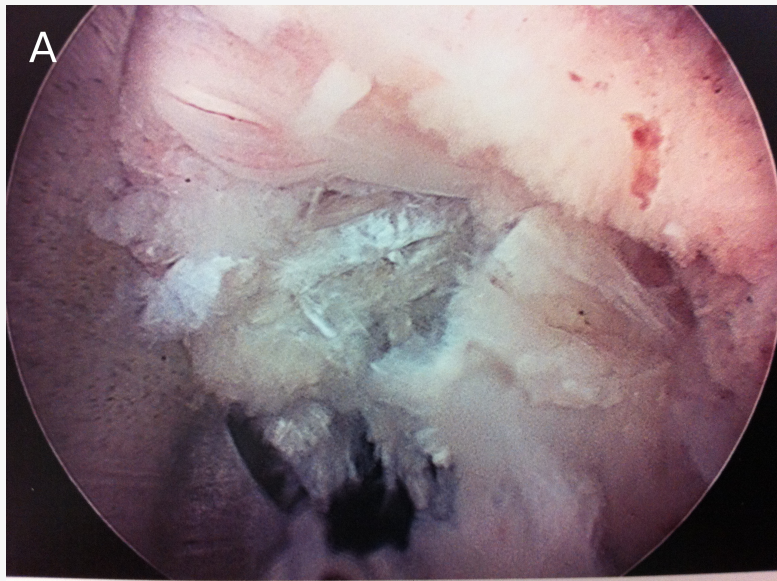


Fig. 9a. Medial branch of the dorsal ramus visualized in the foramen before it exits the foramen to innervate the facet. This is easily mistaken for a furcal nerve. Complete transection or ablation will not produce dysesthesia as it is a pure sensory nerve. Injury or partial ablation of a furcal nerve will produce temporary dysesthesia.

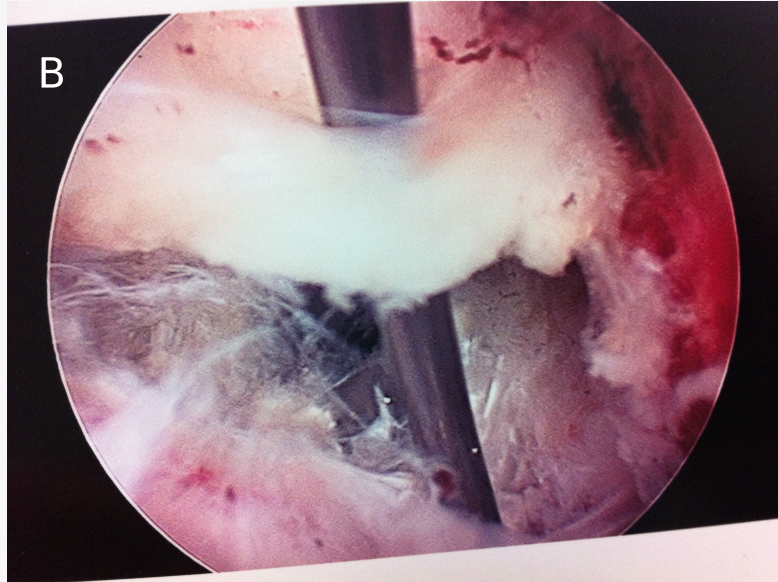
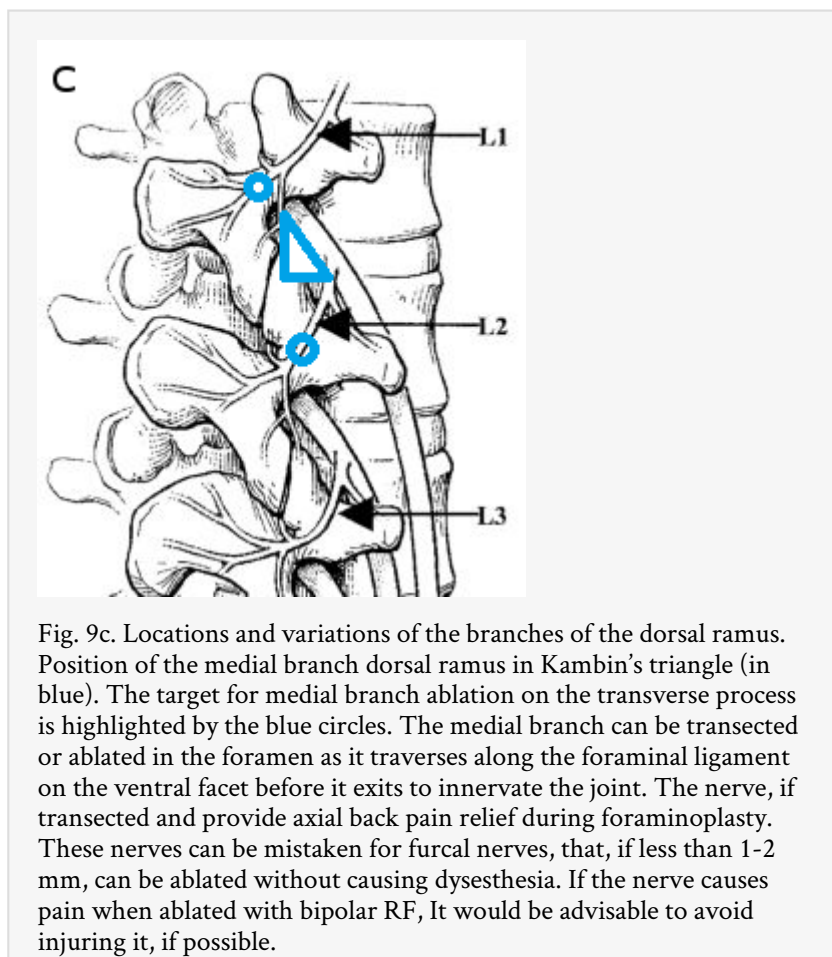


Fig. 9b. Medial branch of dorsal ramus in the foramen vs furcal nerve. It is not always possible to differentiate. If the nerve can be traced branching from a spinal nerve ablating it may cause dysesthesia. Usually very small nerves can be cut. It is better to completely transect that to partially ablate the nerve. The exiting nerve is partially visualized at 7 o'clock.



In the literature, the traditional candidate for initial or primary decompression surgery only is a patient with HNP, severe osteoligamentous compression of the neural structures, severe leg symptoms, mild to moderate neurological deficit and, except for patients with degenerative spondylolisthesis, with little or no back pain.<sup>18,19</sup>

The course of spinal stenosis evolves slowly, and is usually chronic and benign. If this occurs following open spinal decompression, despite a benign natural history, the long term is characterized by slow or moderate deterioration. A randomised study by Amundsen et al compared surgical and conservative treatment with a ten-year follow-up.<sup>20</sup> The outcome was more favorable for surgical treatment, but an initial conservative approach was recommended as late treatment still achieved a good result. This paper provides an alternative transforaminal approach earlier in the degenerative process with an endoscopic transforaminal technique not yet described in peer reviewed pub med cited published literature.

The lateral stenosis is often missed or unable to be adequately decompressed with traditional trans-laminar approaches unless the decompression involves decompression of more than 50% of the medial wall of the facet and both the inferior and superior articular processes. The lateral superior articular process cannot be reached by standard instruments unless the decompression also creates high risk for iatrogenic instability. The transforaminal percutaneous approach provides access for decompression with much less destabilization than open lateral decompression through a midline or even a Wiltse lateral

approach.<sup>11</sup> Because the approach is still dorsal to facet joint, the Wiltse approach is unable to expose all three zones of the axilla for visualization of both the exiting AND traversing nerve without creating some instability.<sup>21</sup> The 30 failed back surgery patients were successfully decompressed transforaminally with combined disc as well as foraminal decompression, decompressing the axilla of the spinal segment. There were no permanent complications, but temporary dysesthesia is a risk of decompressing and irritating the dorsal root ganglion. In this series, 4/30 experienced temporary postop dysesthesia.

Lateral canal stenosis has been actively treated by Knight with use of laser by foraminoplasty and also validated in cases of stable listhesis.<sup>22,23,24,25</sup> Undercutting of the facet has been validated by Hoogland as a part of his outside in access to epidural space for treating lumbar disc herniations.<sup>26</sup>

Contraindications to transforaminal decompression in FBSS are relative, and may be contraindicated with excessive, Grade 2 instability where fusion may be the best viable choice. The surgeon's experience and ability to get to the foramen with enough room for decompression must be assessed. The patient's anatomy, such as an excessively high or narrow iliac crest will limit the ability to enter the foramen at L5S1. In the majority of cases, however, access to the foramen is possible.

We did not perform transforaminal decompression further in the canal towards midline as a recommended procedure in FBSS or in cases where lateral stenosis was the target but if a hard calcified annulus was seen extending to the midline during foraminal decompression, surgery included resection of the visualized annulus until epidural fat was visualized.

The procedure is performed in an outpatient or day-surgery setting. Because of the small incision and minimal internal tissue damage, the rehabilitation period is shorter and scar tissue less. The procedure can be performed in awake patients under local anaesthesia and conscious sedation, avoiding the risk of general anaesthesia, especially for elderly patients with co-morbidities. The ability to probe painful structures in the foramen provides excellent feedback to the operating surgeon and adds to the understanding of treatment of pain generators primarily by decompression of spinal nerves and ablation of pure sensory nerves. Transforaminal endoscopic surgery has a steep learning curve for some, but after the initial learning curve is overcome, this translates into a long and shallow learning curve after the principles of foraminal decompression is mastered. That requires patience and experience, especially for those unfamiliar with percutaneous techniques. The senior author recently experienced his own transforaminal endoscopic surgery performed by his son, Chris Yeung with only local anesthesia and no sedation. The observations discussed in the paper are further validated from personal experience and by expert opinion.

## Complications: Avoidance of irritation of the DRG

The exiting nerve root can be injured. To prevent it, learning curve experience with needle, dilator and cannula placement techniques will mitigate DRG irritation or injury.



In endoscopic surgery through the foraminal approach, a needle can first be placed on the lateral facet or ventral to the facet before entering the disc at the ideal trajectory. Cannula placement technique using specially configured cannulas with a beveled opening can be rotated to avoid and protect the exiting nerve during transforaminal surgery. The facet is then used as a fulcrum to lever the cannula and instruments in the trajectory needed for appropriate decompression. The axilla between the exiting and traversing nerve can then be visualized after foraminoplasty and discectomy. If the patient receives good relief from a foraminal epidural diagnostic and therapeutic steroid injection, it is likely that a blunt obturator can be placed down the path of the needle and the exiting nerve simply gets bluntly nudged out of harm's way by the obturator, using the obturator to dilate the disc space enough to get cannula, in place as a tubular retractor, then a trephine or burr can be utilized to enter the disc and foramen, then to enlarge the foramen in a very collapsed disc to get relief of stenotic symptoms.

The literature suggests many treatment modalities in FBSS.<sup>27,28</sup> The literature seems to suggest that after transforaminal endoscopic surgery 69–83% of the patients experience a satisfactory outcome.<sup>29</sup> In our hands, because we subspecialize in endoscopic foraminal surgery, our experience allows for a success rate of 26/30, or 87%. Satisfaction was very high, even if 13% resulted in mild residuals or a second surgery. The success rate is guided by the patients' response to diagnostic and therapeutic injections performed by the surgeon.

A comprehensive systematic literature review to 2010<sup>29</sup> was made to assess the effectiveness of transforaminal endoscopic surgery in patients with symptomatic lumbar stenosis. Two reviewers independently checked all retrieved titles and abstracts and relevant full text articles for inclusion criteria. Included articles were assessed for quality, and relevant data, including outcomes. The outcomes were extracted by two reviewers independently. No randomized controlled trials were identified in these seven observational studies. The studies were of poor methodological quality and heterogeneous regarding patient selection, indications, operation techniques, follow-up period and outcome measures. The report indicated that overall, 69–83% reported the outcome as satisfactory with a complication rate of 0–8.3%. The reported re-operation rate varied from 0 to 20%. Randomized controlled trials comparing transforaminal endoscopic surgery with other surgical techniques are desired and needed. In our Level 5 expert opinion of this level 3 study, with appropriate "surgeon factor" or giving weight to surgeon experience and technical expertise, high levels results are attainable. The senior author has issued "guarantees" in selected patients who elect to go outside insurance plans to seek the care they desire. There are plans to bring this technique to university training centers where their techniques can be studied and brought gradually to the mainstream MIS surgery, as more MIS endoscopic surgeons are trained.

## Conclusion

The transforaminal approach to the foramen can offer treatment of patho-anatomy in FBSS not visible by traditional surgical techniques. Treatment options by decompressing the foramen and addressing the endoscopic path-anatomy in the "hidden zone" may offer an effective and less invasive alternative solutions for treating spinal pain. An endoscopic spine surgeon experienced with transforaminal access spine surgery, operating only under

local anesthetic, additionally facilitates recognizing and evaluating nerves in the foramen serving as the mediator of pain from the facets in the axial spine. Visualised ablation of these nerves is effective in decreasing axial back pain component of FBSS during "endoscopic foraminoplasty and rhizotomy."

## References

1. Burton CV, Kirkaldy-Willis WH, Yong-Hing K, Heithoff KB Clin Orthop Relat Res. 1981 Jun;(157):191-9. Causes of failure of surgery on the lumbar spine.
2. Pheasant HC, Dyck P. Clin Orthop Relat Res. 1982 Apr;(164):93-109. Failed lumbar disc surgery: cause, assessment, treatment.
3. Schofferman JI, Reynolds J, Herzog R, Covington E, Dreyfuss P, O'Neill C. Spine J. 2003 Sep-Oct;3(5):400-3. Failed back surgery: etiology and diagnostic evaluation
4. Waguespack AI, Schofferman J, Slosar P, Reynolds J Pain Med. 2002 Mar;3(1):18-22. Etiology of long-term failures of lumbar spine surgery.
5. Guyer RD, Patterson M, Ohnmeiss DD J Am Acad Orthop Surg. 2006 Sep;14(9):534-43. Failed back surgery syndrome: diagnostic evaluation..
6. Sihvonen T1, Herno A, Paljärvi L, Airaksinen O, Partanen J, Tapaninaho A. Spine (Phila Pa 1976). 1993 Apr;18(5):575-81. Local denervation atrophy of paraspinal muscles in postoperative failed back syndrome.
7. Yeung AT, Gore S. In-vivo Endoscopic Visualization of Patho-anatomy in Symptomatic Degenerative Conditions of the Lumbar Spine II: Intradiscal, Foraminal, and Central Canal Decompression. Surg Technol Int. 2011 Dec 1;XXI:299-319.
8. Harris RI, Macnab I. Structural changes in the lumbar intervertebral discs; their relationship to low back pain and sciatica. J Bone Joint Surg [Br] 1954;36-B:304-22.
9. Macnab I. Negative disc exploration: an analysis of the causes of nerve-root involvement in sixty-eight patients. J Bone Joint Surg [Am] 1971;53-A:891-903.
10. Maher CO1, Henderson FC. J Neurosurg. 1999 Jan;90(1 Suppl):52-8. Lateral exit-zone stenosis and lumbar radiculopathy.
11. Osman SG1, Nibu K, Panjabi MM, Marsolais EB, Chaudhary R. Spine (Phila Pa 1976). 1997 Aug 1;22(15):1690-5. Transforaminal and posterior decompressions of the lumbar spine. A comparative study of stability and intervertebral foramen area.
12. Riew, et al.: The effect of nerve-root injections (SNRB) on the need for operative treatment of lumbar radicular pain. J Bone Joint Surg Vol. 82-A, No. 11, November 2000 p1589-1593
13. Hussain AI, Erdek M Interventional pain management for failed back surgery syndrome. Pain Pract. 2014 Jan;14(1):64-78. doi: 10.1111/papr.12035. Epub 2013 Feb 3.
14. Lee CK, Rauschnig W, Glenn W (1988) Lateral lumbar spinal canal stenosis: classification, pathologic anatomy and surgical decompression. Spine 13:313-320
15. Wildermuth S, Zanetti M, Duewell S, et al. Lumbar spine: quantitative and qualitative assessment of positional (upright flexion and extension) MR imaging and myelography. Radiology 1998;207:391-98
16. Lee S, Lee JW, Yeon JS, et al. A practical MRI grading system for lumbar foraminal stenosis. AJR Am J Roentgenol 2010;194:1095-98
17. Yeung, A "Endoscopic medial branch and dorsal ramus rhizotomy for chronic Axial back pain: a Pilot Study" International 25th Jubilee Course on Percutaneous

Endoscopic Spine surgery and Complementary Techniques." Zurich Switzerland  
January 24-25, 2007

18. Burton CV (1988) Cauthen JC (eds) Lumbar nerve entrapment: central, foraminal, and extra foraminal zones. Lumbar spine surgery: indications, techniques, failures and alternatives. Williams & Wilkins, Baltimore, pp 202-207
19. FRANCO POSTACCHINI MANAGEMENT OF LUMBAR SPINAL STENOSIS INSTRUCTIONAL COURSE LECTURE European Instructional Course Lectures Vol. 2, 1995.
20. Amundsen T, Weber H, Nordal HJ, Magnaes B, Abdelnoor M, Lilleas F. Lumbar spinal stenosis: conservative or surgical management?: A prospective 10-year study. Spine (Phila Pa 1976) 2000;25:1424-35; discussion 35-6.
21. Vialle R1, Wicart P, Drain O, Dubousset J, Court C. The Wiltse paraspinous approach to the lumbar spine revisited: an anatomic study. Clin Orthop Relat Res. 2006 Apr;445:175-80.
22. Knight M, Goswami A, Patko JT (1999) Endoscopic laser foraminoplasty and a aware-state surgery: a treatment concept and 2-year outcome analyses. Arthroscopie 12:62-73
23. Knight MT, Ellison DR, Goswami A et al (2001) Review of safety in endoscopic laser foraminoplasty for the management of back pain. J Clin Laser Med Surg 19:147-157 29.
24. Knight MT, Vajda A, Jakab GV et al (1998) Endoscopic laser foraminoplasty on the lumbar spine—early experience. Minim Invasive Neurosurg 41:5-9
25. Knight MT, Goswami A, Patko JT et al (2001) Endoscopic foraminoplasty: a prospective study on 250 consecutive patients with independent evaluation. J Clin Laser Med Surg 19:73-81E
26. Hoogland T (2003) Transforaminal endoscopic discectomy with foraminoplasty for lumbar disc herniation. Surg Tech Orthop 1-6
27. Mavrocordatos P1, Cahana A. Adv Tech Stand Neurosurg. 2006;31:221-52. Minimally invasive procedures for the treatment of failed back surgery syndrome.
28. Hayek SM, Helm S, Benyamin RM, Singh V, Bryce DA, Smith HS. Pain Physician. 2009 Mar-Apr;12(2):419-35. Effectiveness of spinal endoscopic adhesiolysis in post lumbar surgery syndrome: a systematic review.
29. Jorm Nellensteijn Ronald Bartels Maurits van Tulder Raymond Ostelo Wilco Peul Barend van Royen "Transforaminal endoscopic surgery for lumbar stenosis: a systematic review." Eur Spine J (2010) 19:879-886 DOI 10.1007/s00586-009-1272-6.

## Disclosures

Dr. Gore is a consultant to Karl Storz Germany. Dr. Yeung receives royalties on Wolf products (Rhizotomy Instrument Set, Endoscope System).

## Corresponding Author

Dr. Anthony Yeung, 1635 E Myrtle Ave, Suite 400, Phoenix, AZ 85020; email: ayeung@sciatica.com.

Copyright © 2014 ISASS - International Society for the Advancement of Spine Surgery. To see more or order reprints or permissions, see <http://ijssurgery.com>.