

Radius of Curvature in Patient-Specific Short Rod Constructs Versus Standard Pre-Bent Rods

Katherine Branche, Rahwa Netsanet, Andriy Noshchenko, Evalina Burger, Vikas Patel, David Ou-Yang and Christopher J. Kleck

Int J Spine Surg published online 29 December 2020
<https://www.ijssurgery.com/content/early/2020/12/17/7143>

This information is current as of May 6, 2025.

Email Alerts Receive free email-alerts when new articles cite this article. Sign up at:
<http://ijssurgery.com/alerts>

Radius of Curvature in Patient-Specific Short Rod Constructs Versus Standard Pre-Bent Rods

KATHERINE BRANCHE, BS, RAHWA NETSANET, BS, ANDRIY NOSHCHENKO, PhD, EVALINA BURGER, MD, VIKAS PATEL, MD, DAVID OU-YANG, MD, CHRISTOPHER J. KLECK, MD

Department of Orthopedics, University of Colorado, Anschutz Medical Campus, Aurora, Colorado

ABSTRACT

Background: Recent studies support the need for sagittal alignment restoration when performing lumbar degenerative spinal fusions. The development of patient-specific spine rods (PSSRs) may help maintain or improve sagittal alignment in these surgeries.

Methods: A retrospective review was conducted for patients who underwent posterior spinal surgeries involving 4 or less levels. The preplanned PSSR radii of curvature (ROC) was compared with standard prebent rods with a ROC of 125 mm. All surgeries were performed at a single institution by 3 surgeons from September 2016 through October 2018. Data were then compared using a 2-tailed paired *t* test. PSSR had either 1 or 2 definitive ROCs.

Results: For rods with 2 ROCs, the “cranial” curve was measured between the upper instrumented level and L4 or L5. The “caudal” curve was measured between L4 or L5 and the lower instrumented level. The PSSR with 1 ROC and the caudal portion of the rods with 2 ROCs were significantly smaller than the industry standard ROC.

Conclusions: PSSR demonstrate more acute ROC than industry standard rods. In PSRs, the most lordosis occurs between L4-S1 and flattens out at the thoracolumbar junction, mimicking the normal distribution of lumbar lordosis. PSSRs could help achieve or maintain sagittal alignment and prevent the sequela of flat back syndrome

Lumbar Spine

Keywords: lumbar lordosis, malalignment, pelvic incidence, pelvic tilt, sagittal balance, degenerative

INTRODUCTION

Lumbar fusion is recognized as an effective means to treat symptoms of degenerative disc disease and spinal instability, including pain resulting from compression of nerves, in patients who have not responded to conservative treatments.¹ The use of pedicle screw and rod constructs in lumbar fusion surgery has been shown to improve immediate postoperative stability and long-term fusion rates.¹ As the techniques and instrumentation continue to develop, research is focusing on sagittal alignment, especially in deformity surgery. Certain parameters, such as sagittal vertical axis and pelvic incidence-lumbar lordosis, have been shown to improve patient outcomes as measured by health-related quality of life scores.^{2–9} These parameters are used in adult deformity surgery; however, the literature is beginning to focus on short-segment constructs, degenerative spine surgery, and its relationship to adjacent segment disease and adult spinal deformity. Specifically, failure through adjacent segment disease and loss of lordosis is a

complication in degenerative lumbar spinal fusions.^{4,6–8,10–12}

Leveque et al¹³ looked at the alignment parameters in degenerative lumbar spinal fusions. Twenty-eight percent of patients were considered malaligned after short segment fusion surgery. Further, 7% of those patients were considered to have appropriate alignment prior to surgery, suggesting surgical intervention caused the malalignment.^{8,13} The results support the implication that alignment preservation, restoration, and improvement should be considered when performing degenerative lumbar spinal fusions.^{8,13} Research into comparative and varying techniques, however, have not shown a significant change in the outcomes,^{1,14} indicating the need for improved methods. Recent studies in spinal deformity patients have shown that patient-specific spine rods (PSSRs) help maintain and improve sagittal alignment.^{2,15}

Although the issues with maintenance of lordosis in lumbar degenerative surgery are multifactorial, the use of precontoured patient-specific rods may contribute to improved lordosis and long-term

Table 1. Specific rods for the 60 patients.

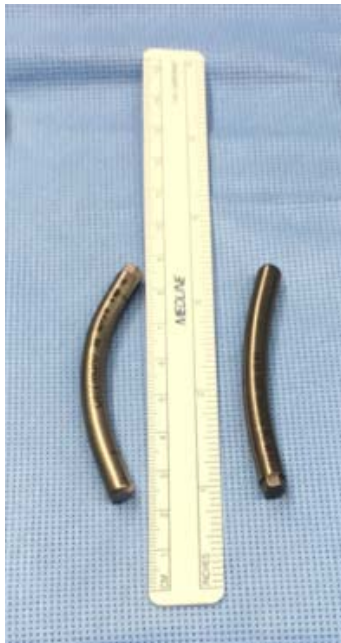	1 ROC	2 ROC
Number of rods	33	27
1 level fused	12	0
2+ levels fused	21	27

Abbreviation: ROC, radii of curvature.

outcomes. The purpose of this study was to compare the radius of curvature of patient-specific rods, prebent for instrumentation based on individual spinopelvic parameters, to the standard rods currently in use (125–135 mm) in a typical implant system.

MATERIALS AND METHODS

Study data were obtained through a retrospective chart review after institutional review board approval (17-2141). The medical records of patients who underwent posterior spinal surgeries involving 4 or less levels, utilizing PSSR (Medicrea, New York, NY) were compared with the standard rod radius of curvature. All surgeries were performed at a single institution by 1 of 3 surgeons from September 2016 through August 2018. Patient data, specifically the cranial and caudal radii of curvatures (ROCs) for each PSSR, were then compared with the industry standard prebent rod radius of 125 mm. Note, 3 level fusion PSSR rods had 2 different ROCs designated as the cranial and caudal radii. For example, in an L4-S1 fusion, the radius of

**Figure 1.** XXXX.**Table 2.** Radius of curvature data for the 60 patients.

	1 ROC	2 ROC
Portion of rod	N/A	Cranial (UIV-L4/L5) Caudal (L4/L5-LIV)
Average curvature, mm	59	105
Standard deviation	23.7	55.9
P value	<.00001	0.1

Abbreviations: LIV, lower instrumented vertebra; N/A, not available; ROC, radii of curvature; UIV, upper instrumented vertebra.

curvature would be different between L4-5 versus L5-S1.

The PSSR was created using standing, preoperative films. The surgical plan was simulated on the image (TLIFs, ALIFs, osteotomies, etc) and a graphical drawing of the rod was placed on the image. The plan focused on lumbar lordosis without fixation to the pelvis and altering pelvic parameters. The rod was then manufactured (Medicrea) to the specifications created by the simulation and shipped for the surgery. The rod is used as a guide to ensure the preoperative surgical plan is met.

The patient was positioned using a Jackson Spine Table (Mizuho OSI® Union City, CA) and sling. The rod was placed in a semiopen technique with no compression across the posterior elements. The ROC was not changed if the instrumentation technique was changed.

STATISTICAL METHODS

The mean values of the caudal and cranial radii were compared with the 125-mm standard rod using a 2-tailed paired *t* test. A *P* < .000001 was found for the rods with 1 ROC and the caudal end for rods with 2 ROCs (Tables 1 and 2).

RESULTS

The PSSRs had either 1 or 2 ROCs. For rods with 2 ROCs, the “Cranial” curve was positioned between the upper instrumented vertebra and L4 or L5. The “Caudal” curve was positioned between L4 or L5 and the lower instrumented vertebra. The PSSRs with 1 radius of curvature and the caudal portion of the rods with 2 ROCs were significantly smaller (more lordotic) than the industry standard radius of curvature. The comparative results between the PSSR and the standard prebent rods is shown in Tables 1 and 2. A total of 60 patients were analyzed. Out of the 60 rods evaluated, 27 had 2 definite curvatures and 33 had 1 curvature.

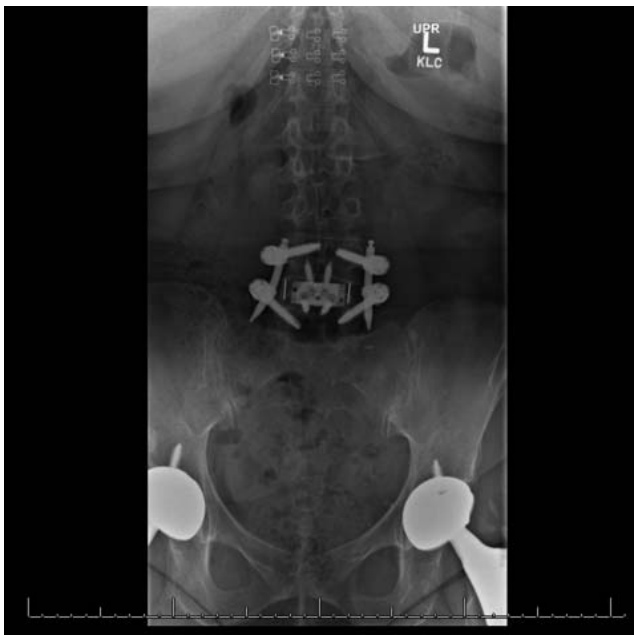

Figure 2. XXXX.

The standard deviation of the caudal curvature of the constructs with 2 ROCs is 28.5 (42% of the average), whereas the standard deviation of the cranial curvature of the constructs with 2 ROCs is 55.9 (53% of the average). The standard deviation of the average curvature of the constructs with 1 radius of curvature is 23.7 (40% of the average).

DISCUSSION

Surgical intervention for degenerative spinal conditions can be an effective treatment, improving patient outcomes. In recent years, the importance of preserving or correcting spinopelvic alignment in degenerative patients undergoing lumbar fusion surgeries has become apparent. There are an increasing number of articles addressing this issue in the current literature. This includes studies referring back to previous literature noting the importance of lumbar lordosis from L4-S1.⁸ With the understanding that lordosis has a great impact on distribution of weight and force, outcomes can be greatly affected by even a small loss of lordosis during surgical intervention. Many studies indicate that an imbalance of the spinopelvic parameters following lumbar fusion can result in higher rates of adjacent segment disease and adjacent segment failure. This in turn can result in recurrence of pain, reoperation, and the need to extend the fusion or undergo deformity correction surgery.¹⁶ Maintaining or correcting sagittal alignment in a short-

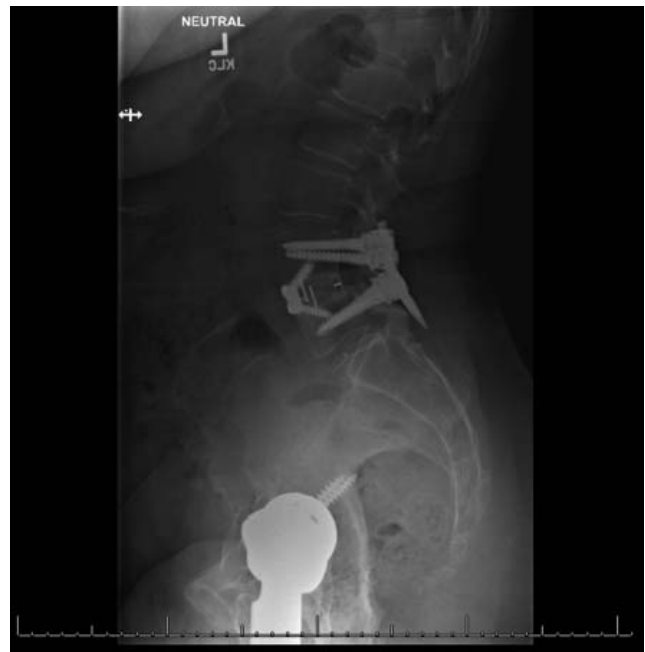

Figure 3. XXXX.

construct fusion may significantly improve patient outcomes. Degeneration and disk height loss in the lumbar spine leads to a loss in sagittal balance. The pathology in itself causes a flat back and thus it is very easy to fuse patients in that incorrect position even when we do not pay attention to the lordosis.^{10,16} Researchers in the past 4 decades have noted the prevalence of iatrogenic complications to lumbar fusions with straight rod instrumentation.^{1,2,7-9,13,17,18} Due to these findings, recent years have shown an increased interest from surgeons to better understand the role of spinopelvic parameters and how they can be used to improve health

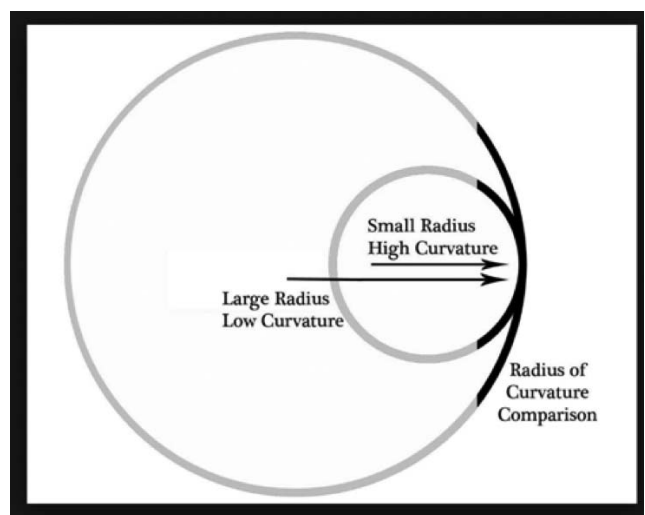


Figure 4. XXXX.

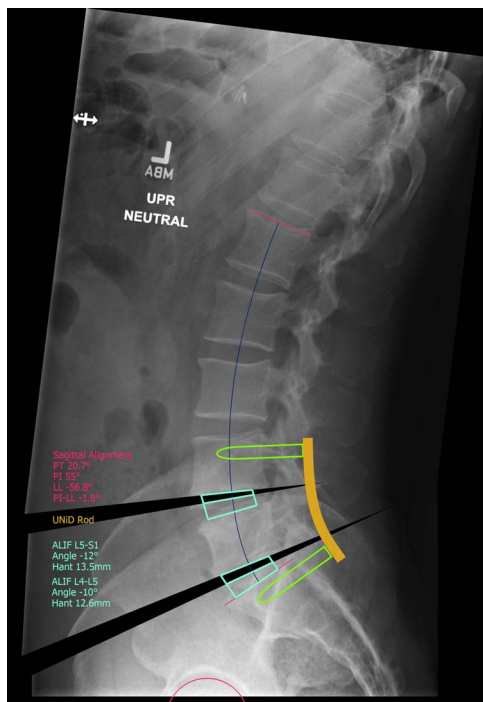


Figure 5. XXXX.

outcomes for patients with degenerative disc conditions who undergo fusion procedures.

These considerations have already been adopted by surgeons when planning for spinal deformity correction, and should be considered for degenerative lumbar spine surgery as well.^{7,13} Glassman et al³ found that restoration or preservation of sagittal alignment is a critical goal for fusion surgery. In their study, it was found to be the most important radiographic predictor of improved clinical outcomes and improved health status. Patients with positive sagittal imbalance reported poorer outcomes such as more pain, worse function, and worse self-image. Sagittal alignment plays a significant role in the success of short-segment lumbar fusion procedures.¹⁹

One of the unintended consequences of standard rods used in lumbar and thoracolumbar spinal fusion is the straightening of the lumbar spine postsurgery.^{12,20} The use of under-bent rods and/or rod flattening leads to a spine fused in a straight position, commonly referred to as “flatback syndrome.” Multiple studies have shown that the most common cause of this phenomenon was iatrogenic, initially due to Harrington rod instrumentation and techniques.^{10,11,19,20} This loss of lordosis was found to result in the acceleration of adjacent segment disease, cause mechanical low back pain, and cause sagittal malalignment. More recent studies have

shown flattening of rods after implantation in spinal deformity patients.²¹ So even if a rod from the standard set is further bent to create greater lordosis, the possibility of an iatrogenic fusion in a flat position may still exist. The smaller radius of curvature in a PSSR maintains and may better match the lumbar curve, potentially improving quality of life outcomes and decreasing the potential for complications.

This study is limited as it is only looking at the rod curvature prior to implantation. Placement of the rod may greatly impact the amount of lordosis seen clinically. Furthermore, the use of interbody devices, the type of approach used, and the use of mono- versus polyaxial screws may have further impact on the lordosis. For example, more research could be done on polyaxial screws and how they affect the lordosis relative to radius of curvature. Polyaxial screws have been shown to have limitations on accommodating a flat rod. Leveque et al¹³ study patients were instrumented with polyaxial screws, and 28% of patients were still considered to be malaligned after surgery, further exemplifying the need to understand the screw’s impact. Further research is being collected to better understand the radiographic and clinical outcomes.

In this study, we looked at the radius of curvature of patient-specific rods and the standard prebent rods (125 mm). Our analysis shows that the patient-specific rods had a significantly smaller radius of curvature than the standard rod. A shorter radius, and therefore a smaller radius of curvature, allows for a more pronounced bend in the rod used to instrument a spinal fusion. The extent the rod is bent is predetermined using a patient’s sagittal alignment parameters prior to surgery. In addition, the radius of curvature varied greatly between the 72 patients. The different curvatures support the use of a patient-specific, small construct rod to help restore or maintain the patient’s sagittal alignment.

CONCLUSIONS

PSSRs demonstrate more acute ROCs than industry standard rods. In PSSRs, the most lordosis occurs between L4-S1 and flattens out at the thoracolumbar junction, mimicking the natural lumbar lordosis in patients undergoing lumbar or thoracolumbar fusion surgeries. PSRs could help achieve or maintain sagittal alignment and prevent the sequela of flat back syndrome.

REFERENCES

1. Qi L, Li M, Zhang S, Xue J, Si H. Comparative effectiveness of PEEK rods versus titanium alloy rods in lumbar fusion: a preliminary report. *Acta Neurochir (Wien)*. 2013;155(7):1187–1193.
2. Barton C, Noshchenko A, Patel V, Kleck C, Burger E. Early experience and initial outcomes with patient-specific spine rods for adult spinal deformity. *Orthopedics*. 2016;39(2):79–86.
3. Glassman SD, Berven S, Bridwell K, Horton W, Dimar JR. Correlation of radiographic parameters and clinical symptoms in adult scoliosis. *Spine (Phila Pa 1976)*. 2005;30(6):682–688.
4. Jang J-S, Lee S-H, Min J-H, Maeng DH. Changes in sagittal alignment after restoration of lower lumbar lordosis in patients with degenerative flat back syndrome. *J Neurosurg Spine*. 2007;7(4):387–392.
5. Schwab FJ, Blondel B, Bess S, et al. Radiographical spinopelvic parameters and disability in the setting of adult spinal deformity: a prospective multicenter analysis. *Spine (Phila Pa 1976)*. 2013;38(13):E803–E812. doi:10.1097/BRS.0b013e318292b7b9.
6. Aoki Y, Nakajima A, Takahashi H, et al. Influence of pelvic incidence-lumbar lordosis mismatch on surgical outcomes of short-segment transforaminal lumbar interbody fusion. *BMC Musculoskelet Disord*. 2015;16:213. doi:10.1186/s12891-015-0676-1.
7. Vazifehdan F, Karantzoulis VG, Igoumenou VG. Sagittal alignment assessment after short-segment lumbar fusion for degenerative disc disease. *Int Orthop*. 2018;43(4):891–898.
8. Barrey C, Roussouly P, Perrin G, Le Huec JC. The importance of restoring the sagittal balance in small and large stabilization procedures of the spine. In: *Surgery of the Spine and Spinal Cord: A Neurosurgical Approach*. 2016.
9. Rothenfluh DA, Mueller DA, Rothenfluh E, Min K. Pelvic incidence-lumbar lordosis mismatch predisposes to adjacent segment disease after lumbar spinal fusion. *Eur Spine J*. 2015;24(6):1251–1258.
10. Lagrone MO, Bradford DS, Moe JH, Lonstein JE, Winter RB, Ogilvie JW. Treatment of symptomatic flatback after spinal fusion. *J Bone Joint Surg Am*. 1988;70(4):569–580.
11. Swank SM, Mauri TM, Brown JC. The lumbar lordosis below Harrington instrumentation for scoliosis. *Spine (Phila Pa 1976)*. 1990;15(3):181–186.
12. Potter BK, Lenke LG, Kuklo TR. Prevention and management of iatrogenic flatback deformity. *J Bone Joint Surg Am*. 2004;86(8):1793–1808.
13. Leveque JCA, Segebarth B, Schroerlucke SR, et al. A multicenter radiographic evaluation of the rates of preoperative and postoperative malalignment in degenerative spinal fusions. *Spine (Phila Pa 1976)*. 2018;43(13):E782–E789. doi:10.1097/BRS.0000000000002500.
14. Galbusera F, Bellini CM, Anasetti F, Ciavarro C, Lovi A, Brayda-Bruno M. Rigid and flexible spinal stabilization devices: a biomechanical comparison. *Med Eng Phys*. 2011;33(4):490–496.
15. Solla F, Barrey CY, Burger E, Kleck CJ, Fièrè V. Patient-specific rods for surgical correction of sagittal imbalance in adults. *Clin Spine Surg*. 2019; 32(2):80–86.
16. Doherty J. Complications of fusion in lumbar scoliosis. *Proc Scoliosis Res Soc*. 1973;55:438–445.
17. Danielsson AJ, Cederlund CG, Ekholm S, Nachemson AL. The prevalence of disc aging and back pain after fusion extending into the lower lumbar spine: a matched MR study twenty-five years after surgery for adolescent idiopathic scoliosis. *Acta Radiol*. 2001;42(2):187–197.
18. Untch C, Liu Q, Hart R. Segmental motion adjacent to an instrumented lumbar fusion: the effect of extension of fusion to the sacrum. *Spine (Phila Pa 1976)*. 2004;29(21):2376–2381.
19. Casey MP, Asher MA, Jacobs RR, Orrick JM. The effect of harrington rod contouring on lumbar lordosis. *Spine (Phila Pa 1976)*. 1987;12(8):750–753.
20. Umehara S, Zindrick MR, Patwardhan AG, et al. The biomechanical effect of postoperative hypolordosis in instrumented lumbar fusion on instrumented and adjacent spinal segments. *Spine (Phila Pa 1976)*. 2000;25(13):1617–1624.
21. Ayers R, Hayne M, Burger E. Spine rod straightening as a possible cause for revision. *J Mater Sci Mater Med*. 2017;28(8):123. doi:10.1007/s10856-017-5935-2

Disclosures and COI: Evalina Burger, David Ou-Yang, and Christopher J. Kleck receive consulting payments from Medicea. The other authors received no funding for this study and report no conflicts of interest.

Corresponding Author: Christopher Kleck, MD, Department of Orthopedics, University of Colorado, Anschutz Medical Campus, 1365 N Aurora Court, Aurora, CO 80045. Phone (303) 724-3496; Fax: (303) 724-1593; Email: christopher.kleck@ucdenver.edu.

Published 0 Month 2020

This manuscript is generously published free of charge by ISASS, the International Society for the Advancement of Spine Surgery. Copyright © 2020 ISASS. To see more or order reprints or permissions, see <http://ijssurgery.com>.