

## Characteristics of Screw Perforation and Screw Loosening in Atlantoaxial Transarticular Fixation Using a Preoperative Computed Tomography-Based Navigation System

Masashi Uehara, Shota Ikegami, Hiroki Oba, Yoshinari Miyaoka, Takayuki Kamanaka, Terue Hatakenaka, Takuma Fukuzawa, Koji Hayashi and Jun Takahashi

*Int J Spine Surg* published online 14 May 2024  
<https://www.ijssurgery.com/content/early/2024/05/13/8604>

This information is current as of May 23, 2025.

---

**Email Alerts** Receive free email-alerts when new articles cite this article. Sign up at:  
<http://ijssurgery.com/alerts>

# Characteristics of Screw Perforation and Screw Loosening in Atlantoaxial Transarticular Fixation Using a Preoperative Computed Tomography-Based Navigation System

MASASHI UEHARA, MD, PhD<sup>1</sup>; SHOTA IKEGAMI, MD, PhD<sup>1</sup>; HIROKI OBA, MD, PhD<sup>1</sup>; YOSHINARI MIYAOKA, MD<sup>1</sup>; TAKAYUKI KAMANAKA, MD, PhD<sup>1</sup>; TERUE HATAKENAKA, MD, PhD<sup>1</sup>; TAKUMA FUKUZAWA, MD<sup>1</sup>; KOJI HAYASHI, MD<sup>1</sup>; AND JUN TAKAHASHI, MD, PhD<sup>1</sup>

<sup>1</sup>Department of Orthopedic Surgery, Shinshu University School of Medicine, Matsumoto, Nagano, Japan

## ABSTRACT

**Background:** Atlantoaxial transarticular fixation, also called the Magerl technique, is said to be the most robust biomechanical method of fixation of the atlantoaxial vertebrae. However, the procedure carries a risk of spinal cord and vertebral artery injury during the insertion process, especially in patients with a high-riding vertebral artery. In this study, a computed tomography (CT)-based navigation system was used for preoperative planning and insertion. This investigation sought to determine the rate and direction of screw perforation as well as the incidence of screw loosening in computer-assisted atlantoaxial transarticular fixation.

**Methods:** Sixty patients (31 men and 29 women; mean  $\pm$  SD age: 65.3  $\pm$  19.6 years) who received atlantoaxial transarticular screw insertion with preoperative CT navigation were analyzed. We investigated screw position and loosening by CT at the final follow-up.

**Results:** Of the 108 screws inserted, the rate of Grade 2 or higher perforation was 4.6% (5/108). Nine of 81 (11.1%) screws inserted into the 44 patients who were followed for at least 6 months showed loosening. Logistic regression analysis revealed that unilateral insertion (odds ratio: 8.50, 95% confidence interval: 1.53–47.2,  $P = 0.014$ ) was significantly associated with the incidence of screw loosening.

**Conclusions:** The screw perforation rate of Grade 2 or higher in computer-assisted atlantoaxial transarticular screw fixation was 4.6%, with comparable frequencies of perforation direction. Unilateral insertion was a significant independent factor associated with screw loosening, which occurred in 11.1% of insertions.

**Clinical Relevance:** Spine surgeons should follow up with patients with caution because screws with unilateral insertion are prone to loosening.

**Level of Evidence:** 4.

Cervical Spine

Keywords: atlantoaxial transarticular screw, screw perforation, screw loosening, navigation

## INTRODUCTION

Posterior atlantoaxial transarticular fixation, also known as the Magerl technique, was first reported by Magerl and Seeman in 1979.<sup>1</sup> Although this procedure is reportedly the most robust biomechanical method of atlantoaxial fixation,<sup>2–4</sup> it also carries a high risk of damaging significant structures, including the vertebral artery (VA), spinal cord, and anatomical variations such as a high-riding VA.<sup>5</sup>

Surgical medicine has undergone tremendous progress owing to a variety of factors,<sup>6</sup> with technique advances widening the scope of spinal surgeries. As normal C1-2 articulations are responsible for approximately 50% of

cervical spine rotation cases,<sup>7</sup> ensuring proper stabilization is an important issue.<sup>8</sup> However, fusion of atlantoaxial joint instability in certain circumstances, such as those involving VA anomalies, ponticulus posticus, or arcuate foramen anomalies, can be challenging to carry out.

Navigation has become widely used to enhance safety in spine surgery, with accuracy improving with the increased use of technology and navigation-based instruments.<sup>9</sup> Accordingly, our group routinely employs a computed tomography (CT)-based navigation system for preoperative planning in atlantoaxial transarticular screw insertion.<sup>10</sup> However, few reports exist on the accuracy of the procedure by preoperative CT-based navigation.

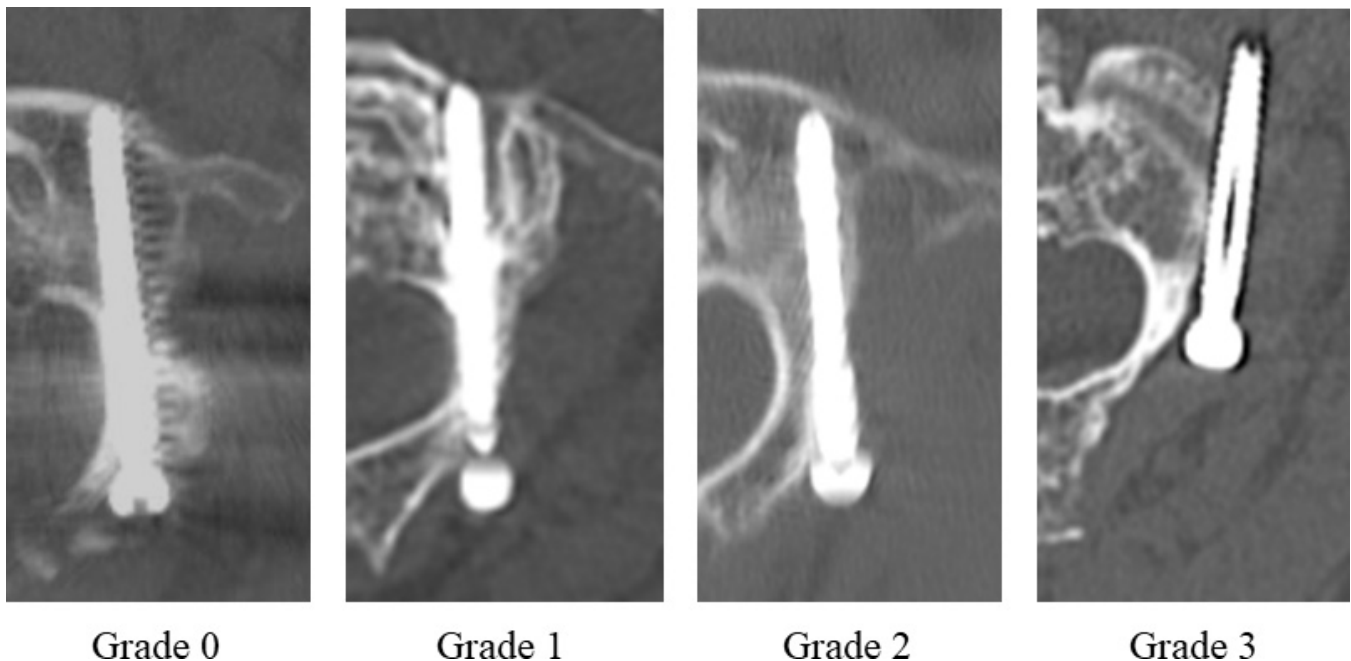
The present study investigated the rate and direction of screw perforation as well as the presence of screw loosening in computer-assisted atlantoaxial transarticular fixation.

## MATERIALS AND METHODS

Sixty patients (31 men and 29 women; mean  $\pm$  SD age:  $65.3 \pm 19.6$  years) undergoing Magerl screw insertion with preoperative CT-based navigation between October 1998 and March 2022 at our University Hospital were analyzed. Lateral fluoroscopy was also used as an adjunct for all cases. Indications included idiopathic atlantoaxial subluxation in 21 cases, trauma in 19 cases, rheumatoid cervical spine in 14 cases, and posterior pseudotumor of the odontoid process and odontoid bone in 3 cases each. The mean follow-up period was  $24.4 \pm 26.0$  (1–96) months. Details of the surgical procedure are presented in a previous study.<sup>10</sup> Briefly, a skin incision is made from the posterior cranial fossa to the third cervical vertebra to prepare the operation field. The reference frame is then positioned at the spinous process of the second cervical vertebra, and registration is carried out. A 3-mm speed drill is used to create an insertion hole at each screw insertion point. Next, a guide pin is inserted under navigation system guidance, and drilling is performed. Finally, an atlantoaxial transarticular screw is inserted under lateral view fluoroscopy. All patients underwent iliac bone grafting using the Brooks or McGraw procedure. In all cases, CT was

performed within 2 weeks postoperative for evaluating screw position. In addition, 44 patients underwent CT 6 months after surgery, at which time we examined patients for screw loosening. We classified screw position as Grade 0 (no perforation), Grade 1 (perforation  $<2$  mm), Grade 2 (perforation  $\geq 2$  but  $<4$  mm), or Grade 3 (perforation  $\geq 4$  mm;<sup>11</sup> (Figure), with the direction of each perforation recorded.

Screw loosening was judged as the appearance of radiolucency around pedicle screws.<sup>12,13</sup> To determine the risk factors of screw loosening, we divided the cohort according to the presence or absence of loosening for multivariate analysis. Logistic regression models were employed to identify factors associated with screw loosening, with the presence of loosening as a response variable and such patient-related factors as age, sex, screw perforation (Grade 3 or Grade 2 or higher), and unilateral screw insertion as explanatory variables. The selection of factors included in the multivariate analysis was performed by stepwise model testing based on the Akaike information criterion. All statistical analyses were conducted using EZR software (Saitama Medical Center, Jichi Medical University, Saitama, Japan), a graphical user interface for R (The Foundation for Statistical Computing, Vienna, Austria). EZR is a modified version of R commander designed to add statistical functions frequently used in biostatistics. The level of significance was set at  $P < 0.05$ .



**Figure.** Screw perforation grading.

**Table 1.** Perforation rates by direction (*N* = 60).

Grade	Perforation Rate, %	Perforation Direction, <i>n</i>			
		Lateral	Medial	Cranial	Caudal
1 or 2 or 3	13.0%	8	3	2	1
2 or 3	4.6%	1	1	2	1
3	0.9%	1	0	0	0

## RESULTS

The mean (SD) operation time was  $186 \pm 65$  (81–383) minutes, and the mean (SD) blood loss volume was  $242 \pm 168$  (20–800) mL. Fifteen of 60 (25%) patients underwent additional laminoplasty, laminectomy, or another level of posterior fusion. A total of 108 screws were inserted, with a Grade 3 perforation rate of 0.9% (1/108) and a Grade 2 or higher perforation rate of 4.6% (5/108). Regarding direction, 1 lateral, 1 medial, 2 cranial, and 1 caudal screw were inserted into patients with Grade 2 or higher perforation (Table 1). One lateral and 1 caudal screw protruded anteriorly into the anterior arch of the atlas. In the 44 patients who were followed for at least 6 months, 9 of 81 (11.1%) screws showed loosening. Seven of the 44 patients received a unilateral atlantoaxial transarticular screw, of which 3 (42.9%) had loosened. All patients who exhibited loosening had no symptoms and did not require reoperation. Logistic regression analysis revealed that unilateral insertion (OR: 8.50, 95% CI: 1.53–47.2,  $P = 0.014$ ) was significantly associated with the incidence of screw loosening, while age (OR: 0.99, 95% CI: 0.95–1.03,  $P = 0.75$ ), gender (OR: 0.67, 95% CI: 0.16–2.73,  $P = 0.58$ ), rheumatoid arthritis (OR: 4.11e-08, 95% CI: 0.00–infinity,  $P = 0.99$ ), and Grade 2 or higher perforation (OR: 1.78e-07, 95% CI: 0.00–infinity,  $P = 0.99$ ) were not. According to multivariate analysis, unilateral insertion was an independent factor associated with screw loosening (OR: 8.25, 95% CI: 1.49–45.8,  $P = 0.015$ ; Table 2).

## DISCUSSION

This study identified the rate and direction of screw perforation as well as the presence of screw loosening

in computer-assisted atlantoaxial transarticular fixation using CT. Of the 108 inserted atlantoaxial transarticular screws, 5 (4.6%) had a Grade 2 or higher perforation, although no VA injury or other serious complications were observed. Screw loosening was detected in 11.1% of screws. Unilateral transarticular screw insertion was a significant independent factor associated with screw loosening.

Posterior atlantoaxial fixation with transarticular screws provides biomechanically strong fixation, with reported fusion rates from 87% to nearly 100%.<sup>14–16</sup> The most serious complication associated with the procedure is VA injury due to inferior or lateral perforation during screw placement.<sup>15,17</sup> Screw insertion into the upper cervical spine is technically difficult, especially in patients with high-riding VA, which increases the risk of complications. High-riding VA ranges between 10.0% and 23% of individuals.<sup>18–21</sup> VA injury rates during atlantoaxial transarticular instrumentation are reportedly 1.3% to 4.1%.<sup>15,16</sup> A meta-analysis of atlantoaxial fusion with transarticular screws estimated a screw deviation rate of 7.1% and a VA injury rate of 3.1%.<sup>22</sup>

Various navigation systems have enhanced the safety and accuracy of spine surgery.<sup>9</sup> Wada et al described that O-arm–assisted transarticular screw fixation eliminated screw deviation and reduced blood loss and operation time compared with C1-2 screw-rod constructs to demonstrate the usefulness of intraoperative navigation.<sup>23</sup> However, the financial outlay required to purchase and maintain such equipment is likely why it has not yet become commonplace in many hospitals.<sup>24</sup> In the present study, using a lower-cost preoperative CT-based navigation system, the transarticular screw deviation rate was relatively low at 4.6%, with no serious complications, making it a good option for transarticular screw insertion as well.

Screw loosening after spinal implant surgery is a complication that leads to bone fusion failure and poor outcomes.<sup>25,26</sup> A study on scoliosis surgery revealed a significant association between screw deviation and screw loosening.<sup>27</sup> The screw loosening rate in our

**Table 2.** Effects of patient-related factors on screw loosening.

Factor	Univariate		Multivariate	
	OR (95% CI)	<i>P</i>	OR (95% CI)	<i>P</i>
Age (+1 y)	0.99 (0.95–1.03)	0.75	-	
Gender (women)	0.67 (0.16–2.73)	0.58	-	
Rheumatoid arthritis	4.11e-08 (0.00–inf)	0.99	-	
Screw perforation (Grade 2 or 3)	1.78e-07 (0.00–inf)	0.99	-	
Unilateral insertion	8.50 (1.53–47.2)	0.014	8.25 (1.49–45.8)	0.015

Abbreviation: inf, infinity.



cohort was 11.1%. Although there was a significant association between unilateral screw insertion and screw loosening, no relationship for screw deviation with screw loosening was found. Since transarticular screws can be relatively long and impart excellent biomechanical stability, their strength may be assured even if the screw perforates slightly. Sutipornpalangkul et al reported 5 cases (22%) having only unilateral transarticular screw fixation but were able to achieve C1-2 biomechanical stability, which was comparable to the results of bilateral transarticular screw fixation.<sup>28</sup> In our series, 7 of 44 patients underwent unilateral fixation. Multivariate analysis revealed unilateral transarticular screw insertion as an independently associated factor for screw loosening, although no revision surgery was needed.

The present study had several limitations, including its small sample size, relatively short follow-up period, and retrospective design. Nevertheless, our analysis of the results of 60 patients, which was a relatively large number for an atlantoaxial fixation cohort, demonstrated the safety and low screw loosening rate of insertion with preoperative CT-based navigation along with identifying an independent associated risk factor in fixation with atlantoaxial transarticular screws. We believe that the fact that this report evaluates not only the frequency of screw deviation but also the frequency of clinically problematic screw loosening and its associated factors offers a novel perspective on this surgical technique.

## CONCLUSION

The screw perforation rate of Grade 2 or higher in computer-assisted atlantoaxial transarticular screw fixation was 4.6%, with a similar frequency of screw perforation in all directions. Unilateral insertion, but not screw perforation, was a significant independent factor associated with screw loosening in atlantoaxial transarticular screw fixation with preoperative CT navigation.

## REFERENCES

1. Magerl F, Seemann PS. Cervical spine I. In: *Stable Posterior Fusion of the Atlas and Axis by Transarticular Screw Fixation*. Vienna: Publisher unknown; 1986:322–327. doi:10.1007/978-3-7091-8882-8
2. Sim HB, Lee JW, Park JT, Mindea SA, Lim J, Park J. Biomechanical evaluations of various C1-C2 posterior fixation techniques. *Spine*. 2011;36(6):E401–E407. doi:10.1097/BRS.0b013e31820611ba
3. Guo X, Ni B, Xie N, Lu X, Guo Q, Lu M. Bilateral C1-C2 transarticular screw and C1 laminar hook fixation and bone graft fusion for reducible atlantoaxial dislocation: a seven-year analysis of outcome. *PLOS ONE*. 2014;9(1):e87676. doi:10.1371/journal.pone.0087676
4. Du JY, Aichmair A, Kueper J, Wright T, Lebl DR. Biomechanical analysis of screw constructs for atlantoaxial fixation in cadavers: a systematic review and meta-analysis. *J Neurosurg Spine*. 2015;22(2):151–161. doi:10.3171/2014.10.SPINE13805
5. Ebraheim NA, Klausner T, Xu R, Yeasting RA. Safe lateral-mass screw lengths in the Roy-Camille and Magerl techniques. *Spine*. 1998;23(16):1739–1742. doi:10.1097/00007632-199808150-00006
6. Kanat A, Tsianaka E, Gasenzer ER, Drosos E. Some interesting points of competition of x-ray using during the Greco-Ottoman war in 1897 and development of neurosurgical radiology: a reminiscence. *Turk Neurosurg*. 2022;32(5):877–881. doi:10.5137/1019-5149.JTN.33484-20.3
7. Kanat A, Aydin Y. Posterior C1-C2 transarticular screw fixation for atlantoaxial arthrodesis. *Neurosurgery*. 1999;44(3):687–689. doi:10.1097/00006123-199903000-00157
8. Kanat A, et al. Reducible nonunited type II odontoid fracture with atlantoaxial instability: outcomes of two different fixation techniques. *Int J Environ Res Public Health*. 2021;19:7990. doi:10.3390/ijerph19095018
9. Butler AJ, Colman MW, Lynch J, Phillips FM. Augmented reality in minimally invasive spine surgery: early efficiency and complications of percutaneous pedicle screw instrumentation. *Spine J*. 2023;23(1):27–33. doi:10.1016/j.spinee.2022.09.008
10. Uehara M, Takahashi J, Hirabayashi H, et al. Computer-assisted C1-C2 transarticular screw fixation "Magerl technique" for atlantoaxial instability. *Asian Spine J*. 2012;6(3):168–177. doi:10.4184/asj.2012.6.3.168
11. Rao G, Brodke DS, Rondina M, Dailey AT. Comparison of computerized tomography and direct visualization in thoracic pedicle screw placement. *J Neurosurg*. 2002;97(2 Suppl):223–226. doi:10.3171/spi.2002.97.2.0223
12. Ohtori S, Inoue G, Orita S, et al. Comparison of teriparatide and bisphosphonate treatment to reduce pedicle screw loosening after lumbar spinal fusion surgery in postmenopausal women with osteoporosis from a bone quality perspective. *Spine*. 2013;38(8):E487–E492. doi:10.1097/BRS.0b013e31828826dd
13. Ozawa T, Takahashi K, Yamagata M, et al. Insertional torque of the lumbar pedicle screw surgery. *J Orthop Sci*. 2005;10(2):133–136. doi:10.1007/s00776-004-0883-3
14. Madawi AA, Casey AT, Solanki GA, Tuite G, Veres R, Crockard HA. Radiological and anatomical evaluation of the atlantoaxial transarticular screw fixation technique. *J Neurosurg*. 1997;86(6):961–968. doi:10.3171/jns.1997.86.6.0961
15. Wright NM, Lauryssen C. Vertebral artery injury in C1-2 transarticular screw fixation: results of a survey of the AANS/CNS section on disorders of the spine and peripheral nerves. *J Neurosurg*. 1998;88(4):634–640. doi:10.3171/jns.1998.88.4.0634
16. Neo M, Fujibayashi S, Miyata M, Takemoto M, Nakamura T. Vertebral artery injury during cervical spine surgery: a survey of more than 5600 operations. *Spine*. 2008;33(7):779–785. doi:10.1097/BRS.0b013e31816957a7
17. Lall R, Patel NJ, Resnick DK. A review of complications associated with craniocervical fusion surgery. *Neurosurgery*. 2010;67(5):1396–1402. doi:10.1227/NEU.0b013e3181f1ec73
18. Kazan S, Yildirim F, Sindel M, Tuncer R. Anatomical evaluation of the groove for the vertebral artery in the axis vertebrae for atlantoaxial transarticular screw fixation technique. *Clin Anat*. 2000;13(4):237–243. doi:10.1002/1098-2353(2000)13:4<237::AID-CA2>3.0.CO;2-K

19. Abou Madawi A, Solanki G, Casey AT, Crockard HA. Variation of the groove in the axis vertebra for the vertebral artery: implications for instrumentation. *J Bone Joint Surg Br.* 1997;79(5):820–823. doi:10.1302/0301-620x.79b5.7566
20. Mandel IM, Kambach BJ, Petersilge CA, Johnstone B, Yoo JU. Morphologic considerations of C2 isthmus dimensions for the placement of transarticular screws. *Spine.* 2000;25(12):1542–1547. doi:10.1097/00007632-200006150-00014
21. Paramore CG, Dickman CA, Sonntag VK. The anatomical suitability of the C1E2 complex for transarticular screw fixation. *J Neurosurg.* 1996;85(2):221–224. doi:10.3171/jns.1996.85.2.0221
22. Elliott RE, Tanweer O, Boah A, et al. Atlantoaxial fusion with transarticular screws: meta-analysis and review of the literature. *World Neurosurg.* 2013;80(5):627–641. doi:10.1016/j.wneu.2012.03.012
23. Wada K, Tamaki R, Inoue T, Hagiwara K, Okazaki K. Comparison of atlantoaxial fusion with transarticular screws and C1 lateral mass-C2 screws using intraoperative O-arm navigation. *World Neurosurgery.* 2020;141:e1005–e1009. doi:10.1016/j.wneu.2020.06.149
24. Lee YC, Lee R. Image-guided pedicle screws using intraoperative cone-beam CT and navigation: a cost-effectiveness study. *J Clin Neurosci.* 2020;72:68–71. doi:10.1016/j.jocn.2020.01.025
25. Berjano P, Bassani R, Casero G, Sinigaglia A, Cecchinato R, Lamartina C. Failures and revisions in surgery for sagittal imbalance: analysis of factors influencing failure. *Eur Spine J.* 2013;22 Suppl 6(Suppl 6):S853–S858. doi:10.1007/s00586-013-3024-x
26. McLain RF, Sparling E, Benson DR. Early failure of short-segment pedicle instrumentation for thoracolumbar fractures. *J Bone Joint Surg Am.* 1993;75(2):162–167. doi:10.2106/00004623-199302000-00002
27. Uehara M, Takahashi J, Ikegami S, et al. Pedicle screw loosening after posterior spinal fusion for adolescent idiopathic scoliosis in upper and lower Instrumented vertebrae having major perforation. *Spine.* 2017;42(24):1895–1900. doi:10.1097/BRS.0000000000002305
28. Sutipornpalangkul W, Thanapitsiri S. Atlantoaxial transarticular screw fixation and posterior fusion using polyester cable: a 10-year experience. *Eur Spine J.* 2013;22(7):1564–1569. doi:10.1007/s00586-013-2789-2

**Disclosures:** The authors have no disclosures related to the content of the present study.

**Corresponding Author:** Masashi Uehara, Department of Orthopaedic Surgery, Shinshu University School of Medicine 3-1-1 Asahi, Matsumoto, Nagano 390-8621, Japan; masashi\_u560613@yahoo.co.jp

This manuscript is generously published free of charge by ISASS, the International Society for the Advancement of Spine Surgery. Copyright © 2024 ISASS. To see more or order reprints or permissions, see <http://ijssurgery.com>.