

## Rotation Preserving Fixation for the Treatment of C1 Burst Fracture Combined With Type II Odontoid Fracture: 2 Case Reports and Literature Review

Hui Tao, Shanzhong Shao, Kun Yang, Chang Liu, Cailiang Shen and Yinshun Zhang

*Int J Spine Surg* published online 23 October 2024  
<https://www.ijssurgery.com/content/early/2024/10/13/8646>

This information is current as of May 29, 2025.

---

**Email Alerts** Receive free email-alerts when new articles cite this article. Sign up at:  
<http://ijssurgery.com/alerts>

# Rotation Preserving Fixation for the Treatment of C1 Burst Fracture Combined With Type II Odontoid Fracture: 2 Case Reports and Literature Review

HUI TAO, MD<sup>1\*</sup>; SHANZHONG SHAO, MD<sup>1\*</sup>; KUN YANG, MD<sup>1</sup>; CHANG LIU, MD<sup>1</sup>; CAILIANG SHEN, MD<sup>1</sup>; AND YINSHUN ZHANG, MD<sup>1</sup>

<sup>1</sup>Department of Orthopedics and Spine Surgery, The First Affiliated Hospital of Anhui Medical University, Hefei, China

\*Hui Tao and Shanzhong Shao contributed equally to the work.

## ABSTRACT

**Objective:** This study aimed to evaluate the clinical feasibility and effectiveness of a monoaxial screw-rod system and anterior screw fixation for C1 and type II odontoid fractures.

**Methods:** We conducted a retrospective review of 2 consecutive patients with acute C1 and Anderson-D'Alonzo type II odontoid fractures. Both patients underwent treatment using a posterior monoaxial screw-rod system and anterior screw fixation. We reviewed their clinical records, including the visual analog pain scale and Neck Disability Index scores, as well as pre- and postoperative radiographs. Additionally, pre- and postoperative computed tomography images were used to classify the fracture types and assess the C1 to C2 reduction, rotation, and instability.

**Results:** Both patients presented with type II C1 and type II B odontoid fractures, combined with Dickman type II transverse atlantal ligament injuries. All surgical procedures were successfully performed without complications such as vertebral artery injury, neurological deficit, esophageal injury, or wound infection. Both patients achieved almost complete bone healing of the fractures, and C1 to C2 rotation was well preserved (32° and 49°) without atlantoaxial instability after follow-ups of 21 and 25 months, respectively.

**Conclusions:** A monoaxial screw-rod system and anterior screw fixation could be promising surgical strategies for C1 fractures combined with type II odontoid fractures, even in cases involving transverse atlantal ligament injuries. The preservation of C1 to C2 rotation without atlantoaxial instability was observed after fixation. However, extensive case-finding and long-term follow-up are needed to understand the effectiveness of this treatment.

**Clinical Relevance:** In order to preserve the C1-C2 rotation, a monoaxial screw-rod system and anterior screw fixation may be more suitable for patients with C1 fractures combined with type II odontoid fractures.

**Level of Evidence:** 5.

## Case Report

Keywords: atlas fracture, odontoid fracture, transverse atlantal ligament, cervical rotation, screw fixation

## INTRODUCTION

Upper cervical spine injuries are relatively common after cervical spine trauma. Isolated C1 and odontoid fractures had been reported to account for 2% to 13%<sup>1</sup> and up to 20% of all cervical spine injuries,<sup>2,3</sup> respectively. However, the occurrence of C1 fractures combined with Anderson-D'Alonzo type II odontoid fractures is extremely rare, accounting for nearly 1.2% of all cervical spine injuries.<sup>4-6</sup> Although the treatment of isolated C1 or Anderson-D'Alonzo type II odontoid fractures has been extensively described, treating multiple fractures involving both the C1 and type II odontoid fractures remains a challenge for spinal surgeons due to the complex injury mechanism, unique anatomy, and potential neurovascular injuries during trauma. To

the best of our knowledge, only a few cases have been reported in the English language (Table 1). Due to the limited number of cases available, there is currently no consensus on the optimal therapeutic strategies for making clinical decisions regarding such complex fractures.

Due to the potential complications and discomfort associated with external immobilization such as hard and soft collars and halo-vests,<sup>12-14</sup> surgical management is generally recommended for C1 fractures combined with type II odontoid fractures. Surgical treatments have been reported for these fractures, including posterior C1 to C2 pedicle screws, posterior arthrodesis of C1 to C3, anterior odontoid fixation, and transarticular C1 to C2 screw fixation.<sup>4,7-10</sup> However, both posterior and anterior surgical treatments involve

**Table 1.** Case reports and case series of C1 burst fracture combined with type II odontoid fracture described in the literature.

Author	Cases	Age, y	Treatment Strategies	Follow-Up, mo
Gleizes et al <sup>4</sup>	8	44.8	A modified Gallie arthrodesis, posterior C1–C2 screw fixation, C2 pedicle screw	13.6
Guiot and Fessler <sup>5</sup>	9	57.8	Posterior C1–C2 transarticular screw+ Songer cable, anterior/posterior C1–C2 transarticular screw, or/and odontoid screw	28.5
Dickman et al <sup>6</sup>	10	44	External immobilization, C1–C2 wiring/fusion	41
Liu et al <sup>7</sup>	3	38, 18, and 56	Odontoid screw fixation combined with atlantoaxial pedicle screw fixation surgery without fusion, plaster immobilization	9, 1, and 30
Zhao et al <sup>8</sup>	21	52.4	Halo vest, posterior C–C2 pedicle screw fixation, occipital cervical fusion	23.9
Josten et al <sup>9</sup>	23	84.6	Anterior odontoid and transarticular C1/C2 screw fixation	12
Malagelada et al <sup>10</sup>	1	92	Rigid collar	1
Biakto et al <sup>11</sup>	1	17	Occipital cervical fusion	2

Note: Age and follow-up are given as mean except for Liu et al, Malagelada et al, and Biakto et al, which are give as number.

the atlas and axis fixation, which sacrifices the C1 to C2 rotation and which accounts for nearly 50% of the overall cervical rotational movement.<sup>15–17</sup> Therefore, there have been no reports on a surgical treatment that preserves the atlantoaxial joint rotation.

In our previous study,<sup>18</sup> we demonstrated that posterior atlas osteosynthesis using a monoaxial screw-rod system could achieve nearly anatomical unstable atlas fracture reduction, even in cases of transverse atlantal ligament (TAL) incompetence. Additionally, anterior screw fixation has been established as a successful treatment for type II odontoid fractures.<sup>19–21</sup> In this context, we present 2 cases in which C1 fractures combined with type II odontoid fractures were successfully treated using a posterior atlas osteosynthesis technique with a monoaxial screw-rod system and anterior screw fixation. This surgical approach aims to preserve rotation and provide an effective treatment for C1 fractures combined with type II odontoid fractures.

## METHODS

### Clinical Data

This study was performed after obtaining ethical approval from our institutional review board and informed consent from all participants. Two patients who were treated for acute C1 and type II odontoid fractures at our department before December 2016 were retrospectively reviewed. Both patients experienced falls from a low height and presented with symptoms of neck pain and stiffness. One patient initially had a transient neurological disorder, which subsequently recovered to normal preoperatively following treatment with detumescence, methylprednisolone, and nutritional nerve support. Details of the 2 patients are presented in Table 2.

Before admission, both patients were fitted with cervical collars, and skull traction was initiated after admission. Preoperative assessments included plain

posteroanterior mouth opening, lateral radiography, computed tomography (CT), and 3-dimensional reconstruction of the upper cervical spine. These imaging modalities were routinely performed to evaluate atlantoaxial stability. The Landells and Van Peteghem<sup>22</sup> and Anderson-D'Alonzo<sup>23</sup> classifications were used to classify the types of C1 and odontoid fractures, respectively. Additionally, magnetic resonance imaging of the cervical spine was performed to evaluate any injury to the cervical spinal cord and ligament structures at the craniovertebral junction, particularly focusing on the integrity of the TAL. In line with the Dickman classification,<sup>6</sup> the specific type of TAL injury was further determined using CT.

### Surgical Procedure

Both patients received general anesthesia and underwent anterior screw fixation for type II odontoid fractures and a posterior monoaxial lateral mass screw-rod system for C1 fractures. Patients were initially placed in the supine position, and closed odontoid fracture reduction was achieved using traction and reclination under the guidance of fluoroscopy. The head was stabilized using an adjusted, padded occipital ring. The surgical procedure involved a right-sided anteromedial approach

**Table 2.** Demographic and clinical data of the patients.

Characteristic	Patient 1	Patient 2
Gender	Man	Man
Age, y	61	63
Injury mechanism	Simple fall	Simple fall
C1 fracture <sup>a</sup>	Type II	Type II
Odontoid fracture <sup>b</sup>	Type IIB	Type IIB
TAL injury <sup>c</sup>	Type II	Type II
Neurological deficit	Transient paresthesias	No
Follow-up, mo	21	25

Abbreviation: TAL, transverse atlantal ligament.

<sup>a</sup>Landells and Van Peteghem's classification.

<sup>b</sup>Anderson-D'Alonzo classification.

<sup>c</sup>Dickman classification.

with a transverse skin incision measuring 4 to 6 cm. According to the process described by Etter et al,<sup>24</sup> a Kirschner wire was first placed into the odontoid under the guidance of fluoroscopy, and subsequent screw fixation of the odontoid process was performed. Only 1 screw was placed in the odontoid in both patients. There was no displacement of the fracture reduction throughout the procedure, and the odontoid fracture reduction was confirmed by intraoperative fluoroscopic open-mouth posteroanterior and lateral views as satisfactory.

The patient was repositioned in a prone reverse Trendelenburg position using a Mayfield head holder with skull traction. The C1 fracture reduction and screw fixation were performed as described in our previous report.<sup>18</sup> Briefly, the C1 posterior arch was exposed subperiosteally, approximately 30 mm lateral to the midline, through a posterior midline skin incision. Two monoaxial 3.5 mm screws were inserted into the C1 bilateral mass using the notching technique. The underside of the arch is notched down to the level of the lateral mass; however, the superior cortex is not violated. Insertion of a screw into the lateral mass via this notch allows for the recession of the screw away from the C2 nerve root. By not violating the superior cortex, one can avoid injury to the vertebral artery.<sup>25</sup> In cases where a patient had a lateral mass, a coronal split fracture was considered. Additionally, a titanium rod adapted to the curve of the C1 posterior arch was used to connect the 2 monoaxial screws. It was essential to ensure that the medial angle between the rod and screws before tightening was obtuse (100°–105°). Initially, 1 of the screw rods was tightened with a nut. Then, a compression force was gently applied to the ends of the 2 screws using a compressor device, following which the other screw rod was tightened by a nut. Furthermore, in 1 patient with overlapping displacement, another miniplat was fixed in the C1 posterior arch. Intraoperative fluoroscopic open-mouth posteroanterior view and 3-dimensional C-arm imaging were used to observe the reduction in the C1 anterior and posterior arch fractures.

### Postoperative Management and Follow-Up Evaluation

Both patients were encouraged to ambulate for 6 hours postoperatively. Clinical assessments were conducted within 1 week postoperatively. Postoperative open-mouth posteroanterior radiography, CT, and 3-dimensional reconstruction were performed to assess the effectiveness of fracture reduction and the accuracy of screw placement. Both patients were recommended to wear a Philadelphia cervical collar during the

initial 6 weeks of the postoperative period. Follow-up evaluations were scheduled at 1 month, 3 months, 6 months, 1 year, and annually thereafter. Flexion-extension dynamic lateral cervical radiographs were obtained to assess atlantoaxial stability. Medial CT and 3-dimensional reconstructions were performed to evaluate fracture healing, while additional CT images in left and right rotation were obtained to assess atlantoaxial rotation. The rotation angles of C1 to C2 rotations were determined by subtracting the rotation angle of the axis from that of the atlas. Both patients were allowed to resume normal activities once stability was confirmed 3 months postoperatively. The visual analog pain scale and Neck Disability Index scores were used to evaluate neck pain and cervical vertebral activity, respectively.

## RESULTS

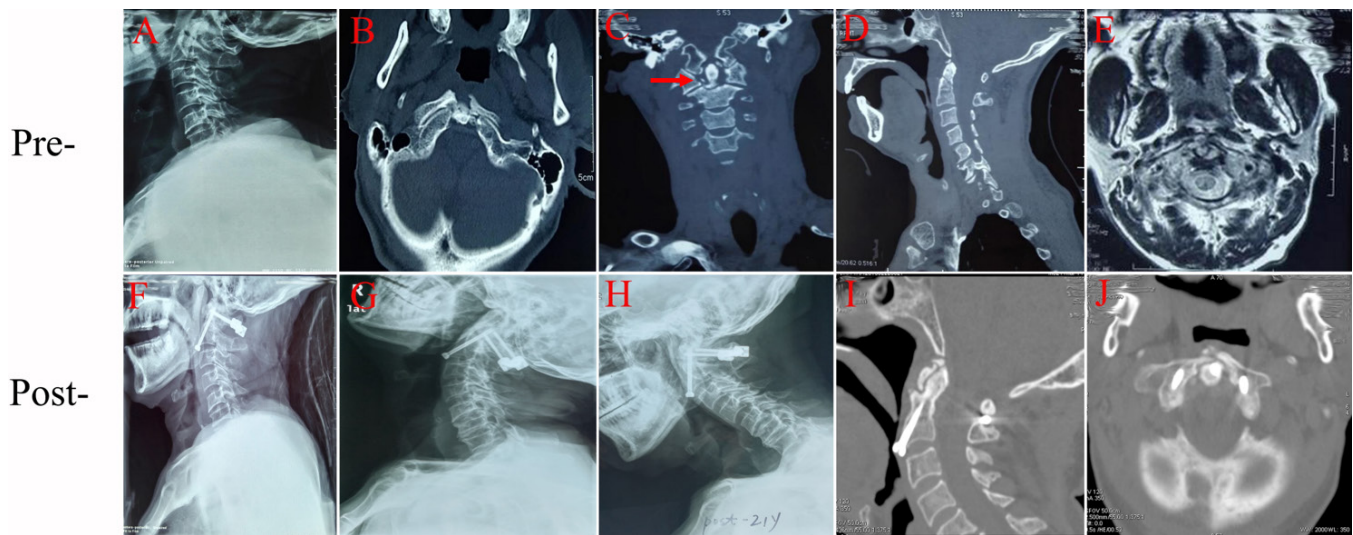
Both patients presented with C1 type II fractures according to the Landells and Van Peteghem classification (Figures 1B and 2B) and type IIB odontoid fractures according to the Anderson-D'Alonzo classification (Figures 1C, 1D, 2C and 2D). Although there was no obvious injury to the TAL in the magnetic resonance imaging of 1 patient (Figure 2E), clear avulsions involving the tubercle for the insertion of the TAL on the C1 lateral mass were observed in the 3-dimensional CT reconstruction in both patients (Figures 1C and 2C). Therefore, the TAL was type II in both patients.

All surgical procedures were successfully performed without complications such as vertebral artery injury, neurological deficit, esophageal injury, or wound infection. One patient was followed up for 21 months, and the other was followed up for 25 months. Except for almost complete bone healing in the C1 anterior arch fracture in 1 patient, other C1 to C2 fractures in both patients achieved bone healing after the last follow-up. Both the flexion-extension and rotation functions of the cervical spine significantly improved at the last follow-up (Figures 3 and 4). Moreover, no atlantoaxial instability was observed on the flexion-extension dynamic lateral cervical radiograph (Figures 1G, 1H, 2G and 2H). On the CT image at the final follow-up, the C1 to C2 rotation in the 2 patients was 32° and 49° (Figure 5), respectively. The visual analog pain scale and Neck Disability Index continuously improved postoperatively (Table 3).

## DISCUSSION

C1 fractures combined with Anderson-D'Alonzo type II odontoid fractures are rare injuries.<sup>4,6</sup> Over the past several years, there has been no consensus on the

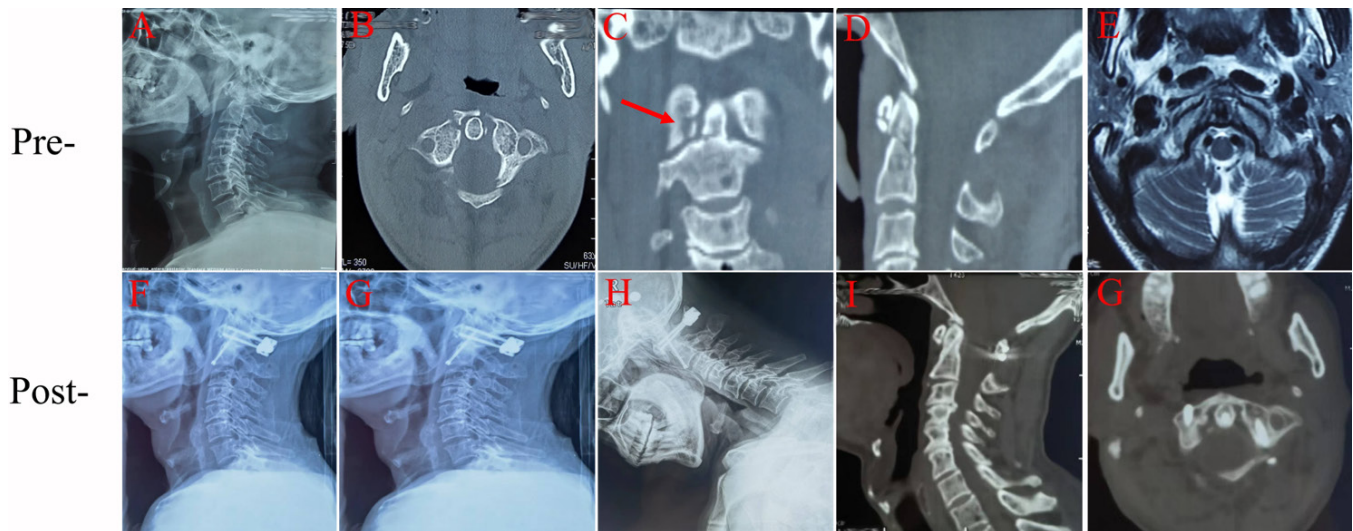




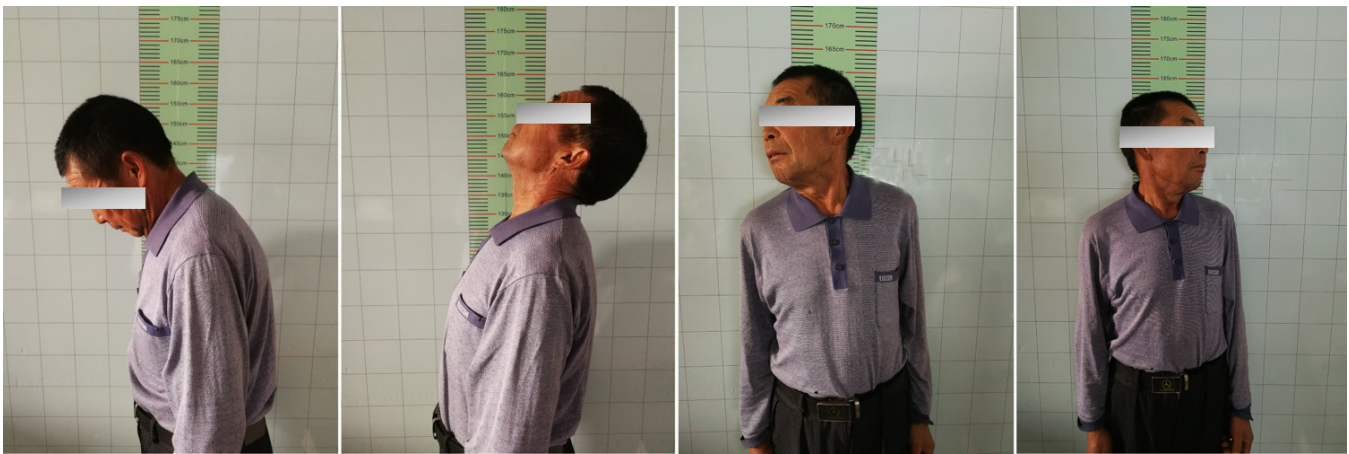**Figure 1.** Radiological data of a 61-year-old male patient (patient 1). (A) Preoperative x-ray. (B) A CT scan showed a type I C1 fracture. (C) Coronal reconstruction of a CT image showed the avulsions involving the tubercle for insertion of TAL on the C1 lateral mass (red arrow). (D) Sagittal reconstruction of a CT image showed type IIB odontoid fracture. (E) MRI showed that the avulsions involved the tubercle for insertion of TAL on the C1 lateral mass. (F) Postoperative x-ray. (G and H) The flexion-extension dynamic lateral cervical radiograph showed stable C1–C2 at 21-month follow-up. (I) Sagittal reconstruction of a CT image showed that the odontoid fracture achieved bone healing at 21-month follow-up. (J) A CT image showed that the C1 fracture achieved almost bone healing at 21-month follow-up. CT, computed tomography; MRI, magnetic resonance imaging; post-, postoperative; pre-, preoperative; TAL, transverse atlantal ligament.

treatment of this complex fracture; however, various fixation techniques for C1 to C2, including occipito-cervical fusion, have been the preferred surgical procedures.<sup>7–9,11,26</sup> These studies have demonstrated that while the aforementioned surgical strategies provide reliable stability for C1 to C2, they result in a loss of rotation. In this study, we present a novel rotation-preserving fixation method for concomitant C1 to C2 fractures. Both patients underwent posterior atlas

osteosynthesis using a monoaxial screw-rod system for C1 fractures and anterior screw fixation for type II odontoid fractures. After a follow-up period of >21 months, both C1 and odontoid fractures achieved almost complete bone healing. Furthermore, the C1 to C2 rotation was perfectly preserved. To the best of our knowledge, this is the first report to provide rotation-sparing treatment for C1 fractures combined with type II odontoid fractures.



**Figure 2.** Radiological data of a 63-year-old male patient (patient 2). (A) Preoperative x-ray. (B) A CT image showed a type II C1 fracture. (C) Coronal reconstruction of a CT image showed the avulsions involving the tubercle for insertion of TAL on the C1 lateral mass (red arrow). (D) Sagittal reconstruction of a CT image showed type IIB odontoid fracture. (E) MRI showed that the TAL was intact. (F) Postoperative x-ray. (G and H) The flexion-extension dynamic lateral cervical radiograph showed stable C1–C2 at 25-month follow-up. (I) Sagittal reconstruction of a CT image showed that the odontoid fracture achieved bone healing at 25-month follow-up. (J) A CT scan showed that the C1 fracture achieved bone healing at 25-month follow-up. CT, computed tomography; MRI, magnetic resonance imaging; post-, postoperative; pre-, preoperative; TAL, transverse atlantal ligament.

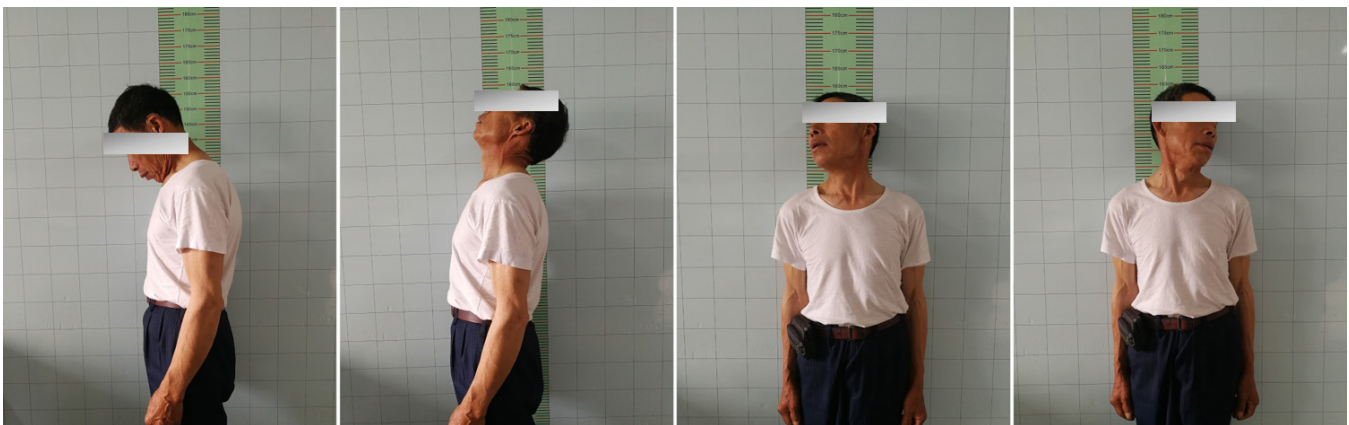

**Figure 3.** General images of the range of motion of the cervical spine for patient 1 at 21-month follow-up. (A) Cervical flexion. (B) Cervical extension. (C) Right cervical rotation. (D) Left cervical rotation.

According to the literature,<sup>7-9,11,26</sup> the management of C1 fractures combined with type II odontoid fractures typically depends on the fracture type and stability of the ligamentous complex. Immobilization using a halo vest or collar may be preferred for patients with stable fractures or the elderly. However, both a halo vest and a collar can lead to discomfort for the patient and may increase the risk of bed-related complications with prolonged bed rest, such as accumulated pneumonia, venous thrombosis, and pin site loosening and infection.<sup>12,13,27</sup> Additionally, type II odontoid fractures have a high nonunion rate due to the limited surface area of the C2 vertebral bone, with an approximate nonunion rate of 40% when treated with immobilization.<sup>28</sup> Therefore, surgical intervention may be required in cases of significant instability in concomitant C1 to C2 fractures. Zhao et al<sup>8</sup> reported that, for type II odontoid fractures combined with the posterior ring or lateral mass fractures with stable atlantoaxial joints, conservative treatments such as traction or immobilization (collar or halo


vest) can be considered. However, surgical interventions are more suitable for unstable fractures. In our study, both C1 and type II odontoid fractures in the 2 patients were visibly displaced and the TAL was injured. These results indicate that the fractures were unstable, warranting surgical intervention for these 2 patients.

Various surgical management strategies have been reported for the combination of C1 and type II odontoid fractures. These treatments include anterior surgical strategies, dorsal approaches such as anterior transarticular C1-C2 fixation, anterior odontoid fixation, transarticular C1-C2 screw fixation, bilateral C1 laminar hooks combined with C2 pedicle screw fixation, posterior pedicle screw fixation, and even occipitocervical fusion, among others.<sup>7-9,11,26</sup> These techniques have traditionally been used to reconstruct the integrity and stability of fractures; however, they result in fixed atlantoaxial joints. Consequently, arthrodesis leads to a significant loss of range of motion (ROM) in the cervical spine, particularly in axial rotation, as the atlantoaxial



**Figure 4.** General images of the range of motion of the cervical spine for patient 2 at 25-month follow-up. (A) Cervical flexion. (B) Cervical extension. (C) Right cervical rotation. (D) Left cervical rotation.





**Figure 5.** The rotation angle of C1–C2 of patient2 at 25-month follow-up. The C1–C2 rotation is equal to the C1 rotation minus the C2 rotation.

complex contributes to approximately 12% of flexion and extension and approximately 50% axial rotation.<sup>15–17</sup>

In recent years, many studies<sup>29,30</sup> have reported temporary posterior C1 to C2 screw and rod instrumentation without fusion for atlantoaxial fractures, specifically type II odontoid fractures. The ROM of C1 to C2 significantly improved after hardware removal. However, bone healing is not possible in all type II odontoid fractures. The bone healing rate of type II odontoid fractures varies widely, from 35% to 100%,<sup>28</sup> and age  $\geq 60$  years was a significant risk factor for odontoid fractures in the elderly. Song et al<sup>30</sup> suggested that instrument removal should not be performed in patients aged  $>60$  years. In our study, both patients were aged  $>60$  years. Thus, posterior temporary C1 to C2 fixation without fusion was not appropriate for these 2 patients. Even if the fractures can undergo bone healing, the removal of the internal fixation requires 2 surgeries, which would undoubtedly increase the pain and cost for the patient.

Monoatlas fixation for unstable C1 fractures and anterior screw fixation for type II odontoid fractures have been reported for many years. However, a combination of these 2 surgical techniques for the treatment of concomitant C1 to C2 fractures has not yet been reported. The most important concern in choosing this surgical strategy is atlantoaxial stability, especially when concomitant with a TAL injury. The TAL is a

strong ligament for the primary stabilizing component against translational forces at C1 to C2. Many studies have described TAL injury with an atlas fracture as an unstable fracture, and C1 to C2 fusion and occipitocervical fusion were required because neither an external brace nor C1 anterior osteosynthesis would correct the transverse ligament incompetence.<sup>6,31,32</sup>

Our previous study<sup>18</sup> and other studies<sup>33–36</sup> demonstrated that monoatlas fixation could also provide effective stability for unstable C1 fractures with TAL injuries and could not result in C1 to C2 instability. This effectively challenged the long-held notion that fixation is essential for fractures with TAL injury.<sup>6</sup> The main reason for this might be the clearly different mechanisms of isolated ligamentous TAL injuries and fractures. A pure ligamentous TAL injury is a shear injury associated with a flexion-extension mechanism and, as a result, might be more likely to disrupt other secondary stabilizers, including the longitudinal ligament (containing longitudinal bundles of crucial ligament, alar ligament, apical ligament, tectorial membrane, and accessory atlantoaxial ligament), alar ligaments, facet capsule, and neck musculature.<sup>37,38</sup> Studies have described the combination of both C1 and type II odontoid fractures as axial load entities that occur in elderly people after low-energy damage and, as such, might be more likely to maintain the integrity of secondary stabilizers.<sup>39,40</sup> Shatsky et al<sup>41</sup> suggested that secondary

**Table 3.** Clinical and radiological results of the 2 patients.

Patient	Visual Analog Scale			Neck Disability Index			Left Rotation	Right Rotation	Total Rotation	Complication
	Pre	Post	Final Follow-Up	Pre	Post	Final Follow-Up				
Patient 1	8.1	4.3	1.6	42.7	26.9	10.8	19°	14°	33°	None
Patient 2	7.8	3.9	1.9	41.6	27.4	10.3	29°	20°	49°	None

Abbreviations: Post, postoperative; Pre, preoperative.

stabilizers and restoration of anatomical congruence play a role in stabilizing the C1 to C2 joint in addition to the TAL. These structures, in conjunction with the reconstruction of the axial tension band through reduction, were sufficient to prevent C1 to C2 instability. Our previous study<sup>18</sup> revealed that patients with an anterior atlantodental interval >4 mm had no clinical symptoms. This suggests that the integrity of the atlas ring, rather than the integrity of the TAL, plays a major role in maintaining C1 to C2 stability for atlas fractures, and the atlantoaxial joint could remain relatively stable even if the atlantoaxial dislocation index is abnormal. Koller et al<sup>42</sup> provided biomechanical evidence that C1-ring osteosynthesis can reconstruct the axial tension of the C1 to C2 ligament complex and restore sufficient stability at C1 to C2, preventing significant translation under physiological loads. Furthermore, Li-Jun et al<sup>40</sup> also reported biomechanical findings that LLs have sufficient capacity to maintain the stability of the atlantoaxial joint, even if there were TAL injuries within the physiological loading range. As a result, TAL incompetence may not prohibit monoatlas fixation for C1 fractures. Accordingly, 2 patients with concomitant C1 to C2 fractures and TAL injuries were treated using a monoaxial screw-rod system and anterior screw fixation. The results showed that both fractures achieved almost complete reduction, and the C1 to C2 rotation was well preserved without atlantoaxial instability after follow-up.

Dickman et al<sup>6</sup> reported that complex fractures result in a higher rate of neurological deficits than isolated atlas or axis fractures. However, in our study, only 1 patient had a transient neurological disorder, and he quickly recovered preoperatively after drug treatment. This may be due to the different mechanisms in young and elderly patients with upper cervical cancer. Unlike young patients with high-energy trauma mechanisms, elderly patients with a low-energy trauma mechanism would suffice to cause such fractures and have a low rate of neurological deficits.<sup>6,43,44</sup> Further research with a larger sample size is required. In general, the clinical results of the 2 patients in the present study are promising. Both patients showed an almost complete reduction, and there were no additional complications. To the best of our knowledge, this is the first report to present a novel rotation-preserving fixation technique for the treatment of concomitant C1 and type II odontoid fractures.

However, the major limitation of this study was the small sample size due to rare morbidities. Additionally, a longer follow-up period is needed to evaluate

the ROM, especially the C1 to C2 rotation and stability. Finally, clinical outcomes for various treatment concepts should be evaluated, particularly temporary posterior C1 to C2 instrumentation without fusion vs our strategy. Therefore, the effectiveness of the new technique for C1 fractures combined with a type II odontoid needs to be further evaluated in large cases and long-term follow-up in the future.

## CONCLUSIONS

C1 fractures combined with Anderson-D'Alonzo type II odontoid fractures are extremely rare. A monoaxial screw-rod system and anterior screw fixation may be promising surgical strategies for concomitant C1 to C2 fractures. TAL injuries in elderly patients with low-energy damage may not prohibit surgical treatment of fractures. The C1 to C2 rotation was well preserved without atlantoaxial instability after follow-up. However, additional cases and the long-term effects need to be investigated.

## REFERENCES

1. Kakarla UK, Chang SW, Theodore N, Sonntag VKH. Atlas fractures. *Neurosurgery*. 2010;66(3 Suppl):60–67. doi:10.1227/01.NEU.0000366108.02499.8F
2. Huybregts JGJ, Jacobs WCH, Vleggeert-Lankamp CLAM. The optimal treatment of type II and III odontoid fractures in the elderly: a systematic review. *Eur Spine J*. 2013;22(1):1–13. doi:10.1007/s00586-012-2452-3
3. Bronson WH, Protosaltis T. Management of type II odontoid fractures in adults. *Bull Hosp Jt Dis*. 2019;77(1):4–10.
4. Gleizes V, Jacquot FP, Signoret F, Feron JM. Combined injuries in the upper cervical spine: clinical and epidemiological data over a 14-year period. *Eur Spine J*. 2000;9(5):386–392. doi:10.1007/s005860000153
5. Guiot B, Fessler RG. Complex atlantoaxial fractures. *J Neurosurg*. 1999;91(2 Suppl):139–143. doi:10.3171/spi.1999.91.2.0139
6. Dickman CA, Hadley MN, Browner C, Sonntag VK. Neurosurgical management of acute atlas-axis combination fractures: a review of 25 cases. *J Neurosurg*. 1989;70(1):45–49. doi:10.3171/jns.1989.70.1.0045
7. Liu C, Kuang L, Wang L, Tian J. Management of combination fractures of the atlas and axis: a report of four cases and literature review. *Int J Clin Exp Med*. 2014;7(8):2074–2080.
8. Zhao Z-S, Wu G-W, Lin J. Management of combined atlas fracture with type II odontoid fracture: a review of 21 cases. *Ind J Orthop*. 2019;53(4):518–524. doi:10.4103/ortho.IJOrtho\_249\_18
9. Josten C, Jarvers JS, Glasmacher S, Spiegl UJ. Odontoid fractures in combination with C1 fractures in the elderly treated by combined anterior odontoid and transarticular C1/2 screw fixation. *Arch Orthop Trauma Surg*. 2018;138(11):1525–1531. doi:10.1007/s00402-018-3013-y
10. Malagelada F, Tibrewal S, Lucar GA, Jeyaseelan L, Fahmy A, Gonzalez JS. Combined type II odontoid fracture with axis anterior



arch fracture: a case report in an elderly patient. *Geriatr Orthop Surg Rehabil*. 2015;6(1):37–41. doi:10.1177/2151458514554083

11. Biakto KT, Arifin J, Lee J, Benjamin M. Occipitocervical fusion and posterior fossa decompression in neglected jefferson fracture-dislocation of atlas associated with odontoid peg fracture: a case report. *Int J Spine Surg*. 2019;13(1):11–16. doi:10.14444/6001

12. Tashjian RZ, Majercik S, Biffl WL, Palumbo MA, Cioffi WG. Halo-vest immobilization increases early morbidity and mortality in elderly odontoid fractures. *J Trauma*. 2006;60(1):199–203. doi:10.1097/01.ta.0000197426.72261.17

13. Garfin SR, Botte MJ, Nickel VL. Complications in the use of the halo fixation device. *J Bone Joint Surg Am*. 1987;69(6).

14. Nakanishi T, Mitra B, Ackland H, O'Reilly G, Cameron P. Time in collars and collar-related complications in older patients. *World Neurosurg*. 2019;129:e478–e484. doi:10.1016/j.wneu.2019.05.187

15. Naderi S, Crawford NR, Song GS, Sonntag VK, Dickman CA. Biomechanical comparison of C1–C2 posterior fixations. cable, graft, and screw combinations. *Spine*. 1998;23(18):1946–1955. doi:10.1097/00007632-199809150-00005

16. Panjabi M, Dvorak J, Duranceau J, et al. Three-dimensional movements of the upper cervical spine. *Spine*. 1988;13(7):726–730. doi:10.1097/00007632-198807000-00003

17. Ishii T, Mukai Y, Hosono N, et al. Kinematics of the upper cervical spine in rotation: in vivo three-dimensional analysis. *Spine*. 2004;29(7):E139–E144. doi:10.1097/01.brs.0000116998.55056.3c

18. Zhang YS, Zhang JX, Yang QG, Li W, Tao H, Shen CL. Posterior osteosynthesis with monoaxial lateral mass screw-rod system for unstable C1 burst fractures. *Spine J*. 2018;18(1):107–114. doi:10.1016/j.spinee.2017.06.029

19. Lee TK, Han MS, Lee SK, Moon BJ, Lee JK. Outcomes of patients undergoing anterior screw fixation for odontoid fracture and analysis of the predictive factors for surgical failure. *Neurospine*. 2020;17(3):603–609. doi:10.14245/ns.2040362.181

20. Chiba K, Fujimura Y, Toyama Y, Takahata T, Nakanishi T, Hirabayashi K. Anterior screw fixation for odontoid fracture: clinical results in 45 cases. *Eur Spine J*. 1993;2(2):76–81. doi:10.1007/BF00302707

21. Wolan-Nieroda A, Maciejczak A, Guzik A, Przysada G, Szeliga E, Drużbicki M. Range of motion in the cervical spine after odontoid fracture treated with anterior screw fixation. *J Orthop Surg Res*. 2019;14(1). doi:10.1186/s13018-019-1135-8

22. Landells CD, Van Peteghem PK. Fractures of the atlas: classification, treatment and morbidity. *Spine*. 1988;13(5):450–452. doi:10.1097/00007632-198805000-00002

23. Anderson LD, D'Alonzo RT. Fractures of the odontoid process of the axis. *J Bone Joint Surg Am*. 1974;56(8):1663–1674.

24. Etter C. Combined anterior screw fixation of an odontoid fracture and the atlanto-axial joints (C1/C2) in a geriatric patient. *Eur Spine J*. 2016;25 Suppl 2:280–284. doi:10.1007/s00586-016-4625-y

25. Lee MJ, Cassinelli E, Riew KD. The feasibility of inserting atlas lateral mass screws via the posterior arch. *Spine*. 2006;31(24):2798–2801. doi:10.1097/01.brs.0000245902.93084.12

26. Lvov I, Grin A, Kaykov A, Smirnov V, Krylov V. Anterior transarticular C1–C2 fixation with contralateral screw insertion: a report of two cases and technical note. *Eur Spine J*. 2018;27(Suppl 3):347–352. doi:10.1007/s00586-017-5257-6

27. Lee D, Adeoye AL, Dahdaleh NS. Indications and complications of crown halo vest placement: a review. *J Clin Neurosci*. 2017;40:27–33. doi:10.1016/j.jocn.2017.01.002

28. Sarode DP, Demetriades AK. Surgical versus nonsurgical management for type II odontoid fractures in the elderly population: a systematic review. *Spine J*. 2018;18(10):1921–1933. doi:10.1016/j.spinee.2018.05.017

29. Garst J, Olson E, Kahn M, Fassett D. Temporary posterior C1–C2 instrumentation without fusion for treatment of displaced atlantoaxial fractures. *World Neurosurg*. 2022;164:e718–e723. doi:10.1016/j.wneu.2022.05.029

30. Song J, Yi P, Wang Y, et al. Short-term posterior C1–C2 pedicle screw fixation without fusion to treat type II odontoid fracture among people under 60 years. *Arch Orthop Trauma Surg*. 2022;142(4):543–551. doi:10.1007/s00402-020-03641-x

31. Sonntag VK, Hadley MN, Dickman CA, Browner CM. Atlas fractures: treatment and long-term results. *Acta Neurochir Suppl*. 1988;43:63–68. doi:10.1007/978-3-7091-8978-8\_15

32. Tan J, Li L, Sun G, et al. C1 lateral mass–C2 pedicle screws and crosslink compression fixation for unstable atlas fracture. *Spine*. 2009;34(23):2505–2509. doi:10.1097/BRS.0b013e3181b4009a

33. He B, Yan L, Zhao Q, Chang Z, Hao D. Self-designed posterior atlas polyaxial lateral mass screw-plate fixation for unstable atlas fracture. *Spine J*. 2014;14(12):2892–2896. doi:10.1016/j.spinee.2014.04.020

34. Hu Y, Xu R-M, Albert TJ, et al. Function-preserving reduction and fixation of unstable jefferson fractures using a C1 posterior limited construct. *J Spinal Disord Tech*. 2014;27(6):E219–E225. doi:10.1097/BSD.0b013e31829a36c5

35. Ma W, Xu N, Hu Y, et al. Unstable atlas fracture treatment by anterior plate C1-ring osteosynthesis using a transoral approach. *Eur Spine J*. 2013;22(10):2232–2239. doi:10.1007/s00586-013-2870-x

36. Tu Q, Chen H, Li Z, et al. Anterior reduction and C1-ring osteosynthesis with jefferson-fracture reduction plate (jerp) via transoral approach for unstable atlas fractures. *BMC Musculoskelet Disord*. 2021;22(1). doi:10.1186/s12891-021-04628-4

37. Woods RO, Inceoglu S, Akpolat YT, Cheng WK, Jabo B, Danisa O. C1 lateral mass displacement and transverse atlantal ligament failure in jefferson's fracture: a biomechanical study of the "rule of spence." *Neurosurgery*. 2018;82(2):226–231. doi:10.1093/neuros/nyx194

38. Heller JG, Amrani J, Hutton WC. Transverse ligament failure: a biomechanical study. *J Spinal Disord*. 1993;6(2):162–165.

39. Gebauer M, Goetzen N, Barvencik F, et al. Biomechanical analysis of atlas fractures: a study on 40 human atlas specimens. *Spine*. 2008;33(7):766–770. doi:10.1097/BRS.0b013e31816956de

40. Li-Jun L, Ying-Chao H, Ming-Jie Y, Jie P, Jun T, Dong-Sheng Z. Biomechanical analysis of the longitudinal ligament of upper cervical spine in maintaining atlantoaxial stability. *Spinal Cord*. 2014;52(5):342–347. doi:10.1038/sc.2014.8

41. Shatsky J, Bellabarba C, Nguyen Q, Bransford RJ. A retrospective review of fixation of C1 ring fractures--does the transverse atlantal ligament (TAL) really matter? *Spine J*. 2016;16(3):372–379. doi:10.1016/j.spinee.2015.11.041

42. Koller H, Resch H, Tauber M, Zenner J, Augat P, Penzkofer R, et al. A biomechanical rationale for C1-ring osteosynthesis as treatment for displaced jefferson burst fractures with incompetency of the transverse atlantal ligament. *Eur Spine J*. 2010;19(8):1288–1298. doi:10.1007/s00586-010-1380-3

43. Spivak JM, Weiss MA, Cotler JM, Call M. Cervical spine injuries in patients 65 and older. *Spine*. 1994;19(20):2302–2306. doi:10.1097/00007632-199410150-00009

44. Ryan MD, Henderson JJ. The epidemiology of fractures and fracture-dislocations of the cervical spine. *Injury*. 1992;23(1):38–40. doi:10.1016/0020-1383(92)90123-a

**Funding:** This study was supported by the Natural Science Research Projects in Colleges and Universities of Anhui Province (KJ2019A0242); the Research Fund of the Anhui Institute of Translational Medicine (2021zhyx-C34); and the Excellent Youth Research Projects in Colleges and Universities of Anhui Province (2022AH030117).

**Declaration of Conflicting Interests:** The authors declare that the article content was composed in the absence of any commercial or financial relationships

that could be construed as a potential conflict of interest.

**Corresponding Author:** Yinshun Zhang, Department of Orthopedics & Spine surgery, The First Affiliated Hospital of Anhui Medical University, No. 218 Jixi Road, Hefei 230022, Anhui Province, People's Republic of China; zhangyinshun@126.com

This manuscript is generously published free of charge by ISASS, the International Society for the Advancement of Spine Surgery. Copyright © 2024 ISASS. To see more or order reprints or permissions, see <http://ijssurgery.com>.