

Computerized Tomography–Based Morphometric Analysis of Subaxial Cervical Spine Pedicle in Asymptomatic Indian Population

KAMRAN FAROOQUE, RAHUL YADAV, BUDDHADEV CHOWDHURY, SHIVANAND GAMANAGATTI, ATIN KUMAR and PRADEEP KUMAR MEENA

Int J Spine Surg 2018, 12 (2) 112-120

doi: <https://doi.org/10.14444/5017>

<https://www.ijssurgery.com/content/12/2/112>

This information is current as of May 17, 2025.

Email Alerts Receive free email-alerts when new articles cite this article. Sign up at:
<http://ijssurgery.com/alerts>

Computerized Tomography–Based Morphometric Analysis of Subaxial Cervical Spine Pedicle in Asymptomatic Indian Population

KAMRAN FAROOQUE, MBBS, MS, MRCS,¹ RAHUL YADAV, MBBS, MS,¹ BUDDHADEV CHOWDHURY, MBBS, MS,¹ SHIVANAND GAMANAGATTI, MBBS, MD,² ATIN KUMAR, MBBS, MD,² PRADEEP KUMAR MEENA, MBBS, MS¹

¹Department of Orthopaedics, All India Institute of Medical Sciences, New Delhi, India, ²Department of Radiodiagnosis, All India Institute of Medical Sciences, New Delhi, India

ABSTRACT

Background: The purpose of this study was to analyze morphometry of the subaxial cervical spine pedicles in an Indian population based on computed tomography (CT), and thus assess the safety and feasibility of cervical pedicle screw in the subaxial cervical spine.

Methods: CT scans of 500 subaxial cervical spine vertebrae were analyzed from 100 patients presenting to our institution and undergoing cervical spine CT scan for an unrelated cause as part of ATLS protocol. Pedicle width (PW), pedicle axis length (PAL), pedicle transverse angulation (PTA), and lateral pedicle distance (LPD) were calculated on axial CT scans, and pedicle height (PH), pedicle length (PL), superior pedicle distance (SPD), and pedicle sagittal angulation (PSA) were calculated on sagittal CT scans.

Results: The mean PW ranged from 4.3 mm at C3 to 5.7 mm at C7. Mean PH ranged from 5.5 mm at C3 to 6.1 mm at C7. Mean PTA ranged from 44.5° at C3 to 37.1° at C7. PSA ranged from 16.65° at C3 to 3.29° at C7. Mean LPD ranged from 1.6 mm at C3 to 3.4 mm at C6. Mean SPD ranged from 3.5 mm at C3 to 1.15 mm at C7. Mean PAL ranged from 29.6 mm at C3 to 33.04 mm at C7. Mean PL ranged from 5.2 mm at C3 to 5.78 mm at C7.

Conclusions: Our CT-based morphometric study confirms that cervical pedicle screw placement is possible in most of the Indian population except at C3 in females. A thorough understanding of pedicle anatomy with proper CT-based preoperative planning can mitigate the risk associated with pedicle screw placement in subaxial cervical spine.

Observational Prospective Study

Keywords: cervical spine, anatomy, pedicle screw, computed tomography, India

INTRODUCTION

Cervical pedicle screw (CPS) fixation is found to be superior compared with lateral mass screws because it provides more axial, bending, and torsional stability,¹ has a higher pullout strength,² and has a low risk of loosening with cyclical loading.³ Despite its biomechanical superiority, CPS fixation is not universally accepted among surgeons because their accuracy and safety remain technically challenging because of the close proximity of vital structures.⁴ Inherent variability in pedicles at each level and lack of consistent suitable landmarks for CPS placement^{3,5} add to the technical challenge.

Various cadaveric studies have been done in the past,^{2,6–8} but comparative computed tomography (CT) data from the age-matched population has shown significant differences.⁹ Recent advances in

CT have made anatomic measurements more accurate. There have been only a few CT-based studies from the Indian subcontinent on cervical pedicles, providing limited data for a proper CPS placement.¹⁰

The present study was undertaken to determine the 3-dimensional pedicle geometry by calculating variables like pedicle length (PL), pedicle height (PH), pedicle width (PW), pedicle axis length (PAL), pedicle transverse angulation (PTA), pedicle sagittal angulation (PSA), superior pedicle distance (SPD), and lateral pedicle distance (LPD) in a large group of young asymptomatic individuals and to appreciate the level-, side-, and sex-specific morphologic differences among the Indian population. Such normative data will provide the surgeon with an improved understanding of cervical pedicle anatomo-

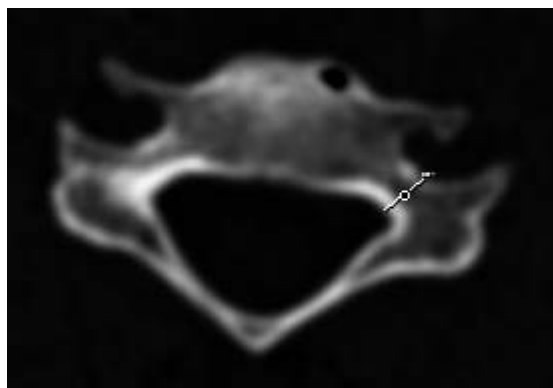


Figure 1. Pedicle width was defined as the mediolateral outer diameter of the pedicle at its isthmus.

my and will allow for safer pedicle screw insertion in cervical spine.

MATERIALS AND METHODS

Ours was an observational/prospective study to evaluate the CT-based morphology of subaxial cervical spine pedicles in asymptomatic individuals. This study was approved by the ethics committee of our institute.

Measurements of 500 subaxial cervical spine pedicles were done in 100 individuals (50 male and 50 female) presenting to our institute and undergoing cervical spine CT scan for an unrelated cause as part of the ATLS protocol.

Individuals with a history of cervical spine abnormalities; previous cervical spine surgery; congenital or developmental malformation of the cervical spine; or inflammatory, infectious, neoplastic, or traumatic conditions were excluded.

Data Collection

CT scans of the cervical spine were done using the CT machines Siemens Somatom Sensation (40 slices) and Siemens Definition AS (64 slices; Siemens, Erlangen, Germany). A preliminary lateral scout scan was done, followed by (3.0-mm) helical scans of the cervical spine and sagittal and coronal reconstructions at (0.75-mm) intervals.

Image Analysis

Measurements were made from the third cervical vertebra (C3) down to the seventh cervical vertebra (C7). On axial CT scans, the parameters measured were PW, PAL, PTA, and LPD. On sagittal CT scan images, the linear and angular parameters measured were PH, PL, SPD, and PSA. Linear

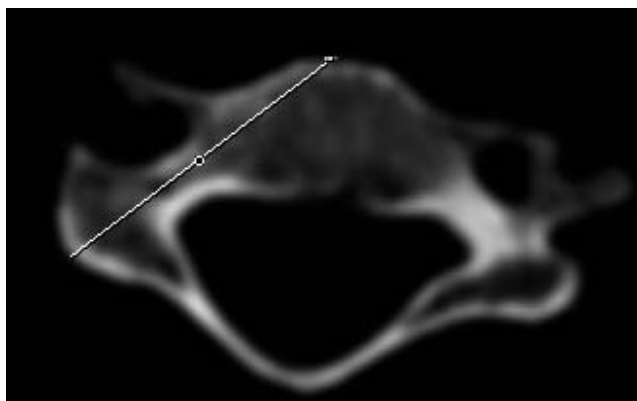


Figure 2. Pedicle axis length (maximum screw length) was defined as the length of the pedicle axis from its projection on the dorsal surface of the lateral mass to the anterior vertebral body surface.

parameters were measured in millimeters. Angular parameters were measured to one tenth of a degree. All the paired cervical pedicle parameters were measured individually for the left and the right sides, using same digital measurement software. The measurements were performed independently by an observer and cross checked by a consultant spine surgeon. Figures 1 through 4 show the parameters measured on the axial images. Figures 5 through 8 show the parameters measured on sagittal images.

Statistical Analysis

Statistical analysis was carried out using Statistical Package for the Social Sciences (IBM SPSS) software version 16. For categorical variable we used the χ^2 test or Fisher exact test and in case of continuous variable Student t test was used, statistical significance with a P value $<.05$ was used as cut off level.

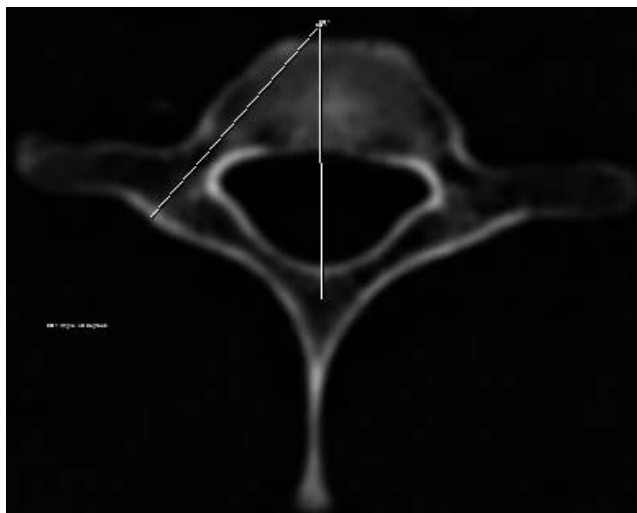


Figure 3. Pedicle transverse angulation was defined as the angle between the pedicle axis and the vertebral body midsagittal axis.

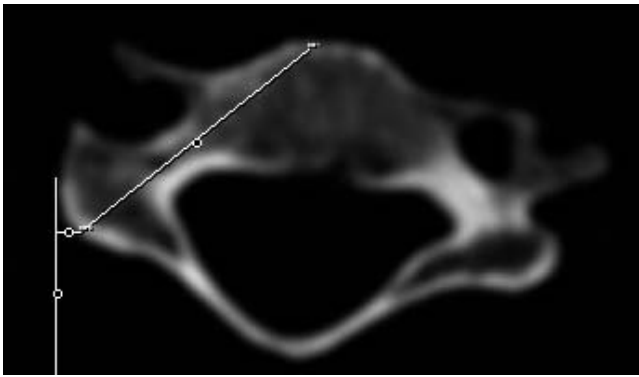


Figure 4. Lateral pedicle distance of the pedicle axis was defined as the mediolateral distance between the pedicle axis projection on the dorsal surface of lateral mass surface and the lateral border of the lateral mass.

RESULTS

The men had a mean age of 29.3 ± 8.1 years, whereas the women had a mean age of 31.3 ± 7.6 years.

PW, PH, PAL, PTA, LPD, PL, SPD, and PSA were observed to be significantly dependent ($P < .05$) on sex as well as on spinal level. All parameters were found to be greater in men than women at each spinal level except at C7, where SPD was found to be similar in both sexes. There was no significant difference ($P > .05$) between the left- and right-sided parameters at any spinal level. In general, PW, PH, PAL, LPD, and PL were found to be significantly increasing craniocaudally, with a few exceptions. At C7 PH was found to be smaller than at C6 in both sexes. At C4 PL was found to be the same as C3 in women. At C3 and C4 PAL was not found to be significantly different in men.

On the other hand, SPD, PSA, and PTA were found to be significantly decreasing craniocaudally.




Figure 5. Pedicle height was defined as the superoinferior outer diameter of the pedicle at its isthmus.

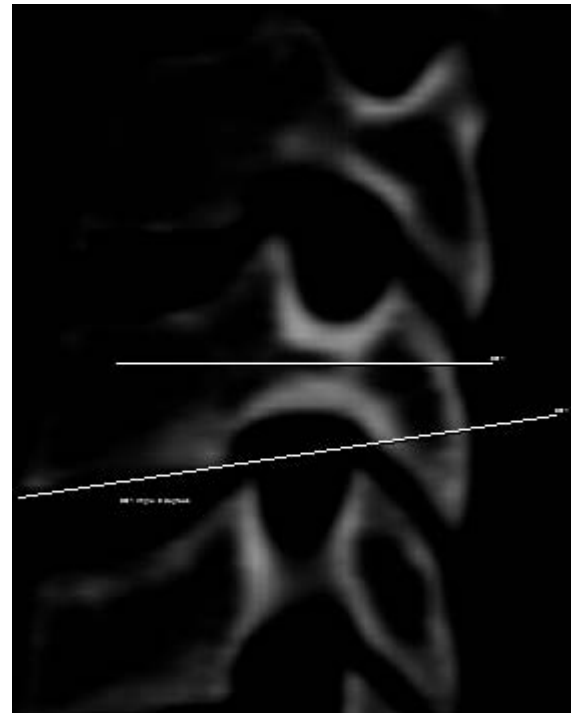


Figure 6. Pedicle sagittal angulation was defined as the angle between the pedicle axis and a line parallel to the inferior end plate of the same vertebra.

There was no typical lateral mass at C7. The mean PH was found to be greater than mean PW at all spinal levels in both sexes.

PW and PH

The mean PW increased from 4.7 mm at C3 to 6.0 mm at C7 in men, and from 4.3 mm at C3 to 5.4 mm at C7 in women (Table 1 and Figures 9 and 10). The PW was found to be less than 4.0 mm in 6 female patients, 8 pedicles at C3, and 2 pedicles at C4. A PW of less than 4.0 mm was found bilaterally in 4 patients and unilaterally in 2 patients. There was no male patient with a PW less than 4.0 mm.

The mean PH increased from 5.7 mm at C3 to 6.4 mm at C6 in men, and 5.2 mm at C3 to 6.1 mm at C6 in women. There was no pedicle with PH less than 4.0 mm in either sex. Maximum PH was 7.4 mm at C6 in men, and 6.7 mm at C6 in women. Minimum PH was 4.7 mm at C3 in men and 4.6 mm at C3 in women.

PL and PAL

The mean PL was found to increase, from 5.1 mm at C3 to 5.7 mm at C7 in women, and from 5.2 mm at C3 to 5.8 mm at C7 in men. The mean shortest PAL was found to be 28.8 mm at C3 in women, and 30.2 mm in men at C3 and C4. The longest PAL was

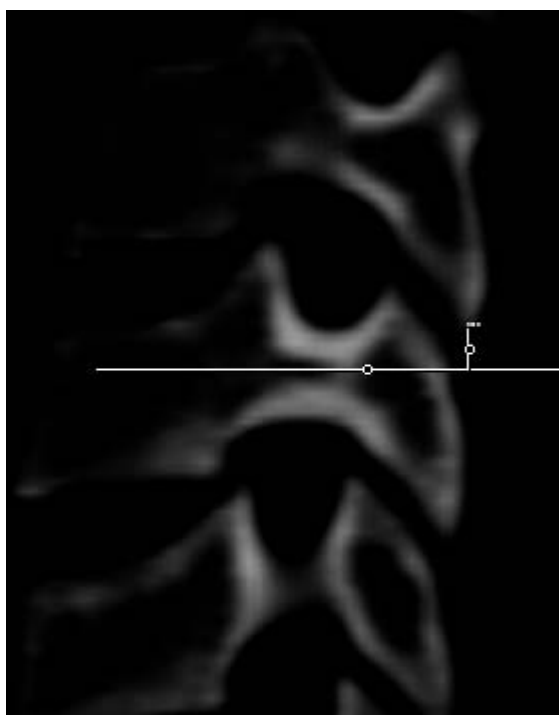


Figure 7. Superior pedicle distance was defined as the superoinferior distance between the pedicle axis projection on the dorsal lateral mass surface and the inferior margin of the inferior articular process of superior vertebrae.

33.7 mm in men and 32.38 mm in women at C7 (Table 2 and Figures 11 and 12).

LPD C3-6 Vertebrae

The mean shortest LPD observed was 1.4 mm in women and 1.8 mm in men at the C3 level, whereas the longest LPD was found to be 3 mm in women and 3.8 mm in men at the C6 vertebrae level (Table 3 and Figure 13). Because C7 did not have a typical lateral mass, LPD was not calculated at the C7 level.

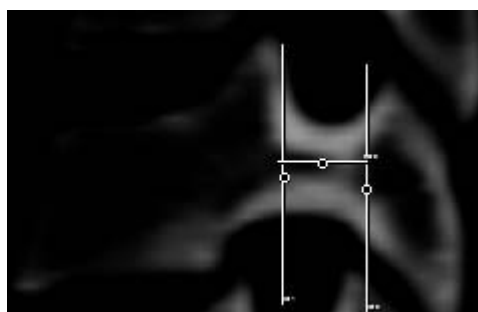


Figure 8. Pedicle length was defined as the distance between the pedicle-lateral mass junction and the pedicle-vertebral body junction.

Superior Pedicle Distance

Analysis revealed that SPD was significantly different ($P < .05$) at each level (Table 3 and Figure 14).

PTA C3-7 Vertebrae

The mean PTA was found to have a significantly ($P < 0.05$) decreasing trend from 45.02° at C3 to 37.66° at C7 in men, and from 44.01° at C3 to 36.61° at C7 in women (Table 4 and Figure 15).

PSA C3-7 Vertebrae

The mean PSA was found to have a significant ($P < .05$) decreasing trend from 18.14° at C3 to 3.7° at C7 in men, and in women it decreased from 15.17° at C3 to 2.88° at C7. The pedicles were directed cranially at C3 to C5, whereas from C6 to C7 they were horizontal to caudally directed (Table 4 and Figure 16).

Table 1. Pedicle width (PW) and pedicle height (PH).

Spinal Level	PW, mm, Mean \pm SD (Range)		PH, mm, Mean \pm SD (Range)	
	Male	Female	Male	Female
C3				
RT	4.72 \pm 0.35 (4.1–5.3)	4.37 \pm 0.26 (3.8–4.8)	5.79 \pm 0.034 (4.7–6.5)	5.29 \pm 0.022 (4.8–5.8)
LT	4.74 \pm 0.34 (3.9–5.5)	4.30 \pm 0.25 (3.6–4.9)	5.72 \pm 0.032 (4.8–6.3)	5.30 \pm 0.023 (4.6–5.9)
C4				
RT	5.0 \pm 0.39 (4.3–5.9)	4.60 \pm 0.27 (3.9–5.2)	6.12 \pm 0.036 (5.1–6.9)	5.57 \pm 0.030 (4.8–6.5)
LT	5.08 \pm 0.33 (4.4–6.1)	4.61 \pm 0.26 (4.0–5.0)	6.08 \pm 0.081 (5.1–7)	5.51 \pm 0.042 (4.9–6.6)
C5				
RT	5.49 \pm 0.37 (4.5–6.1)	4.83 \pm 0.25 (4.4–5.2)	6.29 \pm 0.039 (5.3–7.4)	5.79 \pm 0.031 (5.1–6.7)
LT	5.44 \pm 0.37 (4.3–6.1)	4.80 \pm 0.25 (4.3–5.5)	6.36 \pm 0.043 (5.2–7.4)	5.71 \pm 0.028 (5.2–6.7)
C6				
RT	5.79 \pm 0.50 (4.6–7.1)	5.0 \pm 0.33 (4.6–5.6)	6.41 \pm 0.060 (5.0–7.4)	6.1 \pm 0.030 (5.4–6.6)
LT	5.70 \pm 0.47 (4.8–6.9)	5.08 \pm 0.33 (4.5–5.9)	6.58 \pm 0.074 (5.1–7.4)	6.1 \pm 0.028 (5.6–6.7)
C7				
RT	6.1 \pm 0.41 (5.4–7.6)	5.47 \pm 0.37 (4.8–6.9)	6.39 \pm 0.044 (5.5–7.5)	5.96 \pm 0.026 (5.4–6.6)
LT	6.0 \pm 0.38 (5.5–7.2)	5.42 \pm 0.42 (5.0–7.1)	6.35 \pm 0.050 (5.5–7.5)	5.93 \pm 0.026 (5.2–6.6)

Abbreviations: RT, right pedicle; LT, left pedicle.

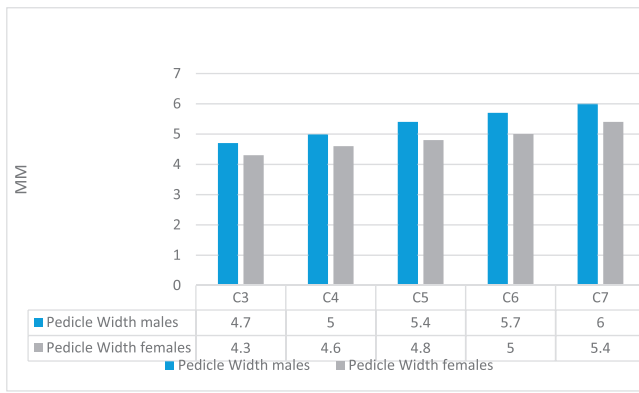


Figure 9. Overall mean pedicle width in male and female patients (mm).

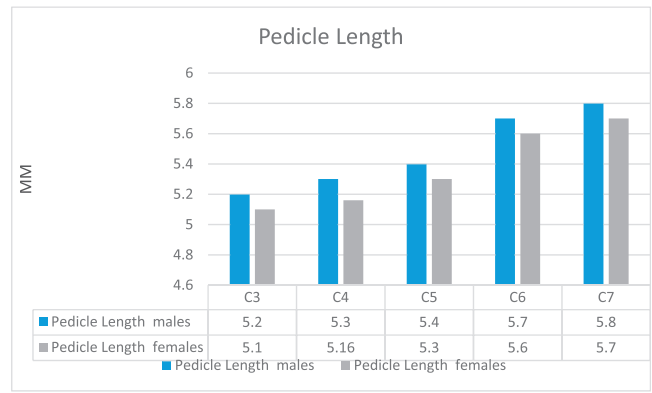


Figure 11. Overall mean pedicle length in male and female patients (mm).

DISCUSSION

Multiple cadaveric studies^{2,6-9,11} and CT-based studies^{9,10,12-21} have been done in the past to help determine subaxial cervical spine morphology and geometry in order to generate data to help spine surgeons in reducing complications associated with CPS placement. Panjabi et al.¹¹ in 1991 were the first to study cervical spine 3-dimensional morphology in cadavers. Okuyama et al.⁹ in 1994 first used CT to obtain a proper understanding of cervical spine anatomy and found significant differences in data when they were compared with cadaveric measurements, and the authors suggested that for cadavers preserved for a long time, the preservatives used may cause morphologic changes.

In 2012, Chazano et al.²² studied and found differences in pedicle morphology among different ethnicities. In our study we that found morphometric parameters were significantly larger in men compared with women, and no significant differences were noted between left- and right-sided measured pedicle parameters at any spinal levels,

which was in accordance with previous studies in other ethnic groups.^{12,13,23,24}

PW, PH, and PTA values in our study were found to be smaller than those in European/American, Thai, and Chinese populations.^{12,13,24}

An optimum of 4.5 mm PW is required for safe CPS placement in order to have 0.5 mm of bone stock on each side.^{13,24,25} We observed in our study that PW was larger than 4.5 mm at all spinal levels in both sexes, except at C3 in women (4.3 mm), which suggests that pedicle screw fixation is possible in male and female Indians at all subaxial cervical spine levels, except at C3 in female individuals.

PH/PW ratio >1 was found in this study at all levels, which was similar to findings for other ethnic groups. Mean PH was 5.5 mm at C3, 5.7 mm at C4, 5.9 mm at C5, 6.2 mm at C6, and 6.1 mm at C7, which was smaller than what Rao et al.¹² noted in the American population, with mean PH values of 6.1 mm at C3, 6.2 mm at C4, 6.1 mm at C5, 6.1 mm at C6, and 6.5 mm at C7. Chanplakorn et al.¹³ found that overall mean PH in the Chinese population was 5.7 mm at C3, 6.01 mm at C4, 5.8 mm at C5, 5.9 mm at C6, and 6.8 mm at C7.

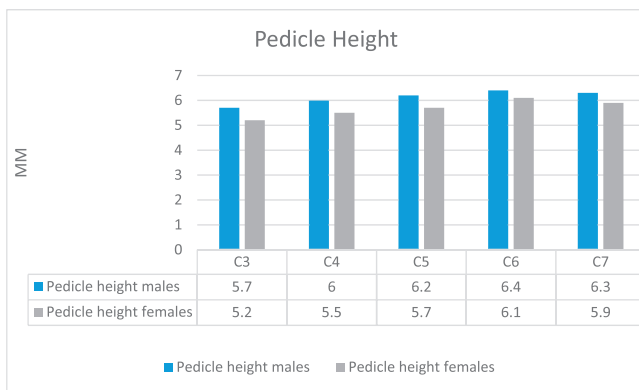


Figure 10. Overall mean pedicle height in male and female patients (mm).

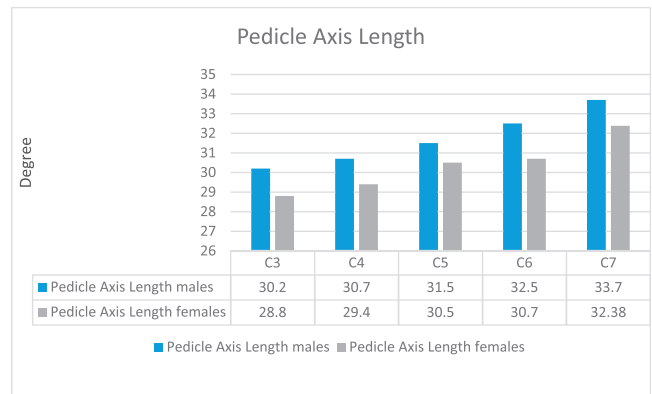


Figure 12. Overall mean pedicle axis length in male and female patients (mm).

Table 2. Pedicle length (PL) and pedicle axis length (PAL).

Spinal Level	PL, mm, Mean ± SD (Range)		PAL, mm, Mean ± SD (Range)	
	Males	Females	Males	Females
C3				
RT	5.28 ± 0.019 (4.7–5.3)	5.15 ± 0.015 (4.8–5.7)	30.29 ± 0.011 (28.2–32.7)	28.89 ± 0.086 (27.91–30.6)
LT	5.25 ± 0.019 (4.5–5.6)	5.13 ± 0.016 (4.4–5.6)	30.32 ± 0.011 (28.0–32.4)	28.90 ± 0.082 (27.63–30.21)
C4				
RT	5.35 ± 0.024 (4.9–5.5)	5.19 ± 0.014 (4.9–5.5)	30.76 ± 0.012 (28.3–32.7)	29.46 ± 0.080 (27.98–31.29)
LT	5.39 ± 0.023 (4.8–5.5)	5.17 ± 0.017 (4.5–5.5)	30.84 ± 0.013 (28.1–33.7)	29.59 ± 0.077 (28.13–31.70)
C5				
RT	5.43 ± 0.021 (5.0–5.8)	5.30 ± 0.019 (5.0–5.8)	31.52 ± 0.013 (28.20–34.2)	30.41 ± 0.083 (28.71–32.60)
LT	5.49 ± 0.022 (4.9–5.5)	5.39 ± 0.021 (5.1–5.6)	31.67 ± 0.014 (28.4–34.5)	30.60 ± 0.089 (28.41–32.42)
C6				
RT	5.77 ± 0.028 (5.0–6.1)	5.65 ± 0.033 (5.1–5.9)	32.61 ± 0.017 (28.8–39.6)	31.78 ± 1.21 (28.36–33.96)
LT	5.79 ± 0.030 (5.1–6.0)	5.69 ± 0.030 (5.1–6.1)	32.41 ± 0.014 (28.9–36.8)	31.81 ± 1.12 (27.89–33.21)
C7				
RT	5.86 ± 0.023 (5.5–6.4)	5.70 ± 0.023 (5.2–6.4)	34.23 ± 0.012 (29.2–34.8)	32.33 ± 0.014 (29.12–33.13)
LT	5.84 ± 0.029 (5.3–6.9)	5.72 ± 0.024 (5.1–6.4)	33.19 ± 0.012 (30.2–35.1)	32.43 ± 0.015 (28.89–36.1)

Abbreviations: RT, right pedicle; LT, left pedicle.

Table 3. Lateral pedicle distance (LPD) C3-6 vertebrae and superior pedicle length (SPD).

Spinal Level	SPD, mm, Mean ± SD (Range)		LPD, mm, Mean ± SD (Range)	
	Males	Females	Males	Females
C3				
RT	3.87 ± 0.034 (3.2–4.9)	3.29 ± 0.048 (2.6–4.5)	1.85 ± 0.040 (1.2–2.8)	1.42 ± 0.025 (1–2.1)
LT	3.89 ± 0.030 (3.1–4.6)	3.26 ± 0.048 (2.8–4.7)	1.88 ± 0.039 (1–3)	1.49 ± 0.021 (1–2.3)
C4				
RT	3.09 ± 0.042 (2.1–4.3)	2.77 ± 0.035 (2–3.8)	2.31 ± 0.034 (1.8–3.6)	1.90 ± 0.035 (1.4–2.9)
LT	3.04 ± 0.043 (2.4–4.2)	2.73 ± 0.036 (1.9–3.6)	2.34 ± 0.032 (1.9–3.3)	1.96 ± 0.037 (1.2–3.1)
C5				
RT	2.36 ± 0.045 (1.4–3.1)	2.1 ± 0.028 (1.6–2.8)	2.87 ± 0.045 (2.4–3.9)	2.4 ± 0.045 (1.9–3.6)
LT	2.39 ± 0.046 (1.7–3.6)	2.1 ± 0.030 (1.5–3.1)	2.88 ± 0.041 (2–4.1)	2.45 ± 0.046 (2–3.9)
C6				
RT	1.79 ± 0.047 (1–3.1)	1.3 ± 0.034 (1.1–2.4)	3.81 ± 0.045 (2.7–4.5)	3.03 ± 0.041 (2.4–4.1)
LT	1.73 ± 0.048 (1.2–2.8)	1.28 ± 0.035 (1.1–2.7)	3.84 ± 0.049 (2.3–4.7)	3.05 ± 0.043 (2.7–4.6)
C7				
RT	1.2 ± 0.013 (1.1–1.5)	1.1 ± 0.012 (1–1.3)		
LT	1.1 ± 0.014 (1.2–1.3)	1.1 ± 0.012 (1–1.4)		

Abbreviations: RT, right pedicle; LT, left pedicle.

Table 4. Pedicle transverse angulation (PTA) C3-7 vertebrae and pedicle sagittal angulation (PSA) C3-7 vertebrae.

Spinal Level	PTA, Mean ± SD (Range)		PSA, Mean ± SD (Range)	
	Males	Females	Males	Females
C3				
RT	45.01° ± 1.46° (42.3°–48.7°)	44.02° ± 1.19° (42.8°–46.1°)	18.22° ± 2.9° (10.3°–23.9°)	15.14° ± 1.9° (12°–20°)
LT	44.94° ± 1.17° (43.8°–49.3°)	44° ± 1.21° (42.7°–48.1°)	18.06° ± 3.0° (11°–24.1°)	15.20° ± 1.7° (12°–19°)
C4				
RT	43.4° ± 1.01° (41.8°–45.2°)	41.92° ± 1.09° (40.9°–44.1°)	15.06° ± 2.2° (9.3°–20.2°)	12.58° ± 1.4° (10°–17°)
LT	43.8° ± 1.15° (41.2°–46°)	41.94° ± 1.31° (41.8°–44.5°)	15.16° ± 2.4° (9.8°–19.23°)	12.7° ± 1.5° (10°–17°)
C5				
RT	41.6° ± 0.92° (40.4°–44.7°)	40.26° ± 1.16° (39.1°–43.1°)	9.92° ± 1.9° (6.9°–13.59°)	9.58° ± 2.0° (6°–14°)
LT	41.55° ± 1.00° (41.1°–44.3°)	40.02° ± 1.65° (37.9°–40.9°)	9.88° ± 1.9° (6.6°–13.70°)	9.49° ± 1.7° (5°–13°)
C6				
RT	39.8° ± 1.40° (37.4°–40.9°)	38.42° ± 1.35° (36.5°–39.02°)	7.31° ± 2.0° (3.2°–11.2°)	5.92° ± 1.6° (4°–10°)
LT	39.2° ± 1.49° (35.1°–42.1°)	38.28° ± 1.43° (35.2°–40.8°)	7.28° ± 2.0° (3.6°–12°)	5.82° ± 1.3° (3°–10°)
C7				
RT	37.72° ± 1.12° (36.2°–39.1°)	36.58° ± 1.38° (35.2°–40.1°)	3.69° ± 1.3° (1°–8°)	2.9° ± 1.2° (1°–8°)
LT	37.63° ± 1.20° (35.8°–38.9°)	36.64° ± 1.31° (34.40°–39.3°)	3.72° ± 1.3° (1°–7.3°)	2.86° ± 1.3° (1°–6°)

Abbreviations: RT, right pedicle; LT, left pedicle.

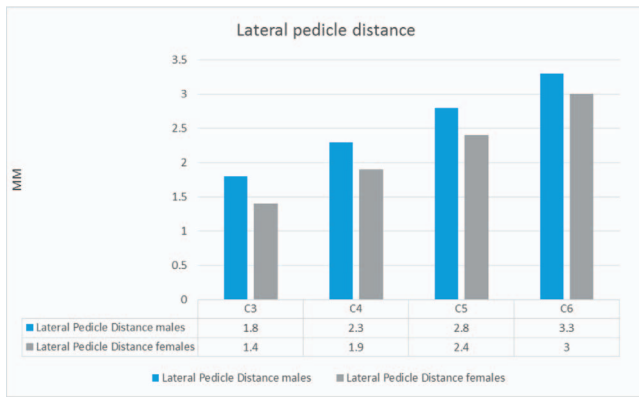


Figure 13. Overall mean lateral pedicle distance in male and female patients (mm).

Wasinpongwanich et al.²³ noted that overall mean PH in the Thai population was 6.3 mm at C3, 6.5 mm at C4, 6.9 mm at C5, 6.9 mm at C6, and 7.4 mm at C7. They observed that PH significantly increased at each level from C3 to C7, and there was no statistically significant difference between left and right pedicle height, except at C4 where left was greater than right. Banerjee et al.¹⁶ observed overall mean PH values in the Indian population of 6.37 mm at C3, 6.52 mm at C4, 6.77 mm at C5, 6.42 mm at C6, and 6.73 mm at C7.

Various methods and techniques have been described to determine the safe screw trajectory, but none of these provided a consistent recommendation for screw entry and trajectory. Abumi et al.^{26,27} proposed the entry point to be slightly lateral to the center of the lateral mass and close to the inferior margin of the cranially adjacent vertebrae. They recommended transverse angulation be medially inclined from 25° to 45° and parallel to the upper end plate in the sagittal plane axis. Karai-kovic et al.²⁸ suggested different entry point locations for different cervical vertebral levels.

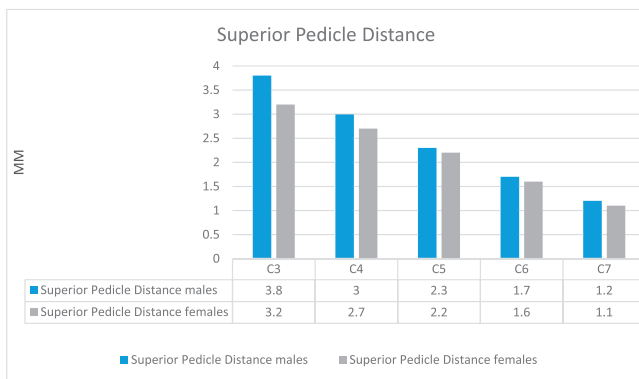


Figure 14. Overall mean superior pedicle distance in male and female patients (mm).

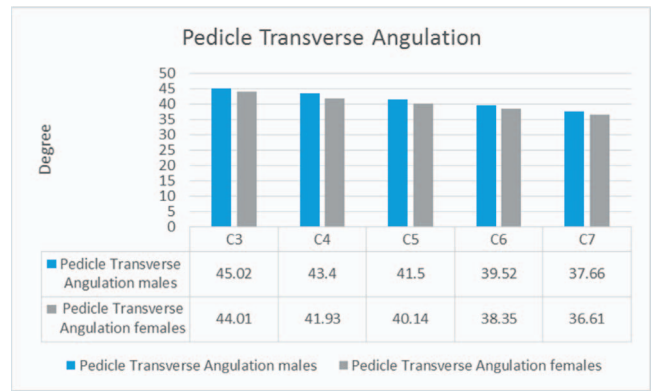


Figure 15. Overall mean pedicle transverse angulation in male and female patients (degrees).

Pedicle entrance was located at lateral vertebral notch at C4, which gradually moved medially away from the notch at C5-7. Sakamoto et al.²⁹ recommended screw insertion angles of approximately 50° from C3 to C6 and 35° at C7 vertebrae. PTA helps in establishing an ideal entry point and trajectory for a safe CPS insertion. In our study, the PTA was compared to that of European/American, Thai, and Chinese populations. Mean PTA in our study was 44.5° at C3, 42.6° at C4, 40.5° at C5, 39.5° at C6, and 37.1° at C7. Rao et al.¹² found that overall mean PTA was 46.5° at C3, 47° at C4, 45.5° at C5, 41.5° at C6, and 33° at C7 in the American population. Wasinpongwanich et al.²³ noted that overall PTA in the Thai population was 46.3° at C3, 48.5° at C4, 48.8° at C5, 44.3° at C6, and 38.7° at C7. Chanplakorn et al.¹³ observed that PTA in the Chinese population was 42.7° at C3, 44.2° at C4, 44.05° at C5, 42.21° at C6, and 39.04° at C7. On comparing our results with those of previously published Indian studies we found a difference in PTA. Banerjee et al.¹⁶ observed that mean PTA was

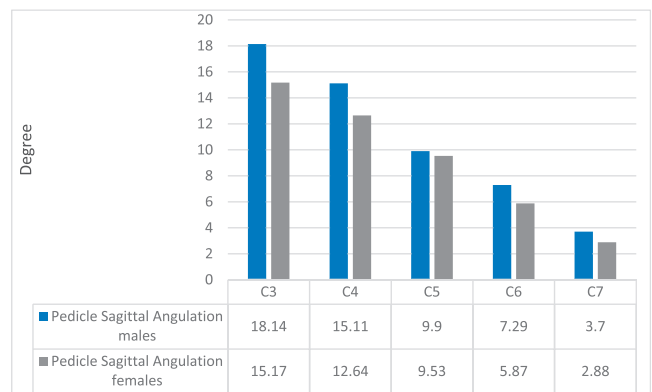


Figure 16. Overall mean pedicle sagittal angulation in male and female patients (degrees).

45.44° at C3, 46.35° at C4, 46.59° at C5, 43.22° at C6, and 36.91° at C7 in the Indian population. Gupta et al.¹⁵ in their cadaveric study observed that mean PTA was 37.9° at C3, 42.75° at C4, 38.5° at C5, and 38.4° at C6.

A proper understanding of PSA is essential to determine CPS trajectory in the sagittal plane to avoid damage to traversing nerve roots in proximity. Although generally a cranial orientation from C3 to C5 and a horizontal to caudal orientation from C6 to C7 were observed in other studies,^{12,23} a significant difference in PSA was noted.

The overall mean PSA in our study was 16.65° at C3, 13.87° at C4, 9.71° at C5, 6.58° at C6, and 3.29° at C7. Overall mean PSA in a study by Rao et al.¹² in the American population was 13.65° at C3, 7.5° at C4, 0.9° at C5, -2.95° at C6, and -3° at C7. Chanplakorn et al.¹³ noted PSA in the Chinese population was 10.7° at C3, 5.47° at C4, 0.56° at C5, -6.8° at C6, and -10.6° at C7.

PL and PAL help in proper screw size selection. The overall mean PAL in our study was 29.6 mm at C3, 30.16 mm at C4, 31.05 mm at C5, 32.15 mm at C6, and 33.04 mm at C7, and was found to be smaller compared with other ethnic groups. In comparison, Rao et al.¹² noted the overall mean PAL to be 32.6 mm at C3, 32 mm at C4, 32.55 mm at C5, 32.35 mm at C6, and 30.75 mm at C7 in the American population. Al-saeed et al.³⁰ noted in an Arab population that PAL was 32.2 mm at C3, 32.3 mm at C4, 33 mm at C5, 33.5 mm at C6, and 34 mm at C7. Wasinpongwanich et al.²³ noted in the Thai population that PAL was 29.10 mm at C3, 30.48 mm at C4, 32.05 mm at C5, 33.40 mm at C6, and 34.36 mm at C7.

Similarly, PL when compared with different ethnic groups was found to be smaller in our study. In our study PL was 5.2 mm at C3, 5.27 mm at C4, 5.4 mm at C5, 5.72 mm at C6, and 5.78 mm at C7. Rao et al.¹² noted the overall mean PL in the American population was 5.25 mm at C3, 5.2 mm at C4, 5.6 mm at C5, 5.8 mm at C6, and 5.7 mm at C7. Wasinpongwanich et al.²³ noted that mean PL in the Thai population was 5.55 mm at C3, 5.76 mm at C4, 6.07 mm at C5, 6.13 mm at C6, and 6.28 mm at C7.

CONCLUSION

We observed from our study that CPS placement is possible in majority of Indian population except at C3 in females. On comparison with other studies, we noted that cervical pedicle morphology varies

with spinal level, sex, and ethnicity. These factors should be taken into account while planning for pedicle screw placement. This study provides quantitative data on pedicle morphology from a young normative/disease-free Indian population, which can give reference data to surgeons regarding safe screw placement. However, preoperative measurements on CT scans are necessary to accommodate individual variation in order to provide greater accuracy and safety in CPS insertion.

REFERENCES

1. Kotani Y, Cunningham BW, Abumi K, McAfee PC. Biomechanical analysis of cervical stabilization systems: an assessment of transpedicular screw fixation in the cervical spine. *Spine (Phila Pa 1976)*. 1994;19(22):2529–2539.
2. Jones EL, Heller JG, Silcox DH, Hutton WC. Cervical pedicle screws versus lateral mass screws. Anatomic feasibility and biomechanical comparison. *Spine (Phila Pa 1976)*. 1997;22(9):977–982.
3. Ito Z, Higashino K, Kato S, et al. Pedicle screws can be 4 times stronger than lateral mass screws for insertion in the midcervical spine: a biomechanical study on strength of fixation. *J Spinal Disord Tech*. 2014;27(2):80–85.
4. Neo M, Sakamoto T, Fujibayashi S, Nakamura T. The clinical risk of vertebral artery injury from cervical pedicle screws inserted in degenerative vertebrae. *Spine (Phila Pa 1976)*. 2005;30(24):2800–2805.
5. Shin EK, Panjabi MM, Chen NC, Wang JL. The anatomic variability of human cervical pedicles: considerations for transpedicular screw fixation in the middle and lower cervical spine. *Eur Spine J*. 2000;9(1):61–66.
6. Bozbuga M, Ozturk A, Ari Z, Sahinoglu K, Bayraktar B, Cecen A. Morphometric evaluation of subaxial cervical vertebrae for surgical application of transpedicular screw fixation. *Spine*. 2004;29(17):1876–1880.
7. Saluja S, Patil S, Vasudeva N. Morphometric analysis of sub-axial cervical vertebrae and its surgical implications. *J Clin Diagn Res*. 2015;9(11):AC01–AC04.
8. Ludwig SC, Kramer DL, Balderston RA, Vaccaro AR, Foley KF, Albert TJ. Placement of pedicle screws in the human cadaveric cervical spine: comparative accuracy of three techniques. *Spine (Phila Pa 1976)*. 2000;25(13):1655–1667.
9. Okuyama K, Sato K, Abe E, Onuma S, Ishikawa N. Vertebral pedicle diameter as determined by computed tomography: inaccuracies observed by direct measurement of cadaveric lumbar spine. *Skeletal Radiol*. 1994;23(7):551–553.
10. Patwardhan AR, Nemade PS, Bhosale SK, Srivastava SK. Computed tomography-based morphometric analysis of cervical pedicles in Indian population: a pilot study to assess feasibility of transpedicular screw fixation. *J Postgrad Med*. 2012;58(2):119–122.
11. Panjabi MM, Duranceau J, Goel V, Oxland T, Takata K. Cervical human vertebrae. Quantitative three-dimensional anatomy of the middle and lower regions. *Spine (Phila Pa 1976)*. 1991;16(8):861–869.
12. Rao RD, Marawar SV, Stemper BD, Yoganandan N, Shender BS. Computerized tomographic morphometric analysis

of subaxial cervical spine pedicles in young asymptomatic volunteers. *J Bone Joint Surg Am*. 2008;90(9):1914–1921.

13. Chanplakorn P, Kraiwattanapong C, Aroonjarattham K, Leelapattana P, Keorochana G, Jaovisidha S, et al. Morphometric evaluation of subaxial cervical spine using multi-detector computerized tomography (MD-CT) scan: the consideration for cervical pedicle screws fixation. *BMC Musculoskelet Disord*. 2014;15:125.

14. Chen C, Ruan D, Wu C, et al. CT morphometric analysis to determine the anatomical basis for the use of transpedicular screws during reconstruction and fixations of anterior cervical vertebrae. *PLoS One*. 2013;8(12):e81159.

15. Gupta R, Kapoor K, Sharma A, Kochhar S, Garg R. Morphometry of typical cervical vertebrae on dry bones and CT scan and its implications in transpedicular screw placement surgery. *Surg Radiol Anat*. 2013;35(3):181–189.

16. Banerjee PS, Roychoudhury A, Karmakar SK. Morphometric analysis of the cervical spine of Indian population by using computerized tomography. *J Med Allied Sci*. 2012;2(2):66–76.

17. Nolte L, Zamorano L, Arm E, et al. Image-guided computer-assisted spine surgery: a pilot study on pedicle screw fixation. *Stereotact Funct Neurosurg*. 1996;66(1–3):108–117.

18. Yusof MI, Ming LK, Abdullah MS. Computed tomographic measurement of cervical pedicles for transpedicular fixation in a Malay population. *J Orthop Surg Hong Kong*. 2007;15(2):187–190.

19. Ruofu Z, Huilin Y, Xiaoyun H, et al. CT evaluation of cervical pedicle in a Chinese population for surgical application of transpedicular screw placement. *Surg Radiol Anat*. 2008;30(5):389–396.

20. Onibokun A, Khoo LT, Bistazzoni S, Chen NF, Sassi M. Anatomical considerations for cervical pedicle screw insertion: the use of multiplanar computerized tomography measurements in 122 consecutive clinical cases. *Spine J*. 2009;9(9):729–734.

21. Nishinome M, Iizuka H, Iizuka Y, Takagishi K. An analysis of the anatomic features of the cervical spine using computed tomography to select safer screw insertion techniques. *Eur Spine J*. 2013;22(11):2526–2531.

22. Chazono M, Tanaka T, Kumagai Y, Sai T, Marumo K. Ethnic differences in pedicle and bony spinal canal dimensions calculated from computed tomography of the cervical spine: a review of the English-language literature. *Eur Spine J*. 2012;21(8):1451–1458.

23. Wasinpongwanich K, Paholpak P, Tuamsuk P, et al. Morphological study of subaxial cervical pedicles by using

three-dimensional computed tomography reconstruction image. *Neurol Med Chir (Tokyo)*. 2014;54(9):736–745.

24. Ludwig SC, Kramer DL, Vaccaro AR, Albert TJ. Transpedicle screw fixation of the cervical spine. *Clin Orthop Relat Res*. 1999;(359):77–88.

25. Chazono M, Soshi S, Inoue T, Kida Y, Ushiku C. Anatomical considerations for cervical pedicle screw insertion: the use of multiplanar computerized tomography reconstruction measurements. *J Neurosurg Spine*. 2006;4(6):472–477.

26. Abumi K, Kaneda K. Pedicle screw fixation for nontraumatic lesions of the cervical spine. *Spine (Phila Pa 1976)*. 1997;22(16):1853–1863.

27. Abumi K, Shono Y, Ito M, Taneichi H, Kotani Y, Kaneda K. Complications of pedicle screw fixation in reconstructive surgery of the cervical spine. *Spine (Phila Pa 1976)*. 2000;25(8):962–969.

28. Karaikovic EE, Kunakornsawat S, Daubs MD, Madson TW, Gaines RW. Surgical anatomy of the cervical pedicles: landmarks for posterior cervical pedicle entrance localization. *J Spinal Disord*. 2000;13(1):63–72.

29. Sakamoto T, Neo M, Nakamura T. Transpedicular screw placement evaluated by axial computed tomography of the cervical pedicle. *Spine (Phila Pa 1976)*. 2004;29(22):2510–2514.

30. Al-Saeed O, Marwan Y, Kombar OR, Samir A, Sheikh M. The feasibility of transpedicular screw fixation of the subaxial cervical spine in the Arab population: a computed tomography-based morphometric study. *J Orthop Traumatol*. 2016;17(3):231–238.

Disclosures and COI: This research did not receive any specific grant from funding agencies in the public, commercial, or not-for-profit sectors.

Corresponding Author: Rahul Yadav, Department of Orthopaedics, All India Institute of Medical Sciences, 118/15, 3rd Floor, Gurukul Street, Gautam Nagar, New Delhi 110029, India. Phone: +91 9013327719; Email: rahulyadavaiims@gmail.com.

Published 3 August 2018

This manuscript is generously published free of charge by ISASS, the International Society for the Advancement of Spine Surgery. Copyright © 2018 ISASS. To see more or order reprints or permissions, see <http://ijssurgery.com>.