

Radiographic Measures of Spinal Alignment Are Not Predictive of the Development of C5 Palsy Following Anterior Cervical Discectomy and Fusion Surgery

Andrew M. Sinensky, Ian D. Kaye, William T. Li, Scott C. Wagner, Joseph S. Butler, Arjun S. Sebastian, Patrick B. Morrissey, Gregory D. Schroeder, Christopher Kepler, Alexander R. Vaccaro and Alan S. Hilibrand

Int J Spine Surg 2021, 15 (2) 213-218

doi: <https://doi.org/10.14444/8029>

<https://www.ijssurgery.com/content/15/2/213>

This information is current as of May 17, 2025.

Email Alerts Receive free email-alerts when new articles cite this article. Sign up at:
<http://ijssurgery.com/alerts>

Radiographic Measures of Spinal Alignment Are Not Predictive of the Development of C5 Palsy Following Anterior Cervical Discectomy and Fusion Surgery

ANDREW M. SINENSKY, BS,¹ IAN D. KAYE, MD,² WILLIAM T. LI, BS,¹ SCOTT C. WAGNER, MD,³ JOSEPH S. BUTLER, MD,⁴ ARJUN S. SEBASTIAN, MD,⁵ PATRICK B. MORRISSEY, MD,² GREGORY D. SCHROEDER, MD,² CHRISTOPHER KEPLER, MD,² ALEXANDER R. VACCARO, MD, MBA,² ALAN S. HILIBRAND, MD²

¹Sidney Kimmel Medical College, Thomas Jefferson University, Philadelphia, Pennsylvania, ²Rothman Orthopaedic Institute, Philadelphia, Pennsylvania, ³Walter Reed National Military Medical Center, Bethesda, Maryland, ⁴National Spinal Injuries Unit, Mater Misericordiae University Hospital, Dublin, Ireland, ⁵Mayo Clinic, Rochester, Minnesota

ABSTRACT

Background: Postoperative C5 palsy is a common complication following cervical decompression, occurring more frequently after posterior-based procedures. It has been theorized that this is the result of C5 nerve stretch resulting from spinal cord drift with these procedures. As such, it is thought to be less common after anterior cervical decompression and fusion (ACDF). However, no consensus has been reached on its true etiology. The purpose of this study is to assess the rate of C5 palsy following ACDF and to determine whether any radiographic or demographic parameters were predictive of its development.

Methods: Two hundred and twenty-six patients who received ACDF between September 2015 and September 2016 were reviewed, and 122 were included in the final analysis. Patient demographic, surgical, and radiographic data were analyzed, including preoperative and postoperative radiographic and motor examination results. The Mann-Whitney *U* test was used to compare continuous variables between independent groups, and Fisher's exact test was used to compare categorical variables between groups.

Results: Seven patients developed a C5 palsy in the postoperative period, an incidence rate of 5.7%. Among the radiographic parameters evaluated, there were no statistically significant differences between the C5 palsy and nonpalsy groups. Additionally, there were no statistically significant differences in age, patient sex, or numbers of vertebral levels fused between groups.

Conclusions: Ultimately, we did not identify any statistically significant demographic or radiographic predictive factors for the development of C5 palsy following ACDF surgery.

Level of Evidence: 3.

Cervical Spine

Keywords: C5 palsy, ACDF, anterior cervical discectomy and fusion, spine, orthopedic, palsy, surgery, cervical, radiographic, demographic

INTRODUCTION

Anterior cervical decompression and fusion (ACDF) is an effective treatment for cervical radiculopathy and myelopathy.^{1–3} Although felt to be more common following posterior cervical decompression,^{1,4–7} postoperative C5 palsy has been reported to occur in as many as 4%–7% of ACDF cases.^{1–3,5,8} Although several radiographic risk factors for the development of a postoperative C5 palsy have been identified, including, among others, excessive posterior cord drift,^{2,5,9} magnitude of change in overall cervical alignment,² and increases

in C4–C5 intervertebral height,² no consensus has emerged on its etiology, and the cause is likely multifactorial.^{2,3} Additionally, the majority of literature on postoperative C5 palsy has been studied in the context of posterior-based procedures; the risks factors for the development of C5 palsy following ACDF surgery have been much less thoroughly studied.^{2,8} Although most patients experience a full recovery within 6 months, C5 palsy is still physically and mentally debilitating for those who experience it.^{2,8} The primary purpose of this retrospective series patient cohort review was to assess the rate of C5 palsy following ACDF and to

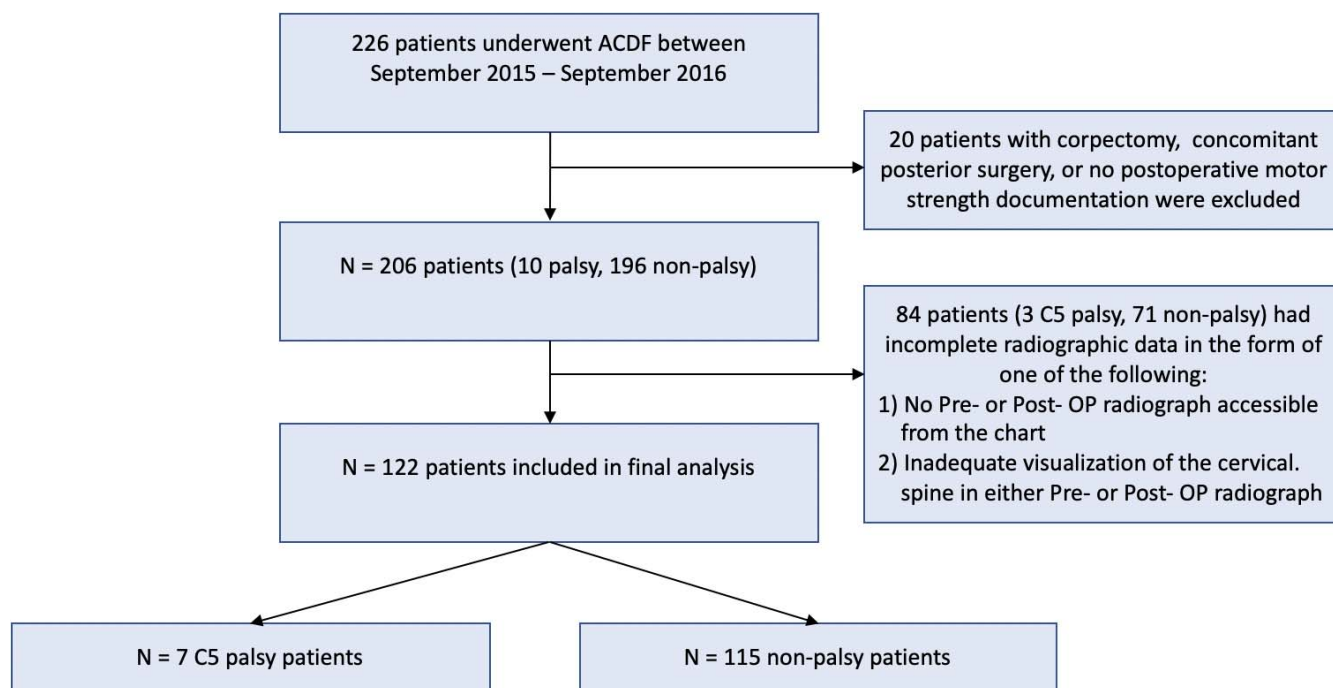


Figure 1. Algorithm describing patient exclusion criteria for analysis. Out of 226 patients who underwent anterior cervical decompression and fusion, 122 were ultimately included in our analysis.

determine whether any radiographic or demographic parameters were predictive of its development.

MATERIALS AND METHODS

Patient Selection and Inclusion Criteria

Patient demographic, surgical, and radiographic data were reviewed, including preoperative and postoperative motor examination results and preoperative and postoperative radiographs. Two hundred and twenty-six patients who underwent ACDF from September 2015 to September 2016 were reviewed in this retrospective, single institution, multisurgeon series patient cohort. Patients were excluded if they underwent concomitant posterior surgery or corpectomy, if no postoperative motor strength was documented, or if radiographs were inadequate for accurate measurement. One hundred and twenty-two patients were included in the final analysis (Figure 1). The average age of the sample was 59.7 years, and 45.1% were female. The study was approved by our institutional review board.

Outcome Measures

The primary outcome measure was the development of a C5 palsy, defined as a decrease of at least 1 motor grade in deltoid and/or biceps brachii muscle

function in the immediate postoperative period. Preoperative and immediate postoperative radiographs were reviewed to determine whether any parameters influenced the development of a C5 palsy. Preoperative and postoperative radiographs were defined as the first sets of radiographic data available before surgery and after surgery, respectively. The radiographic parameters measured included local Cobb angle (Figure 2B), C2–C7 Cobb angle (Figure 2A), C2–C7 sagittal vertical axis (SVA) (Figure 2C), segment vertebral height (Figure 2D), and C2–C7 cervical height (Figure 2E).

Statistics

The Mann-Whitney *U* test was used to compare continuous variables between independent groups, and Fisher's exact test was used to compare categorical variables between groups.

RESULTS

C5 Palsy Patient Demographics

Seven patients developed a postoperative C5 palsy with an overall rate of 5.7%. Five of these patients were men (71.4%), and 2 were women (28.6%). The average patient age was 62.14 years (range 47–80), with an average of 2.71 (range 1–3) spinal levels fused during ACDF. Average follow-

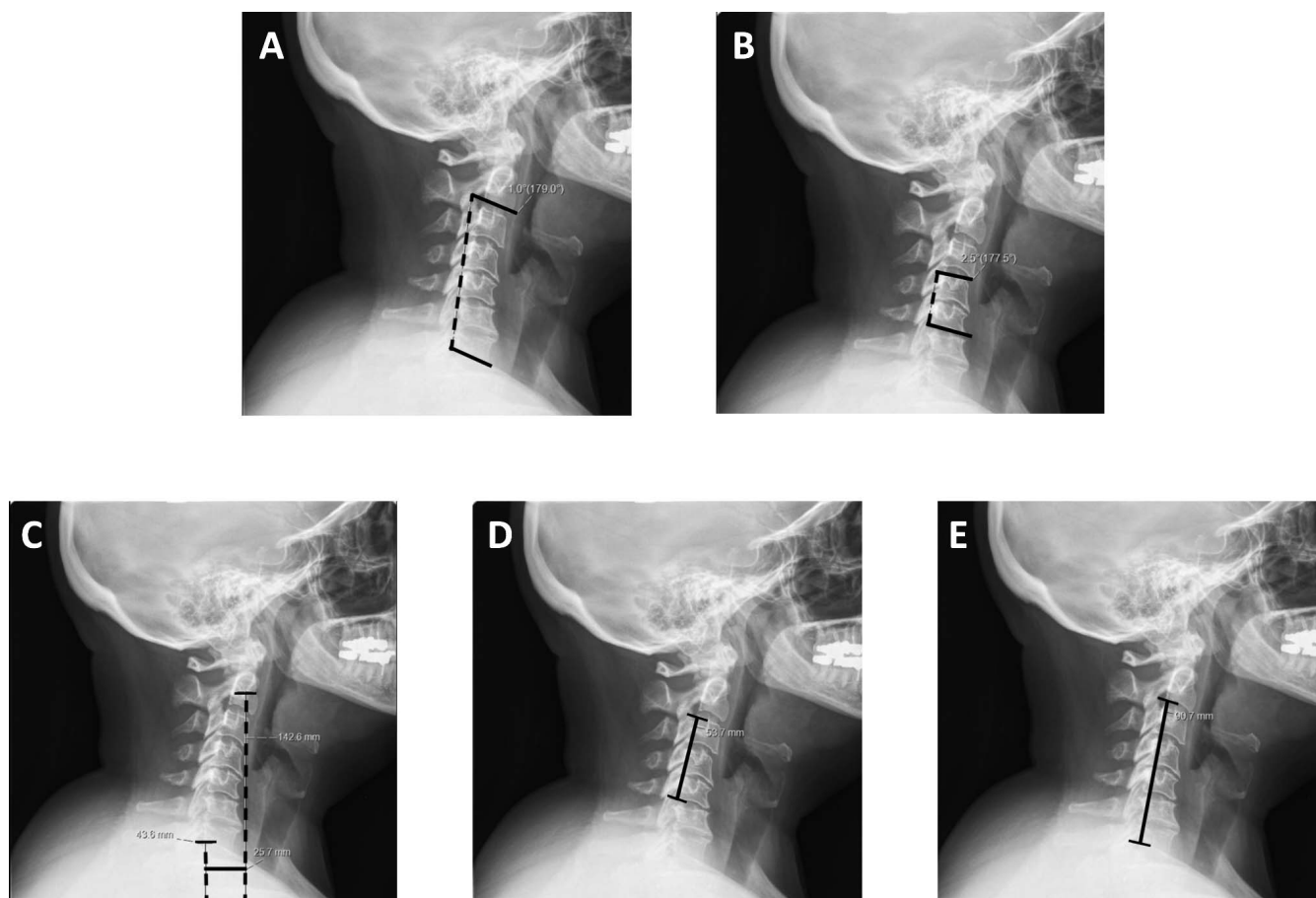


Figure 2. The C2–C7 Cobb angle is defined by the angle made by the intersection of 2 lines, 1 going through the inferior endplate of C2 and the other going through the inferior endplate of C7 (A). The local Cobb angle (B) is defined by the angle made by 2 lines, 1 line going through the superior end plate of the top vertebral level and the other going through the inferior end plate of the bottom vertebral level being considered in the anterior cervical decompression and fusion. For both the C2–C7 and the local Cobb angle, lordotic angles are considered to be positive. The sagittal vertical axis (C) is the length of a perpendicular line drawn between a line drawn vertically down from the center of the dens and a line drawn vertically down from the inferior posterior end plate of C7. Vertebral segment height (D) is defined as the length of a line between the superior posterior end plate of the superior vertebrae and the inferior posterior end plate of the inferior vertebrae being considered. The C2–C7 cervical height (E) is the length of a line drawn between the inferior posterior end plate of C2 to the inferior posterior end plate of C7.

up time for the 7 patients is 20.3 months (range 1–35). There were no statistically significant differences in age (62.14 vs 59.62 years), patient sex (28.6% vs 46.1% female), or numbers of levels fused (2.71

vs 2.31) between the palsy and nonpalsy groups. A full listing of patient demographics can be found in Tables 1 and 2. We did not observe any significant patterns in surgical techniques or surgeon distribu-

Table 1. Demographics of the 7 C5 palsy patients in this cohort. If available from the database, the duration the patients had been experiencing symptoms as well their diagnosis prior to anterior cervical decompression and fusion (ACDF) surgery are included in the table. A full recovery is defined as return of both deltoid and biceps brachii function to full preoperative values. Partial recoveries are defined as improvements in motor strength from the onset of C5 palsy to levels that are less than preoperative values. No recovery should be interpreted to mean that there was no improvement in either biceps brachii or deltoid motor strength after palsy onset.

C5 Palsy Patients (n = 7)						
Age	Sex	ACDF Levels	Duration of Symptoms Prior to ACDF, mo	Diagnosis Prior to ACDF	Recovery After C5 Palsy	Latest Follow-Up, mo
61	M	C4–C7	12	Cervical spondylosis with myelopathy	No	25
73	M	C4–C7	5	Cervical spondylosis with cervical stenosis	Full	32
41	M	C4–C6	24	Cervical radiculopathy with right upper extremity weakness	No	23
67	M	C3–C5	Unknown	Cervical radiculopathy with cervical stenosis	Partial	1
66	F	C4–C5	12	Cervical radiculopathy	Full	24
80	M	C4–C7	24	Cervical spondylosis with myelopathy	Full	2
47	F	C4–C7	2	Cervical radiculopathy	Partial	35

Table 2. Comparison of general demographics and number of levels fused between the C5 palsy and nonpalsy groups.

Parameter	C5 Palsy	Nonpalsy
Sample size	7	115
Mean age, y	62.1	59.6
Male, n (%)	5 (71.4)	62 (53.9)
Female, n (%)	2 (28.6)	53 (46.1)
No. of levels fused, mean	2.71	2.31

tion between the 2 groups. Details outlining surgical technique and surgeon distribution can be found in the Appendix.

Radiographic Measurements

Among all the radiographic parameters evaluated, there were no statistically significant differences between the groups ($P > .05$) (Table 3). None of the measurements obtained had any predictive value for the development of C5 nerve palsy, although there was a trend toward higher postoperative SVA in the C5 palsy group (33.94 vs 41.40 mm, $P = .075$) (Table 3).

Postoperative Radiographic Analysis

No statistically significant differences on postoperative follow-up were observed between the palsy and nonpalsy groups (Table 4). However, there was a trend toward increasing kyphosis within the palsy cohort compared to the nonpalsy cohort among the changes in C2–C7 Cobb angle (4.09° of kyphosis vs 1.25° lordosis, $P = .19$) and local Cobb angle (3.04° kyphosis vs 2.91° lordosis, $P = .059$) (Table 4). There were no significant differences between vertebral segment height (3.37 vs 0.90 mm), overall cervical C2–C7 height (4.26 vs 1.56 mm), and SVA (8.46 vs 5.31 mm) for the palsy versus nonpalsy groups, respectively (Table 4).

DISCUSSION

In this multisurgeon, single-institution retrospective review, no statistically significant demographic

or radiographic parameters were identified that were predictive of C5 palsy development. The small size of the C5 palsy group (7 patients) made establishing radiographic and demographic risk factors problematic. Although a trend for decreased local Cobb angle ($P = .059$) and increased postoperative SVA ($P = .075$) exists, we found that it did not reach statistical significance.

ACDF surgery has become the mainstay of treatment for many cervical degenerative diseases.^{2,3,5,8} Despite being relatively safe and producing a generally favorable outcome, C5 palsy is still a relatively common complication of cervical decompression surgery.^{1–3} Considerable literature exists on C5 palsy risk factors for posterior-based cervical decompression, and many risk factors have been identified.³ By comparison, there is scant literature on predictive factors for the development of C5 palsy in ACDF surgery.^{2,8} This is problematic because ACDF surgery is a more common surgical procedure than posterior-based approaches,² and postoperative complications are less common following ACDF surgery.^{1,4,6,7} It is important that the predictive risk factors for C5 palsy following ACDF surgery be more closely studied in the future, especially in light of the common application of anterior-based cervical decompression techniques.

The risk factors for C5 palsy following posterior-based surgical approaches may be different than those following anterior-based approaches because the postoperative changes in the vertebrae and spinal cord are not comparable.^{2,3,5,8} For example, although the spinal cord shifts posteriorly postoperatively in posterior-based procedures (and increased posterior shift of the spinal cord is a known risk factor for C5 palsy), the spinal cord has been shown to generally shift anteriorly following ACDF surgery.^{5,8}

Although the existing literature for C5 palsy risk factors is considerably less robust for ACDF

Table 3. Comparison of radiographic parameters measured preoperatively and postoperatively. Data are represented as the mean (95% confidence interval [CI]).

Parameter	C5 Palsy (95% CI)	Nonpalsy (95% CI)	P Value
Pre C2–C7 Cobb angle, °	8.70 (–2.92–20.32)	7.67 (4.82–10.51)	.81
Post C2–C7 Cobb angle, °	4.61 (–10.60–19.83)	8.99 (6.71–11.27)	.27
Pre local Cobb angle, °	5.01 (–3.14–13.17)	2.72 (0.59–4.85)	.48
Post local Cobb angle, °	1.97 (–4.39–8.33)	5.68 (4.03–7.34)	.26
Pre C2–C7 sagittal vertical axis, mm	32.94 (23.86–42.03)	28.33 (25.98–30.68)	.26
Post C2–C7 sagittal vertical axis, mm	41.40 (30.36–52.45)	33.94 (31.52–36.36)	.075
Pre vertebral segment height, mm	62.87 (46.02–79.72)	65.91 (62.37–69.46)	.95
Post vertebral segment height, mm	66.24 (50.22–82.27)	67.40 (63.71–71.08)	.83
Pre cervical height, mm	94.81 (85.42–104.21)	98.29 (96.47–100.10)	.56
Post cervical height, mm	99.07 (90.80–107.35)	100.73 (98.79–102.68)	.89

Table 4. Comparison of changes in radiographic measures preoperatively and postoperatively between the C5 palsy and nonpalsy groups. These changes are defined by (postoperative value) – (preoperative value).^a

Parameter	C5 Palsy (95% CI)	Nonpalsy (95% CI)	P Value
Change in C2–C7 Cobb angle, °	–4.09 (–13.55–5.38)	1.25 (–0.46–2.95)	.19
Change in local Cobb angle, °	–3.04 (–9.24–3.15)	2.91 (1.35–4.47)	.059
Change in sagittal vertical axis, mm	8.46 (0.81–16.1)	5.31 (3.64–6.99)	.32
Change in vertebral segment height, mm	3.37 (–1.68–8.42)	0.90 (–0.39–2.18)	.36
Change in post-cervical height, mm	4.26 (–2.72–11.23)	1.56 (–0.36–3.48)	.55

^aCI, confidence interval.

surgery, a few significant findings have been elucidated.^{2,3,5,8,11} Several groups have shown that smaller C4–C5 intervertebral foramen diameter is associated with increased C5 palsy risk following ACDF surgery.^{2,5} Increases in postoperative cervical lordosis (using measures analogous to global and local Cobb angle) are also associated with higher risk of C5 palsy.^{2,8} Although the purpose of ACDF surgery is to provide decompression of the spinal cord and nerve roots, larger (>15 mm) posterior decompression troughs, as well as asymmetric decompression width postoperatively (between the left and right side of the vertebrae), have been reported as risk factors for the development of C5 palsy.^{2,5} In 1 study, patients who developed C5 palsy had less anterior shift of the spinal cord postoperatively than the nonpalsy group.⁵ Finally, although we found no statistical differences in our ACDF surgery patient data set, increased vertebral segment height postoperatively has been found to be a risk factor for the development of C5 palsy.²

The etiology of C5 nerve palsy following ACDF is poorly understood, and there are many prevalent theories in the field.^{1,2,9} Studies using cadavers have shown that the ventral rootlets of the C5 nerve are shorter and exit the intervertebral foramen at a more obtuse angle, potentially making the C5 nerve roots particularly susceptible to iatrogenic injury.^{9,12–14} One theory suggests that it is direct injury from the surgical instruments that lead to palsy development.^{2,9,15} However, in spite of technical advances in surgical technique, the rates of postoperative C5 palsy have not significantly changed in ACDF and posterior-based surgical procedures.^{2,15} Additionally, a few groups have theorized that acute decompression results in spinal cord lesions that ultimately lead to the C5 palsy.^{18–20} Whatever the causative factors are, given the lack of clear predictive risk factors, the etiology of C5 palsy following ACDF surgery is likely multifactorial.

There is currently no standard treatment for C5 palsy, although C5 palsy most often resolves on its

own spontaneously.^{3,10,12} While the long-term outcome is generally favorable, the short-term disability from the loss of upper limb functionality is often debilitating.²¹ If patients do seek treatment, physical therapy, pain management, and other conservative methods are most commonly used.¹²

It is worth mentioning that all the literature we could identify that studied predictive factors for C5 palsy development following ACDF surgery included patients who underwent corpectomy. This is important because surgical decompressive procedures that incorporate corpectomy and/or that are posterior based are known to be associated with higher risk of C5 palsy development.^{3,4,17} Since corpectomy and posterior-based surgeries were part of our exclusion criteria, the existing literature on ACDF surgery uses patient data sets that are not necessarily analogous to our data set.

Potential limitations of this study include the small size of the C5 palsy group (7 patients), which increases the likelihood of false-negative findings. Additionally, this was a retrospective analysis, so we were limited by the demographic and radiographic data we could access. Eighty-four patients in our data set were excluded from formal analysis because radiographic data could not be obtained. Finally, since the C5 palsy group is defined as a decline in function of deltoid and/or biceps brachii function, we were inherently limited by surgeon sensitivity to detect these deficits during postoperative follow-up.

CONCLUSIONS

In this single-institution series, we identified a 5.7% postoperative C5 palsy rate following ACDF surgery. Although some have suggested that certain radiographic parameters can predict the development of C5 palsy, in our series, we could not identify any radiographic parameters that were associated with increased risk, including changes in overall cervical or local cervical alignment.

REFERENCES

1. Wang T, Wang H, Liu S, Ding W-Y. Incidence of C5 nerve root palsy after cervical surgery: a meta-analysis for last decade. *Medicine (Baltimore)*. 2017;96(45):e8560. doi:10.1097/MD.00000000000008560
2. Wang H, Zhang X, Lv B, et al. Analysis of correlative risk factors for C5 palsy after anterior cervical decompression and fusion. *Int J Clin Exp Med*. 2015;8(3):3983–3991. http://www.ncbi.nlm.nih.gov/pubmed/26064300
3. Krätzig T, Mohme M, Mende KC, Eicker SO, Floeth FW. Impact of the surgical strategy on the incidence of C5 nerve root palsy in decompressive cervical surgery. *PLoS One*. 2017;12(11):e0188338. doi:10.1371/journal.pone.0188338
4. Bydon M, Macki M, Kaloostian P, et al. Incidence and prognostic factors of C5 palsy. *Neurosurgery*. 2014;74(6):595–605. doi:10.1227/NEU.0000000000000322
5. Odate S, Shikata J, Yamamura S, Soeda T. Extremely wide and asymmetric anterior decompression causes postoperative C5 palsy. *Spine (Phila Pa 1976)*. 2013;38(25):2184–2189. doi:10.1097/BRS.0000000000000019
6. Chen Y, Guo Y, Lu X, et al. Surgical strategy for multilevel severe ossification of posterior longitudinal ligament in the cervical spine. *J Spinal Disord Tech*. 2011;24(1):24–30. doi:10.1097/BSD.0b013e3181c7e91e
7. Chang P-Y, Chan R-C, Tsai Y-A, et al. Quantitative measures of functional outcomes and quality of life in patients with C5 palsy. *J Chinese Med Assoc*. 2013;76(7):378–384. doi:10.1016/j.jcma.2013.03.008
8. Kim S, Lee S-H, Kim E-S, Eoh W. Clinical and radiographic analysis of C5 palsy after anterior cervical decompression and fusion for cervical degenerative disease. *J Spinal Disord Tech*. 2014;27(8):436–441. doi:10.1097/BSD.0b013e31826a10b0
9. Acharya S, Palukuri N. C5 Palsy in cervical decompression surgeries: a study in 390 patients. *Indian J Neurosurg*. 2016;05(02):069–074. doi:10.1055/s-0036-1586742
10. Currier BL. Neurological complications of cervical spine surgery. *Spine (Phila Pa 1976)*. 2012;37(5):E328–E334. doi:10.1097/BRS.0b013e3182417276
11. Hashimoto M, Mochizuki M, Aiba A, et al. C5 palsy following anterior decompression and spinal fusion for cervical degenerative diseases. *Eur Spine J*. 2010;19(10):1702–1710. doi:10.1007/s00586-010-1427-5
12. Thompson SE, Smith ZA, Hsu WK, et al. C5 palsy after cervical spine surgery: a multicenter retrospective review of 59 cases. *Global Spine J*. 2017;7(suppl 1):64S–70S. doi:10.1177/2192568216688189
13. Shinomiya K, Okawa A, Nakao K, et al. Morphology of C5 ventral nerve rootlets as part of dissociated motor loss of deltoid muscle. *Spine (Phila Pa 1976)*. 1994;19(22):2501–2504. http://www.ncbi.nlm.nih.gov/pubmed/7855672
14. Hung LK, Zhao X. Relationship of cervical spinal rootlets and the inferior vertebral notch. *Clin Orthop Relat Res*. 2003;409(409):131–137. doi:10.1097/01.blo.0000053596.94145.57
15. Tsuzuki N, Abe R, Saiki K, Okai K. Paralysis of the arm after posterior decompression of the cervical spinal cord. II. Analyses of clinical findings. *Eur Spine J*. 1993;2(4):197–202. http://www.ncbi.nlm.nih.gov/pubmed/20058405
16. Sasai K, Saito T, Akagi S, Kato I, Ohnari H, Iida H. Preventing C5 palsy after laminoplasty. *Spine (Phila Pa 1976)*. 2003;28(17):1972–1977. doi:10.1097/01.BRS.0000083237.94535.46
17. Uematsu Y, Tokuhashi Y, Matsuzaki H. Radiculopathy after laminoplasty of the cervical spine. *Spine (Phila Pa 1976)*. 1998;23(19):2057–2062. http://www.ncbi.nlm.nih.gov/pubmed/9794049
18. Komagata M, Nishiyama M, Endo K, Ikegami H, Tanaka S, Imakiire A. Prophylaxis of C5 palsy after cervical expansive laminoplasty by bilateral partial foraminotomy. *Spine J*. 2004;4(6):650–655. doi:10.1016/j.spinee.2004.03.022
19. Hasegawa K, Homma T, Chiba Y. Upper extremity palsy following cervical decompression surgery results from a transient spinal cord lesion. *Spine (Phila Pa 1976)*. 2007;32(6):E197–E202. doi:10.1097/01.brs.0000257576.84646.49
20. Matsunaga H, Inada M, Takeuchi M et al. Pathogenesis and prevention of C5 palsy after cervical laminoplasty [in Japanese]. *Chubu Jpn Orthop Trauma Surg*. 2007;(50):135–136.
21. Chen Y, Chen D, Wang X, et al. Significance of segmental instability in cervical ossification of the posterior longitudinal ligament and treated by a posterior hybrid technique. *Arch Orthop Trauma Surg*. 2013;133(2):171–177. doi:10.1007/s00402-012-1658-5

Disclosures and COI: None of the authors have any conflicts of interest, and no outside funding was received for this work.

Corresponding Author: Andrew Sinensky, BS, Sidney Kimmel Medical College, 1025 Walnut Street, Philadelphia, PA 19107. Phone: (516) 509-1241; Email: axs380@jefferson.edu.

Published 16 April 2021

This manuscript is generously published free of charge by ISASS, the International Society for the Advancement of Spine Surgery. Copyright © 2021 ISASS. To see more or order reprints or permissions, see <http://ijssurgery.com>.

Appendix. Details of anterior cervical decompression and fusion surgery and surgeon distribution between the C5 palsy and nonpalsy groups.

Parameter	C5 Palsy	Nonpalsy
Removal of posterior longitudinal ligament	5	77
Foraminotomy performed	4	94
Curet used for foraminotomy	0	1
Kerrison used for foraminotomy	3	77
Casper distraction pins used	4	76
Surgeon 1	1	11
Surgeon 2	2	24
Surgeon 3	1	17
Surgeon 4	2	13
Surgeon 5	0	8
Surgeon 6	0	16
Surgeon 7	0	21
Surgeon 8	1	5