

## Comparison of Applied Anatomy at L4-L5 and L5-S1 in Context of Tubular Decompression for Lumbar Canal Stenosis

Arvind G. Kulkarni and Sanjeev Asati

*Int J Spine Surg* 2021, 15 (6) 1142-1146

doi: <https://doi.org/10.14444/8145>

<https://www.ijssurgery.com/content/15/6/1142>

This information is current as of May 21, 2025.

---

**Email Alerts** Receive free email-alerts when new articles cite this article. Sign up at:  
<http://ijssurgery.com/alerts>

# Comparison of Applied Anatomy at L4-L5 and L5-S1 in Context of Tubular Decompression for Lumbar Canal Stenosis

ARVIND G. KULKARNI, MS ORTHOPAEDICS<sup>1</sup> AND SANJEEV ASATI, MS ORTHOPAEDICS<sup>1</sup>

<sup>1</sup>Department of Orthopaedics, Mumbai Spine Scoliosis and Disc Replacement Centre, Bombay Hospital and Medical Research Centre, Mumbai, Maharashtra, India

## ABSTRACT

**Background:** Tubular over-the-top decompression is getting popular in the management of lumbar canal stenosis (LCS). While L4-L5 is the most common level affected and operated for LCS, it is not uncommon to encounter patients with stenosis at L5-S1. No previous study has described the technical challenges of tubular decompression at the L5-S1 level as compared to at the L4-L5 level.

**Methods:** This observational study was done on 40 consecutive patients older than 45 years who underwent magnetic resonance imaging (MRI) for back-related issues. The following radiological parameters: interlaminar angle, tube angle, laminar thickness ratio at the isthmus, and the laminar length ratio were evaluated at the L4-L5 level (group A) and the L5-S1 level (group B). The hypothesis behind the study was that if these patients were subjected to tubular decompression, then there will be technical differences between doing the surgery at the L4-L5 and L5-S1 levels.

**Results:** The mean age of the patients was 56.8 years (46–72) and the male to female ratio was 3:2. The mean interlaminar angle in group A was 71° and in group B was 102°. The tube angle in group A and group B was 36.8° and 49.7°, respectively. The laminar thickness ratio (L4:L5) was 1.34:1 and the laminar length ratio (L4:L5) was 1:1.42 in group A and B, respectively.

**Conclusion:** Tubular decompression at the L5-S1 level has its own challenges because of the different anatomy of the L5 lamina compared to that of the L4 lamina. The wide interlaminar angle of L5 as compared to L4 dictates more oblique tube docking (tube angle) and more extensive table tilting to reach the contralateral lateral recess, thus making it challenging. The authors recommend that surgeons be conscious of this fact while performing tubular decompression at the L5-S1 level.

**Clinical Relevance:** This article provides information regarding technical challenges of doing surgery at L5-S1 level as compared to L4-L5 level.

**Level of Evidence:** 3.

Minimally Invasive Surgery

Keywords: lumbar canal stenosis, spinal surgery, interlaminar angle, tube angle, microendoscopic decompression

## INTRODUCTION

Lumbar canal stenosis (LCS) is the most common indication of spinal surgery in elderly.<sup>1</sup> According to the area of affection, it can be categorized as central and lateral recess stenosis. Laminectomy and decompression is the treatment of choice for LCS. Since the time Foley and Smith popularized the use of tubular retractor system in lumbar spine surgery,<sup>2</sup> unilateral laminotomy and bilateral decompression (ULBD) has shown favorable clinical outcomes and is widely used.<sup>3–5</sup> The L4-L5 level is the most affected level with affection of fifth lumbar root followed by the L3-L4 and L5-S1 levels.<sup>6</sup> The morphometry of the L4 vertebra and the L4-L5 facet articulation is different from L5 vertebra and L5-S1 facet articulation, respectively. Previous studies have extensively described the morphometry at different levels and its significance in context of pedicle screw instrumentation.<sup>7–9</sup> However, to

our knowledge, no previous study has described the technical differences faced during L5-S1 ULBD as compared to at the L4-L5 level. In the present article, we present the challenges associated with tubular decompression at the L5-S1 level as compared to the L4-L5 level.

## MATERIALS AND METHODS

After institutional board approval, this observational study was done on 40 consecutive patients from outdoor patient department who underwent magnetic resonance imaging (MRI) for back-related issues. Written informed consent was taken from all the participants included in the study. Patients with spine trauma, tumor, infection, and deformity were excluded from the study and the radiological parameters (mentioned below) were evaluated at L4-L5 level (group 1) and L5-S1 level (group 2). The radiological parameters were assessed independently by 2

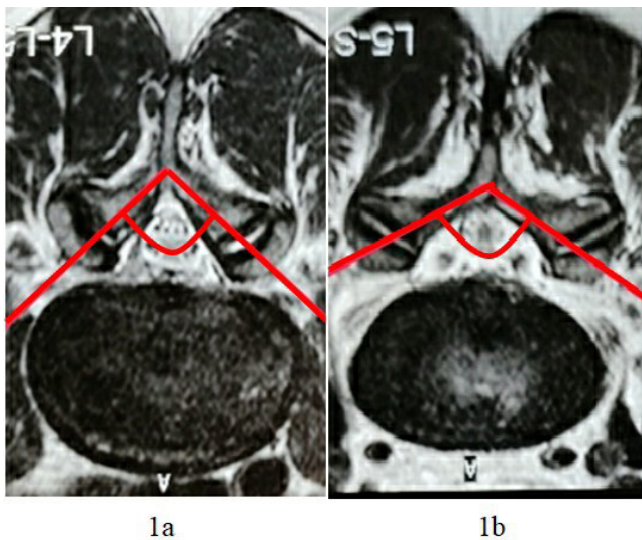


Figure 1. Interlaminar angle at (A) L4-L5 and (B) L5-S1 level.

fellowship-trained spine surgeons and 1 radiologist. The hypothesis behind the study was that if these patients have to undergo tubular decompression in future then there will be technical differences between doing the surgery at L4-L5 and L5-S1 level.

The parameters measured on MRI (measured manually) were as follows:

**1. Interlaminar angle**

Measured between the lines that are in the plane of right and left laminae of vertebrae (Figure 1)

**2. Tube angle**

Measured between a vertical line drawn along the spinous process and a line drawn along the lamina (collinear with the tube) in axial MRI cuts (Figure 2)

**3. Ratio of the thickness of isthmus (thinnest portion) of the lamina of L4 and L5**

**4. Laminar length (from the midline to the lateral recess) ratio at L4 and L5**

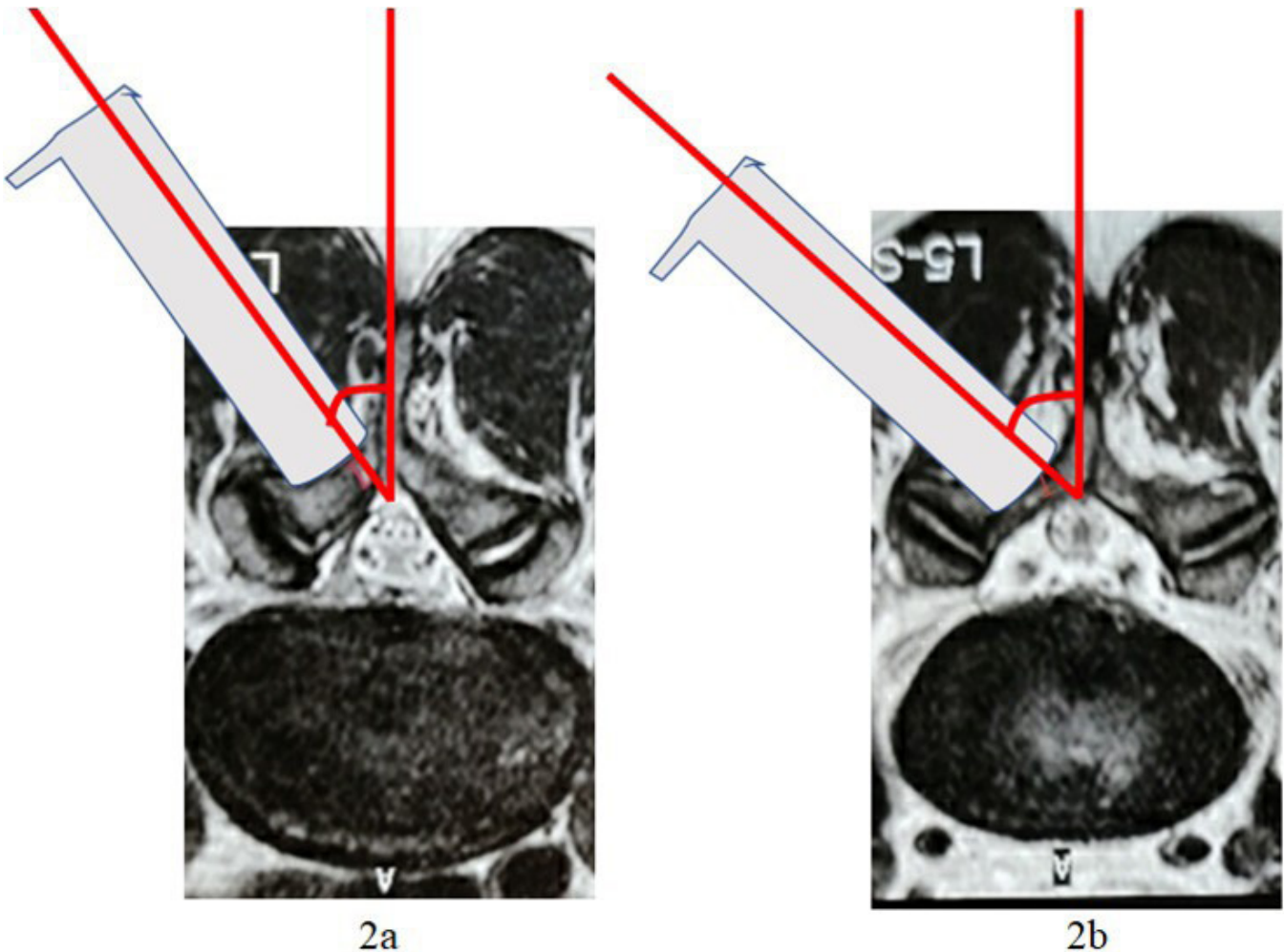


Figure 2. Tube angle at (A) L4-L5 and (B) L5-S1 level.

## Importance of the Above Measurements in the Context of Execution of Tubular Over-the-Top (OTT) Decompression

As a part of minimal access decompression of LCS, decompression of the contralateral lateral recess stenosis is performed using over-the-top (OTT) technique through a tubular retractor. The contralateral lateral recess is remotely situated at an acute angle in the context of ipsilateral laminotomy and is thus difficult for the operating surgeon to access without adaptations. The strategy employed by most surgeons is to strap the patient securely to the operating table and tilt the table to the opposite side. The tilting of the table translates in making the axis of the tubular retractor as vertical as possible, thus making it ergonomically easy for the surgeon to access the contralateral lateral recess. The measurements described previously relate to the degree of complexity in executing contralateral lateral recess decompression at the L4-L5 and L5-S1 levels.

The *t* test was used to compare the 2 groups, and *P* < 0.05 was considered statistically significant. Interobserver correlation of methods of radiological parameters measurement was estimated using the interclass coefficient (ICC).

## RESULTS

The mean age of the patients was 56.8 years (range, 46–72) and the M:F ratio was 3:2. The interlaminar and tube angle were as follows:

### 1. Interlaminar angle among the groups:

Parameter	Group 1 (L4)	Group 2 (L5)	P Value
Interlaminar angle, mean	71°	102°	<0.001

### 2. Tube angle among the groups:

Parameter	Group 1 (L4-L5)	Group 2 (L5-S1)	P Value
Tube angle, mean	36.8°	49.7°	<0.001

The laminar thickness ratio (L4:L5) was 1.34:1 and the laminar length ratio (L4:L5) was 1:1.42. The interobserver reliability among the observers and ICC is shown in Table.

## DISCUSSION

LCS most commonly affects the L4-L5 level and correspondingly minimally invasive surgeons are most experienced and equipped to decompress the L4-L5 segment using tubular retractors. The tenets of tubular

**Table.** Interobserver reliability<sup>a</sup> among the observers.

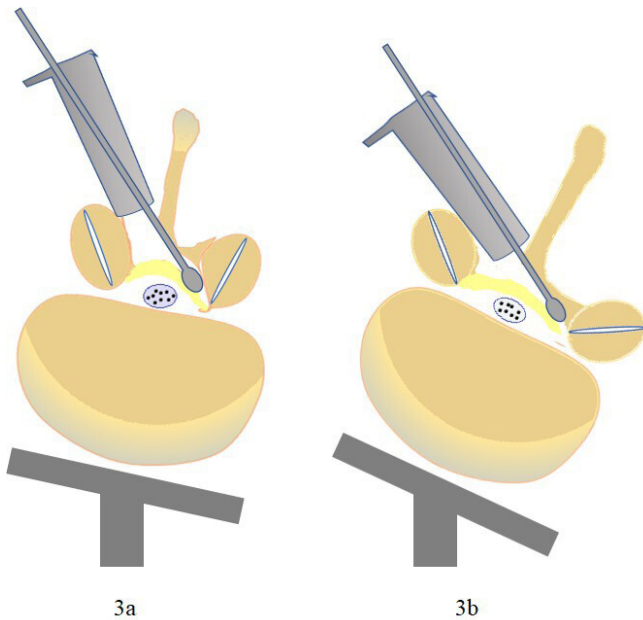
Radiological Parameters	Agreement Between Observers	ICC
Interlaminar angle		
L4-L5	60%	0.98
L5-S1	62.5%	0.99
Tube angle		
L4-L5	62.5%	0.97
L5-S1	57.5%	0.94
Laminar thickness ratio	65%	0.97
Laminar length ratio	62.5%	0.96

<sup>a</sup>Inter-observer correlation was estimated using the interclass coefficient (ICC).

decompression and operative steps are imbibed during the training period by various means such as assisting in surgeries and attending workshops. Tubular OTT decompression is one of the popular and prevalent techniques of minimally invasive decompression.<sup>10</sup> The operative principles involve unilateral laminotomy, tilting of the tube, microscope, and the operating table to the contralateral side, and performing central and contralateral decompression. This is followed by ipsilateral tilting of the operating table, tube, and the microscope, making it convenient for ipsilateral decompression. Hence, for a successful global (central canal and bilateral lateral recesses) decompression, a lot depends upon the ability to incline the operating table, the tubular retractor, and the microscope. The inclination is necessary especially to reach the contralateral lateral recess and foramen while keeping the vision of the operative field as straight and vertical as possible for the operating surgeon. This is necessary from the point of ergonomics as well as feasibility.

The factors that determine the degree of inclination of the above 3 components (table, tube, and microscope) necessary are the depth of the contralateral recess and the angle made by the contralateral lamina (collinear with the tube) with a vertical line. It is safe to state that the more acute the angle of the lamina with the vertical, the lesser the inclination that is necessary (Figure 3). Again, the deeper the contralateral recess, the more deep is the length of excursion of instruments like Kerrison rongeur to decompress the opposite nerve root. These are some important factors that come into play in consideration of tubular over-the-top decompression at L5-S1 in comparison to the more frequently operated L4-L5 level. The current study analyzes these factors in an objective way to put forth an argument that tubular microdecompression at L5-S1 is laid with some unique complexities.

First, the authors found that the interlaminar angle is significantly higher at L5-S1 in comparison to L4-L5 and this makes the working angle steeper for



**Figure 3.** Figure demonstrating table tilting and tube tilting for contralateral over-the-top decompression at (A) L4-L5 and (B) L5-S1 level.

the operating surgeon in the axial plane. This challenge basically demands a higher degree of tilt for the 3 components discussed above. This is also reflected in the angle made by the lamina with the vertical which is much higher at the L5-S1 level, meaning that a greater effort has to be made by the operating surgeon to obtain a more convenient access to the contralateral lateral recess. Again, the difficulty is compounded by the lordosis at L5-S1 which demands an oblique disposition of the surgeon's head toward the headend of the operating table. This can be circumvented to a certain extent by raising the headend of the table in order to reduce the plane at L5-S1 to horizontal.

Second, the first challenge is complicated by a longer stride to reach the corners of the contralateral recess at L5-S1 in comparison to L4-L5 because of the natural widening of the interpedicular distance as we move down in the caudal direction. This is objectively noted in the current study by measuring the laminar length from the midline to the lateral recess, which appears to be significantly higher at L5 compared to L4, almost close to 1.5 times. This feature assumes importance since it makes the access to contralateral decompression deeper and farther.

Third, thickness of the lamina is important in the context of execution of decompression of the contralateral side. A thick lamina will provide sufficient latitude to perform an internal decompression using the drill and Kerrison rongeurs without fracturing. On the contrary, a thin lamina, especially at the site of the isthmus

(thinnest part), has the potential to break while drilling or decompressing, leading to inadvertent entry into the soft tissues on the opposite side. This can lead to disorientation of the anatomy and bleeding from the contralateral soft tissues that is difficult to control. To a certain extent, it also works against the philosophy of the OTT concept of decompression that advocates unilateral laminotomy and global decompression without exposure of the contralateral side. The current study reveals the challenges that L5-S1 decompression would pose in comparison to L4-L5 in this context, demonstrating a much thinner laminar isthmus at L5 in contrast to L4.

The limitation of the current study relates to the non-stenotic MRI images that were considered and evaluated. However, the authors comprehend that this will not influence the revelations and impact of the study.

## CONCLUSION

Tubular decompression at L5-S1 level has its own challenges because of the different anatomy of L5 lamina as compared to that of L4 lamina. The wide interlaminar angle of L5 as compared to L4 dictates more oblique tube docking (tube angle) and more extensive table tilting to reach the contralateral lateral recess, thus making it challenging. Thinner lamina at L5 as compared to L4 lamina has the potential to break while drilling and disorient the anatomy, and a longer distance of lateral recess from midline at L5-S1 compared to L4-L5 makes the access to decompression deeper and farther. The authors recommend that surgeons be conscious of these facts while performing tubular decompression at L5-S1 level.

## REFERENCES

1. Deyo RA, Gray DT, Kreuter W, Mirza S, Martin BI. United States trends in lumbar fusion surgery for degenerative conditions. *Spine*. 2005;30(12):1441–1445. doi:10.1097/01.brs.0000166503.37969.8a.
2. Foley KT. Microendoscopic discectomy. *Techniques in neurosurgery*. 1997;3:301–307.
3. Shamji MF, Goldstein CL, Wang M, Uribe JS, Fehlings MG. Minimally invasive spinal surgery in the elderly: does it make sense? *Neurosurgery*. 2015;77 Suppl 4:S108–15. doi:10.1227/NEU.0000000000000941.
4. Phan K, Mobbs RJ. Minimally invasive versus open laminectomy for lumbar stenosis: a systematic review and meta-analysis. *Spine*. 2016;41(2):E91–E100. doi:10.1097/BRS.0000000000001161.
5. Palmer S, Turner R, Palmer R. Bilateral decompression of lumbar spinal stenosis involving a unilateral approach with microscope and tubular retractor system. *J Neurosurg Spine*. 2002;97(2):213–217. doi:10.3171/spi.2002.97.2.0213.

6. Tomkins-Lane CC, Battié MC, Hu R, Macedo L. Pathoanatomical characteristics of clinical lumbar spinal stenosis. *J Back Musculoskelet Rehabil.* 2014;27(2):223–229. doi:10.3233/BMR-130440.
7. Karabekir HS, Gocmen-Mas N, Edizer M, Ertekin T, Yazici C, Atamturk D. Lumbar vertebra morphometry and stereological assesment of intervertebral space volumetry: a methodological study. *Ann Anat.* 2011;193(3):231–236. doi:10.1016/j.aanat.2011.01.011.
8. Lien SB, Liou NH, Wu SS. Analysis of anatomic morphometry of the pedicles and the safe zone for through-pedicle procedures in the thoracic and lumbar spine. *Eur Spine J.* 2007;16(8):1215–1222. doi:10.1007/s00586-006-0245-2.
9. Alam MM, Waqas M, Shallwani H, Javed G. Lumbar morphometry: a study of lumbar vertebrae from a pakistani population using computed tomography scans. *Asian Spine J.* 2014;8(4):421–426. doi:10.4184/asj.2014.8.4.421.
10. Nomura K, Yoshida M. Microendoscopic decompression surgery for lumbar spinal canal stenosis via the paramedian approach: preliminary results. *Global Spine J.* 2012;2:87–94. doi:10.1055/s-0032-1319774.

**Funding:** This research received no specific grant from any funding agency in the public, commercial, or not-for-profit sectors.

**Declaration of Conflicting Interests:** The author(s) declared no potential conflicts of interest with respect to the research, authorship, and/or publication of this article.

**Ethics Approval:** IRB approval from the hospital and written informed consent from all the participants were taken prior to the study.

**Corresponding Author:** Dr Sanjeev Asati, Department of Orthopaedics, Mumbai Spine Scoliosis and Disc Replacement Centre, Bombay Hospital and Medical Research Centre, Mumbai, Maharashtra, India; asati.sanjeev87@gmail.com

Published 20 January 2022

This manuscript is generously published free of charge by ISASS, the International Society for the Advancement of Spine Surgery. Copyright © 2021 ISASS. To see more or order reprints or permissions, see <http://ijssurgery.com>.