

Current Concepts of Cervical Disc Arthroplasty

David Turkov, Alan Job, Cesar Iturriaga and Rohit B. Verma

Int J Spine Surg 2021, 15 (6) 1174-1183

doi: <https://doi.org/10.14444/8149>

<https://www.ijssurgery.com/content/15/6/1174>

This information is current as of May 17, 2025.

Email Alerts Receive free email-alerts when new articles cite this article. Sign up at:
<http://ijssurgery.com/alerts>

Current Concepts of Cervical Disc Arthroplasty

DAVID TURKOV^{1,2}; ALAN JOB, MD^{1,2}; CESAR ITURRIAGA, DO^{1,2}; AND ROHIT B. VERMA, MD^{1,2}

¹Donald and Barbara Zucker School of Medicine at Hofstra/Northwell, Hempstead, NY, USA; ²Department of Orthopaedic Surgery, North Shore University Hospital, Manhasset, NY, USA

ABSTRACT

Background: Radiculopathy and myelopathy resulting from degenerative disc disease are currently treated with anterior cervical discectomy and fusion (ACDF), but there is a high incidence of adjacent segment disease after treatment.

Methods: With recent advances in cervical disc arthroplasty (CDA), we performed a review of published articles, examining the latest clinical data on the efficacy, safety, and complications of the current cervical disc devices on the market. We focused on the long-term follow up data of single-level, multi-level, and hybrid CDA as compared to ACDF, paying close attention to the newest cervical disc devices. A search was performed utilizing PubMed, Google Scholar, and Clinical Key to identify articles on 1-level, 2-level, and hybrid approaches to CDA. The articles were reviewed by two authors for relevance and power with higher emphasis placed on FDA IDE trials.

Results: The results conclude that CDA has an equivalent or improved clinical outcome when compared with ACDF with improved patient reported neck disability indexes and VAS neck pain scale. CDA also has lower rates of dysphagia, adjacent segment disease, and lower rates of reoperation when compared to ACDF. The data suggest there is no increased rate of reoperation in patients treated with multilevel CDA when compared to ACDF. In addition, the data from the limited clinical trials suggest that hybrid CDA and ACDF is safe and decreases risk of ASD.

Conclusion: CDA has been shown to be effective and safe with low complication rates. However, the data are of low quality, and more hybrid studies must be performed in the future to confirm these findings.

Clinical Relevance: The reduction in overall postsurgical complications including ASD and in the need for additional surgery in the CDA group.

Level of Evidence: 3.

Cervical Spine

Keywords: cervical disc arthroplasty, degenerative disc disease, anterior cervical discectomy and fusion (ACDF), M6-C artificial cervical device, mobi-C cervical device, proDisc-C, historical progression of cervical disc arthroplasty, adjacent segment disease, hybrid CDA, multilevel CDA

INTRODUCTION

Anterior cervical discectomy and fusion (ACDF) is the gold standard approach to surgical treatment of radiculopathic and myelopathic cervical pain. ACDF is highly effective in relieving cervical pain, but with fusions being performed at an increased rate and on younger populations, there has been growing concern over the risk of developing adjacent segment disease (ASD) and its associated symptomatic changes. A motion preserving alternative to ACDF, which has been gaining popularity in recent years, is cervical disc arthroplasty (CDA) which involves removing the intervertebral disc and replacing it with an artificial disc that mimics the natural spine biomechanics. The artificial cervical discs have been changing rapidly since their introduction in 1966 by Ulf Fernstrom. Newer discs have better postsurgical outcomes than before. However, the data were not summarized well. This article will analyze the most recent studies that examine the safety, efficacy, and related complications associated

with all of the devices on the market today. In addition, the article will look at long-term postoperative outcomes between CDA, ACDF, and hybrid surgical interventions.

Pathophysiology of Radiculopathy and Myelopathy

Cervical radiculopathy is a condition that occurs due to the compression of nerve roots in the cervical spine which leads to upper extremity symptoms such as impaired sensation, paresthesia's, weakness, and burning pain. The mechanism leading to nerve compression is typically due to osteophyte formation or disc herniation into the neural foramen. This usually begins with the nucleus pulposus and the anulus fibrosis losing water and proteoglycans with age which causes the disc to bulge out into the spinal canal or the neural foramen. The impingement of the nerve root leads to both mechanical and chemical damage. The compression of the nerve root leads to ischemia which damages the nerve. The ischemia also triggers the inflammatory cascade which leads to the release

of inflammatory markers like tumor necrosis factor α , interleukin 6 (IL-6), and matrix metalloproteinases. This inflammatory cascade leads to additional sensitization in the area and pain.^{1,2}

Myelopathy is the chronic progressive compression of the spinal cord which leads to a decline in physical function and quality of life.¹ Degeneration in the intervertebral discs leads to changes in the spinal biomechanics which lead to hypertrophy of the ligamentum flavum and facet joint laxity. The increased pressure can lead to osteophyte formation and vertebral misalignment which can lead to further spinal cord compression. These degenerative signs are commonly seen in patients with myelopathy; however, the vascular changes and the inflammatory cascade which occur in radiculopathy occur in myelopathy as well.^{1,2}

Biomechanics of Cervical Discs

The cervical spine kinematics consists of flexion/extension, lateral bending, and axial rotation. Cervical spine motion decreases with age in all 3 directions, so maintaining the native cervical spine motion is a goal of cervical spine arthroplasty. In the cervical spine, the center of rotation is typically thought to lie at the midline of the superior end plate of the inferior vertebral body, and the axis travels cranially and anteriorly as you progress inferiorly down the cervical spine.³ The location of the center of rotation changes in each cervical spine with motion. This variation in the center of rotation is called the instant center of rotation. Motion throughout the cervical spine is coupled with different forces. Flexion is coupled with anterior translation, and lateral bending is coupled with axial rotation. The coupling forces of the cervical spine allow for increased mobility without compromising cervical stability. Of clinical importance, the C5-C6 interspine has a large range of motion which may explain the increased rates of cervical spondylosis in this region.⁴ It is also known that the instant center of rotation is shifted in patients with degenerative disc disease (DDD), which is why many of the CDA devices on the market today attempt to mimic these coupling forces which preserves the native motion of the cervical spine and may reduce risks of other complications.⁵

Treatment

Patients with degenerative radiculopathy and myelopathy may be treated conservatively with anti-inflammatory medications and physical therapy as a first approach; however, many patients will experience progressively deteriorating symptoms.⁶ Patients who

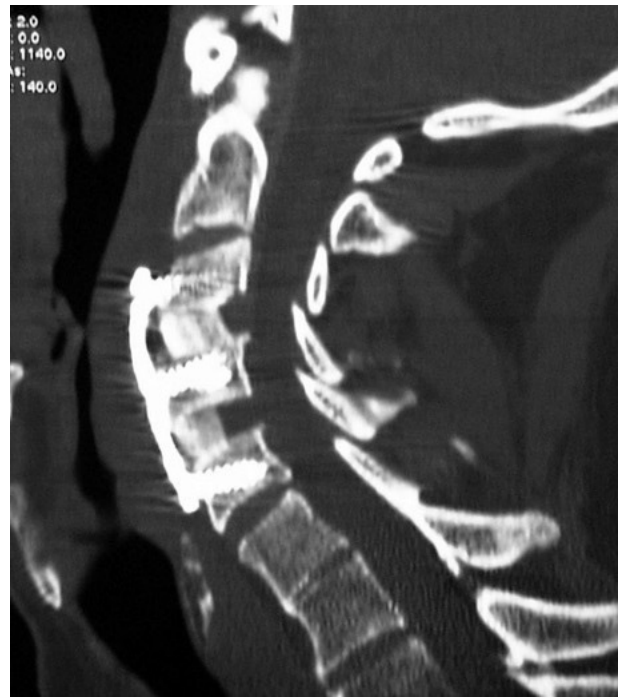

Figure 1. Computed tomographic image of a patient after 2-level anterior cervical discectomy and fusion with allograft.

are not candidates for conservative treatment or who have failed conservative treatment have several surgical options. ACDF is the standard of care for cervical radiculopathy and myelopathy secondary to DDD and spondylosis. ACDF decompresses neural elements, restores intradiscal height, restores normal cervical lordosis, and fuses affected segments. ACDF involves interbody fusion with bone grafts or interbody spacers and is frequently supplemented with anterior cervical plating (Figure 1). The procedure is contraindicated in patients with kyphosis, ossification of the posterior longitudinal ligament, or multilevel 3+ fusion.⁷

ACDF is a reliable and highly effective treatment for cervical radiculopathy and has been reported to provide greater than 90% relief in cervical radiculopathy pain.⁷ However, as spinal fusions are being performed more frequently and on younger patients, there is some concern about the long-term viability of the adjacent spinal segments.⁷ The fusion of the vertebral levels leads to hypermobility of the joints and increased intradiscal pressure above and below the fused levels. Specifically, ACDF increases the intradiscal pressure by about 50% in the proximal adjacent level and 125% in the distal adjacent level.³ The increase in pressure and motion increases stress on the adjacent segments which leads to the development of ASD. ASD is defined as new symptomatic degenerative changes adjacent to the level of fusion. Symptoms include neck pain from instability, radiculopathy, and/or

myelopathy. In contrast, adjacent segment degeneration refers to the radiographic findings with no corresponding clinical findings.⁷ Additional risk factors for developing ASD include fusion close to C5-C7, pre-existing cervical degeneration, and ACDF in patients under the age of 60.³ In a retrospective study of 70 patients, ASD occurred after single level ACDF in 54% of the cases, most commonly after a C5-C6 fusion.⁸ The annual incidence of ASD in fusions is 3% with a prevalence of 25% in the initial 10 years postfusion.⁹

Solutions to ASD: Cervical Disc Arthroplasty

A motion preserving alternative to ACDF is the CDA. CDA has been gaining popularity with recent advances in disc design. CDA involves removing the degenerative cervical disc and replacing it with an artificial disc device. The goals of CDA are to mimic the instant center of rotation and to maintain coupling forces in the cervical spine which helps maintain the cervical spine biomechanics. The preservation of the cervical spine motion reduces the risk of developing pseudoarthrosis, ASD, and allows for quicker return to activities.^{3,10}

Upon being introduced to the market, the indications for CDA were limited to patients with a single-level, myelopathic, or radiculopathic cervical disease between C3 and C7, who have failed 6 weeks of conservative treatment. Conservative treatment includes nonsteroidal anti-inflammatory drugs, physical therapy, and epidural steroid injections. Patients who have failed conservative treatment and have magnetic resonance pathology revealing cervical herniation of the nucleus pulposus or cervical DDD with foraminal stenosis and compression of a nerve root correlating to patients' symptoms of weakness and numbness that correlates with that specific nerve root are indicated for surgery. Surgery should be indicated sooner if patients are having progressive neurological decline, have myelopathic findings on physical exam with spinal cord compression, and myelomalacia on magnetic resonance imaging. CDA as a surgical option currently is indicated for 1- or 2-level disease in a younger patient, with healthy facet joints, moderate disc degeneration with a soft disc herniation, and/or moderate to severe spondylosis and foraminal narrowing. Contraindications include osteoporosis, significant kyphosis, instability, greater than 50% loss of disc height, facet arthropathy, ossification of the posterior longitudinal ligament, inflammatory arthropathy, and multilevel disease.³ Ideal candidates for CDA include young patients with a relatively healthy disc height with no arthropathy. This group of patients typically presents with an acute cervical disc herniation

rather than degenerative changes occurring over a long period of time. Since the majority of patients seeking surgical treatment have underlying DDD, it is harder to come across ideal candidates for CDA, which may explain the lower rates of CDA being performed when compared to ACDF.^{11,12}

The cervical discs available today vary in the number of components, the materials they are made of, and how constrained they are. The single-piece designs generally increase the shear stress on the implant vertebral body interface when compared to the multipiece device. The increased shear stress may lead to loosening of the implant and may require corrective surgery.⁸ Constrained devices have a fixed center of rotation and therefore have a limited range of motion. The unconstrained devices depend primarily on the surrounding soft tissues such as the facet joints and posterior tension band to limit their motion. This is of great importance when selecting devices in patients with previous cervical spine surgery, where unconstrained devices are contraindicated.⁷

History of CDA

The first artificial cervical device was a stainless steel ball bearing prosthesis which was implanted in the cervical and lumbar regions by Ulf Fernstrom in 1966. He implanted 191 lumbar and 13 cervical spheres in total. During the same time, a separate group in South Africa was experimenting with discs similar to Fernstrom's.⁸ Follow-up postimplantation revealed significant device subsidence, migration, and adjacent segment hypermobility. CDA fell out of favor due to the unfavorable results and most of the treatment focused on arthrodesis.⁹

Cummins Bristol Disc (Bristol, England)

It was not until 1989 that cervical arthroplasty was redesigned. Given the success and widespread use of lumbar arthroplasty, this reignited interest in the CDA. One of the early prototypes was designed by B.H. Cummins. The Cummins Bristol Disc developed in Bristol, United Kingdom, was a 2-piece metal on metal device composed of stainless steel.⁸ It had a ball-and-socket articulating surface designed with 2 anterior anchoring screws to the vertebral bodies. The initial results from the follow-up of 18 patients showed hardware failure and its high-profile design led to esophageal irritation and dysphagia in all the patients.⁹ This disc was later redesigned into the current Prestige ST Disc.¹³

Bryan Disc

(Medtronic Sofamor Danek, Memphis, TN, USA)

In the 1990s, Vincent Bryan, a neurosurgeon from Seattle, Washington, designed the Bryan Disc which consisted of 2 titanium alloy shells articulating around a polyurethane core. The device was unconstrained, meaning it was not held in the disc space with any hardware, so it requires a tight fit to be secured in place. Over time, the bone growth bonds the metallic devices to the vertebrae. The Bryan Disc is unique in its shock-absorbing titanium-on-polyurethane articulation with a surrounding polyurethane flexible membrane.⁸ This membrane forms a sealed space containing a saline lubricant to reduce friction and prevent migration of wear debris. However, there is the potential for membrane rupture, and the long-term durability of this design has not been clinically studied.¹³ The clinical success after 1 year was found to be 90% and there was no evidence of any hardware failure.⁶ A recent study in 2017 showed favorable long-term outcomes of the Bryan Disc at 10 years post implantation. The study revealed the majority of the prosthesis remained mobile at 10 years post implantation with 2% of patients requiring secondary surgery at the index level and 6% requiring surgery at an adjacent level.¹⁴ A drawback to the use of the Bryan Disc is that its insertion requires milling of the vertebral bodies which can lead to heterotopic ossification and auto fusion of the operated level.¹⁵

Prestige Disc






(Medtronic Sofamor Danek, Memphis, TN, USA)

In the early 2000s, Medtronic redesigned the Cummins Bristol stainless steel disc and reintroduced it as the Frenchay cervical disc, later renamed the Prestige Disc.¹³ They redesigned the articulating surface of the lower device, its anterior locking system, and the overall

profile of the device. In 2007, a randomized control trial compared the outcomes of the Prestige Disc implantation vs the traditional fusion. The results showed that segmental motion was preserved at 24 months, and there was a reduced rate of secondary surgeries when compared to ACDF.¹⁶ It was approved by the Food and Drug Administration (FDA) in July 2007 to be used for radiculopathy and myelopathy caused by herniated discs in the C3-C7 levels. The initial Prestige ST model was composed of stainless steel, whereas the newer Prestige LP model is made of a titanium ceramic and is coated with a porous titanium plasma spray which facilitates bone growth (Figure 2). Based on a 10-year postoperative study, CDA with the Prestige LP device required secondary revision surgery in 10.3% of the cases, whereas the traditional ACDF required revision in 13.6% of cases.¹⁷ This confirmed that the Prestige LP is an effective and safe single-level alternative to ACDF for appropriately selected patients with radiculopathy and myelopathy of the cervical spine.

**Porous Coated Motion Cervical Disc
(Cervitech, Rockaway, NJ, USA)**

The porous coated motion (PCM) cervical disc was originally invented by Paul McAfee, an orthopedic surgeon, but it was significantly improved by Helmut Link and Arnold Keller.¹⁸ PCM is a 2-piece device with each end plate composed of thin layers of titanium with electrochemically coated calcium phosphate with an inner core composed of ultra-high-molecular-weight polyethylene (UHMWPE). The PCM disc is unique in that it has a large radius UHMWPE bearing surface attached to the caudal end plate, which preserves the natural motion of the cervical spine increasing the radius of curvature.¹⁸ It is the only cervical device without any direct limitations in range of motion (ROM). The

Device	Prestige	Bryan	ProDisc-C	Cervicore	PCM
Image					
Standards	Diameter, mm 14 15 16 17 18	Width depth, mm 12 x 12 12 x 14 12 x 16 12 x 18	Width depth, mm 15 x 12 15 x 14 17 x 14 17 x 16 19 x 16 19 x 18	Width depth, mm 12 x 12 12 x 14 14 x 16 16 x 18	Width depth, mm 15 x 12 17 x 12 20 x 17
Height	11 mm 10.3 mm compressed	6 mm 7 mm 8 mm	5 mm 6 mm 7 mm	5-10 mm	6.5 mm 8.0 mm
Articulation	Chrome cobalt Metal-metal	Metal-polycarbonate-urethane	Metal-UHMWPE	Metal-metal	Metal-UHMWPE
Theoretical center of rotation location	Superior vertebra	Within implant	Inferior vertebra	Superior and inferior vertebra	Inferior vertebra
Initial fixation	Screws	Milled bone	Keels	Screws and spikes	Ridges

UHMWPE indicates ultra high molecular weight polyethylene.

Figure 2. Summary of the common cervical disc devices.¹³ PCM, porous coated motion; UHMWPE, ultra-high-molecular-weight polyethylene.

limitations in ROM are due to the increased stress on the facet joints due to the gliding mechanism of this device.¹³ It is composed of a calcium-coated titanium, which optimizes the end plate anchorage.¹⁸ The porous material coating is similar to the material used in the Charité prosthesis in lumbar arthroplasty except that the pore size has been reduced to match the smaller trabecular structure of the cervical vertebra. Long-term outcomes of the FDA investigational device exemption (IDE) prospective randomized control trial show equivalent or better clinical outcomes in the PCM disc treated patients than ACDF.¹⁹ The patients in the PCM disc treated group showed a higher patient satisfaction at 5 years postoperative with a lower incidence of secondary surgical procedures at 7 years postoperative.¹⁹

CerviCore Device (Stryker Spine, Allendale, NJ, USA)

The CerviCore device is a metal on metal, semi-constrained prosthesis with 2 keels containing spikes on each end plate. It has a saddle-shaped articulating surface which separates the axis of rotation for flexion/extension and lateral bending. The saddle shape allows for 2 separate centers of rotation. The center of rotation in the inferior vertebral body allows for flexion extension, and a center of rotation in the superior vertebral body controls lateral bending.¹³ The saddle shape theoretically imitates the motion found naturally in the cervical spine.²⁰ Based on an in vitro study, the CerviCore device approach and the traditional ACDF approach both decrease the cervical spine ROM; however, the CerviCore device permits more ROM and maintains some level of kinematics in the cadaver model.²¹ Although the in vitro and the early FDA IDE studies showed promising results, the FDA IDE for the CerviCore Cervical Discs (Stryker, Kalamazoo, MI, USA) was abandoned before completion.^{7,22} The metal-on-metal articulation used in the CerviCore devices seems to prevent the osteolysis found in metal on polyethylene devices; however, recent studies show increased serum concentrations of metal ions which can lead to hypersensitivity-related lymphocytic responses.²³

Of clinical importance, it was shown that the Prestige ST, CerviCore, and augmented PCM can lead to dysphagia due to the anteriorly elevated profile of the device.¹³ Another potential disadvantage of the ProDisc-C is the excessive amount of bone needed to be removed to explant the device. The overall benefits of the ProDisc-C and standard PCM is that they do not require milling or screw fixation which can decrease

risk of complications such as heterotopic ossification and autofusion.¹³

ProDisc-C Device (Synthes Inc., West Chester, PA, USA)

Based on a survey released to spine surgeons in 2017, ProDisc-C was the most common arthroplasty device used.¹² The ProDisc-C device was invented by Thierry Marnay of France, and it was approved by the FDA in December 2007. The design was based off of the ProDisc-L which is used in lumbar arthroplasty. It is a ball-and-socket joint and has 2 keels on each external surface which facilitates anchoring to the vertebral end plates, making it a semiconstrained device. It is a 3-piece uniaxial device with 2 end plates composed of cobalt chrome molybdenum and an articulating surface that is composed of ultra-high-molecular-weight polyethylene (UHMWPE) (Figure 2). The inferior end plate contains the polyethylene inlay which articulates with the superior end plate.²⁴ The ProDisc-C device showed promising results in an FDA IDE trial, which concluded that the neck pain intensity and frequency as well as arm pain were statistically lower during follow-up in patients postoperatively when compared with preoperative levels (Table). In addition, there was a significant decrease in the number of secondary surgeries in the ProDisc-C treatment group vs the ACDF group. At the 24-month postoperative period, 8.5% of the ACDF patients required a repeat operation, whereas only 1.8% of ProDisc-C group patients required any secondary procedures.²⁵ This study concluded that the ProDisc-C is safe and effective for treatment of cervical radiculopathy due to single-level disease, and clinical outcomes after ProDisc-C implantation were either equivalent or better than after fusion.^{25,26}

Mobi-C Cervical Disc (LDR Medical, Troyes, France)

Critics of the ProDisc-C disc believe it does not mimic the physiological motion of the spine since it has a fixed center of motion unlike the physiological spine with its center of rotation changing with flexion/extension and lateral bending. Newer discs achieve the physiological motion of the spine by using multiple moving components as seen in the Mobi-C or the M6-C devices. Another point of criticism of the ProDisc-C is that the device requires the creation of gutters in the end plates with a special chisel which leads to additional complications during the implantation of the device.²⁶

In an attempt to solve these issues, the Mobi-C device was developed which is a semiconstrained disc

Table. Summary comparing values from 3 different Food and Drug Administration investigational device exemption studies including ProDisc-C, Mobi-C, and M6-C.

Study and Disc	Mean Blood Loss	Surgical Time	Reduction in NDI	Reduction in VAS Neck Pain	Reduction in VAS Arm Pain	Rates of Reoperation	ASD
Murray et al ²⁵							
ProDisc-C (<i>n</i> = 106)	83.5 mL	107 min	32.5%	4.6 cm	4.3 cm	1.90%	^a
ACDF (<i>n</i> = 103)	63.5 mL	98.7 min	31.7%	4.3 cm	4.4 cm	8.50%	^a
Davis et al ²⁶							
Mobi-C (<i>n</i> = 225)	^a	^a	36.5%	5.4 cm	5.6 cm	4.00%	41.50%
ACDF (<i>n</i> = 105)	^a	^a	28.5%	4.8 cm	5.3 cm	15.20%	85.90%
Sasso et al ²⁷							
M6-C (<i>n</i> = 83)	31 mL	81 min	41.8%	5.9 cm	6.9 cm	0.00%	^a

The reductions in Neck Disability Index (NDI) and visual analog scale (VAS) measure the difference between the value measured prior to surgery and the value measured at 2 years postsurgery.

^aData missing where unavailable.

Abbreviations: ACDF, anterior cervical discectomy and fusion; ASD, adjacent segment disease.

composed of 2 titanium shells with a central polyethylene insert.²⁶ It has a self-centering mobile bearing which allows for 6° ROM and optimal positioning of the plates, which can simplify the implantation.²⁶ The inferior plate has 2 peripheral stops which limit the disc's mobility and can prevent the migration of the device. The Mobi-C Cervical Disc is commonly used outside the United States, and data from a 4-year IDE study suggest significant advantages in 2-level Mobi-C CDA vs 2-level ACDF (Table).²⁶ In a 2-year follow-up of patients after a Mobi-C CDA, the mean improvement in Neck Disability Index (NDI) score was 36.5 ± 21.3 for the Mobi-C group and 28.5 ± 18.3 for the ACDF group ($P < .0048$). Both the ACDF and the Mobi-C group had an improvement in their visual analog scale (VAS) neck pain at 48 months; however, the Mobi-C group experienced a greater improvement at 53 ± 30 , and the ACDF group experienced a 48 ± 29 improvement ($P < .0048$). There was no statistically significant difference in rates of complications between the ACDF and the Mobi-C group. There was a significant increase in rate in reoperation in the ACDF group at 15.2% compared to 4.0% in the Mobi-C group. In addition, the rate of ASD in the Mobi-C group was 41.5% and 85.9% for the ACDF group. The data from the 48-month FDA IDE follow-up of the Mobi-C CDA suggest improved clinical outcomes when compared to ACDF and signify lower rates of reoperation, making Mobi-C arthroplasty a safe and effective alternative to ACDF.²⁶

M6-C Cervical Device (Orthofix Medical, Lewisville, Texas, USA)

The M6-C disc (Figure 3) is the most recent and advanced cervical disc on the market today. The novel disc mimics the anatomy and ROM found in the native cervical disc. It consists of a compressible

polycarbonate inner core that imitates the nucleus pulposus, and a polyethylene woven fiber that surrounds the inner core mimicking the annulus fibrosis.²⁸ Two titanium inner end plates hold the disc together. The outer titanium end plates contain a tri-keel design, which allows for anchoring to the adjacent vertebral bodies during implantation.²⁹ The outer end plates are coated with a porous titanium material, which promotes osseointegration. The prosthetic disc also has a polymer sheath surrounding the inner core and the woven fiber, which prevents any ingrowth into the disc and captures any wear debris.²⁸ A 2-year follow-up of 5 FDA IDE investigations of the M6-C disc resulted in no cases of neurologic deterioration, and there were no reports of revision, removal, or supplemental fixation. The results show significant reduction in the NDI from 55.4 preoperatively to 13.6 at 2-year follow-up. There was also significant improvement in the VAS pain scale.²⁷ The




Figure 3. M6-C disc.²⁸

results of this 2-year follow-up study support the safety and efficacy of the M6-C disc; however, the study lacked a control ACDF group for comparisons. Additional studies are needed to compare the efficacy of M6-C to ACDF.

In a study by Pham et al, it was concluded that there was no statistically significant difference in the overall flexion range between the M6-C and the Mobi-C prosthesis.³⁰ However, overall range of extension was found to be greater in the Mobi-C prosthesis ($14.2^\circ \pm 5.1^\circ$) compared to the M6-C ($7.3^\circ \pm 4.6^\circ$) ($P = 0.0009$). This is expected as it is a semiconstrained device.³⁰ More studies must be done to observe the long-term changes in ROM.

Single-Level CDA vs ACDF

A 7-year follow-up of a prospective randomized FDA study of single-level ProDisc-C CDA concluded that ACDF had 400% more revision procedures than the CDA group ($P = 0.0099$). Not only did CDA have less secondary surgeries, but CDA resulted in an average savings of \$12,789 when compared with ACDF and had a quality-adjusted life year gain of 0.16 with CDA.³¹ A Cochrane review including 9 randomized controlled trials with 2400 participants in total, concluded that the arthroplasty has better outcomes than ACDF with regard to arm pain, neck pain, neck-related function, and global health status. The differences between the 2 treatment groups were small in magnitude, but the data consistently favored CDA when compared to ACDF.³²

ASD in CDA vs ACDF

There is a significant amount of literature that shows the decreased rate of ASD in patients who undergo CDA vs ACDF. A recent meta-analysis of 20 RCTs and 4004 patients concluded that CDA was superior to ACDF with fewer adverse events, fewer cases of ASDs, fewer reoperations, better neurological success, better ROM, and arm pain functional recovery.³³ The study concluded that the rate of ASD was significantly lower in the CDA group compared to the ACDF group with a relative risk of 0.62 and a 95 % CI (0.43, 0.88).³³ Another study compared incidence and risk of ASD in patients who underwent CDA vs ACDF at 38 months after treatment. The authors concluded that there was no significant difference in risk of developing ASD in the CDA vs ACDF group in patients treated for cervical DDD. However, results did show a significantly greater finding of 24.8 % ASD in radiographic images in the group that underwent ACDF treatment with a 9 % ASD in radiographic findings in the CDA group ($P < 0.0001$).³⁴

Incidence of Dysphagia in Cervical Arthroplasty and ACDF

A common complication in ACDF is dysphagia with multiple different etiologies. One likely cause of dysphagia is the anterior profile of the implant device used, which protrudes into the retropharyngeal space. For this reason, it is expected that a no-profile cervical disc may reduce or eliminate the dysphagia often encountered post ACDF. In a study that examined the rate of dysphagia between a group treated with ACDF and a group treated with a no-profile CDA showed 42.1% of the ACDF group developed dysphagia, whereas 13.8% of the CDA group developed dysphagia.²⁷ This study suggests a significantly lower rate of dysphagia with a no-profile disc arthroplasty compared to ACDF for a single-level disc disease between C3 and C7.³⁵

Two-Level ACDF vs CDA

There is significant literature showing that CDA is superior to ACDF in single-level operations with better clinical outcomes; however, there is less literature that examines 2-level cervical operations. The available literature shows some mixed results; however, the majority of the trials suggest CDA as a more effective alternative to ACDF with fewer secondary surgeries. A study by Fay et al examines the clinical outcomes of 77 patients who underwent 2-level anterior cervical operations for DDD. The patients were split into 2-level CDA and ACDF groups. The 2 groups experienced similar blood loss and no differences in clinical outcomes and adverse events at 40 months after surgery. However, the CDA group had increased their ROM significantly more to 23.5° vs 20.1° for the ACDF group ($P = 0.018$). The CDA group also experienced a longer operating time compared to the ACDF group (315.5 ± 82.0 vs 224.9 ± 61.8 minutes, $P < 0.001$).³⁶ Although there were no significant differences in the adverse events at 40 months, there was a significant increase in the ROM for the CDA group.

Other studies suggest that CDA patients have greater clinical outcome scores and lower rates of reoperation. A 4-year follow-up of 291 patients showed ACDF to have a 15.2% reoperation rate vs 4% for the CDA group and an increased rate of radiographic ASD at 86% for the ACDF group vs 42% in the CDA group.²⁶ Another 5-year follow-up by Radcliff et al examined 225 patients who underwent CDA and 105 patients who underwent ACDF. The results showed greater clinical improvement and satisfaction in the CDA group with a significantly lower reoperation rate at 4% vs 16% for ACDF at the index level and 3.1% vs 11.4% reoperation at the adjacent level.³⁷ This suggests

CDA results in less secondary surgeries. The 2 groups had statistically insignificant differences in the rate of complications. A meta-analysis performed by Zou et al concludes that the 2 contiguous level CDA is equivalent to, and in some cases, has more significant clinical outcomes than 2-level ACDF.³⁸ The analysis shows a decreased effective blood loss, reoperation rate, and ASD in the 2-level CDA when compared to ACDF. The analysis does not show significant differences in surgical time, postoperative complications, or postoperative pain scores. The literature concludes that 2-level CDA provides better clinical outcomes with a lower rate of reoperation than ACDF, but it may have a longer operating time and costs \$2139 more on average when compared to ACDF.^{26,39}

Multilevel vs Single-Level CDA

When comparing multilevel CDA vs single-level CDA, the meta-analysis concludes there is no increased rate of reoperation with multilevel vs single-level CDA, no increased rate of ASD in the multilevel vs single-level CDA, and cervical mobility is maintained in both groups at 2 years follow-up.⁴⁰ The study concluded there was no significant difference in NDI scores, VAS neck scores, VAS arm scores, or rates of heterotopic ossification between the multilevel CDA group vs the single-level CDA group at 1 and 2 years follow-up post-operatively.⁴⁰ A few limitations exist with this study including a lack of randomized controlled trials and the statistical power could be improved by having more larger studies included in the analysis.

Hybrid Surgery

Another option for DDD treatment is a hybrid surgery approach, which incorporates ACDF and CDA together as a surgical treatment. One level may be treated with ACDF and another level is treated with motion preserving CDA. Theoretically, this approach preserves motion and decreases hypermobility at adjacent levels, thus decreasing the risk of ASD. This would be preferred to ACDF since it maintains the cervical spine biomechanics. A recent systematic review of 15 studies revealed that hybrid surgery maintains motion at the operated levels and decreases adverse effects on adjacent segments. The evidence suggests that hybrid surgery may be favorable to ACDF or CDA alone; however, the evidence is of low quality. There is no consensus on the operating time or effective blood loss when comparing CDA, ACDF, or hybrid surgery.^{3,41}

Complications of CDA

CDA is a relatively safe procedure; however, there are certain risks associated with the procedure. Known complications include longer surgical time and increased estimated blood loss compared to ACDF. Heterotopic ossification (HO) is another common complication of CDA. Based on a retrospective cohort study of 45 patients, it was found that 42.2% of the patients developed HO post CDA; however, functional improvement was maintained despite the development of HO.³⁷ In addition, males are more likely to develop HO than females.¹⁵ The patient may also experience spinal malalignment and osteolysis.²³ As previously mentioned in the article, the patient may develop metal hypersensitivity reactions.²³ The patient may also experience loss of lordosis and disc height. The CDA may also predispose to neck pain from increased facet motion and stress.⁷

Revision of CDA

Although numerous studies have demonstrated the efficacy and safety of CDA, there are mixed data on the revision rates between CDA and ACDF. Nandyala et al performed a retrospective review of patients who underwent revision surgery for ACDF and CDA from 2002 to 2011 and concluded the revision rate for CDA is 7.7% and 2% for ACDF.⁴² Although the data suggest CDA to have more revisions over ACDF, there is conflicting evidence that argues the opposite. Zhao-Ming Zhong et al suggest the percentage of reoperation in their meta-analysis was 6% for the CDA group and 12 % for the ACDF group. A likely explanation for the increased rate of revision in patients treated with ACDF may be due to the increased rate of ASD. The publication does, however, have a few limitations with the funnel plot suggesting evidence of positive outcomes bias.⁴³ CDA patients who undergo revision experience a greater risk of wound infections, hematomas, dysphagia, and neurologic complications when compared to the primary procedure.⁴² The increased rates of complications in CDA revision vs ACDF revision may be attributed to the more invasive exposure needed to remove the arthroplasty device, which can lead to further damage.⁴² In addition, revision of CDA was more highly associated with longer operative times, increased blood loss, longer hospital stays, and increased total cost.⁴² Revision of CDA is indicated in patients with ASD and those who experience catastrophic implant retropulsion into the canal, which can lead to paralysis.⁴³ In a study comparing surgical revision between single-level and multilevel ACDF, it was concluded that revision rates were 10.68% in the multilevel ACDF and 9.16% in the

single-level ACDF at 2-year follow-up postsurgery.⁴⁴ The increased revision rate in multilevel ACDF may be due to pseudoarthrosis or other degenerative pathologies since the incidence of ASD in multilevel ACDF is lower than in single-level ACDF.⁴⁴

Future Directions

The current literature suggests that CDA is safe, effective, and has similar or improved clinical outcomes when compared to ACDF; however, there is insufficient studies to show the long-term outcomes. More evidence is needed for multilevel CDA since much of the data are not of high quality. In addition, a study that compares multilevel CDA vs ACDF vs the hybrid approach in the treatment of multilevel DDD is needed. It is of great importance to know the indications and complications of single-level CDA, multilevel CDA, and the hybrid approach in order to select the best possible treatment for the patient. The efficacy of the M6-C disc may also be strengthened by performing an additional prospective investigation with a larger population size and by including an ACDF control group to compare the rates of ASD and the long-term clinical outcomes. The ultimate goal of CDA is to have a single surgical intervention that would decrease any future complications, which would normally lead to additional secondary surgeries, and to use CDA in patients with multilevel spondylitic changes.

REFERENCES

- Garfin S, Eismont F, Bell G, Bono C, Fischgrund J. *Rothman-Simeone and Herkowitz's the spine*. 7th ed. Elsevier; 2017.
- Iyer S, Kim HJ. Cervical radiculopathy. *Curr Rev Musculoskelet Med*. 2016;9(3):272–280. doi:10.1007/s12178-016-9349-4.
- Laratta JL, Shillingford JN, Saifi C, Riew KD. Cervical disc arthroplasty: a comprehensive review of single-level, multi-level, and hybrid procedures. *Global Spine J*. 2018;8(1):78–83. doi:10.1177/2192568217701095.
- Richard A, Banton D. Biomechanics of the spine. *Spinal Research Foundation*. 2012;7(2):12–20.
- Liu B, Liu Z, VanHoof T, Kalala JP, Zeng Z, Lin X. Kinematic study of the relation between the instantaneous center of rotation and degenerative changes in the cervical intervertebral disc. *Eur Spine J*. 2014;23(11):2307–2313. doi:10.1007/s00586-014-3431-7.
- Shimomura T, Sumi M, Nishida K, et al. Prognostic factors for deterioration of patients with cervical spondylotic myelopathy after nonsurgical treatment. *Spine (Phila Pa 1976)*. 2007;32(22):2474–2479. doi:10.1097/BRS.0b013e3181573aee.
- Staudt MD, Das K, Duggal N. Does design matter? Cervical disc replacements under review. *Neurosurg Rev*. 2016;41(2):399–407. doi:10.1007/s10143-016-0765-0.
- Le H, Thongtrangan I, Kim DH. Historical review of cervical arthroplasty. *FOC*. 2004;17(3):1–9. doi:10.3171/foc.2004.17.3.1.
- Baaj AA, Uribe JS, Vale FL, Preul MC, Crawford NR. History of cervical disc arthroplasty. *Neurosurg Focus*. 2009;27(3):E10. doi:10.3171/2009.6.FOCUS09128.
- McAfee PC, Cunningham B, Dmitriev A, et al. Cervical disc replacement—porous coated motion prosthesis. *Spine*. 2003;28(Supplement):S176–S185. doi:10.1097/01.BRS.0000092219.28382.0C.
- Kolenkiewicz M, Włodarczyk A, Wojtkiewicz J. Diagnosis and incidence of spondylosis and cervical disc disorders in the University Clinical Hospital in Olsztyn, in years 2011–2015. *Biomed Res Int*. 2018;2018:1–7. doi:10.1155/2018/5643839.
- Chin-See-Chong TC, Gadraj PS, Boelen RJ, Harhangi BS. Current practice of cervical disc arthroplasty: a survey among 383 AOSpine International members. *Neurosurg Focus*. 2017;42(2):E8. doi:10.3171/2016.11.FOCUS16338.
- Yi S, Lee DY, Kim DH, et al. Cervical artificial disc replacement. *Neurosurgery Quarterly*. 2008;18(2):89–95. doi:10.1097/WNQ.0b013e318172f349.
- Dejaegher J, Walraevens J, van Loon J, Van Calenbergh F, Demaerel P, Goffin J. 10-year follow-up after implantation of the Bryan cervical disc prosthesis. *Eur Spine J*. 2016;26(4):1191–1198. doi:10.1007/s00586-016-4897-2.
- Yi S, Shin DA, Kim KN, et al. The predisposing factors for the heterotopic ossification after cervical artificial disc replacement. *Spine J*. 2013;13(9):1048–1054. doi:10.1016/j.spinee.2013.02.036.
- Gornet MF, Burkus JK, Shaffrey ME, Argires PJ, Nian H, Harrell FE. Cervical disc arthroplasty with PRESTIGE LP disc versus anterior cervical discectomy and fusion: a prospective, multicenter investigational device exemption study. *J Neurosurg Spine*. 2015;23(5):558–573. doi:10.3171/2015.1.SPINE14589.
- Gornet MF, Burkus JK, Shaffrey ME, Schranck FW, Copay AG. Cervical disc arthroplasty: 10-year outcomes of the Prestige LP cervical disc at a single level. *J Neurosurg Spine*. 2019;31(3):317–325. doi:10.3171/2019.2.SPINE1956.
- Pimenta L, McAfee PC, Cappuccino A, Bellera FP, Link HD. Clinical experience with the new artificial cervical PCM (Cervitech) disc. *Spine J*. 2004;4(6):S315–S321. doi:10.1016/j.spinee.2004.07.024.
- Phillips FM, Geisler FH, Gilder KM, Reah C, Howell KM, McAfee PC. Long-term outcomes of the US FDA IDE prospective, randomized controlled clinical trial comparing PCM cervical disc arthroplasty with anterior cervical discectomy and fusion. *Spine (Phila Pa 1976)*. 2015;40(10):674–683. doi:10.1097/BRS.0000000000000869.
- Pisano A, Helgeson M. Cervical disc replacement surgery: biomechanical properties, postoperative motion, and postoperative activity levels. *Curr Rev Musculoskelet Med*. 2017;10(2):177–181. doi:10.1007/s12178-017-9400-0.
- Colle KO, Butler JB, Reyes PM, Newcomb A, Theodore N, Crawford NR. Biomechanical evaluation of a metal-on-metal cervical intervertebral disc prosthesis. *Spine J*. 2013;13(11):1640–1649. doi:10.1016/j.spinee.2013.06.026.
- Abitbol J.-J, Maroon JC, Edwards WS, Fischgrund JS. 2-Year results from four IDE study sites: cervicore® intervertebral disc vs. fusion. *Spine J*. 2010;10(9):S139–S140. doi:10.1016/j.spinee.2010.07.359.
- Willert H.-G, Buchhorn GH, Fayyazi A, et al. Metal-on-metal bearings and hypersensitivity in patients with artificial hip joints. *J Bone Joint Surg Am*. 2005;87(1):28–36. doi:10.2106/00004623-200501000-00006.

24. Sekhon LHS, Ball J. Artificial cervical disc replacement: principles, types and techniques. *Neurol India*. 2005;53(4):445. doi:10.4103/0028-3886.22611.
25. Murrey D, Janssen M, Delamarter R, et al. Results of the prospective, randomized, controlled multicenter Food and Drug Administration investigational device exemption study of the ProDisc-C total disc replacement versus anterior discectomy and fusion for the treatment of 1-level symptomatic cervical disc disease. *Spine J*. 2009;9(4):275–286. doi:10.1016/j.spinee.2008.05.006.
26. Davis RJ, Nunley PD, Kim KD, et al. Two-level total disc replacement with Mobi-C cervical artificial disc versus anterior discectomy and fusion: a prospective, randomized, controlled multicenter clinical trial with 4-year follow-up results. *J Neurosurg Spine*. 2015;22(1):15–25. doi:10.3171/2014.7.SPINE13953.
27. Sasso RC, Phillips FM, Guyer RD, et al. M6-C artificial cervical disc: two-year follow-up at five IDE investigation centers. *Spine J*. 2017;17(10):S116. doi:10.1016/j.spinee.2017.07.151.
28. Lauryssen C, Coric D, Dimmig T, Musante D, Ohnmeiss DD, Stubbs HA. Cervical total disc replacement using a novel compressible prosthesis: results from a prospective Food and Drug Administration-regulated feasibility study with 24-month follow-up. *Int J Spine Surg*. 2012;6(1):71–77. doi:10.1016/j.ijssp.2012.02.001.
29. König A, Spetzger U. Choice of Implant. *Degenerative Diseases of the Cervical Spine*. 2017:49–77. doi:10.1007/978-3-319-47298-0_7.
30. Pham M, Phan K, Teng I, Mobbs RJ. Comparative study between M6-C and Mobi-C cervical artificial disc replacement: biomechanical outcomes and comparison with normative data. *Orthop Surg*. 2018;10(2):84–88. doi:10.1111/os.12376.
31. Radcliff K, Lerner J, Yang C, Bernard T, Zigler JE. Seven-year cost-effectiveness of ProDisc-C total disc replacement: results from investigational device exemption and post-approval studies. *J Neurosurg Spine*. 2016;24(5):760–768. doi:10.3171/2015.10.SPINE15505.
32. Boselie TFM, Willems PC, van Mameren H, de Bie RA, Benzel EC, van Santbrink H. Arthroplasty versus fusion in single-level cervical degenerative disc disease. *Spine*. 2013;38(17):E1096–E1107. doi:10.1097/BRS.0b013e3182994a32.
33. Xie L, Liu M, Ding F, Li P, Ma D. Cervical disc arthroplasty (CDA) versus anterior cervical discectomy and fusion (ACDF) in symptomatic cervical degenerative disc diseases (CDDDs): an updated meta-analysis of prospective randomized controlled trials (RCTs). *Springerplus*. 2016;5(1):1188. doi:10.1186/s40064-016-2851-8.
34. Nunley PD, Jawahar A, Kerr EJ, et al. Factors affecting the incidence of symptomatic adjacent-level disease in cervical spine after total disc arthroplasty. *Spine*. 2012;37(6):445–451. doi:10.1097/BRS.0b013e31822174b3.
35. Segebarth B, Datta JC, Darden B, et al. Incidence of dysphagia comparing cervical arthroplasty and ACDF. *SAS J*. 2010;4(1):3–8. doi:10.1016/j.esas.2009.12.001.
36. Fay L-Y, Huang W-C, Tsai T-Y, et al. Differences between arthroplasty and anterior cervical fusion in two-level cervical degenerative disc disease. *Eur Spine J*. 2014;23(3):627–634. doi:10.1007/s00586-013-3123-8.
37. Radcliff K, Coric D, Albert T. Five-year clinical results of cervical total disc replacement compared with anterior discectomy and fusion for treatment of 2-level symptomatic degenerative disc disease: a prospective, randomized, controlled, multicenter investigational device exemption clinical trial. *J Neurosurg Spine*. 2016;25(2):213–224. doi:10.3171/2015.12.SPINE15824.
38. Zou S, Gao J, Xu B, Lu X, Han Y, Meng H. Anterior cervical discectomy and fusion (ACDF) versus cervical disc arthroplasty (CDA) for two contiguous levels cervical disc degenerative disease: a meta-analysis of randomized controlled trials. *Eur Spine J*. 2017;26(4):985–997. doi:10.1007/s00586-016-4655-5.
39. Ament JD, Yang Z, Nunley P, Stone MB, Kim KD. Cost-effectiveness of cervical total disc replacement vs fusion for the treatment of 2-level symptomatic degenerative disc disease. *JAMA Surg*. 2014;149(12):1231–1239. doi:10.1001/jamasurg.2014.716.
40. Zhao H, Cheng L, Hou Y, et al. Multi-level cervical disc arthroplasty (CDA) versus single-level CDA for the treatment of cervical disc diseases: a meta-analysis. *Eur Spine J*. 2015;24(1):101–112. doi:10.1007/s00586-014-3429-1.
41. Jia Z, Mo Z, Ding F, He Q, Fan Y, Ruan D. Hybrid surgery for multilevel cervical degenerative disc diseases: a systematic review of biomechanical and clinical evidence. *Eur Spine J*. 2014;23(8):1619–1632. doi:10.1007/s00586-014-3389-5.
42. Nandyala SV, Marquez-Lara A, Fineberg SJ, Singh K. Comparison of revision surgeries for one- to two-level cervical TDR and ACDF from 2002 to 2011. *Spine J*. 2014;14(12):2841–2846. doi:10.1016/j.spinee.2014.03.037.
43. Zhong ZM, Zhu SY, Zhuang JS, Wu Q, Chen JT. Reoperation after cervical disc arthroplasty versus anterior cervical discectomy and fusion: a meta-analysis. *Clin Orthop Relat Res*. 2016;474(5):1307–1316. doi:10.1007/s11999-016-4707-5.
44. Veeravagu A, Cole T, Jiang B, Ratliff JK. Revision rates and complication incidence in single- and multilevel anterior cervical discectomy and fusion procedures: an administrative database study. *Spine J*. 2014;14(7):1125–1131. doi:10.1016/j.spinee.2013.07.474.

Funding: The author(s) received no financial support for the research, authorship, and/or publication of this article.

Declaration of Conflicting Interests: The authors report no conflicts of interest with respect to the research, authorship, and/or publication of this article.

Corresponding Author: David Turkov, Donald and Barbara Zucker School of Medicine at Hofstra/Northwell, 500 Hofstra Blvd, Hempstead, NY 11549, USA; dturkov1@pride.hofstra.edu

Published 20 January 2022

This manuscript is generously published free of charge by ISASS, the International Society for the Advancement of Spine Surgery. Copyright © 2021 ISASS. To see more or order reprints or permissions, see <http://ijssurgery.com>.