

## Full Endoscopic Thoracic Discectomy: Is the Interlaminar Approach an Alternative to the Transforaminal Approach? A Technical Note

Marcelo Campos Moraes Amato, Bruno César Aprile, Luiz Adriano Esteves, Vinicius Marques Carneiro and Ricardo Santos de Oliveira

*Int J Spine Surg* 2022, 16 (2) 309-317

doi: <https://doi.org/10.14444/8209>

<https://www.ijssurgery.com/content/16/2/309>

This information is current as of May 17, 2025.

---

**Email Alerts** Receive free email-alerts when new articles cite this article. Sign up at: <http://ijssurgery.com/alerts>

# Full Endoscopic Thoracic Discectomy: Is the Interlaminar Approach an Alternative to the Transforaminal Approach? A Technical Note

MARCELO CAMPOS MORAES AMATO, MD, PhD<sup>1</sup>; BRUNO CÉSAR APRILE, MD<sup>2</sup>; LUIZ ADRIANO ESTEVES, MD, PhD<sup>3</sup>; VINICIUS MARQUES CARNEIRO, MD, PhD<sup>4</sup>; AND RICARDO SANTOS DE OLIVEIRA, MD, PhD<sup>4</sup>

<sup>1</sup>Neurosurgeon, Amato – Instituto de Medicina Avançada, São Paulo, Brazil; <sup>2</sup>Orthopedic surgeon, Clínica SOU, São Paulo, Brazil; <sup>3</sup>Neurosurgeon, Universidade Estadual de Campinas, Campinas, Brazil; <sup>4</sup>Neurosurgeon, Faculdade de Medicina de Ribeirão Preto, Universidade de São Paulo, São Paulo, Brazil

## ABSTRACT

**Background:** Various approaches are used for decompressive surgeries in the thoracic spine depending on the location and consistency of the pathology, always avoiding manipulation of the thoracic spinal cord. Recently, there has been an effort to achieve adequate results and reduce morbidity with minimally invasive surgeries. Good outcomes and the advantages of full endoscopic spine surgery (FESS) have been proven for surgical correction of herniated discs and stenoses in the lumbar and cervical spine. Similar evidence has recently been described for the thoracic spine, but it has not previously been reported in Brazil. Although the transforaminal approach is already established for the thoracic spine, the newly described interlaminar approach is equally efficient, and both techniques must be considered when treating thoracic spine diseases. The objective of the present article was to present the full endoscopic interlaminar and transforaminal techniques in patients with symptomatic disc herniation of the thoracic spine, discuss the rationality for implementing FESS in thoracic spine, and discuss the rationality in choosing between both approaches.

**Methods:** Two patients were submitted to thoracic FESS. A transforaminal approach was chosen for a T10-T11 foraminal disc herniation; an interlaminar approach was selected for a paramedian T7-T8 disc extrusion. Data regarding operating time, intraoperative images, hospital stay, visual analog scales before and after FESS, course of recovery, and surgery satisfaction were evaluated.

**Results:** The patients had eventless surgeries, improved from preoperative pain without morbidity. Both were satisfied and recovered well. Hospital stay was less than 6 hours after surgery.

**Conclusions:** Transforaminal and interlaminar FESS for thoracic disc herniation are safe, efficient, and minimally invasive alternatives.

**Clinical Relevance:** Despite being an innovative technique with evident advantages, it should be carefully considered along with conventional technique for the treatment of thoracic spine diseases, since its clinical relevance is yet to be determined.

**Level of Evidence:** 4.

Endoscopic Minimally Invasive Surgery

Keywords: Intervertebral disc displacement, percutaneous discectomy, endoscopic surgical procedures, thoracic vertebrae

## INTRODUCTION

Surgery for thoracic disc herniations is comparatively rare, but often challenging. Various surgical techniques such as laminectomy, transpedicular approach, costotransversectomy, axillary, transthoracic, thoracoscopic, or transternal approach have been described.<sup>1–5</sup> Morbidity associated with some of these approaches may discourage surgical treatment, as the approach may cause more harm than the disease itself.<sup>6</sup> Depending on the location and severity of symptoms, such as intolerable and/or persistent pain and/or neurological deficits, surgery is necessary. Knowledge of different techniques and

approaches is required for individual planning.<sup>4,6–8</sup> Besides the location and consistency of the pathology, avoiding manipulation of the thoracic spinal cord is of primary concern in choosing the best approach. There are no clear standards, but recent minimally invasive surgical attempts have achieved adequate results and reduced morbidity.<sup>1,4,6,7</sup> Good outcomes and advantages of full endoscopic spine surgery (FESS) have been described for surgeries of herniated discs and stenoses in the lumbar and cervical spine.<sup>7,9–14</sup> For the thoracic spine, although the full endoscopic transforaminal approach has been described since 2006,<sup>6</sup> the interlaminar approach to treat disc herniation of the thoracic spine has only been recently published,<sup>7,15,16</sup>

both approaches must be considered when treating thoracic spinal diseases.

In this study, we present the full endoscopic interlaminar and transforaminal techniques in patients with symptomatic disc herniation of the thoracic spine and discuss the rationality for implementing FESS in the thoracic spine and choosing between both approaches.

## METHODS

### Literature Search

The following searches of the literature from 1980 to February 2021 were conducted to retrieve case series and case reports of interlaminar FESS of the thoracic spine:

1. A core search by computer-aided searching of PubMed and Google Scholar databases. “Thoracic” and “endoscopic” and “interlaminar” were identified as key search terms from an initial recent literature screen and were secondarily used in combination with “disc” and “discectomy.”
2. A standard search including citation tracking from all papers identified by the above strategy and from review articles.

Titles and abstracts meeting the inclusion criteria were screened. Articles considering the interlaminar approach only for ossification of the flavum ligament were excluded. Three studies were identified, and patient characteristics, level(s) of disc herniation, surgery details, and postoperative course were extracted from each article (Table 1).

## Full Endoscopic Instruments

The endoscope used was a TESSYS HD foramino-scope (Joimax) that has an outside diameter of 6.3 mm, has a working length of 208 mm, and is introduced through a working sheath. The view angle is 30°. For the uniportal technique, an intraendoscopic working channel with a diameter of 3.7 mm, light guide, inflow for continuous irrigation, and the rod lens system are needed. For coagulation and tissue ablation, a bipolar articulating probe that applies a radiofrequency current (Elliquence—Surgimax), which reduces the transmission of heat to adjacent tissue structures, is used. Surgical site irrigation was performed using a Richard Wolf Fluid Control 2203 automatic pump. Initial settings were 350 mL/min for flow rate and 60 mm Hg for maximum irrigation pressure; minor adjustments were made to obtain the best visual clarity for performing the surgery.

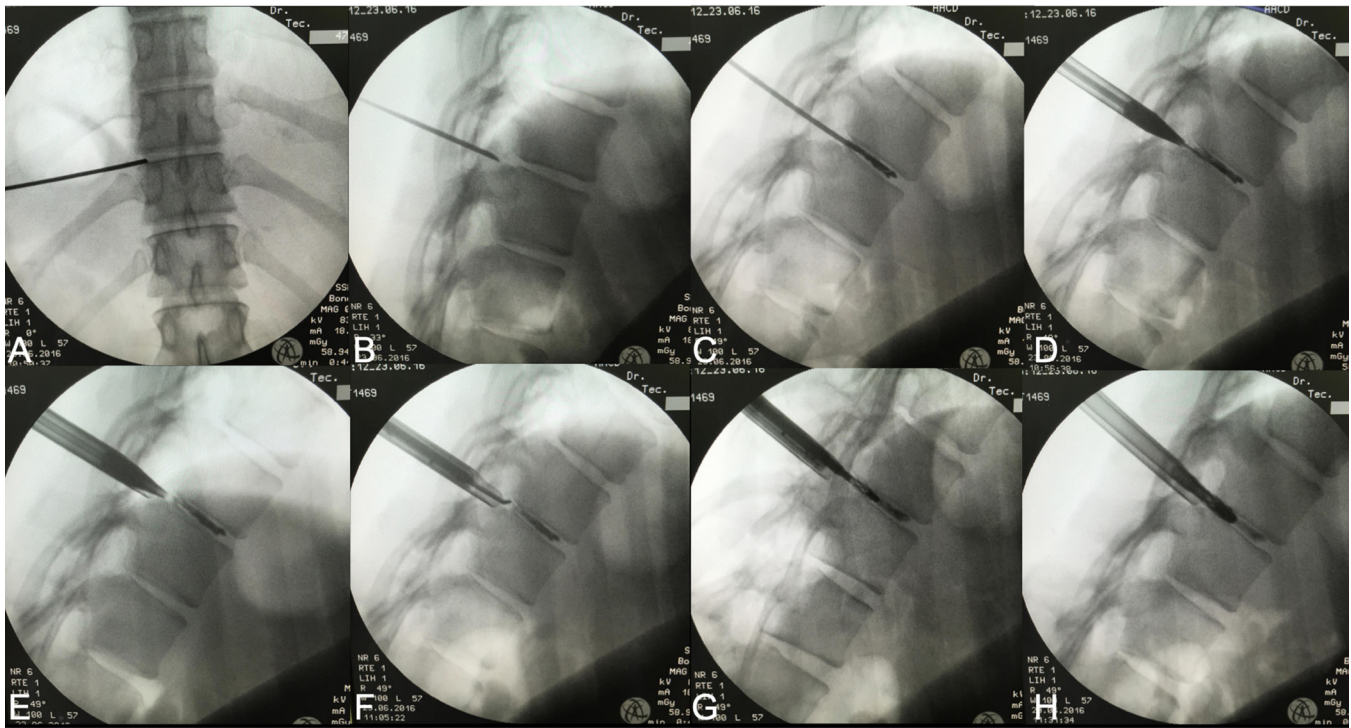
## Transforaminal Approach

Surgery was performed using local anesthesia and intravenous mild sedation with patient in prone position. Approach trajectory was planned on fluoroscopic lateral view by drawing an oblique line from the posterior end plate of the lower vertebra passing the tip of superior articular process (SAP) to avoid obstruction of the thick transverse process and rib head at the costotransverse junction. Skin entry point was located at about 5–6 cm from the midline. Using anteroposterior (AP) and lateral fluoroscopy, a 25-cm 18G needle was placed in the floor of the left T10–T11 neural foramen. The needle tip was placed at the midpedicular level at

**Table 1.** Published patients series of interlaminar full endoscopic spine surgery for thoracic disc herniations.

Patient Series	Pathology	N (M:F)	Age, y (range)	Operative Time, min	Length of Stay, d	Follow-Up, mo	Postoperative Course	Complications
Ruetten, 2018 <sup>7</sup>	T1-T2 (6), T4-T5 (1), T7-T8 (2), T9-T10 (4), T10-T11 (5), T11-T12 (2)	20 (8:12)	53 (23–71)	95 (35–135)	3 (2–5)	18	All patients with radiculopathy showed symptom regression. Preoperative thoracic spine pain was reduced, but not significantly.	Epidural hematoma ×1 (revision), transient intercostal neuralgia, deterioration of myelopathy
Hur, 2019 <sup>15</sup>	T10-T11	1 (1:0)	65	95	Not reported	1.5	Paresthesia immediately subsided, motor grade improved from G2-G3 to G3-G4	None
Liu L, 2020 <sup>16</sup>	T10-T11 and ossification of ligamentum flavum	1 (0:1)	58	110	3	6	Motor grade improved from G4 to G4+ bilaterally. The VAS score improved from 8 to 5.	None

Abbreviations: F, female; M, male; VAS, visual analog score. All patients received general anesthesia.



**Figure 1.** Fluoroscopic views of the transforaminal approach of patient 1. (A) Insertion of the needle at T10-T11 level at anteroposterior (AP) view until needle tip reaches the midpedicular line. (B) After reaching the disc at the AP view, the C-arm is turned to lateral position, the needle tip is observed a few millimeters behind the posterior intervertebral disc line due to the disc protrusion. (C) The needle is now observed inside the disc space, and intraoperative discography is performed by injecting a mixture of radiopaque dye and methylene blue. (D) A guide wire is inserted through the needle and the dilator followed over the guide wire, note the tip of the dilator at the same point where the needle tip had touched the disc extrusion. (E) The guide wire is removed and the operating sheath is inserted over the dilator. (F) Through the endoscope, a dissector touches the disc herniation. (G and H) Progressive reamers are inserted inside the disc to assure nucleotomy.

the AP view (Figure 1A) and a few millimeters behind the posterior intervertebral disc line due to the disc protrusion (Figure 1B). The needle was then advanced into the disc space and intraoperative discography (Figure 1C) was performed by injecting a mixture of radiopaque dye and methylene blue. A guide wire was inserted through the needle, the needle was extracted, and the dilator followed the guide wire (Figure 1D). The operating sheath (Figure 1E) and the endoscope are then inserted bluntly into the foraminal area. The procedure is full endoscopic and uniportal—that is, surgical instruments are introduced under continuous visual control and irrigation through the intraendoscopic working channel. Under endoscopic visualization, the blue-stained annular surface and part of the disc material could be directly observed (Figure 2A–B) and also through the fluoroscopic lateral view (Figure 2F). The foramen was dissected and widened by resecting bone and disc material with a cutter and forceps, and a trephine was used to open de annulus. Further disc material was resected using the Lowe punch (Figure 2E). A burr was used to complete discectomy through the working channel (Figure 2F), and the endoscope was retracted to complete foraminoplasty and disc removal using manual reamers (Figure 2G–H). After adequate

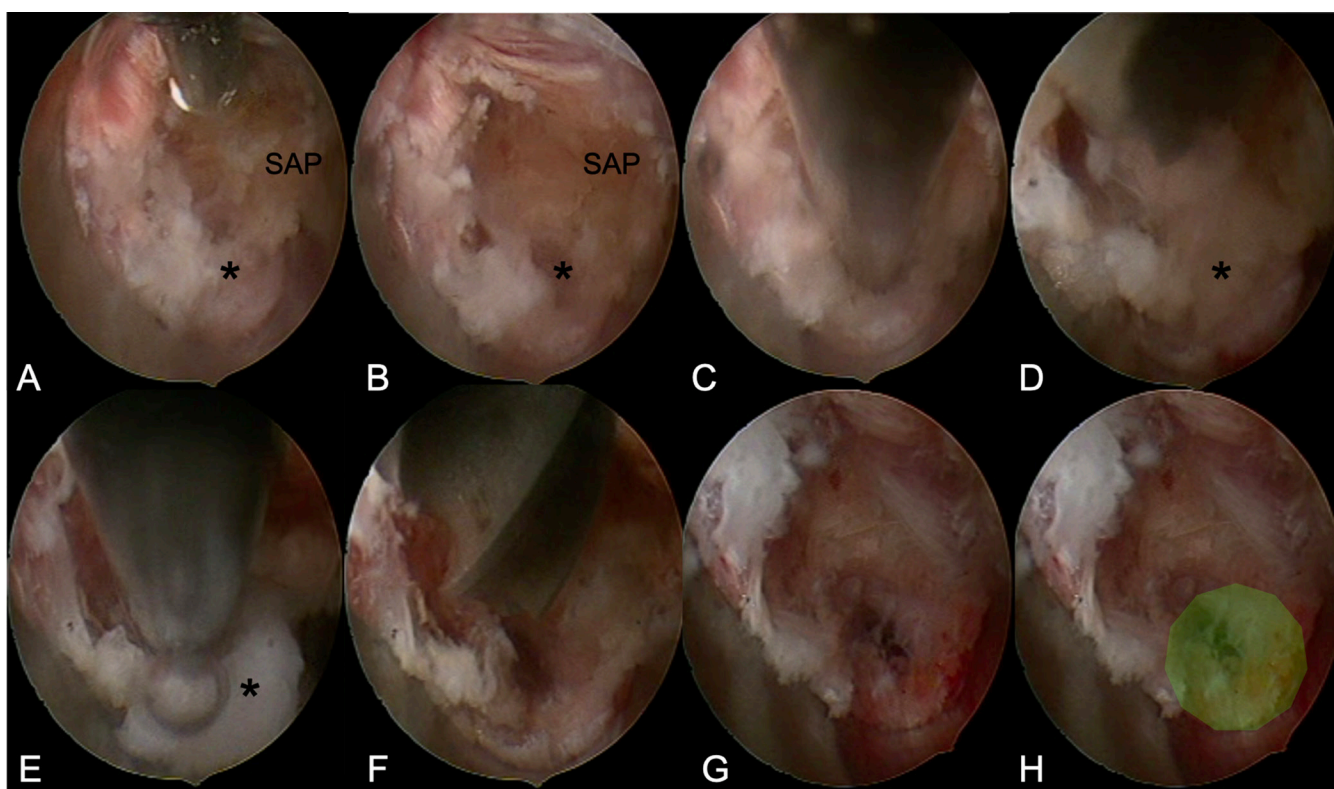
decompression, it is possible to notice the widened foramen as well as to feel free movement of the instruments inside it. Skin was closed with a single subcuticular suture, and sterile dressing was applied. Patient was discharged from the hospital 6 hours after surgery, after walking.

### Interlaminar Approach

Surgery was performed using general anesthesia with patient in prone position. Using AP fluoroscopic view, skin entry point was planned at about 1–2 cm from the midline, orthogonally directed to the interlaminar window. After an 8-mm skin and fascia incision, the dilator was introduced until bone contact.

Then the operating sheath and endoscope were introduced bluntly. The procedure was full endoscopic and uniportal—that is, all surgical instruments were introduced under continuous visual control and irrigation through the intraendoscopic working channel. The laminae, the vertebral joint, and the ligamentum flavum were dissected (Figure 3A). The cutter was used to start bone resection at the medial edge of the inferior articular process and at the bottom of the spinous process. Resection was carried out at the SAP and the caudal lamina





**Figure 2.** (A and B) After insertion of the transforaminal endoscope, it is possible to identify the superior articular process (SAP) and the disc herniation (\*). The radiofrequency probe is used to palpate and clean the SAP. (C) A trephine is used to open de annulus. (D and E) Further disc material is resected using the Lowe punch. (F) A burr is used to complete discectomy. (G and H) At the end of the surgery, it is possible to notice the widened foramen (green area).

(Figure 3B–C). The ligamentum flavum remained closed as long as possible, but after drilling the SAP, it was possible to identify the opening of the spinal canal. The remaining ligamentum flavum was resected until there was enough visualization of the dura and the disc material (Figure 3D), which was resected using forceps and punches (Figure 3E). The access to the disc level and medially to the pedicle with the forceps are respectively shown in Figure 4D and H. The operating sheath was maintained outside of the spinal canal throughout the entire surgery to avoid any manipulation of the dura. Free-floating dura mater in the irrigation fluid was a sign of sufficient decompression (Figure 3F).

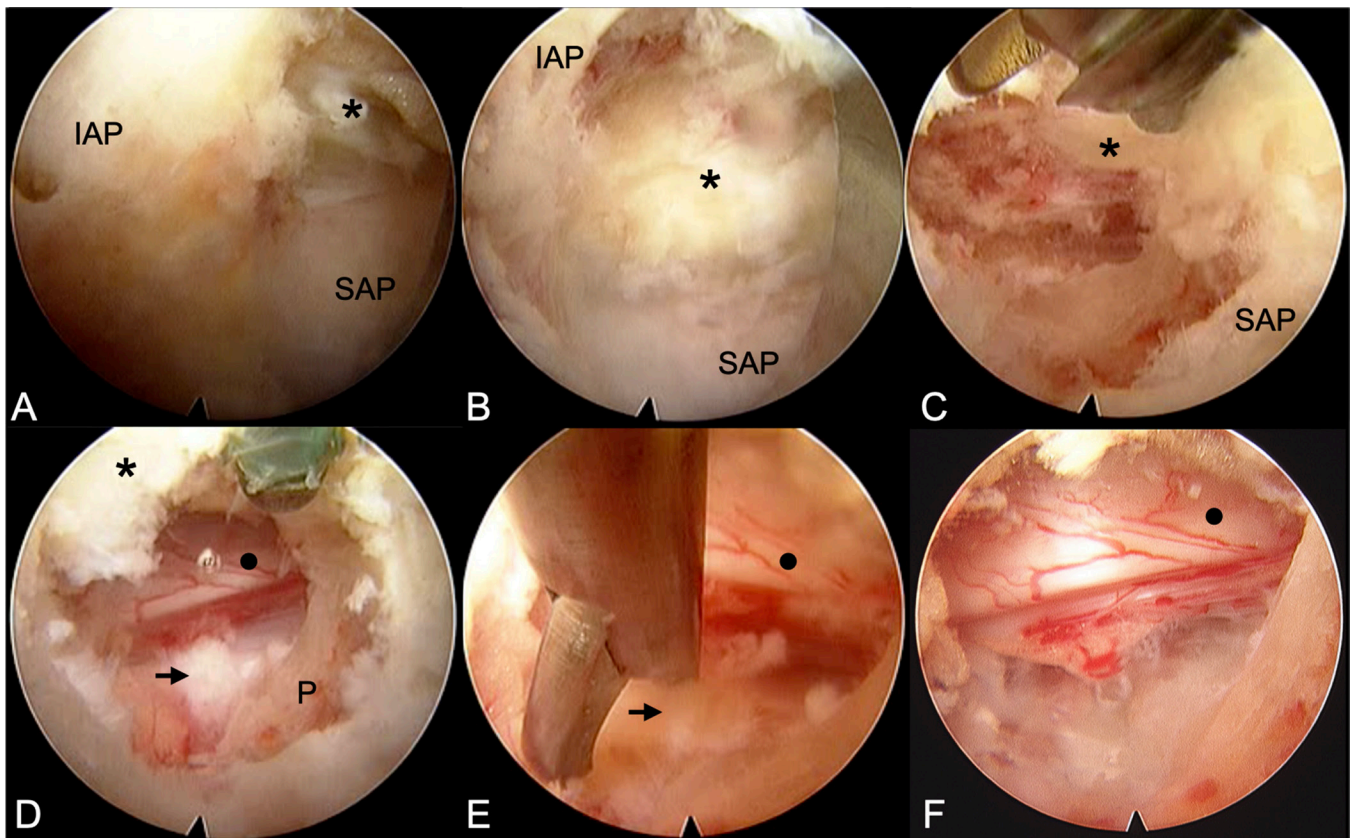
## RESULTS

Using the primary search terms in combination with each of the secondary terms on PubMed yielded 18 unique results. Searching Google Scholar for article titles containing the same terms in combination and published over the same period (1980–2021) yielded 10 unique results. When combined, the literature searches of these 2 databases revealed a total of 24 full articles for review. Two other articles were cited by a review. Articles considering only transforaminal approach to

the thoracic spine were excluded, as well as articles considering the interlaminar approach only for ossification of ligamentum flavum. Only 3 articles remained and were included (Table 1).

On arrival, patient 1 (Table 2) had already been complaining of T10 radicular pain for 5 years with progressive worsening (visual analog score [VAS] 10/10). Besides more than 3 years of physical therapy, she had used analgesic, nonsteroidal anti-inflammatory drugs, duloxetine, and pregabalin and never had significant improvement of the pain. Magnetic resonance imaging (MRI) showed T10-T11 foraminal disc herniation (Figure 5A–B). She had been submitted to left T10 radicular block and had transitory improvement. She was then selected for transforaminal FESS, which was performed with local anesthesia and sedation as previously described. She had good improvement immediately after the surgery and was discharged from the hospital 6 hours after the procedure. One week later she reported total improvement (VAS 0/10) and remained so until last evaluation 2 years after surgery.

Patient 2 (Table 2) had been complaining of thoracic pain (VAS 9/10) for 3 years with progressive worsening. The pain didn't improve with physical therapy,



**Figure 3.** Endoscopic view of the interlaminar approach. (A) After preparing the operating field it is possible to identify the inferior articular process (IAP), the superior articular process (SAP), and the interlaminar window with the flavum ligament (\*). (B) After drilling the IAP and enlarging the interlaminar window, the SAP is ready to be drilled. (C) It is possible to see the burr drilling the inferior laminae and the SAP, lateral to the flavum ligament (\*) it is possible to identify the opening of the spinal canal. (D) Above the pedicle (P), it is possible to identify the extruded disc herniation (arrow) and the partially compressed dural sac (circle). (E) Low punch resecting the disc herniation. (F) Dural sac free at the end of the surgery.

various analgesic drugs, nor with duloxetine or pregabalin. He was then submitted to T7 radicular block and had transitory improvement. MRI showed T7-T8 paramedian disc herniation with caudal migration medial to the inferior pedicle (Figure 4A–C). He was then selected for interlaminar FESS, which was performed with general anesthesia as previously described. He had good improvement immediately after the surgery and was discharged from hospital 3 hours after the procedure. One week later he reported significant improvement (VAS 2/10) and remained so until last evaluation 2 months after surgery. Postoperative MRI showed good resection of the disc herniation (Figure 4E–G).

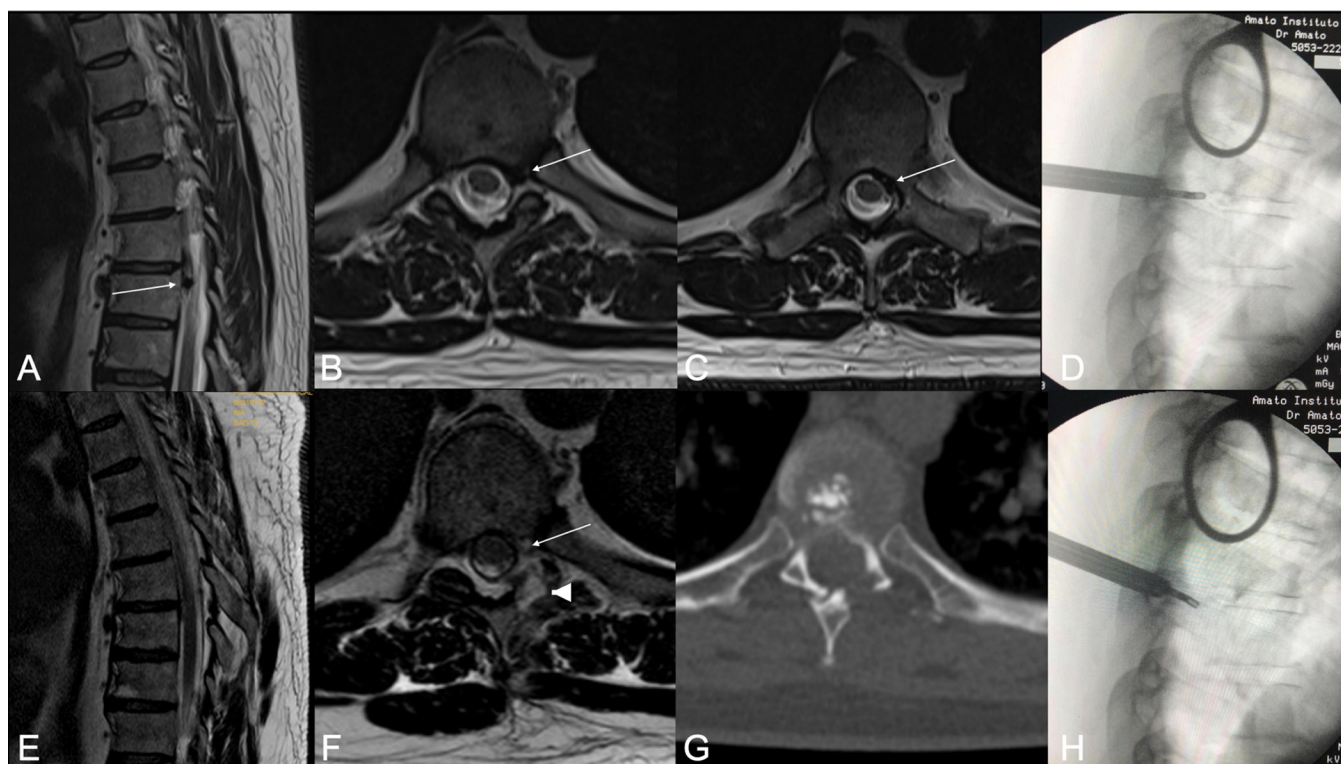
## DISCUSSION

In thoracic decompression, surgical manipulation of the spinal cord must be avoided. Therefore, depending on the location and consistency of the pathology, various approaches were described to cover the entire area around the spinal cord.<sup>1–5,7</sup> The most direct access route to the disc herniation is required. The larger,

more medial, or more calcified is a disc herniation, the more likely it is that a lateral (transthoracic) or an anterior approach should be considered.<sup>5,7</sup> The posterior approaches may involve difficult or inadequate visualization or handling of the area anterior to the spinal cord, with an increased risk of neurological injury and approach-related damage of the posterior structures.<sup>7,17</sup> Nevertheless, many disc herniations may be accessed by minimally invasive posterior or posterolateral approaches such as the reported cases in literature<sup>1,4,6,7,9,15,16,18–21</sup> and those of this study.

There is a growing movement among surgeons to achieve adequate results and fewer complications with minimally invasive alternatives for all spine procedures. In addition to the superiority of FESS for lumbar discectomies,<sup>10</sup> similar results have been increasingly described with FESS for cervical disc herniations and spinal canal stenosis in the cervical and lumbar spine,<sup>10–13,22</sup> and were naturally expected for the thoracic spine. The FESS has proven technical advantages such as skin incision of only approximately 8 mm, an enlarged visual





**Figure 4.** (A) Sagittal T2-weighted magnetic resonance imaging (MRI) showing the extruded disc herniation with caudal migration (arrow). (B and C) Axial T2-weighted MRI showing the paramedian disc herniation with migration medial to pedicle. (E and F) Postoperative images showing good resection of the disc herniation. It is possible to see the partial facetectomy (arrow head), with complete preservation of the spinal muscles. (G) Computed tomographic image showing partial facetectomy. (D and H) Intraoperative images showing access to the intervertebral disc and manipulation of the instrument medial to the pedicle.

field due to the 30° view angle, excellent illumination and visualization, dissection of less tissue, reduced bleeding due to continuous irrigation, minimal damage to the paraspinal muscles, and low complication rates.<sup>7,9</sup> As a result, FESS can reduce the length of hospital stay and the cost of medical treatment and thus has good socioeconomic benefits<sup>10,23</sup>; it is also more favorable in terms of outcome, duration of surgery, and overall complications when compared to open or microendoscopic surgery.<sup>10</sup>

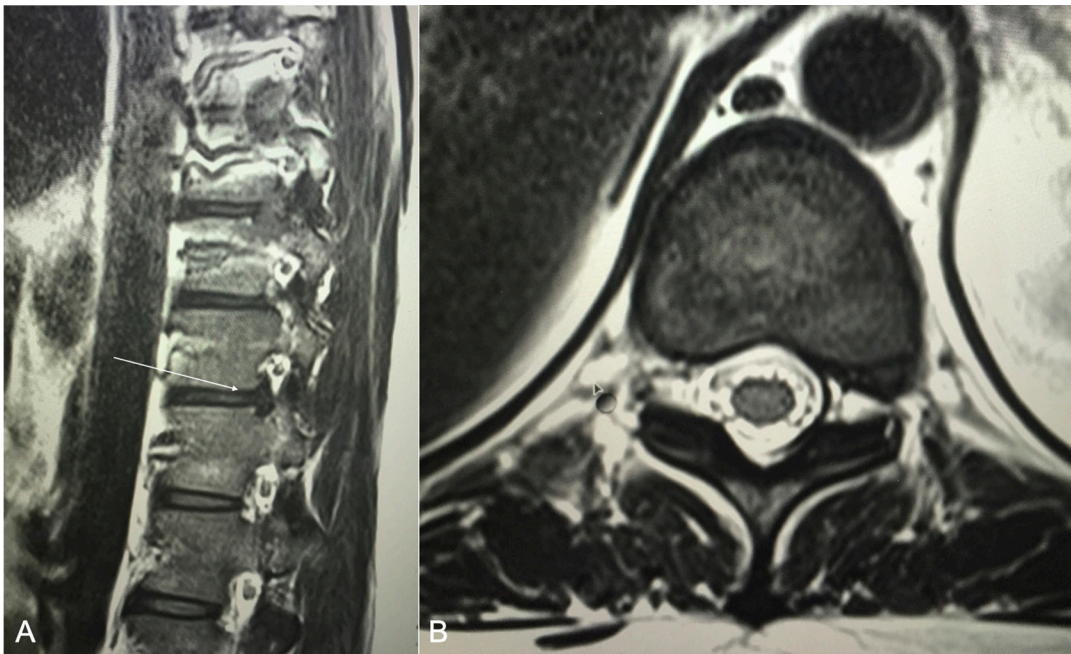
FESS for the thoracic spine achieves technically sufficient decompression based on the clinical results, radiological outcomes, intraoperative findings, and patient satisfaction.<sup>4,6,18,24</sup> The duration of surgery is also shorter than that of the methods described in the literature;<sup>7,24</sup> indeed, our cases lasted only 50 and 80 minutes. The intraoperative blood loss was so low that it cannot be measured due to continuous irrigation,

although it is also not considered to be problematic in other techniques.<sup>17</sup> Gibson et al, in a review of FESS for thoracic pathology, reported low rate of complications that consisted of 2% of dural tears, 2% of transient neuralgia, 1.5% of revision surgery, 0.6% of neurological injury, and 0.6% of dural hematoma.<sup>24</sup> Consistent with the literature, no surgery-related complications or thoracic spine pain was observed postoperatively in the present cases. The hospital stay was only a few hours long and much shorter than reported in the literature.<sup>7,24</sup> The shorter stay can be explained by 2 factors: (1) the present cases took place in a day-hospital structure and (2) in some countries, for socioeconomic purposes, the patients are not dismissed from the hospital before the third postoperative day.

Fusion is sometimes necessary for traditional transpedicular and transfacet approaches, which damage posterior structures or result in more than half of the

**Table 2.** Patients' results.

Patient	Level	Approach	Anesthesia	Total Time, min	Irrigation Time, min	Hospital Stay, h	Complications
Patient 1: female, 38 y	T10–T11	Transforaminal	Local and sedation	50	32	6	None
Patient 2: male, 39 y	T7–T8	Interlaminar	General	80	70	3	None



**Figure 5.** (A and B) Sagittal and axial T2-weighted magnetic resonance images of patient 1 showing a T10-T11 foraminal disc herniation.

vertebral body resection. In addition to the previously mentioned advantages of FESS, the provided structural preservation may avoid the need for fusion, thus making FESS an alternative choice for elderly patients with comorbidity and for whom major surgical trauma would be harmful.<sup>7,9,25</sup>

The individual selection of the respective FESS approach enables different working areas to be used and makes it possible to reach the target area without manipulating the spinal cord.<sup>7</sup> The extraforaminal approach is used for intraforaminal and extraforaminal disc herniations and also for intraspinal mediolateral or some medial disc herniations. The extraforaminal technique has the broadest range of indications for anterior pathologies and also for giant disc herniations.<sup>7,26,27</sup> The transforaminal case presented was a typical indication for the approach, as it was a pure extraforaminal disc herniation. Any other approach would probably be more risky and less efficient.

Anterior medial pathologies that cannot be treated using an extraforaminal approach, may be accessed by minimally invasive anterior approaches, such as the full endoscopic transthoracic retropleural approach described by Ruetten et al.<sup>7</sup>

The interlaminar approach was initially described for posterior pathologies such as ossification of ligamentum flavum,<sup>9,19</sup> but can also be used for disc herniations as previously reported<sup>7,15,16</sup> and verified with the present study. Although this approach is mostly known as interlaminar (because the interlaminar window in the thoracic spine is narrow), it always includes partial

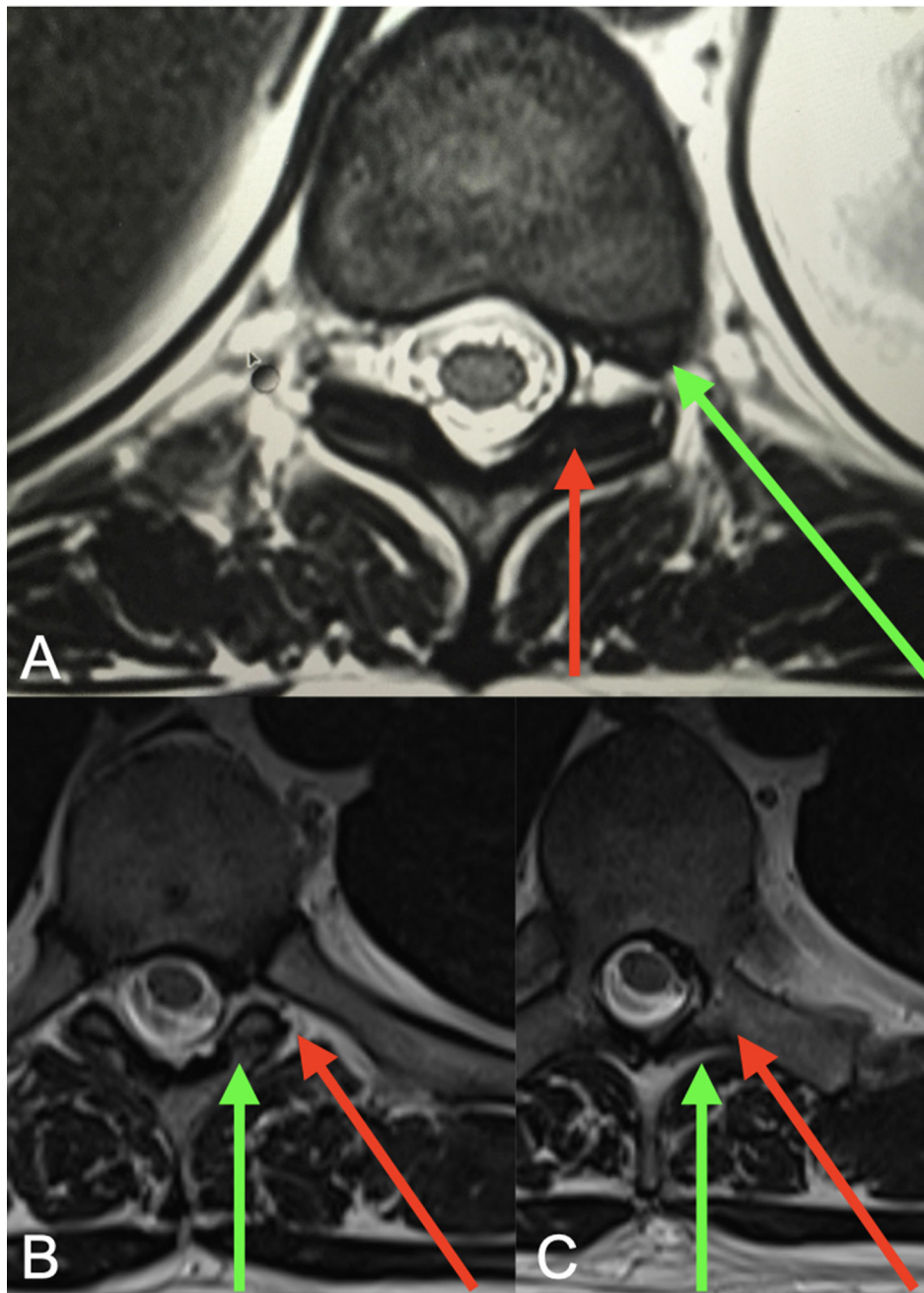
laminectomy and/or partial facetectomy. For patient 2, the interlaminar approach was indicated because of the caudal migration and location of the disc herniation medially to the pedicle.

Overall, there are no clear standards in the literature with respect to the surgical technique. To minimize the risk of surgery-induced damage to the spinal cord as well as other complications, the approach must be individually adapted to the anatomic location of the herniated material, the general health of the patient, and also the surgeon's experience.<sup>17</sup> The same applies to the full endoscopic techniques considered in this study. While previous publications have included the surgical treatment of herniated discs with a transforaminal approach,<sup>4,6,9</sup> the interlaminar approach must also be considered, especially for migrated disc herniations and those located medially to the pedicle. It is important to consider the amount of facetectomy in both approaches, choosing the one that will give the better visualization with the smaller facetectomy.

Note that in patient 1, if the interlaminar approach was selected, almost the whole facet would have to be removed to reach the disc herniation (Figure 6A). In patient 2, if the transforaminal approach was selected, a greater amount of the facet and pedicle would have to be resected to provide good visualization of the disease (Figure 6B).

FESS of the thoracic spine is evolving fast, and both transforaminal and interlaminar approaches are safe, efficient, and minimally invasive alternatives.





**Figure 6.** (A) Patient 1 axial magnetic resonance image (MRI) showing a T10-T11 foramina disc herniation; the green arrow shows the selected transforaminal approach, which is a straight forward direction to the disease, avoiding bone resection. (B and C) Patient 2 axial MRI showing a T7-T8 paramedian disc herniation; the green arrow shows the selected interlaminar approach, the need of medial facetectomy is more adequate than a lateral facetectomy that would be needed in a transforaminal approach (red arrow), because it allows navigation inside the spinal canal to access the migrated material, sparing the pedicle.

Nevertheless, the surgical technique must be determined for every pathology on a case-by-case basis. If the inclusion criteria for a full endoscopic technique are not met, decompression must always be performed using a conventional method.

## REFERENCES

1. Bae J, Chachan S, Shin SH, Lee SH. Percutaneous endoscopic thoracic discectomy in the upper and midthoracic spine: a technical note. *Neurospine*. 2019;16(1):148–153. doi:10.14245/ns.1836260.130
2. Cho JY, Lee SH, Jang SH, Lee HY. Oblique paraspinous approach for thoracic disc herniations using tubular retractor with robotic holder: a technical note. *Eur Spine J*. 2012;21(12):2620–2625. doi:10.1007/s00586-012-2438-1
3. Stillerman CB, Chen TC, Day JD, Couldwell WT, Weiss MH. The transfacet pedicle-sparing approach for thoracic disc removal: cadaveric morphometric analysis and preliminary clinical experience. *J Neurosurg*. 1995;83(6):971–976. doi:10.3171/jns.1995.83.6.0971

4. Choi KY, Eun SS, Lee SH, Lee HY. Percutaneous endoscopic thoracic discectomy. *Transforaminal Approach Minim Invasive Neurosurg.* 2010;53(1):25–28. doi:10.1055/s-0029-1246159
5. Quint U, Bordon G, Preissl I, Sanner C, Rosenthal D. Thoracoscopic treatment for single level symptomatic thoracic disc herniation: a prospective followed cohort study in a group of 167 consecutive cases. *Eur Spine J.* 2012;21(4):637–645. doi:10.1007/s00586-011-2103-0
6. Lee HY, Lee S-H, Kim D-Y, Kong BJ, Ahn Y, Shin S-W. Percutaneous endoscopic thoracic discectomy. *Posterolateral Transforaminal Approach J Korean Neurosurg Soc.* 2006;40(1):58–62.
7. Ruetten S, Hahn P, Oezdemir S, et al. Full-endoscopic uniportal decompression in disc herniations and stenosis of the thoracic spine using the interlaminar, extraforaminal, or transthoracic retropleural approach. *J Neurosurg Spine.* 2018;29(2):157–168. doi:10.3171/2017.12.SPINE171096
8. Awwad EE, Martin DS, Smith KR, Baker BK. Asymptomatic versus symptomatic herniated thoracic discs: their frequency and characteristics as detected by computed tomography after myelography. *Neurosurgery.* 1991;28(2):180–186. doi:10.1227/00006123-199102000-00002
9. Cheng XK, Chen B. Percutaneous endoscopic thoracic decompression for thoracic spinal stenosis under local Anesthesia. *World Neurosurg.* 2020;139(May):488–494. doi:10.1016/j.wneu.2020.04.199
10. Muthu S, Ramakrishnan E, Chellamuthu G. Is endoscopic discectomy the next gold standard in the management of lumbar disc disease. *Systematic Review and Superiority Analysis Glob Spine J.* 2020. doi:10.1177/2192568220948814
11. Ruetten S, Komp M, Merk H, Godolias G. Full-endoscopic cervical posterior foraminotomy for the operation of lateral disc herniations using 5.9-mm endoscopes: a prospective, randomized, controlled study. *Spine (Phila Pa 1976).* 2008;33(9):940–948. doi:10.1097/BRS.0b013e31816c8b67
12. Komp M, Oezdemir S, Hahn P, Ruetten S. Full-endoscopic posterior foraminotomy surgery for cervical disc herniations. *Oper Orthop Traumatol.* 2018;30(1):13–24. doi:10.1007/s00064-017-0529-1
13. Birkenmaier C, Komp M, Leu HF, Wegener B, Ruetten S. The current state of endoscopic disc surgery: review of controlled studies comparing full-endoscopic procedures for disc herniations to standard procedures. *Pain Physician.* 2013;16(4):335–344.
14. Zhang C, Wu J, Zheng W, Li C, Zhou Y. Posterior endoscopic cervical decompression: review and technical note. *Neurospine.* 2020;17(Suppl 1):S74–S80. doi:10.14245/ns.2040166.083
15. Hur JW, Kim JS, Seung JH. Full-endoscopic interlaminar discectomy for the treatment of a dorsal migrated thoracic disc herniation: case report. *Medicine (Baltimore).* 2019;98(22):22. doi:10.1097/MD.00000000000015541
16. Liu L, Li Q, Ao J, Du Q, Xin ZJ, Liao WB. Posterior percutaneous endoscopic technique through bilateral translaminar osseous channels for thoracic spinal stenosis caused by ossification of the ligamentum flavum combined with disk herniation at the T10-T11 level: a technical note. *World Neurosurg.* 2020;133:135–141. doi:10.1016/j.wneu.2019.08.215
17. Börm W, Bäßner U, König RW, Kretschmer T, Antoniadis G, Kandenwein J. Surgical treatment of thoracic disc herniations via tailored posterior approaches. *Eur Spine J.* 2011;20(10):1684–1690. doi:10.1007/s00586-011-1821-7
18. Bae J, Chachan S, Shin SH, Lee SH. Transforaminal endoscopic thoracic discectomy with foraminoplasty for the treatment of thoracic disc herniation. *J Spine Surg.* 2020;6(2):397–404. doi:10.21037/jss.2019.11.19
19. Li X, An B, Gao H, et al. Surgical results and prognostic factors following percutaneous full endoscopic posterior decompression for thoracic myelopathy caused by ossification of the ligamentum flavum. *Sci Rep.* 2020;10(1):1–9. doi:10.1038/s41598-020-58198-x
20. Nie HF, Liu KX. Endoscopic transforaminal thoracic foraminotomy and discectomy for the treatment of thoracic disc herniation. *Minim Invasive Surg.* 2013;2013:264105. doi:10.1155/2013/264105
21. Quillo-Olvera J, Kim JS. A novel, minimally invasive hybrid technique to approach intracanal herniated thoracic discs. *Oper Neurosurg (Hagerstown).* 2020;19(2):E106–E116. doi:10.1093/ons/oz362
22. Aprile BC, Amato MCM, de Oliveira CA. Functional evolution after percutaneous endoscopic lumbar discectomy, an earlier evaluation of 32 cases. *Rev Bras Ortop (Sao Paulo).* 2020;55(4):415–418. doi:10.1055/s-0039-3402473
23. Choi G, Pophale CS, Patel B, Uniyal P. Endoscopic spine surgery. *J Korean Neurosurg Soc.* 2017;60(5):485–497. doi:10.3340/jkns.2017.0203.004
24. Gibson RDS, Wagner R, Gibson JNA. Full endoscopic surgery for thoracic pathology: an assessment of supportive evidence. *EFORT Open Rev.* 2021;6(1):50–60. doi:10.1302/2058-5241.6.2000080
25. Oppenlander ME, Clark JC, Kalyvas J, Dickman CA. Indications and techniques for spinal instrumentation in thoracic disk surgery. *Clin Spine Surg.* 2016;29(2):E99–E106. doi:10.1097/BSD.0000000000001110
26. Paolini S, Tola S, Missori P, Esposito V, Cantore G. Endoscope-assisted resection of calcified thoracic disc herniations. *Eur Spine J.* 2016;25(1):200–206. doi:10.1007/s00586-015-3858-5
27. Wagner R, Telfeian AE, Ipreburg M, et al. Transforaminal endoscopic foraminoplasty and discectomy for the treatment of a thoracic disc herniation. *World Neurosurg.* 2016;90:194–198. doi:10.1016/j.wneu.2016.02.086

**Funding:** The author(s) received no financial support for the research, authorship, and/or publication of this article.

**Declaration of Conflicting Interests:** The authors report no conflicts of interest in this work.

**Ethics Approval:** The Research Ethics Committee of the institution where surgeries were performed approved this study.

**Corresponding Author:** Marcelo Campos Moraes Amato, Neurosurgeon, Amato – Instituto de Medicina Avançada, Av. Brasil, 2283, Jardim América, São Paulo, Brazil; amato@neurocirurgia.com

Published 09 March 2022

This manuscript is generously published free of charge by ISASS, the International Society for the Advancement of Spine Surgery. Copyright © 2022 ISASS. To see more or order reprints or permissions, see <http://ijssurgery.com>.