

## Differential Agnostic Effect Size Analysis of Lumbar Stenosis Surgeries

Kai-Uwe Lewandrowski, Ivo Abraham, Jorge Felipe Ramírez León, José Antonio Soriano Sánchez, Álvaro Dowling, Stefan Hellinger, Max Rogério Freitas Ramos, Paulo Sérgio Teixeira De Carvalho, Christopher Yeung, Nima Salari and Anthony Yeung

*Int J Spine Surg* 2022, 16 (2) 318-342

doi: <https://doi.org/10.14444/8222>

<http://ijssurgery.com/content/16/2/318>

This information is current as of April 16, 2024.

---

**Email Alerts** Receive free email-alerts when new articles cite this article. Sign up at:  
<http://ijssurgery.com/alerts>

# Differential Agnostic Effect Size Analysis of Lumbar Stenosis Surgeries

KAI-UWE LEWANDROWSKI, MD<sup>1,2,3</sup>; IVO ABRAHAM, PhD<sup>4,5</sup>; JORGE FELIPE RAMÍREZ LEÓN, MD<sup>5,6,7</sup>; JOSÉ ANTONIO SORIANO SÁNCHEZ, MD<sup>8</sup>; ÁLVARO DOWLING, MD<sup>9,10</sup>; STEFAN HELLINGER, MD<sup>11</sup>; MAX ROGÉRIO FREITAS RAMOS, MD, PhD<sup>12</sup>; PAULO SÉRGIO TEIXEIRA DE CARVALHO, MD, PhD<sup>13</sup>; CHRISTOPHER YEUNG, MD<sup>14</sup>; NIMA SALARI, MD<sup>14</sup>; AND ANTHONY YEUNG, MD<sup>14,15</sup>

<sup>1</sup>Center for Advanced Spine Care of Southern Arizona and Surgical Institute of Tucson, Tucson, AZ, USA; <sup>2</sup>Department of Orthopaedic Surgery, Fundación Universitaria Sanitas, Bogotá, DC, Colombia; <sup>3</sup>Department of Orthopaedic Surgery, UNIRIO, Rio de Janeiro, Brazil; <sup>4</sup>Family and Community Medicine, Clinical Translational Sciences at the University of Arizona, Tucson, AZ 85721, USA; <sup>5</sup>Centro de Cirugía de Mínima Invasión, CECIMIN - Clínica Reina Sofía, Bogotá, Colombia; <sup>6</sup>Research Team, Centro de Columna, Bogotá, Colombia; <sup>7</sup>Fundación Universitaria Sanitas, Bogotá, DC, Colombia; <sup>8</sup>Neurosurgeon and Minimally Invasive Spine Surgeon, Head of the Spine Clinic of The American-British Cowdray Medical Center I.A.P. Campus Santa Fe [Centro Médico ABC Campus Santa Fe], Santa Fe, Mexico; <sup>9</sup>Department of Orthopaedic Surgery, USP, Ribeirão Preto, Brazil; <sup>10</sup>Orthopaedic Spine Surgeon, Director of Endoscopic Spine Clinic, Santiago, Chile; <sup>11</sup>Department of Orthopedic Surgery, Isar Hospital, Munich, Germany; <sup>12</sup>Orthopedics and Traumatology, Universidade Federal do Estado do Rio de Janeiro, UNIRIO, Rio de Janeiro, Brazil; <sup>13</sup>Department of Neurosurgery, Universidade Federal do Estado do Rio de Janeiro, UNIRIO, Rio de Janeiro, Brazil; <sup>14</sup>Desert Institute for Spine Care, Phoenix, AZ, USA; <sup>15</sup>Department of Neurosurgery Albuquerque, University of New Mexico School of Medicine, Albuquerque, NM, New Mexico

## ABSTRACT

**Study Design:** A meta-analysis of 89 randomized prospective, prospective, and retrospective studies on spinal endoscopic surgery outcomes.

**Objective:** The study aimed to provide familiar Oswestry Disability Index (ODI), visual analog scale (VAS) back, and VAS leg effect size (ES) data following endoscopic decompression for sciatica-type back and leg pain due to lumbar herniated disc, foraminal, or lateral recess spinal stenosis.

**Background:** Higher-grade objective clinical outcome ES data are more suitable than lower-grade clinical evidence, including cross-sectional retrospective study outcomes or expert opinion to underpin the ongoing debate on whether or not to replace some of the traditional open and with other forms of minimally invasive spinal decompression surgeries such as the endoscopic technique.

**Methods:** A systematic search of PubMed, Embase, Web of Science, and the Cochrane Central Register of Controlled Trials from 1 January 2000 to 31 December 2019 identified 89 eligible studies on lumbar endoscopic decompression surgery enrolling 23,290 patient samples using the ODI and VAS for back and leg pain used for the ES calculation.

**Results:** There was an overall mean overall reduction of ODI of 46.25 (SD 6.10), VAS back decrease of 3.29 (SD 0.65), and VAS leg reduction of 5.77 (SD 0.66), respectively. Reference tables of familiar ODI, VAS back, and VAS leg show no significant impact of study design, follow-up, or patients' age on ES observed with these outcome instruments. There was no correlation of ES with long-term follow-up ( $P = 0.091$ ). Spinal endoscopy produced an overall ODI ES of 0.92 extrapolated from 81 studies totaling 12,710 patient samples. Provided study comparisons to tubular retractor microdiscectomy and open laminectomy showed an ODI ES of 0.9 (2895 patients pooled from 16 studies) and 0.93 (1188 patients pooled from 5 studies). The corresponding VAS leg ES were 0.92 (12,631 endoscopy patients pooled from 81 studies), 0.92 (2348 microdiscectomy patients pooled from 15 studies), and 0.89 (1188 open laminectomy patients pooled from 5 studies).

**Conclusion:** Successful clinical outcomes can be achieved with various lumbar surgeries. ESs with endoscopic spinal surgery are on par with those found with open laminectomy and microsurgical decompression.

**Clinical Relevance:** This article is a meta-analysis on the benefit overlap between lumbar endoscopy, microsurgical decompression, laminectomy, and lumbar decompression fusion.

**Level of Evidence:** 2.

Endoscopic Minimally Invasive Surgery

Keywords: lumbar surgery, herniated disc, spinal stenosis, meta-analysis, minimally invasive surgery, endoscopy

## INTRODUCTION

Endoscopic spinal surgery is on the rise, and in some countries has become the standard of care in the treatment of lumbar herniated disc and spinal stenosis in the foramen and lateral recess.<sup>1</sup> Within the last 3 years alone, there has been a surge of publications coming out

of China,<sup>2–54</sup> South Korea,<sup>42,55–78</sup> and other Asian countries,<sup>79–87</sup> where spinal endoscopy has replaced microsurgical dissection techniques. Many of these articles focus on technological innovations with the procedure. Clinical benefits over traditional translaminar lumbar decompression techniques are often demonstrated in the context of a new instrument or a new technology,

which is used to expand the clinical indications for endoscopic spinal surgery. While the transforaminal approach has been the “workhorse” endoscopic technique as pioneered by the senior author of this article some 30 years ago,<sup>88–95</sup> alternatives such as the interlaminar,<sup>7,9,21,24,41,54,59,96,97</sup> the full-endoscopic, and the uniportal biportal endoscopic (UBE)<sup>61,67,98,99</sup> techniques have recently been popularized to promote one method over another. At least on the surface, it may appear to the novice to endoscopic spinal surgery attempting to organize the available clinical information that some authors may be pushing biased agendas by attempting to exploit some perceived procedural advantages and disadvantages to make a case for their preferred spinal surgery technique. One example of this trend is the sheer number of procedural acronyms—YESS (Yeung endoscopic spine system),<sup>12,26,90,95,100–104</sup> TESSYS (transforaminal endoscopic spine system),<sup>105–110</sup> PELD (percutaneous endoscopic lumbar discectomy),<sup>14,19,25,36,54,56,111</sup> SED (selective endoscopic discectomy), BELD (biportal endoscopic lumbar decompression),<sup>112</sup> ULBD (unilateral laminotomy with bilateral decompression),<sup>113</sup> PBED (percutaneous biportal endoscopic decompression),<sup>74</sup> PTED (percutaneous transforaminal endoscopic discectomy),<sup>114</sup> UBE (unilateral biportal endoscopy),<sup>61,67,98,99</sup> BEIS (intervertebral foramen endoscopy),<sup>115</sup> TESSYS (transforaminal endoscopic spine system)-ISEE (Interlaminar endoscopic 270° spinal canal decompression),<sup>116</sup> so on—to list the most commonly used terminology. These acronyms are being proposed to improve the relevance of a new version of endoscopic and minimally invasive spine surgery that supposedly improves clinical outcomes. But does it, though, and which of these procedural variations of lumbar spinal stenosis surgery are clinically relevant? The Arbeitsgemeinschaft für Osteosynthesefragen-Spine has proposed an evidence-oriented classification system to meliorate this situation somewhat and to moderate the debate but has not presented any clinical evidence to back it up.<sup>117</sup>

The authors of this study attempted to grade the clinical evidence on lumbar spine surgeries directed at soft tissue and bony spinal stenosis including modern spinal endoscopy. Many of these studies including control arms consist of traditional translaminar microsurgical and open decompression. Therefore, the authors qualitatively graded and quantitatively analyzed the clinical evidence on the endoscopic literature including that of the respective control groups published thus far by performing a meta-analysis on commonly used numerical spinal surgery outcome instruments: the Oswestry

Disability Index (ODI),<sup>118–121</sup> and the visual analog scale (VAS)<sup>122</sup> for back and leg pain. While many published meta-analyses attempted to demonstrate clinical superiority of the endoscopic spinal surgery outcomes compared to traditional translaminar microsurgical decompression techniques by selecting a few high-quality studies and without reporting the actual effect size (ES) numbers,<sup>8,22,34,50,59,123–127</sup> the authors of this article took a different approach to delineate the clinical relevance of procedural variations and technology advances in minimally invasive and endoscopic spinal surgery and the mode of studying them. Instead of performing a narrow focus meta-analysis based on a few prospective or randomized prospective, or well-controlled cross-sectional retrospective studies, this team of authors was interested in a broad investigation of the ESs associated with reported clinical outcome improvements with traditional translaminar and lumbar endoscopic spinal surgery by extracting and analyzing the ODI and VAS means, SDs, and number of patients in each study. Therefore, we performed additional subcategory, modifier, and wave analysis to cross-tabulate ES extractions by the length of follow-up, patients’ age, the indication for surgery, the type of minimally invasive spinal surgery performed, the publication year, and the type of study design employed by the authors of the original studies. Ultimately, the authors intended to create a reference table of ES with the various minimally invasive spinal surgery to employ it in the comparative evaluation and discussion of their clinical merits.

## MATERIALS AND METHODS

### Search Strategy and Study Selection

The authors were interested in analyzing the ES data reported for commonly used numerical clinical outcome instruments including the ODI,<sup>118–121</sup> and the VAS<sup>122</sup> for back and leg pain with lumbar endoscopic decompression procedures for soft tissue and bony stenosis. Therefore, we performed a meta-analysis of clinical studies on endoscopic decompression for lumbar herniated disc and spinal stenosis employing preferred reporting items for systematic reviews and meta-analyses guidelines.<sup>128–131</sup> For this purpose, the authors searched the English literature on PubMed, Embase, Web of Science, and the Cochrane Database from 1 January 2000 to 31 December 2019 using “lumbar” and “herniated disc” or “spinal stenosis” and “endoscopic” and “ODI” and “VAS” as keywords. Three independent researchers (KUL, JFR, and ATY) contributed their literature searches and also reached consensus with the

other coauthors if there were any discrepancies in the interpretation of the selected studies.

### Inclusion Criteria and Data Extraction

The literature search was aimed at finding studies which included analysis of endoscopic spinal surgery outcomes reported on patients suffering from symptoms related to lumbar herniated disc, and foraminal or lateral recess stenosis utilizing ODI and VAS for back and leg pain. This literature search included straightforward cross-sectional retrospective, prospective single treatment group, or randomized prospective multitreatment arm study designs comparing endoscopic, with other minimally invasive spinal surgery techniques (MISST) including tubular retractor, and others. Retrieved studies were further stratified by the type of endoscopic MISST access to the neural elements including transforaminal, interlaminar, or combinations, or variations of these techniques. Case reports, review articles, letters to the editor, editorials, short-term reports, and nonclinical studies, such as biomechanical or cadaveric studies were excluded. Each study discovered during the extensive literature search performed by the authors was categorized as retrospective, prospective single treatment group, or randomized prospective multitreatment arm cohort studies. Their respective quality was assessed by the authors via consensus discussions to resolve any discrepancies in study quality assessment by evaluating the risk of bias (ROB) using the ROB assessment tool for controlled nonrandomized observational cohort studies, and the ROB tool for randomized controlled trials.<sup>132</sup>

### Statistical Analysis

The purpose of our meta-analysis was to determine and compare the ES of the clinical improvement of patients treated with the various endoscopic spinal decompression surgery techniques for herniated disc, central, lateral recess, and foraminal stenosis on the basis of the reported numerical clinical outcome instruments. For this purpose, the authors extracted the reported data for ODI, VAS back, and VAS leg at baseline and postoperatively at final follow-up. Only studies which reported the mean, the SD, and the sample size preoperatively and postoperatively were included in this meta-analysis for the ES calculation using random ES models. The authors considered other ways of calculating the ES from reported *t* values or significance levels less accurate

with the potential of underestimating the ES and did not employ them.

Clinical outcome data extracted from the articles included in this meta-analysis were means and SD of the VAS back, the VAS leg, and the ODI. The ES of postoperative improvements was calculated on the basis of the number of enrolled study patients available at last follow-up using Cohen *d* analysis. We used Prometa3 version 3.0 for the meta-analysis by creating a meta-analysis database of the included studies by recording the first study author and up to 2 additional coauthors, the year of publication, the study patients' mean age, and of the preoperative baseline and the postoperative value of the 3 numerical outcome variables at final available follow-up. Studies comparing multiple treatments were categorized by comparisons of "endoscopy" vs "microsurgical" decompression, laminectomy, and variations of these procedures with and without fusion. Additional moderators used in the analysis were the study design (retrospective, prospective, and randomized prospective), the indication for surgery (herniated disc radiculopathy, stenosis claudication, and discogenic pain), the type of MISST (endoscopy, open laminectomy, and tubular microdiscectomy), and, if employed, the type of endoscopic (transforaminal outside-in, transforaminal inside-out, interlaminar, combined outside-in and interlaminar, or biportal UBE endoscopy). The calculated ESs, lower limit (LL), upper limit (UL), the Higgins  $I^2$  statistic of heterogeneity ( $I^2$ ), variance (*V*), SE, number of patients, and the significance level (sig) of 95% CI were tabulated separately for ODI, VAS back, and VAS leg. The underlying average reduction of ODI, VAS back, and VAS leg was compared to the reported and calculated minimal clinically important difference (MCID) data—3.0 for VAS leg and VAS back and 15 for ODI.<sup>83,133–137</sup> Furthermore, the extracted mean ODI, VAS back, and VAS leg from each individual study were weighted by the inverse of the variance for each outcome instrument. The data heterogeneity was examined by Cochran *Q* test and the Higgins  $I^2$  statistic with an  $I^2$  threshold of greater than 50% being considered as sufficient. Funnel plots (SE vs ES) were visually assessed for evidence of publication bias and by calculating the *P* value (1-sided) for Egger intercept using the Prometa3 software, version 3.0 (Internovi, 2015). IBM SPSS statistics version 26.0 was used for area-plot analysis of ES vs SE to graphically display the extent of the overlap in postoperative surgical decompression benefit.

## RESULTS

### Initial Search Results

The initial screening literature search using the keywords “lumbar” and “herniated disc” or “spinal stenosis” and “endoscopic\*” and “ODI” and “VAS” as subject headings identified 882 studies in PubMed, Embase, Web of Science, and the Cochrane Central Register of Controlled Trials. Among these 882 studies, duplicates, case reports, review articles, letters, technical notes, or patents as well as studies not reporting the average mean, SD of ODI and VAS scores, and number of patients or length of follow-up were excluded. The remaining 89 eligible studies were subjected to a full-text review. In attempt to compare short-term and long-term ES, study analysis was further stratified into short-term—53 studies with less than 2-year follow-up (Table 1)<sup>1,4,5,7,9,11,13,18–20,23–28,36,38,40,42,43,45,51,56,66,68,74,78,111–114,116,138–156</sup>—and long-term follow-up (36 studies) with a minimum of 2 years or longer follow-up (Table 2).<sup>10,30,33,41,46,49,52,53,55,60,67,71,75,76,97,157–175</sup> The details of the preferred reporting items for systematic reviews and meta-analyses study selection process are summarized in Figure 1.

### Meta-Analysis Results

The ODI, VAS back, and VAS leg data obtained from the collective analysis of the 23,290 samples extracted from 89 articles with 112 study entries considering multiple treatment arms revealed an overall ES of 0.9 using a random effects model with an LL of 0.89 and UL of 0.91 and  $I^2$  98.49. The weighted regression analysis for age vs overall ES showed no significant correlation between these 2 variables ( $P = 0.539$ ). The weighted regression analysis for follow-up vs overall ES showed a significant correlation between these 2 variables ( $P = 0.014$ ). The majority of the 89 studies only provided short postoperative follow-up times: under 12 months in 17 study entries, 1 year in 27 study entries, under 24 months in 23 study entries. Long-term follow-up was reported by 36 articles of which, 18 study entries had follow-up of 2 years, 17 study entries had follow-up data between 2 and 4 years, and another 10 study entries over 60 months with the longest 2 follow-up study entries running for 74.8 and 76.2 months. However, there was no statistically significant difference in ES on analysis of variance (ANOVA)  $Q$  testing between short-term and long-term follow-up studies ( $P = 0.091$ ). A similar analysis of ES vs publication year using random effects model showed a trend toward increasing ES since 2010

although statistically not significant ( $P = 0.186$ ) presumably representing clinical treatment improvements due to technology advancements. Publication bias analysis showed overall observed ES as 0.92 (ODI), 0.8 (VAS back), and 0.92 (VAS leg) with a significant improvement ( $P < 0.0001$  for all 3 outcome instruments) on Egger linear regression with an intercept =  $-0.82$  and  $t = -0.51$  for ODI, an intercept =  $1.62$  and  $t = 0.74$  for VAS back, and an intercept =  $0.39$  and  $t = 0.25$  for VAS leg. Seventy-two of the 89 studies included in this meta-analysis were retrospective studies. Twelve studies were prospective, and another 5 studies were randomized prospective clinical trials both of which had multiple treatment arms. Twenty-four of the 36 studies included in the meta-analysis with longer than 2-year follow-up were retrospective studies and were estimated to have a high ROB. This was reflected in the asymmetric funnel plot with a significant number of studies falling outside the expected area of SE vs ES plot suggesting that the bias in the underlying studies put the authors' overall meta-analysis at moderate ROB.

### Meta-Analysis by Modifiers

The impact of study design on ES was minimal and statistically not significantly different among retrospective, prospective, and randomized prospective trials (Table 3). The mean ODI analysis on 17,921 patients' samples showed ES of 0.92 for retrospective, ES of 0.92 for prospective, and ES of 0.91 for randomized prospective trials ( $P = 0.925$ ). The mean VAS back analysis on 8002 patients' samples also did not show any statistically significant impact of study design on ES: ES of 0.8 for retrospective, ES of 0.6 for prospective, and ES of 0.81 for randomized prospective trials ( $P = 0.204$ ). Similarly, the mean VAS leg analysis on 17,295 patients' samples also did not show any statistically significant impact of study design on ES: ES of 0.91 for retrospective, ES of 0.93 for prospective, and ES of 0.88 for randomized prospective trials ( $P = 0.575$ ).

The indication for surgery was another modifier studied in our meta-analysis (Table 4). Extracted ODI means analysis showed a higher overall ES for endoscopic decompression of spinal stenosis-related claudication symptoms (ES = 0.95; 1638 patients pooled from 14 studies) than for herniated disc (ES = 0.92; 3520 patients pooled from 22 studies) or discogenic back pain (ES = 0.91; 216 patients pooled from 2 studies) at statistically insignificant level ( $P = 0.094$ ). Moreover, extracted means analysis for VAS back ( $P = 0.074$ ) and VAS leg ( $P = 0.74$ ) did not produce any significant difference in overall ES for either of these 3 indications

**Table 1.** List of short-term (<2-year follow-up) lumbar decompression studies included into the effect size meta-analysis comparing endoscopic to other translaminar decompression surgeries with brief summary of study highlights.

#	Authors	Year	Title	Reference	Study Highlights
1.	Abudurexiti T, Qi L, et al <sup>36</sup>	2018	Microendoscopic discectomy vs percutaneous endoscopic surgery for lumbar disk herniation.	<i>J Int Med Res</i> 2018;46:3910–7.	Prospective study comparing PELD vs MED in the treatment of 216 patients with lumbar disc herniation
2.	Ahn JS, Lee HJ, et al <sup>78</sup>	2018	Extraforaminal approach of biportal endoscopic spinal surgery: a new endoscopic technique for transforaminal decompression and discectomy.	<i>J Neurosurg Spine</i> 2018;28:492–8.	Retrospective cohort study of 21 patients treated with biportal endoscopic spinal surgery as a new endoscopic technique for transforaminal decompression
3.	Ao S, Wu J, et al <sup>19</sup>	2019	Percutaneous endoscopic lumbar discectomy assisted by O-arm-based navigation improves the learning curve.	<i>Biomed Res Int</i> 2019;2019:6509409.	Prospective cohort study of 118 patients to assess the safety and efficacy of PELD assisted by O-arm-based navigation for treating LDH
4.	Cao S, Cui H, et al <sup>138</sup>	2019	"Tube in tube" interlaminar endoscopic decompression for the treatment of lumbar spinal stenosis: technique notes and preliminary clinical outcomes of case series.	<i>Medicine (Baltimore)</i> 2019;98:e17021.	Retrospective efficacy and safety study of 35 patients treated with tube-in-tube interlaminar endoscopic MED decompression in treating LSS
5.	Chen Z, Zhang L, et al <sup>114</sup>	2018	Percutaneous transforaminal endoscopic discectomy compared with microendoscopic discectomy for lumbar disc herniation: 1 year results of an ongoing randomized controlled trial.	<i>J Neurosurg Spine</i> 2018;28:300–10.	Randomized prospective controlled study of 153 patients to investigate whether percutaneous transforaminal endoscopic discectomy results in better clinical outcomes and less surgical trauma than MED
6.	Choi G, Lee SH, et al <sup>139</sup>	2006	Percutaneous endoscopic interlaminar discectomy for intracanalicular disc herniations at L5-S1 using a rigid working channel endoscope.	<i>Neurosurgery</i> 2006;58:ONS59–68; discussion ONS59–68.	Retrospective study of 65 patients on the procedure and clinical results of interlaminar L5-S1 level PELD and the relevant surgical anatomy
7.	Dabo X, Ziqiang C, et al <sup>24</sup>	2016	The clinical results of percutaneous endoscopic interlaminar discectomy (PEID) in the treatment of calcified lumbar disc herniation: a case-control study.	<i>Pain Physician</i> 2016;19:69–76.	Retrospective case-control study of 30 patients treated with PELD for calcified and noncalcified lumbar disc herniations
8.	Eun SS, Chachan S, et al <sup>140</sup>	2018	Interlaminar percutaneous endoscopic lumbar discectomy: rotate and retract technique.	<i>World Neurosurg</i> 2018;118:188–92.	Retrospective study of 17 patients who underwent interlaminar PELD with the rotate and retract technique
9.	Eun SS, Eum JH, et al <sup>112</sup>	2017	Biportal endoscopic lumbar decompression for lumbar disc herniation and spinal canal stenosis: a technical note.	<i>J Neurol Surg A Cent Eur Neurosurg</i> 2017;78:390–6.	Retrospective study of 17 patients treated with biportal endoscopic lumbar decompression technique using 2 portals to treat difficult lumbar disc herniations and also lumbar spinal stenoses
10.	Gadjradj, Pravesh S, et al <sup>141</sup>	2016	Clinical outcomes after percutaneous transforaminal endoscopic discectomy for lumbar disc herniation: a prospective case series.	<i>Neurosurg Focus</i> . 2016 Feb;40(2):E3.	Prospective study of 166 patients who underwent surgery for a total of 167 LDH
11.	He S, Sun Z, et al <sup>26</sup>	2018	Combining YESS and TESSYS techniques during percutaneous transforaminal endoscopic discectomy for multilevel lumbar disc herniation.	<i>Medicine (Baltimore)</i> 2018;97:e11240.	Retrospective study on 52 patients with multilevel LDH treated with combination of YESS and TESSYS
12.	Heo DH, Lee DC, et al <sup>113</sup>	2019	Comparative analysis of three types of minimally invasive decompressive surgery for lumbar central stenosis: biportal endoscopy, uniportal endoscopy, and microsurgery.	<i>Neurosurg Focus</i> 2019;46:E9.	Retrospective study on MED vs endoscopic unilateral laminotomy with bilateral decompression to treat lumbar canal stenosis
13.	Heo DH, Sharma S, et al <sup>66</sup>	2019	Endoscopic treatment of extraforaminal entrapment of L5 nerve root (far out syndrome) by unilateral biportal endoscopic approach: technical report and preliminary clinical results.	<i>Neurospine</i> 2019;16:130–7.	Retrospective consecutive of 16 patients with unilateral extraforaminal entrapment of the L5 nerve root (far out syndrome) treated with percutaneous biportal endoscopies
14.	Hsu HT, Chang SJ, et al <sup>142</sup>	2013	Learning curve of full-endoscopic lumbar discectomy.	<i>Eur Spine J</i> 2013;22:727–33.	Retrospective study of 57 patients who underwent full-endoscopic lumbar discectomy and 66 patients who underwent open microdiscectomy
15.	Hu A, Gu X, et al <sup>5</sup>	2018	Epidural vs intravenous steroids application following percutaneous endoscopic lumbar discectomy.	<i>Medicine (Baltimore)</i> 2018;97:e0654.	Retrospective study of LDH patients who had undergone transforaminal PELD comparing epidural steroid, intravenous steroid to control a group each containing 60 patients

Table 1. Continued.

#	Authors	Year	Title	Reference	Study Highlights
16.	Hu Z, Li X, et al <sup>45</sup>	2017	Significance of preoperative planning software for puncture and channel establishment in percutaneous endoscopic lumbar discectomy: a study of 40 cases.	<i>Int J Surg</i> 2017;41:97–103.	Retrospective study of 40 patients to compare the clinical efficacy of preoperative planning software in puncture and channel establishment of PELD
17.	Hua W, Tu J, et al <sup>13</sup>	2018	Full-endoscopic discectomy via the interlaminar approach for disc herniation at L4-L5 and L5-S1: an observational study.	<i>Medicine (Baltimore)</i> 2018;97:e0585.	Retrospective study of 80 patients to investigate the clinical outcomes of full-endoscopic discectomy via the interlaminar approach for LDH at L4-L5 under general anesthesia
18.	Hua W, Zhang Y, et al <sup>7</sup>	2018	Outcomes of discectomy by using full-endoscopic visualization technique via the interlaminar and transforaminal approaches in the treatment of L5-S1 disc herniation: an observational study.	<i>Medicine (Baltimore)</i> 2018;97:e13456.	Retrospective study of 60 patients treated with full-endoscopic visualization technique via the interlaminar approach vs the transforaminal approach for LDH under general anesthesia
19.	Hubbe U, Franco-Jimenez P, et al <sup>143</sup>	2006	Minimally invasive tubular microdiscectomy for recurrent lumbar disc herniation.	<i>J Neurosurg Spine</i> 2016;24:48–53.	Retrospective safety and efficacy of minimally invasive tubular microdiscectomy LDH
20.	Hwa Eum J, Hwa Heo D, et al <sup>74</sup>	2016	Percutaneous biportal endoscopic decompression for lumbar spinal stenosis: a technical note and preliminary clinical results.	<i>J Neurosurg Spine</i> 2016;24:602–7.	Retrospective study of 58 single-level lumbar stenosis patients who underwent unilateral laminotomy with bilateral foraminal decompression using a unilateral biportal endoscopic system
21.	Kapetanakis S, Giannopoulos E, et al <sup>144</sup>	2016	Transforaminal percutaneous endoscopic discectomy in Parkinson disease: preliminary results and short review of the literature.	<i>Korean J Spine</i> 2016;13:144–50.	Retrospective case-control effectiveness study of transforaminal PELD in 10 Parkinson patients and 10 control patients
22.	Kim HS, Adsul N, et al <sup>145</sup>	2018	Full-endoscopic lumbar discectomy using the calcification floating technique for symptomatic partially calcified lumbar herniated nucleus pulposus.	<i>World Neurosurg</i> 2018;119:500–5.	Retrospective study of 31 patients who underwent full-endoscopic discectomy using free floating technique for partially calcified lumbar HNP
23.	Kim HS, Adsul N, et al <sup>1</sup>	2018	A mobile outside-in technique of transforaminal lumbar endoscopy for lumbar disc herniations.	<i>J Vis Exp</i> 2018.	Prospective study of 184 patients to describe the technical aspects of a novel mobile outside-in method in dealing with different types of disc prolapse
24.	Kim HS, Paudel B, et al <sup>56</sup>	2018	Percutaneous endoscopic lumbar discectomy for all types of lumbar disc herniations (LDH) including severely difficult and extremely difficult LDH cases.	<i>Pain Physician</i> 2018;21:E401-E8.	Retrospective consecutive case study of 98 patients who underwent PELD for severely difficult and extremely difficult
25.	Kim HS, Yudoyono F, et al <sup>68</sup>	2017	Analysis of clinical results of three different routes of percutaneous endoscopic transforaminal lumbar discectomy for lumbar herniated disk.	<i>World Neurosurg</i> 2017;103:442–8.	Retrospective study of 71 transforaminal PELD patients divided in the foraminal (group A), intervertebral (group B), and suprapedicular (group C) with 32, 46, and 33 patients, respectively
26.	Li LJ, Chang F, et al <sup>146</sup>	2018	Clinical effects of percutaneous endoscopic transforaminal decompression for the treatment of lumbar spinal stenosis.	<i>Zhongguo Gu Shang</i> 2018;31:617–20.	Retrospective study of 67 patients who underwent transforaminal PELD for lumbar spinal stenosis
27.	Li M, Yang H, et al <sup>27</sup>	2015	Full-endoscopic technique discectomy vs microendoscopic discectomy for the surgical treatment of lumbar disc herniation.	<i>Pain Physician</i> 2015;18:359–63.	Restrospective study of 85 patients treated with PELD vs MED for LDH
28.	Li XF, Jin LY, et al <sup>147</sup>	2019	Endoscopic ventral decompression for spinal stenosis with degenerative spondylolisthesis by partially removing posteriorsuperior margin underneath the slipping vertebral body: technical note and outcome evaluation.	<i>World Neurosurg</i> 2019;126:e517-e25.	Retrospective study of 25 patients to describe the percutaneous transforaminal endoscopic ventral decompression technique
29.	Liu W, Li Q, et al <sup>4</sup>	2019	Clinical efficacy of percutaneous transforaminal endoscopic discectomy in treating adolescent lumbar disc herniation.	<i>Medicine (Baltimore)</i> 2019;98:e14682.	Retrospective study of 43 adolescent patients diagnosed with single-segment LDH treated with transforaminal PELD
30.	Liu X, Yuan S, et al <sup>111</sup>	2018	Comparison of percutaneous endoscopic transforaminal discectomy, microendoscopic discectomy, and microdiscectomy for symptomatic lumbar disc herniation: minimum 2 year follow-up results.	<i>J Neurosurg Spine</i> 2018;28:317–25.	Retrospective study of 192 LDH patients at L3-L4 and L4-L5 divided into PELD (60 patients), MED (63 patients), and microdiscectomy (69 patients)

Table 1. Continued.

#	Authors	Year	Title	Reference	Study Highlights
31.	Liu Y, Cai P, et al <sup>148</sup>	2017	Effectiveness of percutaneous endoscopic spine surgery for treatment of lumbar spine disorders with intraspinal ossification.	<i>Zhongguo Xiu Fu Chong Jian Wai Ke Za Zhi</i> 2017;31:1326–33.	Retrospective study of 96 patients with LDH and LSS with intraspinal ossification were treated with PELD
32.	Madhavan K, Chieng LO, et al <sup>149</sup>	2016	Early experience with endoscopic foraminotomy in patients with moderate degenerative deformity.	<i>Neurosurg Focus</i> 2016;40:E6.	Retrospective study of retrospective analysis of 16 patients with coronal deformity of between 10° and 20° treated with PELD
33.	Pan Z, Ha Y, et al <sup>42</sup>	2016	Efficacy of transforaminal endoscopic spine system (TESSYS) technique in treating lumbar disc herniation.	<i>Med Sci Monit</i> 2016;22:530–9.	Retrospective study efficacy and safety study in 109 patients treated with percutaneous TESSYS and traditional fenestration discectomy
34.	Sang PM, Zhang M, et al <sup>150</sup>	2018	Treatment of migrated lumbar disc herniation with percutaneous endoscopic lumbar discectomy and target foraminoplasty.	<i>Zhongguo Gu Shang</i> 2018;31:302–5.	Retrospective study of 25 patients with migrated LDH were treated with PELD with target foraminoplasty
35.	Shi C, Kong W, et al <sup>9</sup>	2018	The early clinical outcomes of a percutaneous full-endoscopic interlaminar approach via a surrounding nerve root discectomy operative route for the treatment of ventral-type lumbar disc herniation.	<i>Biomed Res Int</i> 2018;2018:9157089.	Retrospective study of 22 patients undergoing full-endoscopic interlaminar discectomy for ventral LDH via both the shoulder and the axilla of the corresponding nerve root
36.	Shin SH, Bae JS, et al <sup>151</sup>	2018	Transforaminal endoscopic decompression for lumbar spinal stenosis: a novel surgical technique and clinical outcomes.	<i>World Neurosurg</i> 2018;114:e873–e82.	Retrospective study of 30 consecutive cases LCS treated with transforaminal endoscopic decompression
37.	Sun Y, Zhang W, et al <sup>38</sup>	2017	Comprehensive comparing percutaneous endoscopic lumbar discectomy with posterior lumbar internal fixation for treatment of adjacent segment lumbar disc prolapse with stable retrolisthesis: a retrospective case-control study.	<i>Medicine (Baltimore)</i> 2017;96:e7471.	Retrospective comparison study PELD (11 patients) and PLIF (13 patients) for treatment of adjacent segment lumbar disc prolapse with stable retrolisthesis after a previous fusion
38.	Tang S, Jin S, et al <sup>25</sup>	2018	Transforaminal percutaneous endoscopic lumbar decompression by using rigid bendable burr for lumbar lateral recess stenosis: technique and clinical outcome.	<i>Biomed Res Int</i> 2018;2018:2601232.	Retrospective comparative study PELD open decompression in LSS in 48 consecutive patients
39.	Tao, X. Z., Jing, L, et al <sup>20</sup>	2018	Therapeutic effect of transforaminal endoscopic spine system in the treatment of prolapse of lumbar intervertebral disc.	<i>Eur Rev Med Pharmacol Sci</i> . 2018 Jul;22(1 Suppl):103–110.	Randomized prospective trial of 462 LDH patients treated with PELD ( $n = 231$ ) and open decompression in the control group ( $n = 231$ )
40.	Wang H, Zhou Y, et al <sup>18</sup>	2015	Risk factors for failure of single-level percutaneous endoscopic lumbar discectomy.	<i>J Neurosurg Spine</i> 2015;23:320–5.	Retrospective study to identify risk factors for failure of PELD for single-level LDH in 350 patients who underwent PELD
41.	Wang J, Zhou Y, et al <sup>152</sup>	2009	Percutaneous endoscopic lumbar discectomy for treatment of chronic discogenic low back pain.	<i>Zhongguo Xiu Fu Chong Jian Wai Ke Za Zhi</i> 2009;23:400–3.	Retrospective study of 52 PELD patients with discogenic chronic low back pain
42.	Wang SJ, Chen BH, et al <sup>23</sup>	2017	The effect of percutaneous endoscopic lumbar discectomy under different anesthesia on pain and immunity of patients with prolapse of lumbar intervertebral disc.	<i>Eur Rev Med Pharmacol Sci</i> 2017;21:2793–9.	Restrospective study of 82 PELD patients under different anesthesia on pain and immunity of patients with lumbar disc herniation
43.	Wang Y, Yan Y, et al <sup>153</sup>	2019	Outcomes of percutaneous endoscopic transarticular discectomy for huge central or paracentral lumbar disc herniation.	<i>Int Orthop</i> 2019;43:939–45.	Retrospective study on 16 patients undergoing percutaneous endoscopic transarticular discectomy for huge central/paracentral LDH
44.	Wen B, Zhang X, et al <sup>43</sup>	2016	Percutaneous endoscopic transforaminal lumbar spinal canal decompression for lumbar spinal stenosis.	<i>Medicine (Baltimore)</i> 2016;95:e5186.	Retrospective study of 64 patients with lumbar spinal stenosis who underwent percutaneous endoscopic lumbar spinal canal decompression
45.	Wu GN, Zhang SM, et al <sup>154</sup>	2017	Percutaneous endoscopic lumbar discectomy for the treatment of lumbar intervertebral disc protrusion.	<i>Zhongguo Gu Shang</i> 2017;30:861–5.	Retrospective study of 46 PELD patients treated for LDH.
46.	Xin Z, Huang P, et al <sup>51</sup>	2019	Using a percutaneous spinal endoscopy unilateral posterior interlaminar approach to perform bilateral decompression for patients with lumbar lateral recess stenosis.	<i>Asian J Surg</i> 2019.	Retrospective study of 47 patients with bilateral symptomatic LCS treated with percutaneous spinal endoscopy via a unilateral posterior interlaminar approach with bilateral decompression



Table 1. Continued.

#	Authors	Year	Title	Reference	Study Highlights
47.	Xiong C, Li T, et al <sup>116</sup>	2009	Early outcomes of 270 degree spinal canal decompression by using TESSYS-ISEE technique in patients with lumbar spinal stenosis combined with disk herniation.	<i>Eur Spine J</i> 2019;28:78–86.	Retrospective study of 32 patients with LSS due to LDH with newly developed minimal invasive TESSYS-ISEE technique
48.	Xu B, Xu H, et al <sup>11</sup>	2017	Anatomic investigation of lumbar transforaminal fenestration approach and its clinical application in far lateral disc herniation.	<i>Medicine (Baltimore)</i> 2017;96:e7542.	Retrospective study of 30 patients with LDH underwent MED via the transforaminal fenestration approach
49.	Xu Z, Liu Y, et al <sup>28</sup>	2018	Percutaneous ndoscopic interlaminar discectomy for L5-S1 adolescent lumbar disc herniation.	<i>Turk Neurosurg</i> 2018;28:923–8.	Retrospective study of 23 adolescent patients who underwent percutaneous endoscopic interlaminar discectomy for L5-S1 LDH
50.	Yang D, Wu X, et al <sup>155</sup>	2018	A modified percutaneous endoscopic technique to remove extraforaminal disk herniation at the L5-S1 segment.	<i>World Neurosurg</i> 2018;119:e671-e8.	Retrospective study of 100 extraforaminal LDH patients. The geometric parameters of the transverse process, facet joint, and sacrum space based on imaging examination were measured
51.	Yang JC, Hai Y, et al <sup>156</sup>	2018	Percutaneous endoscopic transforaminal lumbar interbody fusion for lumbar spinal stenosis.	<i>Zhonghua Yi Xue Za Zhi</i> 2018;98:3711–5.	Retrospective study of percutaneous endoscopic transforaminal lumbar interbody fusion in 7 patients with L4-L5 single-segment lumbar spinal stenosis
52.	Ying J, Huang K, et al <sup>40</sup>	2016	The effect and feasibility study of transforaminal percutaneous endoscopic lumbar discectomy via superior border of inferior pedicle approach for down-migrated intracanal disc herniations.	<i>Medicine (Baltimore)</i> 2016;95:e2899.	Retrospective study of 45 PELD patients with down-migrated single-level LDH treated with upper border of inferior pedicle, foraminoplasty, or common transforaminal route
53.	Zhang J, Jin MR, et al <sup>185</sup>	2019	Clinical application of percutaneous transforaminal endoscope-assisted lumbar interbody fusion.	<i>Zhongguo Gu Shang</i> 2019;32:1138–43.	Retrospective safety and efficacy study on 25 patients percutaneous transforaminal endoscope-assisted lumbar interbody fusion

Abbreviations: HNP, Herniated Nucleus Pulposus; ISEE, Interlaminar Endoscopy; LCS, lateral canal stenosis; LDH, lumbar disc herniation; LSS, lumbar spinal stenosis; MED, minimally endoscopic discectomy; PELD, percutaneous endoscopic lumbar discectomy; TESSYS, transforaminal endoscopic spine system; YESS, Yeung endoscopic spine system.

(Table 4). Another question of interest to the authors was the impact of long-term vs short-term follow-up on the overall ES for the 3 clinical outcome instruments measuring benefit from the lumbar endoscopic spine surgery for indications investigated (Table 5). The highest overall ES numbers were calculated at 2-year follow-up for VAS leg (ES = 0.94;  $P < 0.0001$ ; based on total 17,295 patient samples) and VAS back (ES = 0.9;  $P < 0.0001$ ; based on total of 8002 patient samples pooled from 55 studies) at a statistically significant level. The overall ES based on the extracted ODI means from a total of 17,543 patients pooled from 108 study entries at 2-year follow-up and longer was ES = 0.92 without statistical significance ( $P = 0.678$ ; Table 5).

Using the type of decompression as a modifier in calculating the overall ES in endoscopic spinal decompression surgeries allowed to compare postoperative improvements in ODI, VAS back, and VAS leg to those achieved with other types of decompression surgeries as they were used in multiarm comparison studies (Table 6). Spinal endoscopy produced an overall ODI ES of 0.92 extrapolated from 81 studies totaling 12,710 patient samples. Tubular retractor microdiscectomy

produced smaller ODI ES (ES = 0.9; 2895 patient samples pooled from 16 studies) than open laminectomy (ES = 0.93; 1188 patient samples from 5 studies). The highest ODI ES was observed with endoscopically assisted minimally invasive fusions with percutaneous posterior supplemental pedicle screw instrumentation (ES = 0.95; 166 patient samples pooled from 4 studies; Table 4). Similar, VAS leg ESs were observed with endoscopy (ES = 0.92; 12,631 patient samples pooled from 80 studies) with spinal endoscopy, with small and statistically insignificant ( $P = 0.592$ ) ES difference to the other MISST procedures listed in Table 6. The VAS back ESs were smaller without any statistically significant difference between spinal endoscopy and the other various MISSTs that were evaluated in the individual multitreatment arm comparison studies ( $P = 0.4167$ ; 8002 patient samples from 55 studies; Table 6). The postoperative benefit overlap is graphically illustrated in Figure 2. The largest overall ES with the smallest SE was observed with laminectomy, tubular retractor microdiscectomy, and with endoscopically assisted MISST fusion and standalone endoscopic fusion surgery ( $P = 0.022$ ). There was a wider scatter between

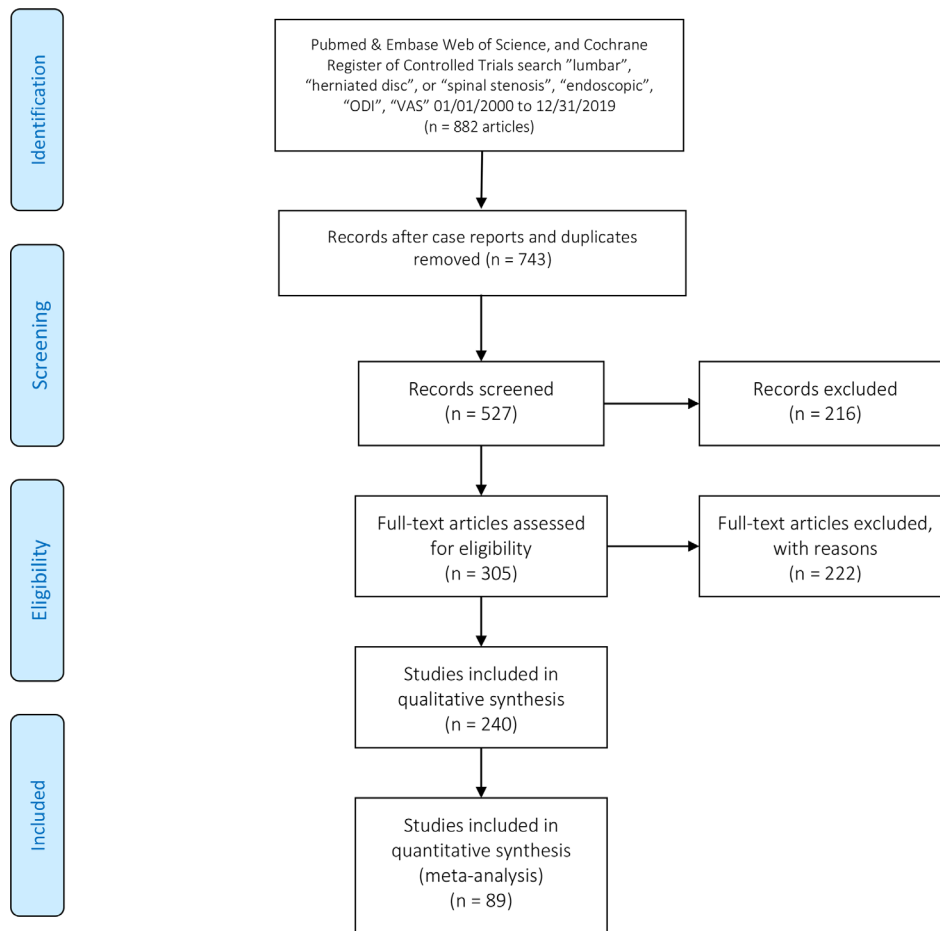
**Table 2.** List of long-term (>2-year follow-up) lumbar stenosis decompression studies included into the effect size meta-analysis comparing endoscopic to other translaminar decompression surgeries with brief summary of study highlights.

#	Authors	Year	Title	Reference	Study Highlights
1.	Ahn Y, Keum H, et al <sup>157</sup>	2019	Transforaminal endoscopic decompression for lumbar lateral recess stenosis: an advanced surgical technique and clinical outcomes.	<i>World Neurosurg</i> 2019;125:e916-e24.	Retrospective study of 45 consecutive patients who underwent transforaminal endoscopic decompression for LCS.
2.	Ahn Y, Lee HY, et al <sup>158</sup>	2011	Dural tears in percutaneous endoscopic lumbar discectomy.	<i>Eur Spine J</i> 2011;20:58-64.	Retrospective study of 816 consecutive PELD patients to assess frequency of dural tears.
3.	Ahn Y, Lee SG, et al <sup>159</sup>	2009	Transforaminal endoscopic lumbar discectomy vs open lumbar microdiscectomy: a comparative cohort study with a 5 year follow-up.	<i>Pain Physician</i> 2019;22:295-304.	Prospective study of 335 LDH patients treated with PELD or open lumbar microdiscectomy.
4.	Ahn Y, Lee U, et al <sup>160</sup>	2018	Five-year outcomes and predictive factors of transforaminal full-endoscopic lumbar discectomy.	<i>Medicine (Baltimore)</i> 2018;97:e13454.	Retrospective 5-y outcomes study of 204 transforaminal PELD patients to determine the factors predicting favorable outcome.
5.	Bai YB, Xu L, et al <sup>159</sup>	2012	Diagnosis and treatment of lumbar disc herniation by discography and percutaneous transforaminal endoscopic surgery.	<i>Zhonghua Yi Xue Za Zhi</i> 2012;92:3350-3.	Retrospective study of 119 patients with lumbar disc herniation who underwent discography and transforaminal endoscopic surgery under focal anesthesia.
6.	Casal-Moro R, Castro-Mendez M, et al <sup>160</sup>	2011	Long-term outcome after microendoscopic discectomy for lumbar disk herniation: a prospective clinical study with a 5 year follow-up.	<i>Neurosurgery</i> 2011;68:1568-75; discussion 75.	Prospective study of 120 LDH patients treated with MED using an 18-mm tubular retractor.
7.	Choi G, Lee SH, et al <sup>161</sup>	2007	Percutaneous endoscopic discectomy for extraforaminal lumbar disc herniations: extraforaminal targeted fragmentectomy technique using working channel endoscope.	<i>Spine (Phila Pa 1976)</i> 2007;32:E933-9.	Retrospective analysis of 41 patients with soft lumbar extraforaminal disc herniation treated with PELD.
8.	Choi G, Modi HN, et al <sup>162</sup>	2013	Clinical results of XMR-assisted percutaneous transforaminal endoscopic lumbar discectomy.	<i>J Orthop Surg Res</i> 2013;8:14.	Prospective study of 89 LDH patients who had undergone PELD.
9.	Choi KC, Kim JS, et al <sup>163</sup>	2016	Percutaneous endoscopic lumbar discectomy as an alternative to open lumbar microdiscectomy for large lumbar disc herniation.	<i>Pain Physician</i> 2016;19:E291-300.	Retrospective study of 30 consecutive patients treated with transforaminal and interlaminar PELD for L5-S1 disc herniation.
10.	Choi KC, Park CK <sup>76</sup>	2016	Percutaneous endoscopic lumbar discectomy for L5-S1 disc herniation: consideration of the relation between the Iliac crest and L5-S1 disc.	<i>Pain Physician</i> 2016;19:E301-8.	Retrospective study of 100 consecutive L5-S1 PELD patients with and without foraminoplasty.
11.	Chung J, Kong C, et al <sup>164</sup>	2019	Percutaneous endoscopic lumbar foraminoplasty for lumbar foraminal stenosis of elderly patients with unilateral radiculopathy: radiographic changes in magnetic resonance images.	<i>J Neurol Surg A Cent Eur Neurosurg</i> 2019;80:302-11.	Retrospective study of 24 patients aged >65 y underwent PELD to treat unilateral radiculopathy caused by LCS.
12.	Dey PC, Nanda SN <sup>60</sup>	2019	Functional outcome after endoscopic lumbar discectomy by Destandau's technique: a prospective study of 614 patients.	<i>Asian Spine J</i> 2019;13:786-92.	Prospective study of 614 LDH patients treated with PELD.
13.	Eun SS, Lee SH, et al <sup>165</sup>	2018	Transforaminal percutaneous endoscopic lumbar discectomy for down-migrated disk herniations: lever-up, rotate, and tilt technique.	<i>J Neurol Surg A Cent Eur Neurosurg</i> 2018;79:163-8.	Retrospective review of 18 LDH patients who underwent PELD.
14.	Gibson JNA, Subramanian AS, et al <sup>166</sup>	2017	A randomized controlled trial of transforaminal endoscopic discectomy vs microdiscectomy.	<i>Eur Spine J</i> 2017;26:847-56.	Randomized prospective study of 143 single-level LDH patients: 70 received TED under conscious sedation and 70 MED under general anesthesia.
15.	Hong X, Shi R, et al <sup>167</sup>	2018	Lumbar disc herniation treated by microendoscopic discectomy: prognostic predictors of long-term postoperative outcome.	<i>Orthopaed</i> 2018;47:993-1002.	Retrospective study of 664 LDH patients who suffered from sciatica and underwent primary MED.
16.	Kim JE, Choi DJ <sup>65</sup>	2018	Clinical and radiological outcomes of unilateral biportal endoscopic decompression by 30 degrees arthroscopy in lumbar spinal stenosis: minimum 2 year follow-up.	<i>Clin Orthop Surg</i> 2018;10:328-36.	Retrospective study of 55 LSS patients treated with PELD.
17.	Kim JE, Choi DJ <sup>67</sup>	2018	Unilateral biportal endoscopic decompression by 30 degrees arthroscopy in lumbar spinal stenosis: technical note and preliminary report.	<i>J Orthop</i> 2018;15:366-71.	Retrospective study of 105 patients receiving 30° endoscopy through biportals or triportals.
18.	Komp M, Hahn P, et al <sup>67</sup>	2015	Bilateral spinal decompression of lumbar central stenosis with the full-endoscopic interlaminar vs microsurgical laminotomy technique: a prospective, randomized, controlled study	<i>Pain Physician</i> . 2015 Jan-Feb;18(1):61-70.	Randomized prospective study of 135 patients comparing FEID with a conventional microsurgical laminotomy technique.
19.	Kong W, Chen T, et al <sup>11</sup>	2019	Treatment of L5-S1 intervertebral disc herniation with posterior percutaneous full-endoscopic discectomy by grafting tubes at various positions via an interlaminar approach.	<i>BMC Surg</i> 2019;19:124.	Retrospective study on 98 patients with L5-S1 LDH were treated with PELD.
20.	Lee SH, Kang HS, et al <sup>168</sup>	2010	Foraminoplasty ventral epidural approach for removal of extruded herniated fragment at the L5-S1 level.	<i>Neurol Med Chir (Tokyo)</i> 2010;50:1074-8.	Retrospective review was performed of 25 consecutive LDH patients treated with PELD with foraminoplasty.
21.	Lowandrowski KU, Ostergren M, et al <sup>169</sup>	2018	Intradiscal expandable balloon distraction during transforaminal decompression for lumbar foraminal and lateral recess stenosis.	<i>Surg Innov</i> 2018;25:165-73.	Retrospective study of 52 patients with symptomatic LCS treated with PELD.
22.	Li H, Jiang C, et al <sup>52</sup>	2018	Comparison of MED and PELD in the treatment of adolescent lumbar disc herniation: a 5 year retrospective follow-up.	<i>World Neurosurg</i> 2018;112:e255-e60.	Retrospective efficacy and safety study MED and PELD in the treatment of 30 ALDH patients.
23.	Li ZZ, Hou SX, et al <sup>30</sup>	2017	Modified percutaneous lumbar foraminoplasty and percutaneous endoscopic lumbar discectomy: instrument design, technique notes, and 5 years follow-up.	<i>Pain Physician</i> 2017;20:E85-E98.	Prospective cohort study of 148 patients with uncontained LDH was treated with modified percutaneous lumbar foraminoplasty PELD.
24.	Lubbers, T, Abuamona, R., et al <sup>170</sup>	2012	Percutaneous endoscopic treatment of foraminal and extraforaminal disc herniation at the L5-S1 level.	<i>Acta Neurochir (Wien)</i> . 2012 Oct;154(10):1789-95.	Prospective study of 22 PELD patients with lateral and far lateral LDH at the L5-S1.
25.	Pan F, Shen B, et al <sup>49</sup>	2016	Transforaminal endoscopic system technique for discogenic low back pain: a prospective cohort study.	<i>Int J Surg</i> 2016;35:134-8.	Retrospective study 77 consecutive patients treated with PELD for discogenic low back pain.
26.	Shawky Abdelgawad A, Babic D, et al <sup>171</sup>	2018	Extraforaminal microscopically-assisted percutaneous nucleotomy for foraminal and extraforaminal lumbar disc herniations.	<i>Spine J</i> 2018;18:620-5.	Prospective cohort study of 76 patients with foraminal or extraforaminal LDH treated with tubular percutaneous extraforaminal microscopically-assisted nucleotomy.
27.	Soliman HM <sup>172</sup>	2013	Irrigation endoscopic discectomy: a novel percutaneous approach for lumbar disc prolapse.	<i>Eur Spine J</i> 2013;22:1037-44.	Prospective of 43 patients with uncontained LDH underwent surgery biportal with irrigation endoscopic discectomy.

Table 2. Continued.

#	Authors	Year	Title	Reference	Study Highlights
28.	Song H, Hu W, et al <sup>16</sup>	2017	Percutaneous endoscopic interlaminar discectomy of L5-S1 disc herniation: a comparison between intermittent endoscopy technique and full endoscopy technique.	<i>J Orthop Surg Res</i> 2017;12:162.	Retrospective study of 126 patients intermittent endoscopy technique and full endoscopy technique of endoscopic interlaminar lumbar discectomy at the L5-S1.
29.	Teli M, Lovi A, et al <sup>173</sup>	2010	Higher risk of dural tears and recurrent herniation with lumbar microendoscopic discectomy.	<i>Eur Spine J</i> 2010;19:443–50.	Randomized controlled trial of 240 patients was randomized to microendoscopic (group 1), micro (group 2) or open (group 3) discectomy with minimum 2-y follow-up.
30.	Tu Z, Wang B, et al <sup>83</sup>	2018	Early experience of full-endoscopic interlaminar discectomy for adolescent lumbar disc herniation with sciatic scoliosis.	<i>Pain Physician</i> 2018;21:E63-E70.	Retrospective case series of patients aged < 20 y with single-level ALDH with and without scoliosis treated with
31.	Wang Y, Zhang W, et al <sup>10</sup>	2018	Transforaminal endoscopic discectomy for treatment of central disc herniation: surgical techniques and clinical outcome.	<i>Pain Physician</i> 2018;21:E113-E23.	FEED: average follow-up 39.0 mo.
32.	Wang YP, Zhang W, et al <sup>83</sup>	2016	Suprapedicular foraminal endoscopic approach to lumbar lateral recess decompression surgery to treat degenerative lumbar spinal stenosis.	<i>Med Sci Monit</i> 2016;22:4604–11.	Retrospective 2-y follow-up study of 69 consecutive patients treated with transforaminal PELD central disc herniation.
33.	Xu B, Xu H, et al <sup>174</sup>	2018	Bilateral decompression and intervertebral fusion via unilateral fenestration for complex lumbar spinal stenosis with a mobile microendoscopic technique.	<i>Medicine (Baltimore)</i> 2018;97:e9715.	Retrospective study of 52 patients with lumbar spinal stenosis underwent transforaminal endoscopic surgery.
34.	Youn MS, Shin JK, et al <sup>64</sup>	2018	Endoscopic posterior decompression under local anesthesia for degenerative lumbar spinal stenosis.	<i>J Neurosurg Spine</i> 2018;29:661–6.	Retrospective study on 61 patients with complex lumbar spinal stenosis (lumbar canal stenosis combined with degenerative spondylolisthesis, instability, and scoliosis) treated with Destandar-type mobile microendoscopic discectomy
35.	Zhang B, Kong Q, et al <sup>175</sup>	2019	Short-term effectiveness of percutaneous endoscopic transforaminal bilateral decompression for severe central lumbar spinal stenosis.	<i>Zhongguo Xiu Fu Chong Jian Wai Ke Za Zhi</i> 2019;33:1399–405.	Retrospective study of 50 patients (28 women and 22 men) treated for LDH with endoscopic posterior decompression under local anesthesia followed up to 24 mo postoperatively.
36.	Zhang Y, Chong F, et al <sup>17</sup>	2019	Comparison of endoscope-assisted and microscope-assisted tubular surgery for lumbar laminectomies and discectomies: minimum 2 year follow-up results.	<i>Biomed Res Int</i> 2019;2019:5321580.	Retrospective study on effectiveness and safety of bilateral transforaminal bilateral PELD decompression for severe central lumbar spinal stenosis in 44 patients.
					Retrospective study of 307 with lumbar spinal stenosis or LDH treated with endoscope- or microscope-assisted tubular laminectomy or discectomy.

Abbreviations: ALDH, adolescent lumbar disc herniation; FEED, full-endoscopic interlaminar discectomy; LCS, lateral canal stenosis; LDH, lumbar disc herniation; LSS, lumbar spinal stenosis; MED, minimally endoscopic discectomy; METRs, minimal exposure tubular retractor; PELD, percutaneous endoscopic lumbar discectomy; TED, transforaminal endoscopic discectomy.



**Figure 1.** Preferred reporting items for systematic reviews and meta-analyses flow chart of selected lumbar spinal stenosis studies found in PubMed, Embase, Web of Science, and in the Cochrane Central Register of Controlled Trials using the keywords “lumbar” and “herniated disc” or “spinal stenosis” and “endoscopic” and “ODI” and “VAS” as subject headings analyzed to compare effect sizes of endoscopic to traditional translaminar decompression with and without fusion. ODI, Oswestry Disability Index; VAS, visual analog scale.

SE and ES combinations with spinal endoscopy as a whole likely graphically representing variations in surgeon skill level, indication for surgery, and patient selection criteria (Figure 2).

The ES comparison using the type of endoscopy as a modifier in the meta-analysis on 13,184 patient samples pooled from 81 studies showed statistically significant differences ( $P < 0.0001$ ) between transforaminal

**Table 3.** Analysis of effect size, heterogeneity, and ANOVA testing of difference by study type.

	Study Design	Number of Studies Included in this Analysis	Effect Size	Lower Limit	Upper Limit	Higgins $I^2$ Statistic of Heterogeneity	Variance	Standard Error	Number of Patients
Oswestry Disability Index	Prospective study	6	0.9217	0.8644	0.9789	0.0000	0.0009	0.0292	2106
	Randomized	11	0.9100	0.8398	0.9802	0.0000	0.0013	0.0358	1891
	Retrospective study	83	0.9234	0.9095	0.9373	0.0000	0.0001	0.0071	12,464
VAS back	ANOVA $Q$ test random effects with separate estimates of $T^2$					Sig = 0.925		Total patient samples	16,461
	Prospective study	3	0.5951	0.3093	0.8809	0.0000	0.0213	0.1458	534
	Randomized	39	0.8009	0.7412	0.8606	0.0000	0.0009	0.0305	6056
VAS leg	ANOVA $Q$ test random effects with separate estimates of $T^2$					Sig = 0.204		Total patient samples	7260
	Prospective study	7	0.9318	0.8774	0.9862	0.0000	0.0008	0.0278	2258
	Randomized	7	0.8834	0.8066	0.9603	0.0000	0.0015	0.0392	1594
	ANOVA $Q$ test random effects with separate estimates of $T^2$					Sig = 0.575		Total patient samples	15,553
	Retrospective study	82	0.9134	0.8980	0.9288	0.0000	0.0001	0.0079	11,701

Abbreviations: ANOVA, analysis of variance; Sig, significance level of 95% CI; VAS, visual analog scale.

**Table 4.** Analysis of effect size, heterogeneity, and ANOVA testing of difference by surgery indication.

	Indication for Surgery	Number of Studies Included in This Analysis	Effect Size	Lower Limit	Upper Limit	Higgins I <sup>2</sup> Statistic of Heterogeneity	Variance	Standard Error	Number of Patients
Oswestry Disability Index	Discogenic pain	2	0.9112	0.8866	0.9359	0.0000	0.0002	0.0126	216
	HNP radiculopathy	22	0.9179	0.8888	0.9471	0.0000	0.0002	0.0149	3520
	Stenosis claudication	14	0.9531	0.9290	0.9772	0.0000	0.0002	0.0123	1638
	ANOVA Q test random effects with separate estimates of T <sup>2</sup>					Sig = 0.094		Total patient samples	5374
VAS back	Stenosis claudication	5	0.8745	0.7792	0.9698	0.0000	0.0024	0.0486	388
	HNP radiculopathy	10	0.7086	0.5522	0.8650	0.0000	0.0064	0.0798	1108
	ANOVA Q test random effects with separate estimates of T <sup>2</sup>					Sig = 0.074		Total patient samples	1496
	Stenosis claudication	13	0.9113	0.8673	0.9553	0.0000	0.0005	0.0225	1024
VAS leg	HNP radiculopathy	23	0.8942	0.8612	0.9273	0.0000	0.0003	0.0169	3667
	Discogenic pain	3	0.8828	0.8204	0.9452	0.0000	0.0010	0.0318	320
	ANOVA Q test random effects with separate estimates of T <sup>2</sup>					Sig = 0.74		Total patient samples	5011

Abbreviations: ANOVA, analysis of variance; HNP, herniated nucleus pulposus; Sig, significance level of 95% CI; VAS, visual analog scale.

outside-in (ODI ES = 0.9), transforaminal inside-out (ODI ES = 0.9), interlaminar (ODI ES = 0.96), and the combination of the transforaminal outside-in and interlaminar (ODI ES = 0.98), and UBE (ODI ES = 0.93; Table 7). Similar ES differences were calculated for the VAS leg on a total of 13,105 patients pooled from 85 studies at statistical significance level ( $P < 0.00001$ ) comparing outcomes between transforaminal outside-in (VAS leg ES = 0.91), transforaminal inside-out (VAS leg ES = 0.89), interlaminar (VAS leg ES = 0.93), and the combination of the transforaminal outside-in and interlaminar (VAS leg ES = 0.97), and UBE (VAS leg ES = 0.93; Table 7). Such differences were not statistically significant for the VAS back outcome means obtained on a total of 5134 patients pooled from 37 studies (Table 7). The statistically significant post-operative benefit overlap is graphically illustrated in Figure 3 ( $P = 0.001$ ). The largest ESs with the smallest SEs were observed with the combined outside-in and interlaminar technique, the transforaminal inside-out, and UBE technique. The widest scatter was seen with the transforaminal outside-in technique.

### Forest Plot Analysis of Long-Term Studies

Since the ES analysis suggested a significant difference when studied by follow-up, the authors performed a visual forest plot analysis of the ESs for the extracted means of ODI, VAS back, and VAS leg. There were 46 long-term study entries which reported ODI with a minimum of 2 years or longer. The overall ES for ODI was 0.92 with an LL of 0.9, and a UL of 0.94 calculated from the total of 9420 patient samples (Figure 4). In comparison, there were 26 studies which reported VAS back with a minimum of 2 years or longer follow-up. The overall ES for VAS back was 0.71 with an LL of 0.61, and a UL of 0.81 calculated from the total of 4926 patient samples (Figure 5). Another 44 studies reported VAS leg with a minimum of 2 years or longer follow-up. The overall ES for VAS leg was 0.71 with a lower 95% CI limit of 0.61 and a UL of 0.81 calculated from the total of 4926 patient samples (Figure 6).

### Individual Studies Results and MCID

The meta-analysis on the 36 long-term studies showed the following mean preoperative baseline

**Table 5.** Analysis of effect size, heterogeneity, and ANOVA testing of difference by length of follow-up.

	Length of Follow-Up	Number of Studies Included in This Analysis	Effect Size	Lower Limit	Upper Limit	Higgins I <sup>2</sup> Statistic of Heterogeneity	Variance	Standard Error	Number of Patients
Oswestry Disability Index	More than 2 y	45	0.9243	0.9044	0.9442	0.0000	0.0001	0.0101	9304
	Up to 2 y	46	0.9240	0.8996	0.9484	0.0000	0.0002	0.0125	5283
	Up to 12 mo	15	0.9074	0.8775	0.9372	0.0000	0.0002	0.0152	2664
	Up to 6 mo	2	0.9104	0.8862	0.9345	0.0000	0.0002	0.0123	292
	ANOVA Q test random effects with separate estimates of T <sup>2</sup>					Sig = 0.678		Total patient samples	17,543
VAS back	More than 2 y	25	0.7075	0.6043	0.8106	0.0000	0.0028	0.0526	4948
	Up to 2 y	21	0.9023	0.8723	0.9323	0.0000	0.0002	0.0153	1978
	Up to 12 mo	6	0.7007	0.5910	0.8104	0.0000	0.0031	0.0560	872
	ANOVA Q test random effects with separate estimates of T <sup>2</sup>					Sig <0.0001		Total patient samples	7798
VAS leg	More than 2 y	43	0.8920	0.8651	0.9190	0.0000	0.0002	0.0138	8690
	Up to 2 y	46	0.9441	0.9299	0.9582	0.0000	0.0001	0.0072	5237
	Up to 12 mo	16	0.8915	0.8465	0.9365	0.0000	0.0005	0.0230	2768
	Up to 6 mo	2	0.8366	0.8088	0.8643	0.0000	0.0002	0.0142	292
	ANOVA Q test random effects with separate estimates of T <sup>2</sup>					Sig <0.0001		Total patient samples	16,987

Abbreviations: ANOVA, analysis of variance; Sig, significance level of 95% CI; VAS, visual analog scale.

**Table 6.** Analysis of effect size, heterogeneity, and ANOVA testing of difference by surgery type.

Type of Surgery		Number of Studies Included in This Analysis	Effect Size	Lower Limit	Upper Limit	Higgins I <sup>2</sup> Statistic of Heterogeneity	Variance	Standard Error	Number of Patients
Oswestry Disability Index	Endoscopic-assisted MIS fusion	4	0.9496	0.9087	0.9905	0.0000	0.0004	0.0209	166
	Open laminectomy	5	0.9294	0.8793	0.9795	0.0000	0.0007	0.0255	1188
	Endoscopy	81	0.9178	0.9013	0.9343	0.0000	0.0001	0.0084	12,710
	Tubular microdiscectomy	16	0.8968	0.8543	0.9394	0.0000	0.0005	0.0217	2895
	Standalone endo fusion	1	0.8337	0.7336	0.8984	0.0000	0.0017	0.0410	36
ANOVA Q test random effects with separate estimates of T <sup>2</sup>						Sig = 0.049		Total patient samples	16,995
VAS back	Endoscopic-assisted MIS fusion	2	0.9325	0.8087	1.0563	0.0000	0.0040	0.0632	28
	Tubular microdiscectomy	11	0.8186	0.6960	0.9413	0.0000	0.0039	0.0626	1962
	Open laminectomy	4	0.7918	0.6583	0.9253	0.0000	0.0046	0.0681	726
	Endoscopy	34	0.7732	0.7122	0.8342	0.0000	0.0010	0.0311	5028
	Standalone endo fusion	1	0.7320	0.5740	0.8374	0.0000	0.0044	0.0662	36
ANOVA Q test random effects with separate estimates of T <sup>2</sup>						Sig = 0.607		Total patient samples	7780
VAS LEG	Endoscopic-assisted MIS fusion	4	0.9313	0.8945	0.9682	0.0000	0.0004	0.0188	166
	Tubular microdiscectomy	15	0.9172	0.8770	0.9574	0.0000	0.0004	0.0205	2348
	Endoscopy	80	0.9158	0.9002	0.9315	0.0000	0.0001	0.0080	12,631
	Open laminectomy	5	0.8929	0.7910	0.9949	0.0000	0.0027	0.0520	1188
	Standalone endo fusion	1	0.8796	0.8070	0.9261	0.0000	0.0009	0.0295	36
ANOVA Q test random effects with separate estimates of T <sup>2</sup>						Sig = 0.592		Total patient samples	16,369

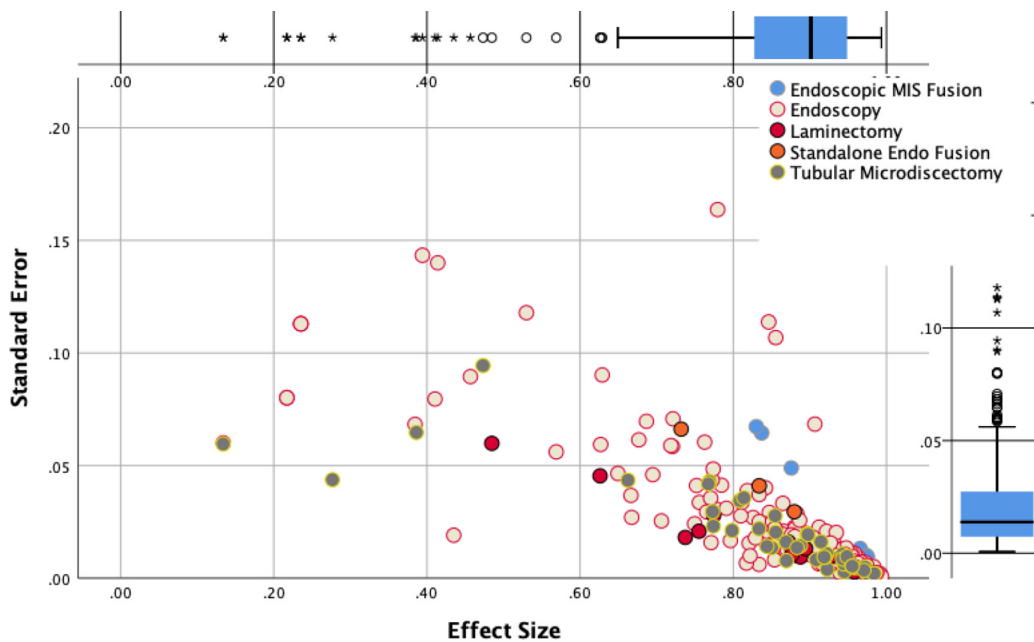
Abbreviations: ANOVA, analysis of variance; MIS, minimally invasive surgery; Sig, significance level of 95% CI; VAS, visual analog scale.

numbers: ODI 59.34 (SD 12.67), VAS back 4.90 (SD 1.89), and VAS leg 7.22 (SD 1.90), respectively. The overall improvements after endoscopic surgery were: ODI reduction of 46.25 (SD 6.10), VAS back reduction of 3.29 (SD 0.65), and VAS leg reduction of 5.77 (SD 0.66), respectively. These ODI reductions are the equivalent of 3 times the MCID for endoscopy.<sup>176</sup> The VAS leg reduction was 2 times as high as the reported MCID,<sup>176</sup> and the VAS back reduction was on the order of the reported MCID.<sup>83,177</sup> The mean percent change of ODI, VAS back, and VAS leg at minimum 2-year

follow-up or longer after the endoscopic decompression was 77.94% (SD 10.28%), 67.14% (SD 13.26%), and 79.71% (SD 9.14%), respectively.

## DISCUSSION

The authors of this meta-analysis took a broad approach to extract ES data from original studies on the various types of minimally invasive spinal stenosis surgeries to afford the reader the ability to understand their clinical benefit concerning indication for



**Figure 2.** Meta-analysis regression plot of effect size (ES) vs standard error stratified for the type of decompression surgery using random effects model showed substantial overlap in the plotted relationship between these procedures and, hence, clinical benefit with all lumbar decompression methods some of which were with fusion including endoscopy with statistical significance in spite of the underlying risk of moderate publication bias: endoscopic-assisted minimally invasive surgery fusion - 3 studies, ES = 0.94, endoscopy - 84 studies, ES = 0.9, open laminectomy - 6 studies, ES = 0.89, and tubular microdiscectomy - 21 studies, ES = 0.89, P = 0.022.

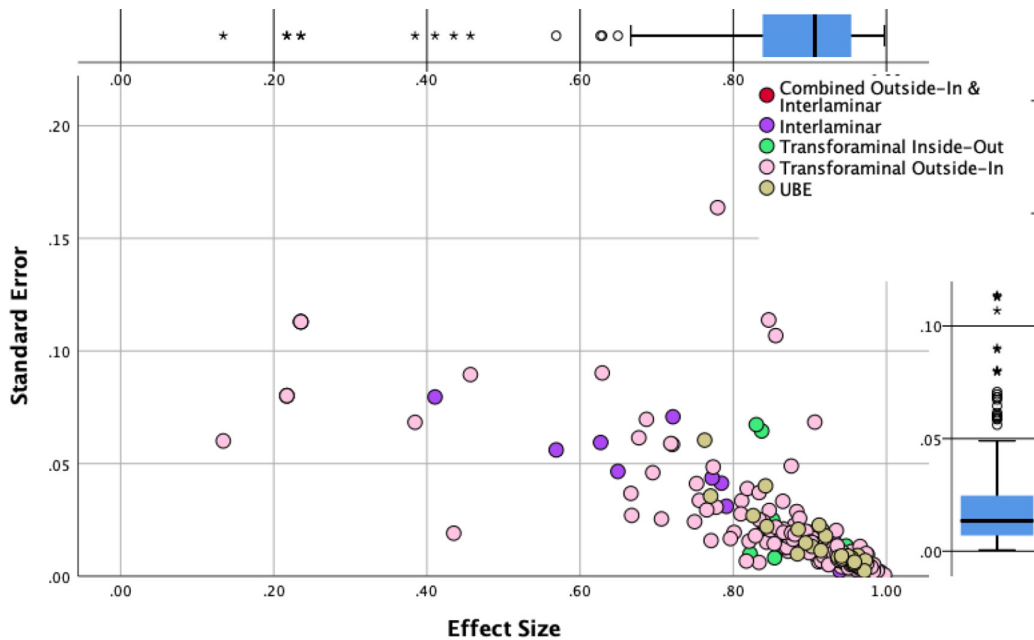
**Table 7.** Analysis of effect size, heterogeneity, and ANOVA testing of difference by type of endoscopy.

Type of Endoscopy		Number of Studies Included in This Analysis	Effect Size	Lower Limit	Upper Limit	Higgins $I^2$ Statistic of Heterogeneity	Variance	Standard Error	Number of Patients
Oswestry Disability Index	Combined outside-in and Interlaminar	1	0.9805	0.9749	0.9848	0.0000	0.0000	0.0025	124
	Interlaminar approach	20	0.9567	0.9403	0.9732	0.0000	0.0001	0.0084	2940
	Biportal UBE endoscopy	9	0.9299	0.8954	0.9645	0.0000	0.0003	0.0176	960
	Transforaminal outside-in	51	0.9044	0.8803	0.9285	0.0000	0.0002	0.0123	8198
	Transforaminal inside-out	5	0.8967	0.8468	0.9467	0.0000	0.0007	0.0255	962
ANOVA $Q$ test random effects with separate estimates of $T^2$						Sig < 0.0001	Total patient samples		13,184
VAS back	Biportal UBE endoscopy	4	0.8943	0.8470	0.9416	0.0000	0.0006	0.0241	336
	Interlaminar approach	10	0.8336	0.7687	0.8984	0.0000	0.0011	0.0331	794
	Transforaminal outside-in	22	0.7775	0.6964	0.8586	0.0000	0.0017	0.0414	3990
	Transforaminal inside-out	1	0.8300	0.6435	0.9235	3.9883	0.0045	0.0673	14
	ANOVA $Q$ test random effects with separate estimates of $T^2$						Sig = 0.093	Total patient samples	
VAS leg	Combined outside-in and interlaminar	1	0.9660	0.9562	0.9736	0.0000	0.0000	0.0044	124
	Interlaminar approach	20	0.9331	0.9106	0.9556	0.0000	0.0001	0.0115	2914
	Biportal UBE endoscopy	10	0.9271	0.9008	0.9534	0.0000	0.0002	0.0134	1002
	Transforaminal outside-in	48	0.9112	0.8880	0.9345	0.0000	0.0001	0.0119	7954
	Transforaminal inside-out	6	0.8912	0.8544	0.9281	0.0000	0.0004	0.0188	1111
ANOVA $Q$ test random effects with separate estimates of $T^2$						Sig < 0.00001	Total patient samples		13,105

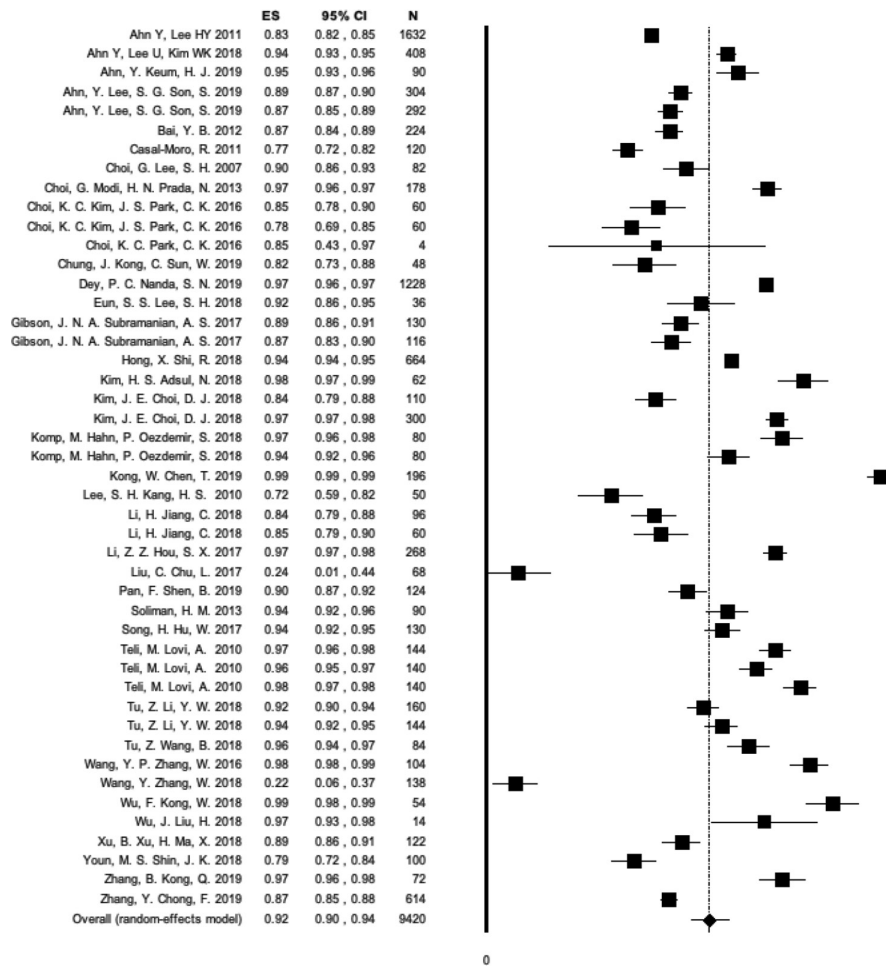
Abbreviations: ANOVA, analysis of variance; Sig, significance level of 95% CI; UBE, uniportal biportal endoscopy; VAS, visual analog scale.

surgery and burden to the patient in an across-the-board normalized comparison. Highlighting differences in outcomes between endoscopic and other forms of minimally invasive (MISST) and traditional open spinal surgery techniques by reporting the ES has several advantages to reporting statistical significance in group comparison tests. The ES calculation emphasizes the size of the difference between the various treatment groups rather than confounding it with sample size.<sup>178</sup>

Although the ES determination is straightforward—for example, it can be calculated by subtracting the means of the control group from the means of the experimental group and divide it by the SD—ES is rarely used in the discussion of clinical outcomes between various treatments.<sup>179</sup> However, it can be highly useful as a measure of overlap between the various lumbar stenosis surgeries. It is a form of data interpretation the authors employed in this study to illustrate the clinical benefit



**Figure 3.** Meta-analysis area plot of effect size (ES) vs standard error using random effects model showed substantial overlap in the plotted relationship between these 2 variables and, hence, clinical benefit with all endoscopic lumbar decompression methods in spite of the underlying risk of moderate publication bias: transforaminal outside-in with combined interlaminar approach - 1 study, ES = 0.97, uniportal biportal endoscopy (UBE) - 6 studies, ES = 0.92, interlaminar approach - 23 studies, ES = 0.93, transforaminal inside-out approach - 2 studies, ES = 0.89, and transforaminal outside-in approach - 54 studies, ES = 0.89, with statistically significant ES differences between these procedures ( $P < 0.001$ ).



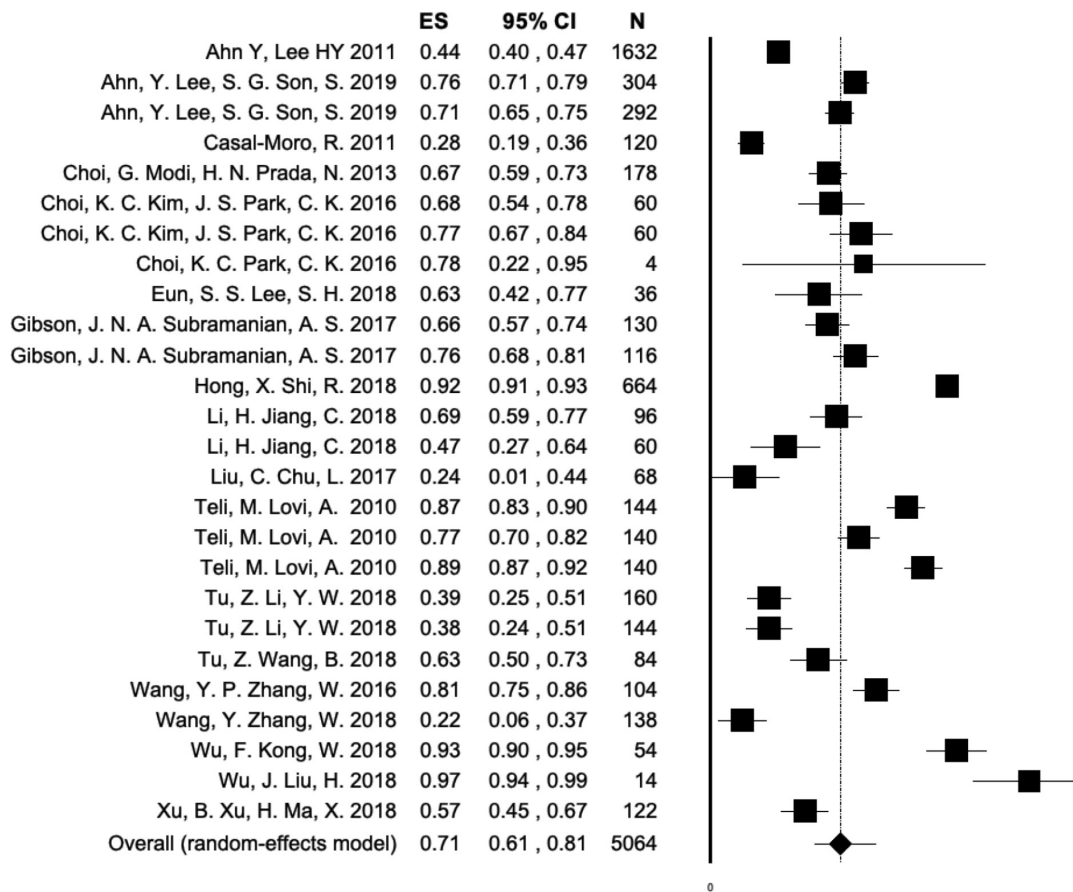
**Figure 4.** Forest plot of effect sizes (ESs), 95% CI, and the number of patients enrolled in each individual endoscopic spinal surgery study (N) calculated for the 46 study groups which reported Oswestry Disability Index with a minimum of 2 y or longer follow-up listed in alphabetical order according to the first author's name. The number of individual study patients is represented by the size of the symbol. The overall ES was 0.92 with a lower 95% CI limit of 0.9, and an upper limit of 0.94 calculated from the total of 9420 patient samples enrolled in these studies.

of the various open, minimally invasive, and endoscopic lumbar spinal stenosis surgeries to patients and all other stakeholders involved in the delivery of modern spine care.

We chose the meta-analysis approach to calculating the ESs since it overcomes the common problem of not knowing the SD in the population from which the different treatment groups came from by estimating it through pooling data from the treatment groups of various studies. The authors also expected, based on their collective clinical experience, substantial overlap in terms of clinical benefit of the different endoscopic surgeries. Ultimately, this overlap of clinical benefit was confirmed by the area plots of ES vs SE (Figures 2 and 3). The ES determination was employed by the authors to handle this well-known clinical situation best since this overlap could be conceptualized as the probability analysis by the surgeon to accurately choose the most effective of the various lumbar stenosis

surgeries for each patient regardless of whether endoscopic, MISST, or traditional open surgery based on the type of painful pathoanatomy, the clinical context of the patient's relevant symptoms at the time when the spine care is delivered, and the surgeon's bias toward a preferred technique based on his or her training, experience, and skill level.<sup>180</sup> The impact of skill level was most likely apparent with the transforaminal outside-in technique where the widest spread of ES vs SE was seen (Figure 3). In other words, when attempting to compare clinical outcomes with the various endoscopic and other MISST techniques one is entering a gray zone where many confounding factors impacting clinical outcomes may play out but where identifying the best performing treatment for a certain clinical indication may still be possible at a high probability in spite of substantial overlap in clinical outcomes. While it is obvious that the reported ESs ranging from 0.71 to 0.97 derived from preoperative and postoperative disability



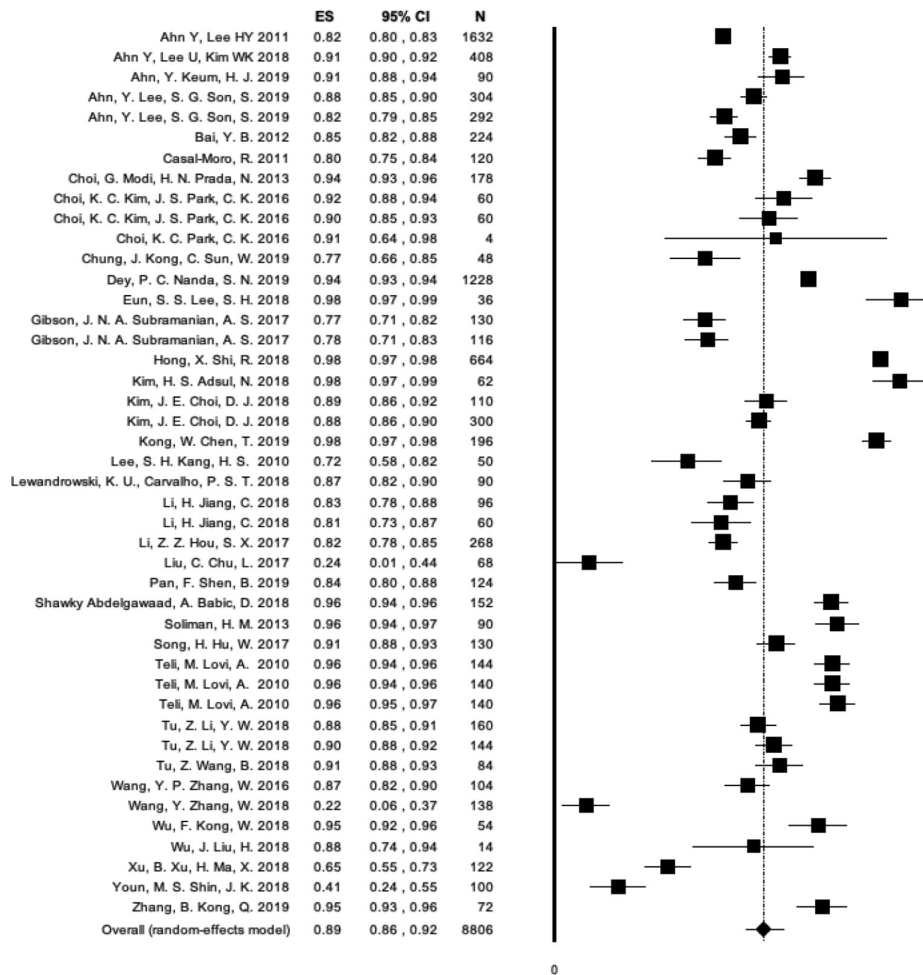


**Figure 5.** Forest plot of effect sizes (ESs), 95% CI, and the number of patients enrolled in each individual endoscopic spinal surgery study (*N*) calculated for the 26 study groups which reported visual analog scale back with a minimum of 2 y or longer follow-up listed in alphabetical order according to the first author's name. The number of individual study patients is represented by the size of the symbol. The overall ES was 0.71 with a lower 95% CI limit of 0.61, and an upper limit of 0.81 calculated from the total of 4926 patient samples enrolled in these studies.

data (ODI, VAS back, and VAS leg) extrapolated by the authors from a total of 89 studies were large,<sup>181</sup> which represented multiple of the reported MCID,<sup>83,177</sup> and without dispute justify the use of the endoscopic and other forms of MISST to treat symptoms related to herniated disc and spinal stenosis in the lateral recess and the foramen, a familiar data set of ESs with these procedures—to the authors' best knowledge—has not been published. Filling this knowledge gap with the many types of endoscopic spinal surgeries, as exemplified by the long list of acronyms noted in the introduction, was the primary motivation of this team of authors to employ this broad rather than a narrow focus meta-analysis approach.

Employing the inclusion and exclusion criteria stated in the method section, the authors' meta-analysis was based on studies, most of which were published within the last 3 years, but rarely older than 10 years, thus, likely representing the recent technology advancements facilitating the outcomes of increasing ES—without statistical significance—reported herein. As a result, ESs

were calculated based on extracted ODI, VAS back, and VAS leg data extrapolated from a vast number of 23,290 patient samples pooled from 89 studies (Tables 1 and 2). Explicitly, our meta-analysis confirmed that the majority of patients treated with endoscopic and other forms of MISST lumbar stenosis decompressions were between the ages of 30 and 70 years without ES being impacted by that at a statistically significant level by age. Neither did the study design translate into any statistically significant impact on ES (Table 3). In other words, patients' outcomes are more likely to be impacted by addressing the relevant painful clinical pathology adequately rather than by the way they are studied. Typically, longer follow-up is valued as a prerequisite of meaningful outcome study. However, as illustrated by our meta-analysis, ESs were the largest when extrapolated for VAS back and VAS leg up until a 2-year follow-up in most studies at a statistically significant level (Table 5). Longer follow-up to as much as 6 years and longer did not necessarily translate into larger ESs ( $P = 0.091$ ); in other words, the natural progression of the disease process may play out with diminishing ESs



**Figure 6.** Forest plot of effect sizes (ESs), 95% CI, and the number of patients enrolled in each individual endoscopic spinal surgery study (*N*) calculated for the 44 study groups which reported visual analog scale leg with a minimum of 2 y or longer follow-up listed in alphabetical order according to the first author's name. The number of individual study patients is represented by the size of the symbol. The overall ES was 0.89 with a lower 95% CI limit of 0.86, and an upper limit of 0.92 calculated from the total of 8806 patients enrolled in these studies.

over time, and perhaps Kaplan Meier durability analyses are more suitable to determine the long-term effects of the contemporary lumbar stenosis surgeries by way of a utilization analysis of additional treatments if any at what point after that.<sup>182</sup> Patients with incomplete pain relief and ongoing disability continue to utilize medical services. In the opinion of public health policymakers, the absence of any additional utilization following the lumbar stenosis index surgery is the ultimate proof of superiority by making good on the promise of better value spine care purchasing for the increasing number of aging patients who need it.

When breaking down the ES by a surgical indication as to the modifier, a mixed picture emerged. The ODI ES spinal stenosis-related neurogenic claudication was higher than VAS back and VAS leg at a statistically significant level (Table 4), emphasizing the more functional context of his 10-item outcome tool. The statistical overlap between the VAS leg ESs for the 3 clinical indications

studied—stenosis claudication, HNP radiculopathy, and discogenic pain were quite large, suggesting that endoscopic spinal surgery is effective in relieving sciatica-type leg and back pain due to either 1 of these 3 conditions. Using the type of MISST and endoscopic surgery as modifiers was possible, because some of the studies included in this meta-analysis had treatment arms comparing these techniques. There was significant overlap between ESs observed with open laminectomy or tubular retractor microsurgical dissection with similar VAS back, and VAS leg ES data to endoscopy, there were statistically significant differences ( $P = 0.049$ ) when employing the ODI as an outcome tool with ESs for endoscopy being higher (0.92) than for microsurgical dissection (0.89; Table 6). The open laminectomy (ES = 0.93) and endoscopically assisted interbody spinal fusion followed by percutaneous posterior supplemental pedicle screw fixation (ES = 0.95) had a higher overall ODI ES numbers presumably because of a more comprehensive decompression and perhaps

elimination of instability (Table 6). The largest ODI (8198 patients), VAS back (3990 patients), and VAS leg (7954 patients) data set were observed with the transforaminal outside-in approach (Table 7). The highest ODI and VAS leg ESs were found with statistical significance with the interlaminar approach, which was the second most commonly performed endoscopic approach, followed by the UBE uniportal biportal technique ( $P < 0.0001$ ). Besides the endoscopic lumbar fusion studies included in this meta-analysis, 2 additional noteworthy uniportal endoscopic fusion articles in patients with low-grade scoliosis,<sup>183</sup> and patients with symptomatic foraminal stenosis secondary to severe collapsed disc space<sup>184</sup> were published within the last year after the cut-off date of this meta-analysis. Based on VAS and ODI outcome reporting, these pivotal studies would not have met the inclusion criteria of our meta-analysis, even if they were published before 31 December 2019, since ES could either not be calculated, or allocated.

As discussed at the outset of this article, the authors were not interested in pushing one endoscopic approach or MISST over another. We were only interested in reporting a familiar set of ODI, VAS back, and VAS leg ESs in the form of reference tables (Table 3 through 7) to aid in the ongoing discussion on how to most effectively transition modern spine care to more reliable and less costly procedures by replacing some of the traditional open with endoscopic and other types of MISST spinal surgery in routine practice. The authors expected the publication bias found in our meta-analysis as one of the main limitations. Seventy-two of the 89 studies included in this meta-analysis were retrospective studies. Twelve studies were prospective, and another 5 studies were randomized prospective clinical trials both of which had multiple treatment arms. Twenty-four of the 36 studies included in the meta-analysis with longer than 2-year follow-up were retrospective. They were estimated to have a high ROB supported by the asymmetric funnel plot, and the spread of ES data in the individual ODI, VAS back, and VAS leg forest plots (Figures 4–6) suggesting that the authors' meta-analysis was at an overall moderate ROB. To diminish the effect of publication bias the authors employed random ES models for the calculations. While there may be many additional unknown limitations to this type of meta-analysis because of variation in patient's expectations, surgeons' skill level, or the organizational process and procedural aspects of the surgery either carried out in an outpatient ambulatory surgery center or in a hospital setting, and many other factors that may be responsible for the heterogeneity observed in some of the subgroups as evidenced by some of the outliers, the difference found in the ODI, VAS back, and VAS leg ESs is reflective of real-life clinical scenarios

where spine care is delivered under a great variety of patient- and system-related circumstances. The surgeon skill factor is likely the most relevant confounder in this whole analysis and may be responsible for the wide overlap in successful clinical outcomes regardless of the type of surgery employed. However, statistically significant differences do exist between the type of endoscopic and other types of MISST surgery and should be further investigated to better define and validate preoperative predictors of favorable clinical outcomes with their use. At this juncture, though, the authors accomplished their task of reporting a familiar ODI, VAS back, and VAS leg ES data set (Tables 3–7) for common minimally invasive and endoscopic spinal surgeries, and how they compare to traditional open spinal surgery in the treatment of symptoms related to herniated disc, foraminal, and lateral recess stenosis.

## CONCLUSIONS

Despite these limitations, and considering that the authors did not attempt a formal comparison to other MISSTs or traditional open surgical decompression, one argument is to be made from the authors' meta-analysis: the 3 types of ES data sets with the various endoscopic spinal surgeries are on par with those observed with open laminectomy, microsurgical dissection, and those seen with MISST fusion surgeries which often come with a higher perioperative burden to the patient and are more costly due to the use of implants, higher complication and reoperation rates and unplanned aftercare, longer postoperative recovery and return to work. The surgeon skill level is the most significant confounding factor. The ongoing debate on the merits of endoscopic spine surgery will likely continue. With this meta-analysis, the authors provided the statistical numbers required to have this debate in an objective manner where one wonders about the continued need for aggressive open surgeries for the indications investigated herein if the reported differences in ES numbers for clinical improvements are marginal.

## REFERENCES

1. Kim HS, Adsul N, Kapoor A, et al. A mobile outside-in technique of transforaminal lumbar endoscopy for lumbar disc herniations. *J Vis Exp*. 2018;(138). doi:10.3791/57999
2. Wang X, Zhou S, Bian Z, et al. Unilateral percutaneous endoscopic debridement and drainage for lumbar infectious spondylitis. *J Orthop Surg Res*. 2018;13(1):306. doi:10.1186/s13018-018-1009-5
3. Wu F, Kong W, Liao W, et al. Percutaneous total endoscopic resection of partial articular processes for treatment of lateral crypt stenosis and lumbar spinal stenosis: technical report

- and efficacy analysis. *Biomed Res Int.* 2018;2018:9130182. doi:10.1155/2018/9130182
4. Liu W, Li Q, Li Z, Chen L, Tian D, Jing J, et al. Clinical efficacy of percutaneous transforaminal endoscopic discectomy in treating adolescent lumbar disc herniation. *Medicine (Baltimore).* 2019;98(9):e14682. doi:10.1097/MD.00000000000014682
  5. Hu A, Gu X, Guan X, Fan G, He S, et al. Epidural versus intravenous steroids application following percutaneous endoscopic lumbar discectomy. *Medicine (Baltimore).* 2018;97(18):e0654. doi:10.1097/MD.00000000000010654
  6. Yadav RI, Long L, Yanming C. Comparison of the effectiveness and outcome of microendoscopic and open discectomy in patients suffering from lumbar disc herniation. *Medicine (Baltimore).* 2019;98(50):e16627. doi:10.1097/MD.00000000000016627
  7. Hua W, Zhang Y, Wu X, et al. Outcomes of discectomy by using full-endoscopic visualization technique via the interlaminar and transforaminal approaches in the treatment of L5-S1 disc herniation: an observational study. *Medicine (Baltimore).* 2018;97(48):e13456. doi:10.1097/MD.00000000000013456
  8. Li X-C, Zhong C-F, Deng G-B, Liang R-W, Huang C-M, et al. Full-endoscopic procedures versus traditional discectomy surgery for discectomy: a systematic review and meta-analysis of current global clinical trials. *Pain Physician.* 2016;19(3):103–118. doi:10.36076/ppj/2019.19.103
  9. Shi C, Kong W, Liao W, et al. The early clinical outcomes of a percutaneous full-endoscopic interlaminar approach via a surrounding nerve root discectomy operative route for the treatment of ventral-type lumbar disc herniation. *Biomed Res Int.* 2018;2018:9157089. doi:10.1155/2018/9157089
  10. Zhang W Met al. Transforaminal endoscopic discectomy for treatment of central disc herniation: surgical techniques and clinical outcome. *Pain Phys.* 2018;1(21;1):E113–E123. doi:10.36076/ppj.2018.2.E113
  11. Xu B, Xu H, Destandau J, et al. Anatomic investigation of lumbar transforaminal fenestration approach and its clinical application in far lateral disc herniation. *Medicine (Baltimore).* 2017;96(29):e7542. doi:10.1097/MD.00000000000007542
  12. Liu T, Zhou Y, Wang J, et al. Clinical efficacy of three different minimally invasive procedures for far lateral lumbar disc herniation. *Chin Med J (Engl).* 2012;125(6):1082–1088.
  13. Hua W, Tu J, Li S, et al. Full-endoscopic discectomy via the interlaminar approach for disc herniation at L4-L5 and L5-S1: an observational study. *Medicine (Baltimore).* 2018;97(17):e0585. doi:10.1097/MD.00000000000010585
  14. Yang J-S, Chu L, Chen C-M, et al. Foraminoplasty at the tip or base of the superior articular process for lateral recess stenosis in percutaneous endoscopic lumbar discectomy: a multicenter, retrospective, controlled study with 2-year follow-up. *Biomed Res Int.* 2018;2018:1–9. doi:10.1155/2018/7692794
  15. Qu Y, Cheng M, Dong R, Kang M, Zhou H, Zhao J, et al. K-rod dynamic internal fixation versus microendoscopic discectomy for the treatment of single-segment lumbar disc herniation. *J Orthop Surg (Hong Kong).* 2017;25(3):2309499017742740. doi:10.1177/2309499017742740
  16. Yu ZR, Li CD, Zhu SN, Sun HL, Zhao Y, Qi LT, et al. Efficacy of transforaminal endoscopic nerve root decompression in the treatment of degenerative lumbar spinal stenosis. *Beijing Da Xue Xue Bao Yi Xue Ban.* 2017;49(2):252–255.
  17. Zhang Y, Chong F, Feng C, Wang Y, Zhou Y, Huang B, et al. Comparison of endoscope-assisted and microscope-assisted tubular surgery for lumbar laminectomies and discectomies: minimum 2-year follow-up results. *Biomed Res Int.* 2019;2019:5321580. doi:10.1155/2019/5321580
  18. Wang H, Zhou Y, Li C, Liu J, Xiang L, et al. Risk factors for failure of single-level percutaneous endoscopic lumbar discectomy. *J Neurosurg Spine.* 2015;23(3):320–325. doi:10.3171/2014.10.SPINE1442
  19. Ao S, Wu J, Tang Y, et al. Percutaneous endoscopic lumbar discectomy assisted by o-arm-based navigation improves the learning curve. *Biomed Res Int.* 2019;2019:6509409. doi:10.1155/2019/6509409
  20. Tao XZ, Jing L, Li JH. Therapeutic effect of transforaminal endoscopic spine system in the treatment of prolapse of lumbar intervertebral disc. *Eur Rev Med Pharmacol Sci.* 2018;22(1 Suppl):103–110. doi:10.26355/eurrev\_201807\_15371
  21. Liu C, Chu L, Yong H-C, Chen L, Deng Z-L, et al. Percutaneous endoscopic lumbar discectomy for highly migrated lumbar disc herniation. *Pain Physician.* 2017;20(1):E75–E84. doi:10.36076/ppj.2017.1.E75
  22. Zhang B, Liu S, Liu J, et al. Transforaminal endoscopic discectomy versus conventional microdiscectomy for lumbar disc herniation: a systematic review and meta-analysis. *J Orthop Surg Res.* 2018;13(1):169. doi:10.1186/s13018-018-0868-0
  23. Wang S-J, Chen B-H, Wang P, Liu C-S, Yu J-M, Ma X-X, et al. The effect of percutaneous endoscopic lumbar discectomy under different anesthesia on pain and immunity of patients with prolapse of lumbar intervertebral disc. *Eur Rev Med Pharmacol Sci.* 2017;21(12):2793–2799.
  24. Dabo X, Ziqiang C, Yinchuan Z, et al. The clinical results of percutaneous endoscopic interlaminar discectomy (PEID) in the treatment of calcified lumbar disc herniation: a case-control study. *Pain Physician.* 2016;19(2):69–76. doi:10.36076/ppj/2016.19.69
  25. Tang S, Jin S, Liao X, Huang K, Luo J, Zhu T, et al. Transforaminal percutaneous endoscopic lumbar decompression by using rigid bendable burr for lumbar lateral recess stenosis: technique and clinical outcome. *Biomed Res Int.* 2018;2018:2601232. doi:10.1155/2018/2601232
  26. He S, Sun Z, Wang Y, Ma D, Tan W, Lai J, et al. Combining YESS and TESSYS techniques during percutaneous transforaminal endoscopic discectomy for multilevel lumbar disc herniation. *Medicine (Baltimore).* 2018;97(28):e11240. doi:10.1097/MD.00000000000011240
  27. Li M, Yang H, Yang Q. Full-endoscopic technique discectomy versus microendoscopic discectomy for the surgical treatment of lumbar disc herniation. *Pain Physician.* 2015;18(4):359–363. doi:10.36076/ppj.2015/18/359
  28. Xu Z, Liu Y, Chen J. Percutaneous endoscopic interlaminar discectomy for L5-S1 adolescent lumbar disc herniation. *Turk Neurosurg.* 2018;28(6):923–928. doi:10.5137/1019-5149.JTN.21579-17.3
  29. Wang B MD Pet al. Clinical outcome of full-endoscopic interlaminar discectomy for single-level lumbar disc herniation: a minimum of 5-year follow-up. *Pain Phys.* 2017;3(20;3):E425–E430. doi:10.36076/ppj.2017.E430
  30. Li Z-Z, Hou S-X, Shang W-L, Song K-R, Zhao H-L, et al. Modified percutaneous lumbar foraminoplasty and percutaneous endoscopic lumbar discectomy: instrument design, technique notes, and 5 years follow-up. *Pain Physician.* 2017;20(1):E85–E98. doi:10.36076/ppj.2017.1.E85
  31. Wu J, Liu H, Ao S, et al. percutaneous endoscopic lumbar interbody fusion: technical note and

- preliminary clinical experience with 2-year follow-up. *Biomed Res Int.* 2018;2018:5806037. doi:10.1155/2018/5806037
32. He E-X, Guo J, Ling Q-J, Yin Z-X, Wang Y, Li M, et al. Application of a narrow-surface cage in full endoscopic minimally invasive transforaminal lumbar interbody fusion. *Int J Surg.* 2017;42:83–89. doi:10.1016/j.ijss.2017.04.053
33. Wang Y-P, Zhang W, Li B-L, Sun Y-P, Ding W-Y, Shen Y, et al. Suprapedicular foraminal endoscopic approach to lumbar lateral recess decompression surgery to treat degenerative lumbar spinal stenosis. *Med Sci Monit.* 2016;22:4604–4611. doi:10.12659/msm.901686
34. Ruan W, Feng F, Liu Z, Xie J, Cai L, Ping A, et al. Comparison of percutaneous endoscopic lumbar discectomy versus open lumbar microdiscectomy for lumbar disc herniation: a meta-analysis. *Int J Surg.* 2016;31:86–92. doi:10.1016/j.ijss.2016.05.061
35. Gu Get al. Comparison of 3 anesthetic methods for percutaneous transforaminal endoscopic discectomy: a prospective study. *Pain Phys.* 2018;1(21;1):E347–E353. doi:10.36076/ppj.2018.4.E347
36. Abudurexiti T, Qi L, Muheremu A, Amudong A, et al. Microendoscopic discectomy versus percutaneous endoscopic surgery for lumbar disc herniation. *J Int Med Res.* 2018;46(9):3910–3917. doi:10.1177/0300060518781694
37. Kong W, Liao W, Ao J, Cao G, Qin J, Cai Y, et al. The strategy and early clinical outcome of percutaneous full-endoscopic interlaminar or extraforaminal approach for treatment of lumbar disc herniation. *Biomed Res Int.* 2016;2016:4702946. doi:10.1155/2016/4702946
38. Sun Y, Zhang W, Qie S, Zhang N, Ding W, Shen Y, et al. Comprehensive comparing percutaneous endoscopic lumbar discectomy with posterior lumbar internal fixation for treatment of adjacent segment lumbar disc prolapse with stable retrolisthesis: a retrospective case-control study. *Medicine (Baltimore).* 2017;96(29):e7471. doi:10.1097/MD.00000000000007471
39. Yang Y, Liu B, Rong L-M, et al. Microendoscopy-assisted minimally invasive transforaminal lumbar interbody fusion for lumbar degenerative disease: short-term and medium-term outcomes. *Int J Clin Exp Med.* 2015;8(11):21319–21326.
40. Ying J, Huang K, Zhu M, et al. The effect and feasibility study of transforaminal percutaneous endoscopic lumbar discectomy via superior border of inferior pedicle approach for down-migrated intracanal disc herniations. *Medicine (Baltimore).* 2016;95(8):e2899. doi:10.1097/MD.0000000000002899
41. Kong W, Chen T, Ye S, Wu F, Song Y, et al. Treatment of L5 - S1 intervertebral disc herniation with posterior percutaneous full-endoscopic discectomy by grafting tubes at various positions via an interlaminar approach. *BMC Surg.* 2019;19(1):124. doi:10.1186/s12893-019-0589-2
42. Pan Z, Ha Y, Yi S, Cao K, et al. Efficacy of transforaminal endoscopic spine system (TESSYS) technique in treating lumbar disc herniation. *Med Sci Monit.* 2016;22:530–539. doi:10.12659/msm.894870
43. Wen B, Zhang X, Zhang L, Huang P, Zheng G, et al. Percutaneous endoscopic transforaminal lumbar spinal canal decompression for lumbar spinal stenosis. *Medicine (Baltimore).* 2016;95(50):e5186. doi:10.1097/MD.0000000000005186
44. Zhang Y, Yang X-J, Zeng T-H, Qiu Y-Y, Wang Y-T, Liang F-G, et al. A retrospective study of epidural and intravenous steroids after percutaneous endoscopic lumbar discectomy for large lumbar disc herniation. *Chin J Traumatol.* 2017;20(1):34–38. doi:10.1016/j.cjtee.2016.10.003
45. Hu Z, Li X, Cui J, et al. Significance of preoperative planning software for puncture and channel establishment in percutaneous endoscopic lumbar discectomy: a study of 40 cases. *Int J Surg.* 2017;41:97–103. doi:10.1016/j.ijss.2017.03.059
46. Song H, Hu W, Liu Z, Hao Y, Zhang X, et al. Percutaneous endoscopic interlaminar discectomy of L5-S1 disc herniation: a comparison between intermittent endoscopy technique and full endoscopy technique. *J Orthop Surg Res.* 2017;12(1):162. doi:10.1186/s13018-017-0662-4
47. Kim CW, Doerr TM, Luna IY, et al. Minimally invasive transforaminal lumbar interbody fusion using expandable technology: a clinical and radiographic analysis of 50 patients. *World Neurosurg.* 2016;90:228–235. doi:10.1016/j.wneu.2016.02.075
48. Zhu Y, Zhao Y, Fan G, et al. Comparison of the effects of local anesthesia and epidural anesthesia for percutaneous transforaminal endoscopic discectomy in elderly patients over 65 years old. *Int J Surg.* 2017;48:260–263. doi:10.1016/j.ijss.2017.11.029
49. Pan F, Shen B, Chy SK, et al. Transforaminal endoscopic system technique for discogenic low back pain: a prospective cohort study. *Int J Surg.* 2016;35:134–138. doi:10.1016/j.ijss.2016.09.091
50. Liu J, Zhang H, Zhang X, He T, Zhao X, Wang Z, et al. Percutaneous endoscopic decompression for lumbar spinal stenosis: protocol for a systematic review and network meta-analysis. *Medicine (Baltimore).* 2019;98(20):e15635. doi:10.1097/MD.00000000000015635
51. Xin Z, Huang P, Zheng G, Liao W, Zhang X, Wang Y, et al. Using a percutaneous spinal endoscopy unilateral posterior interlaminar approach to perform bilateral decompression for patients with lumbar lateral recess stenosis. *Asian J Surg.* 2020;43(5):593–602. doi:10.1016/j.asjsur.2019.08.010
52. Li H, Jiang C, Mu X, Lan W, Zhou Y, Li C, et al. Comparison of MED and PELD in the treatment of adolescent lumbar disc herniation: a 5-year retrospective follow-up. *World Neurosurg.* 2018;112:e255–e260. doi:10.1016/j.wneu.2018.01.030
53. Tu Z, Wang B, Li L, et al. Early experience of full-endoscopic interlaminar discectomy for adolescent lumbar disc herniation with sciatic scoliosis. *Pain Physician.* 2018;21(1):E63–E70. doi:10.36076/ppj.2018.1.E63
54. Xuexiao M Met al. Unique complications of percutaneous endoscopic lumbar discectomy and percutaneous endoscopic interlaminar discectomy. *Pain Phys.* 2018;1(21;1):E105–E112. doi:10.36076/ppj.2018.2.E105
55. Kim JE, Choi DJ. Clinical and radiological outcomes of unilateral biportal endoscopic decompression by 30° arthroscopy in lumbar spinal stenosis: minimum 2-year follow-up. *Clin Orthop Surg.* 2018;10(3):328–336. doi:10.4055/cios.2018.10.3.328
56. Paudel B Met al. Percutaneous endoscopic lumbar discectomy for all types of lumbar disc herniations (LDH) including severely difficult and extremely difficult cases. *Pain Phys.* 2018;1(21;1):E401–E408. doi:10.36076/ppj.2018.4.E401
57. Soo ES, Sourabh C, LS H. Posterolateral endoscopic lumbar decompression rotate-to-retract technique for foraminal disc herniation: a technical report. *Biomed Res Int.* 2019;2019:5758671. doi:10.1155/2019/5758671
58. Choi KC, Kim J-S, Ryu K-S, Kang BU, Ahn Y, Lee S-H, et al. Percutaneous endoscopic lumbar discectomy for L5-S1 disc herniation: transforaminal versus interlaminar approach. *Pain Physician.* 2013;16(6):547–556. doi:10.36076/ppj.2013/16/547
59. Lee C-H, Choi M, Ryu DS, et al. Efficacy and safety of full-endoscopic decompression via interlaminar approach for central or lateral recess spinal stenosis of the lumbar spine: a meta-analysis.

*Spine (Phila Pa 1976)*. 2018;43(24):1756–1764. doi:10.1097/BRS.0000000000002708

60. Dey PC, Nanda SN. Functional outcome after endoscopic lumbar discectomy by standau's technique: a prospective study of 614 patients. *Asian Spine J*. 2019;13(5):786–792. doi:10.31616/asj.2018.0320

61. Kim S-K, Kang S-S, Hong Y-H, Park S-W, Lee S-C, et al. Clinical comparison of unilateral biportal endoscopic technique versus open microdiscectomy for single-level lumbar discectomy: a multicenter, retrospective analysis. *J Orthop Surg Res*. 2018;13(1):22. doi:10.1186/s13018-018-0725-1

62. Park JH, Bae CW, Jeon SR, Rhim SC, Kim CJ, Roh SW. Clinical and radiological outcomes of unilateral facetectomy and interbody fusion using expandable cages for lumbosacral foraminal stenosis. *J Korean Neurosurg Soc*. 2010;48(6):496–500. doi:10.3340/jkns.2010.48.6.496

63. Kapetanakis S, Giannopoulou E, Thomaidis T, Charitoudis G, Pavlidis P, Kazakos K, et al. Transforaminal percutaneous endoscopic discectomy in parkinson disease: preliminary results and short review of the literature. *Korean J Spine*. 2016;13(3):144–150. doi:10.14245/kjs.2016.13.3.144

64. Youn MS, Shin JK, Goh TS, Son SM, Lee JS, et al. Endoscopic posterior decompression under local anesthesia for degenerative lumbar spinal stenosis. *J Neurosurg Spine*. 2018;29(6):661–666. doi:10.3171/2018.5.SPINE171337

65. Lee SH, Erken HY, Bae J. Percutaneous transforaminal endoscopic lumbar interbody fusion: clinical and radiological results of mean 46-month follow-up. *Biomed Res Int*. 2017;2017:3731983. doi:10.1155/2017/3731983

66. Heo DH, Sharma S, Park CK. Endoscopic treatment of extraforaminal entrapment of L5 nerve root (far out syndrome) by unilateral biportal endoscopic approach: technical report and preliminary clinical results. *Neurospine*. 2019;16(1):130–137. doi:10.14245/ns.1938026.013

67. Kim JE, Choi DJ. Unilateral biportal endoscopic decompression by 30° endoscopy in lumbar spinal stenosis: technical note and preliminary report. *J Orthop*. 2018;15(2):366–371. doi:10.1016/j.jor.2018.01.039

68. Kim HS, Yudoyono F, Paudel B, et al. Analysis of clinical results of three different routes of percutaneous endoscopic transforaminal lumbar discectomy for lumbar herniated disk. *World Neurosurg*. 2017;103:442–448. doi:10.1016/j.wneu.2017.04.008

69. Lewandrowski K-U, Ransom NA, Ramírez León JF, Yeung A, et al. The concept for a standalone lordotic endoscopic wedge lumbar interbody fusion: the LEW-LIF. *Neurospine*. 2019;16(1):82–95. doi:10.14245/ns.1938046.023

70. Moon BJ, Yi S, Ha Y, Kim KN, Yoon DH, Shin DA, et al. Clinical efficacy and safety of trans-sacral epiduroscopic laser decompression compared to percutaneous epidural neuroplasty. *Pain Res Manag*. 2019;2019:2893460. doi:10.1155/2019/2893460

71. Ahn Y, Lee U, Kim W-K, Keum HJ, et al. Five-year outcomes and predictive factors of transforaminal full-endoscopic lumbar discectomy. *Medicine (Baltimore)*. 2018;97(48):e13454. doi:10.1097/MD.00000000000013454

72. Lee C-W, Yoon K-J, Ha S-S. Comparative analysis between three different lumbar decompression techniques (microscopic, tubular, and endoscopic) in lumbar canal and lateral recess stenosis: preliminary report. *Biomed Res Int*. 2019;2019:6078469. doi:10.1155/2019/6078469

73. Heo DH, Son SK, Eum JH, Park CK, et al. Fully endoscopic lumbar interbody fusion using a percutaneous unilateral

biportal endoscopic technique: technical note and preliminary clinical results. *Neurosurg Focus*. 2017;43(2):E8. doi:10.3171/2017.5.FOCUS17146

74. Hwa Eum J, Hwa Heo D, Son SK, Park CK, et al. Percutaneous biportal endoscopic decompression for lumbar spinal stenosis: a technical note and preliminary clinical results. *J Neurosurg Spine*. 2016;24(4):602–607. doi:10.3171/2015.7.SPINE15304

75. Ahn Y, Lee SG, Son S, Keum HJ, et al. Transforaminal endoscopic lumbar discectomy versus open lumbar microdiscectomy: a comparative cohort study with a 5-year follow-up. *Pain Physician*. 2019;22(3):295–304.

76. Choi KC, Park CK. Percutaneous endoscopic lumbar discectomy for L5-S1 disc herniation: consideration of the relation between the iliac crest and L5-S1 disc. *Pain Physician*. 2016;19(2):E301-8.

77. Shin DA MD Pet al. Safety and effectiveness of transforaminal epiduroscopic laser ablation in single level disc disease: a case-control study. *Pain Phys*. 2018;1(21;1):E643–E650. doi:10.36076/ppj.2018.6.E643

78. Ahn J-S, Lee H-J, Choi D-J, Lee K-Y, Hwang S-J, et al. Extraforaminal approach of biportal endoscopic spinal surgery: a new endoscopic technique for transforaminal decompression and discectomy. *J Neurosurg Spine*. 2018;28(5):492–498. doi:10.3171/2017.8.SPINE17771

79. Komatsu J, Iwabuchi M, Endo T, et al. Clinical outcomes of lumbar diseases specific test in patients who undergo endoscopy-assisted tubular surgery with lumbar herniated nucleus pulposus: an analysis using the Japanese Orthopaedic Association Back Pain Evaluation Questionnaire (JOABPEQ). *Eur J Orthop Surg Traumatol*. 2020;30(2):207–213. doi:10.1007/s00590-019-02574-5

80. Murata K, Akeda K, Takegami N, Cheng K, Masuda K, Sudo A, et al. Morphology of intervertebral disc ruptures evaluated by vacuum phenomenon using multi-detector computed tomography: association with lumbar disc degeneration and canal stenosis. *BMC Musculoskelet Disord*. 2018;19(1):164. doi:10.1186/s12891-018-2086-7

81. Komatsu J, Muta T, Nagura N, et al. Tubular surgery with the assistance of endoscopic surgery via a paramedian or midline approach for lumbar spinal canal stenosis at the L4/5 level. *J Orthop Surg (Hong Kong)*. 2018;26(2):2309499018782546. doi:10.1177/2309499018782546

82. Ishimoto Y, Yamada H, Curtis E, et al. Spinal endoscopy for delayed-onset lumbar radiculopathy resulting from foraminal stenosis after osteoporotic vertebral fracture: a case report of a new surgical strategy. *Case Rep Orthop*. 2018;2018:1593021. doi:10.1155/2018/1593021

83. Azimi P, Yazdanian T, Benzel EC. Determination of minimally clinically important differences for JOABPEQ measure after discectomy in patients with lumbar disc herniation. *J Spine Surg*. 2018;4(1):102–108. doi:10.21037/jss.2018.03.11

84. Yoshimoto M, Iesato N, Terashima Y, Tanimoto K, Takebayashi T, Yamashita T, et al. Long-term outcome of microendoscopic discectomy for lumbar disk herniation. a clinical study of consecutive 112 cases with more than 5-year follow-up. *J Neurol Surg A Cent Eur Neurosurg*. 2017;78(5):446–452. doi:10.1055/s-0037-1598657

85. Sasaki T, Yoshimura N, Hashizume H, et al. MRI-defined paraspinous muscle morphology in Japanese population: the wakayama spine study. *PLoS One*. 2017;12(11):e0187765. doi:10.1371/journal.pone.0187765

86. Imajo Y, Taguchi T, Neo M, et al. Complications of spinal surgery for elderly patients with lumbar spinal stenosis in a super-aging country: an analysis of 8033 patients. *J Orthop Sci*. 2017;22(1):10–15. doi:10.1016/j.jos.2016.08.014
87. Dohzono S, Toyoda H, Takahashi S, et al. Factors associated with improvement in sagittal spinal alignment after microendoscopic laminotomy in patients with lumbar spinal canal stenosis. *J Neurosurg Spine*. 2016;25(1):39–45. doi:10.3171/2015.12.SPINE15805
88. Yeung AT, Yeung CA. In-vivo endoscopic visualization of patho-anatomy in painful degenerative conditions of the lumbar spine. *Surg Technol Int*. 2006;15:243–256.
89. Tsou PM, Alan Yeung C, Yeung AT. Posterolateral transforaminal selective endoscopic discectomy and thermal annuloplasty for chronic lumbar discogenic pain: a minimal access visualized intradiscal surgical procedure. *Spine J*. 2004;4(5):564–573. doi:10.1016/j.spinee.2004.01.014
90. Yeung AT, Yeung CA. Advances in endoscopic disc and spine surgery: foraminal approach. *Surg Technol Int*. 2003;11:255–263.
91. Yeung AT, Tsou PM. Posterolateral endoscopic excision for lumbar disc herniation: surgical technique, outcome, and complications in 307 consecutive cases. *Spine (Phila Pa 1976)*. 2002;27(7):722–731. doi:10.1097/00007632-200204010-00009
92. Tsou PM, Yeung AT. Transforaminal endoscopic decompression for radiculopathy secondary to intracanal noncontained lumbar disc herniations: outcome and technique. *Spine J*. 2002;2(1):41–48. doi:10.1016/s1529-9430(01)00153-x
93. Bini W, Yeung AT, Calatayud V, Chaaban A, Seferlis T, et al. The role of provocative discography in minimally invasive selective endoscopic discectomy. *Neurocirugia (Astur)*. 2002;13(1):27–31. doi:10.1016/s1130-1473(02)70646-5
94. Yeung AT. The evolution of percutaneous spinal endoscopy and discectomy: state of the art. *Mt Sinai J Med*. 2000;67(4):327–332.
95. Yeung AT. Minimally invasive disc surgery with the yeung endoscopic spine system (YESS). *Surg Technol Int*. 1999;8:267–277.
96. Ruetten S, Hahn P, Oezdemir S, et al. Full-endoscopic uniportal decompression in disc herniations and stenosis of the thoracic spine using the interlaminar, extraforaminal, or transthoracic retropleural approach. *J Neurosurg Spine*. 2018;29(2):157–168. doi:10.3171/2017.12.SPINE171096
97. Komp M, Hahn P, Oezdemir S, et al. Bilateral spinal decompression of lumbar central stenosis with the full-endoscopic interlaminar versus microsurgical laminotomy technique: a prospective, randomized, controlled study. *Pain Physician*. 2015;18(1):61–70.
98. Kim KR, Park JY. The technical feasibility of unilateral biportal endoscopic decompression for the unpredicted complication following minimally invasive transforaminal lumbar interbody fusion: case report. *Neurospine*. 2020;17(Suppl 1):S154–S159. doi:10.14245/ns.2040174.087
99. Lin G-X, Huang P, Kotheeranurak V, et al. A systematic review of unilateral biportal endoscopic spinal surgery: preliminary clinical results and complications. *World Neurosurg*. 2019;125:425–432. doi:10.1016/j.wneu.2019.02.038
100. Yeung A, Kotheeranurak V. Transforaminal endoscopic decompression of the lumbar spine for stable isthmic spondylolisthesis as the least invasive surgical treatment using the YESS surgery technique. *Int J Spine Surg*. 2018;12(3):408–414. doi:10.14444/5048
101. Wu X-D, Chen Y, Yu W-C, et al. Effectiveness of bi-needle technique (hybrid yeung endoscopic spine system/transforaminal endoscopic spine system) for percutaneous endoscopic lumbar discectomy. *World Neurosurg*. 2018;119:e53–e59. doi:10.1016/j.wneu.2018.06.220
102. Gore S, Yeung A. The “inside out” transforaminal technique to treat lumbar spinal pain in an awake and aware patient under local anesthesia: results and a review of the literature. *Int J Spine Surg*. 2014;8. doi:10.14444/1028
103. Zhou Y, Zhang C, Wang J, et al. Minimally invasive strategies and options for far-lateral lumbar disc herniation. *Chin J Traumatol*. 2008;11(5):259–266. doi:10.1016/s1008-1275(08)60053-x
104. Yeung AT. The evolution and advancement of endoscopic foraminal surgery: one surgeon’s experience incorporating adjunctive technologies. *SAS J*. 2007;1(3):108–117. doi:10.1016/SASJ-2006-0014-RR
105. Hoogland T, van den Brekel-Dijkstra K, Schubert M, Miklitz B, et al. Endoscopic transforaminal discectomy for recurrent lumbar disc herniation: a prospective, cohort evaluation of 262 consecutive cases. *Spine (Phila Pa 1976)*. 2008;33(9):973–978. doi:10.1097/BRS.0b013e31816c8ade
106. Hoogland T, Schubert M, Miklitz B, Ramirez A, et al. Transforaminal posterolateral endoscopic discectomy with or without the combination of a low-dose chymopapain: a prospective randomized study in 280 consecutive cases. *Spine (Phila Pa 1976)*. 2006;31(24):E890-7. doi:10.1097/01.brs.0000245955.22358.3a
107. Schubert M, Hoogland T. Endoscopic transforaminal nucleotomy with foraminoplasty for lumbar disk herniation. *Oper Orthop Traumatol*. 2005;17(6):641–661. doi:10.1007/s00064-005-1156-9
108. Hoogland T, Scheckenbach C. Percutaneous lumbar nucleotomy with low-dose chymopapain, an ambulatory procedure. *Z Orthop Ihre Grenzgeb*. 1995;133(2):106–113. doi:10.1055/s-2008-1039420
109. Hoogland T, Scheckenbach C. Low-dose chemonucleolysis combined with percutaneous nucleotomy in herniated cervical disks. *J Spinal Disord*. 1995;8(3):228–232. doi:10.1097/00002517-199506000-00009
110. Hoogland T. Percutaneous endoscopic discectomy. *J Neurosurg*. 1993;79(6):967–968. doi:10.3171/jns.1993.79.2.0309
111. Liu X, Yuan S, Tian Y, et al. Comparison of percutaneous endoscopic transforaminal discectomy, microendoscopic discectomy, and microdiscectomy for symptomatic lumbar disc herniation: minimum 2-year follow-up results. *J Neurosurg Spine*. 2018;28(3):317–325. doi:10.3171/2017.6.SPINE172
112. Eun SS, Eum JH, Lee SH, Sabal LA, et al. Biportal endoscopic lumbar decompression for lumbar disk herniation and spinal canal stenosis: a technical note. *J Neurol Surg A Cent Eur Neurosurg*. 2017;78(4):390–396. doi:10.1055/s-0036-1592157
113. Heo DH, Lee DC, Park CK. Comparative analysis of three types of minimally invasive decompressive surgery for lumbar central stenosis: biportal endoscopy, uniportal endoscopy, and microsurgery. *Neurosurg Focus*. 2019;46(5):2019.2.FOCUS197. doi:10.3171/2019.2.FOCUS197
114. Chen Z, Zhang L, Dong J, et al. Percutaneous transforaminal endoscopic discectomy compared with microendoscopic discectomy for lumbar disc herniation: 1-year results of an ongoing randomized controlled trial. *J Neurosurg Spine*. 2018;28(3):300–310. doi:10.3171/2017.7.SPINE161434
115. Gao K, Yang H, Yang L-Q, Hu M-Q, et al. Application of intervertebral foramen endoscopy BEIS technique in the lumbar spine surgery failure syndrome over 60 years old. *Zhongguo Gu Shang*. 2019;32(7):647–652. doi:10.3969/j.issn.1003-0034.2019.07.012

116. Xiong C, Li T, Kang H, Hu H, Han J, Xu F, et al. Early outcomes of 270-degree spinal canal decompression by using TESSYS-ISEE technique in patients with lumbar spinal stenosis combined with disk herniation. *Eur Spine J.* 2019;28(1):78–86. doi:10.1007/s00586-018-5655-4
117. Lin G-X, Kotheeranurak V, Mahatthanatrakul A, et al. Worldwide research productivity in the field of full-endoscopic spine surgery: a bibliometric study. *Eur Spine J.* 2020;29(1):153–160. doi:10.1007/s00586-019-06171-2
118. Fairbank J. Use of Oswestry disability index (ODI). *Spine.* 1976;20:1535–1537. doi:10.1097/00007632-199507000-00020
119. Fairbank JCT, Pynsent PB. The Oswestry disability index. *Spine (Phila Pa 1976).* 2000;25(22):2940–2952. doi:10.1097/00007632-200011150-00017
120. van Hooff ML, Mannion AF, Staub LP, Ostelo RWJG, Fairbank JCT, et al. Determination of the Oswestry disability index score equivalent to a “satisfactory symptom state” in patients undergoing surgery for degenerative disorders of the lumbar spine—a spine tango registry-based study. *Spine J.* 2016;16(10):1221–1230. doi:10.1016/j.spinee.2016.06.010
121. van Hooff ML, Spruit M, Fairbank JCT, van Limbeek J, Jacobs WCH, et al. The Oswestry disability index (version 2.1a): validation of a Dutch language version. *Spine (Phila Pa 1976).* 2015;40(2):E83–90. doi:10.1097/BRS.0000000000000683
122. Reed CC, Wolf WA, Cotton CC, Dellon ES, et al. A visual analogue scale and a Likert scale are simple and responsive tools for assessing dysphagia in eosinophilic oesophagitis. *Aliment Pharmacol Ther.* 2017;45(11):1443–1448. doi:10.1111/apt.14061
123. Barber SM, Nakhla J, Konakondla S, et al. Outcomes of endoscopic discectomy compared with open microdiscectomy and tubular microdiscectomy for lumbar disc herniations: a meta-analysis. *J Neurosurg Spine.* 2019;31(6):802–815. doi:10.3171/2019.6.SPINE19532
124. He J, Xiao S, Wu Z, Yuan Z, et al. Microendoscopic discectomy versus open discectomy for lumbar disc herniation: a meta-analysis. *Eur Spine J.* 2016;25(5):1373–1381. doi:10.1007/s00586-016-4523-3
125. Phan K, Xu J, Schultz K, et al. Full-endoscopic versus micro-endoscopic and open discectomy: a systematic review and meta-analysis of outcomes and complications. *Clin Neurol Neurosurg.* 2017;154:1–12. doi:10.1016/j.clineuro.2017.01.003
126. Qin R, Liu B, Hao J, et al. Percutaneous endoscopic lumbar discectomy versus posterior open lumbar microdiscectomy for the treatment of symptomatic lumbar disc herniation: a systemic review and meta-analysis. *World Neurosurg.* 2018;120:352–362. doi:10.1016/j.wneu.2018.08.236
127. Shi R, Wang F, Hong X, et al. Comparison of percutaneous endoscopic lumbar discectomy versus microendoscopic discectomy for the treatment of lumbar disc herniation: a meta-analysis. *Int Orthop.* 2019;43(4):923–937. doi:10.1007/s00264-018-4253-8
128. Hutton B, Salanti G, Caldwell DM, et al. The PRISMA extension statement for reporting of systematic reviews incorporating network meta-analyses of health care interventions: checklist and explanations. *Ann Intern Med.* 2015;162(11):777–784. doi:10.7326/M14-2385
129. Liberati A, Altman DG, Tetzlaff J, et al. The PRISMA statement for reporting systematic reviews and meta-analyses of studies that evaluate healthcare interventions: explanation and elaboration. *BMJ.* 2009;339:bmj.b2700. doi:10.1136/bmj.b2700
130. Liu H, Zhou X, Yu G, Sun X, et al. The effects of the PRISMA statement to improve the conduct and reporting of systematic reviews and meta-analyses of nursing interventions for patients with heart failure. *Int J Nurs Pract.* 2019;25(3):e12729. doi:10.1111/ijn.12729
131. Poveda-Montoyo I, Belinchón-Romero I, Romero-Pérez D, Ramos-Rincón JM, et al. Topics and PRISMA checklist compliance for meta-analyses in dermatology: journal case study. *Acta Dermatovenerol Croat.* 2019;27(4):275–277.
132. Kim SY, Lee EJ, Jeon JH, Kim JH, Jung IC, Kim YI, et al. Quality assessment of randomized controlled trials of moxibustion using standards for reporting interventions in clinical trials of moxibustion (STRICTOM) and risk of bias (ROB). *J Acupunct Meridian Stud.* 2017;10(4):261–275. doi:10.1016/j.jams.2017.05.012
133. Lauridsen HH, Hartvigsen J, Manniche C, Korsholm L, Grunnet-Nilsson N, et al. Responsiveness and minimal clinically important difference for pain and disability instruments in low back pain patients. *BMC Musculoskelet Disord.* 2006;7:82. doi:10.1186/1471-2474-7-82
134. Jaeschke R, Singer J, Guyatt GH. Measurement of health status. Ascertaining the minimal clinically important difference. *Control Clin Trials.* 1989;10(4):407–415. doi:10.1016/0197-2456(89)90005-6
135. Held U, Burgstaller JM, Wertli MM, et al. Prognostic function to estimate the probability of meaningful clinical improvement after surgery - results of a prospective multicenter observational cohort study on patients with lumbar spinal stenosis. *PLoS One.* 2018;13(11):e0207126. doi:10.1371/journal.pone.0207126
136. Copay AG, Eyberg B, Chung AS, Zurcher KS, Chutkan N, Spangehl MJ, et al. Minimum clinically important difference: current trends in the orthopaedic literature, part II: lower extremity: a systematic review. *JBJS Rev.* 2018;6(9):e2. doi:10.2106/JBJS.RVW.17.00160
137. Cook CE. Clinimetrics corner: the minimal clinically important change score (MCID): a necessary pretense. *J Man Manip Ther.* 2008;16(4):E82–3. doi:10.1179/jmt.2008.16.4.82E
138. Cao S, Cui H, Lu Z, et al. “Tube in tube” interlaminar endoscopic decompression for the treatment of lumbar spinal stenosis: technique notes and preliminary clinical outcomes of case series. *Medicine (Baltimore).* 2019;98(35):e17021. doi:10.1097/MD.00000000000017021
139. Choi G, Lee S-H, Raiturker PP, Lee S, Chae Y-S, et al. Percutaneous endoscopic interlaminar discectomy for intracanalicular disc herniations at L5-S1 using a rigid working channel endoscope. *Neurosurgery.* 2006;58(1 Suppl):S59–68. doi:10.1227/01.neu.0000192713.95921.4a
140. Eun SS, Chachan S, Lee SH. Interlaminar percutaneous endoscopic lumbar discectomy: rotate and retract technique. *World Neurosurg.* 2018;118:188–192. doi:10.1016/j.wneu.2018.07.083
141. Gadradj PS, van Tulder MW, Dirven CMF, Peul WC, Harhangi BS, et al. Clinical outcomes after percutaneous transforaminal endoscopic discectomy for lumbar disc herniation: a prospective case series. *Neurosurg Focus.* 2016;40(2):E3. doi:10.3171/2015.10.FOCUS15484
142. Hsu H-T, Chang S-J, Yang SS, Chai CL, et al. Learning curve of full-endoscopic lumbar discectomy. *Eur Spine J.* 2013;22(4):727–733. doi:10.1007/s00586-012-2540-4
143. Hubbe U, Franco-Jimenez P, Klingler J-H, Vasilikos I, Scholz C, Kogias E, et al. Minimally invasive tubular microdiscectomy for recurrent lumbar disc herniation. *J Neurosurg Spine.* 2016;24(1):48–53. doi:10.3171/2015.4.SPINE14883
144. Kapetanakis S, Giovannopoulou E, Thomaidis T, Charitoudis G, Pavlidis P, Kazakos K, et al. Transforaminal percutaneous



- endoscopic discectomy in parkinson disease: preliminary results and short review of the literature. *Korean J Spine*. 2016;13(3):144–150. doi:10.14245/kjs.2016.13.3.144
145. Kim HS, Adsul N, Ju YS, et al. Full endoscopic lumbar discectomy using the calcification floating technique for symptomatic partially calcified lumbar herniated nucleus pulposus. *World Neurosurg*. 2018;119:500–505. doi:10.1016/j.wneu.2018.06.133
146. Li L-J, Chang F, Hai Y, et al. Clinical effects of percutaneous endoscopic transforaminal decompression for the treatment of lumbar spinal stenosis. *Zhongguo Gu Shang*. 2018;31(7):617–620. doi:10.3969/j.issn.1003-0034.2018.07.007
147. Li X-F, Jin L-Y, Lv Z-D, et al. Endoscopic ventral decompression for spinal stenosis with degenerative spondylolisthesis by partially removing posterosuperior margin underneath the slipping vertebral body: technical note and outcome evaluation. *World Neurosurg*. 2019;126:e517–e525. doi:10.1016/j.wneu.2019.02.083
148. Liu Y, Cai P, Kong Q, Song Y, et al. Effectiveness of percutaneous endoscopic spine surgery for treatment of lumbar spine disorders with intraspinal ossification. *Zhongguo Xiu Fu Chong Jian Wai Ke Za Zhi*. 2017;31(11):1326–1333. doi:10.7507/1002-1892.201705108
149. Madhavan K, Chieng LO, McGrath L, Hofstetter CP, Wang MY, et al. Early experience with endoscopic foraminotomy in patients with moderate degenerative deformity. *Neurosurg Focus*. 2016;40(2):E6. doi:10.3171/2015.11.FOCUS15511
150. Sang P-M, Zhang M, Chen B-H, Gu S-R, Lu L-J, Li J, et al. Treatment of migrated lumbar disc herniation with percutaneous endoscopic lumbar discectomy and target foraminoplasty. *Zhongguo Gu Shang*. 2018;31(4):302–305. doi:10.3969/j.issn.1003-0034.2018.04.002
151. Shin S-H, Bae J-S, Lee S-H, Keum H-J, Kim H-J, Jang W-S, et al. Transforaminal endoscopic decompression for lumbar spinal stenosis: a novel surgical technique and clinical outcomes. *World Neurosurg*. 2018;114:e873–e882. doi:10.1016/j.wneu.2018.03.107
152. Wang J, Zhou Y, Li C, Zhang Z, Zhang N, et al. Percutaneous endoscopic lumbar discectomy for treatment of chronic discogenic low back pain. *Zhongguo Xiu Fu Chong Jian Wai Ke Za Zhi*. 2009;23(4):400–403.
153. Wang Y, Yan Y, Yang J, et al. Outcomes of percutaneous endoscopic trans-articular discectomy for huge central or paracentral lumbar disc herniation. *Int Orthop*. 2019;43(4):939–945. doi:10.1007/s00264-018-4210-6
154. Wu G-N, Zhang S-M, Jin J, Sun B-Q, et al. Percutaneous endoscopic lumbar discectomy for the treatment of lumbar intervertebral disc protrusion. *Zhongguo Gu Shang*. 2017;30(9):861–865. doi:10.3969/j.issn.1003-0034.2017.09.016
155. Yang D, Wu X, Zheng M, Wang J, et al. A modified percutaneous endoscopic technique to remove extraforaminal disk herniation at the L5-S1 segment. *World Neurosurg*. 2018;119:e671–e678. doi:10.1016/j.wneu.2018.07.240
156. Yang JC, Hai Y, Ding Y, et al. Percutaneous endoscopic transforaminal lumbar interbody fusion for lumbar spinal stenosis. *Zhonghua Yi Xue Za Zhi*. 2018;98(45):3711–3715. doi:10.3760/cma.j.issn.0376-2491.2018.45.016
157. Ahn Y, Keum HJ, Lee S-G, Lee S-W, et al. Transforaminal endoscopic decompression for lumbar lateral recess stenosis: an advanced surgical technique and clinical outcomes. *World Neurosurg*. 2019;125:e916–e924. doi:10.1016/j.wneu.2019.01.209
158. Ahn Y, Lee HY, Lee S-H, Lee JH, et al. Dural tears in percutaneous endoscopic lumbar discectomy. *Eur Spine J*. 2011;20(1):58–64. doi:10.1007/s00586-010-1493-8
159. Bai Y, Xu L, Xi J, Mu X, et al. Diagnosis and treatment of lumbar disc herniation by discography and percutaneous transforaminal endoscopic surgery. *Zhonghua Yi Xue Za Zhi*. 2012;92(47):3350–3353.
160. Casal-Moro R, Castro-Menéndez M, Hernández-Blanco M, Bravo-Ricoy JA, Jorge-Barreiro FJ, et al. Long-term outcome after microendoscopic discectomy for lumbar disk herniation: a prospective clinical study with a 5-year follow-up. *Neurosurgery*. 2011;68(6):1568–1575. doi:10.1227/NEU.0b013e31820cd16a
161. Choi G, Lee S-H, Bhanot A, Raiturker PP, Chae YS, et al. Percutaneous endoscopic discectomy for extraforaminal lumbar disc herniations: extraforaminal targeted fragmentectomy technique using working channel endoscope. *Spine (Phila Pa 1976)*. 2007;32(2):E93–9. doi:10.1097/01.brs.0000252093.31632.54
162. Choi G, Modi HN, Prada N, et al. Clinical results of XMR-assisted percutaneous transforaminal endoscopic lumbar discectomy. *J Orthop Surg Res*. 2013;8:14. doi:10.1186/1749-799X-8-14
163. Choi KC, Kim JS, Park CK. Percutaneous endoscopic lumbar discectomy as an alternative to open lumbar microdiscectomy for large lumbar disc herniation. *Pain Physician*. 2016;19(2):E291–300. doi:10.36076/ppj/2016.19.E291
164. Chung J, Kong C, Sun W, Kim D, Kim H, Jeong H, et al. Percutaneous endoscopic lumbar foraminoplasty for lumbar foraminal stenosis of elderly patients with unilateral radiculopathy: radiographic changes in magnetic resonance images. *J Neurol Surg A Cent Eur Neurosurg*. 2019;80(4):302–311. doi:10.1055/s-0038-1677052
165. Eun SS, Lee SH, Erken HY. Transforaminal percutaneous endoscopic lumbar discectomy for downmigrated disk herniations: lever-up, rotate, and tilt technique. *J Neurol Surg A Cent Eur Neurosurg*. 2018;79(2):163–168. doi:10.1055/s-0037-1608837
166. Gibson JNA, Subramanian AS, Scott CEH. A randomised controlled trial of transforaminal endoscopic discectomy vs microdiscectomy. *Eur Spine J*. 2017;26(3):847–856. doi:10.1007/s00586-016-4885-6
167. Hong X, Shi R, Wang Y-T, Liu L, Bao J-P, Wu X-T, et al. Lumbar disc herniation treated by microendoscopic discectomy: prognostic predictors of long-term postoperative outcome. *Orthopade*. 2018;47(12):993–1002. doi:10.1007/s00132-018-3624-6
168. Lee S-H, Kang HS, Choi G, et al. Foraminoplastic ventral epidural approach for removal of extruded herniated fragment at the L5-S1 level. *Neurol Med Chir (Tokyo)*. 2010;50(12):1074–1078. doi:10.2176/nmc.50.1074
169. Lewandrowski K-U, Ostergren M, de Carvalho PST. Intradiscal expandable balloon distraction during transforaminal decompression for lumbar foraminal and lateral recess stenosis. *Surg Innov*. 2018;25(2):165–173. doi:10.1177/1553350617753243
170. Lübbers T, Abuamona R, Elsharkawy AE. Percutaneous endoscopic treatment of foraminal and extraforaminal disc herniation at the L5-S1 level. *Acta Neurochir (Wien)*. 2012;154(10):1789–1795. doi:10.1007/s00701-012-1432-z
171. Shawky Abdelgawaad A, Babic D, Siam AE, Ezzati A, et al. Extraforaminal microscopic assisted percutaneous nucleotomy for foraminal and extraforaminal lumbar disc herniations. *Spine J*. 2018;18(4):620–625. doi:10.1016/j.spinee.2017.08.258
172. Soliman HM. Irrigation endoscopic discectomy: a novel percutaneous approach for lumbar disc prolapse. *Eur Spine J*. 2013;22(5):1037–1044. doi:10.1007/s00586-013-2701-0
173. Teli M, Lovi A, Brayda-Bruno M, et al. Higher risk of dural tears and recurrent herniation with lumbar micro-endoscopic

discectomy. *Eur Spine J.* 2010;19(3):443–450. doi:10.1007/s00586-010-1290-4

174. Xu B, Xu H, Ma X, et al. Bilateral decompression and intervertebral fusion via unilateral fenestration for complex lumbar spinal stenosis with a mobile microendoscopic technique. *Medicine.* 2018;97(4):e9715. doi:10.1097/MD.00000000000009715

175. Zhang B, Kong Q, Yang J, Feng P, Ma J, Liu J, et al. Short-term effectiveness of percutaneous endoscopic transforaminal bilateral decompression for severe central lumbar spinal stenosis. *Zhongguo Xiu Fu Chong Jian Wai Ke Za Zhi.* 2019;33(11):1399–1405. doi:10.7507/1002-1892.201904131

176. Lewandrowski K-U, Carvalho PST DE, Carvalho P DE, Yeung A, et al. Minimal clinically important difference in patient-reported outcome measures with the transforaminal endoscopic decompression for lateral recess and foraminal stenosis. *Int J Spine Surg.* 2020;14(2):254–266. doi:10.14444/7034

177. Parker SL, Godil SS, Shau DN, Mendenhall SK, McGirt MJ, et al. Assessment of the minimum clinically important difference in pain, disability, and quality of life after anterior cervical discectomy and fusion: clinical article. *J Neurosurg Spine.* 2013;18(2):154–160. doi:10.3171/2012.10.SPINE12312

178. Staffa SJ, Zurakowski D. Statistical power and sample size calculations: a primer for pediatric surgeons. *J Pediatr Surg.* 2020;55(7):1173–1179. doi:10.1016/j.jpedsurg.2019.05.007

179. Staffa SJ, Zurakowski D. Calculation of confidence intervals for differences in medians between groups and comparison of methods. *Anesth Analg.* 2020;130(2):542–546. doi:10.1213/ANE.0000000000004535

180. Croe R. It's the effect size stupid. What effect size is and why it is important. *British Educational Research Association.* 2002.

181. COHEN J. The statistical power of abnormal-social psychological research: a review. *J Abnorm Soc Psychol.* 1962;65:145–153. doi:10.1037/h0045186

182. Lewandrowski K-U, Yeung A. Meaningful outcome research to validate endoscopic treatment of common lumbar pain generators with durability analysis. *J Spine Surg.* 2020;6(S1):S6–S13. doi:10.21037/jss.2019.09.07

183. Kim HS, Wu PH, Lee YJ, Kim DH, Jang IT, et al. Technical considerations of uniportal endoscopic posterolateral lumbar interbody fusion: a review of its early clinical results in application in adult degenerative scoliosis. *World Neurosurg.* 2021;145:682–692. doi:10.1016/j.wneu.2020.05.239

184. Wu PH, Kim HS, Lee YJ, et al. Uniportal full endoscopic posterolateral transforaminal lumbar interbody fusion with endoscopic disc drilling preparation technique for symptomatic foraminal stenosis secondary to severe collapsed disc space: a clinical

and computer tomographic study with technical note. *Brain Sci.* 2020;10(6):373. doi:10.3390/brainsci10060373

185. Zhang J, Jin M-R, Zhao T-X, et al. Clinical application of percutaneous transforaminal endoscope-assisted lumbar interbody fusion. *Zhongguo Gu Shang.* 2019;32(12):1138–1143. doi:10.3969/j.issn.1003-0034.2019.12.014

**Funding:** The authors received no financial support for the research, authorship, and/or publication of this article.

**Declaration of Conflicting Interests:** This manuscript is not meant for or intended to endorse any products or push any other agenda other than the associated clinical outcomes with endoscopic spine surgery. The motive for compiling this clinically relevant information is by no means created and/or correlated to directly enrich anyone due to its publication. This publication was intended to substantiate contemporary endoscopic spinal surgery concepts to facilitate technology advancements. The authors report no conflicts of interest or financial relationships relevant to this work.

**Disclaimer:** The views expressed in this meta-analysis represent those of the authors and no other entity or organization. The authors are accountable for all aspects of the work in ensuring that questions related to the accuracy or integrity of any part of the work are appropriately investigated and resolved.

**Corresponding Author:** Kai-Uwe Lewandrowski, Center for Advanced Spine Care of Southern Arizona and Surgical Institute of Tucson, 4787 E Camp Lowell Dr, Tucson, AZ 85712, USA; business@tucson-spine.com

Published 07 April 2022

This manuscript is generously published free of charge by ISASS, the International Society for the Advancement of Spine Surgery. Copyright © 2022 ISASS. To see more or order reprints or permissions, see <http://ijssurgery.com>.