

Full-Endoscopic Ventral Facetectomy vs Open Laminectomy for Lumbar Lateral Recess Stenosis: A Comparative Study and Brief Literature Review

Stylianos Kapetanakis, Nikolaos Gkantsinikoudis and Georgios Charitoudis

Int J Spine Surg 2022, 16 (2) 361-372

doi: <https://doi.org/10.14444/8218>

<http://ijssurgery.com/content/16/2/361>

This information is current as of April 18, 2024.

Email Alerts Receive free email-alerts when new articles cite this article. Sign up at:
<http://ijssurgery.com/alerts>

Full-Endoscopic Ventral Facetectomy vs Open Laminectomy for Lumbar Lateral Recess Stenosis: A Comparative Study and Brief Literature Review

STYLIANOS KAPETANAKIS, MD, PhD^{1,2}; NIKOLAOS GKANTSINIKOUDIS, MD¹; AND
GEORGIOS CHARITOUDIS, MD, PhD¹

¹Spine Department and Deformities, Interbalkan European Medical Center, Thessaloniki, Greece; ²Department of Minimally Invasive and Endoscopic Spine Surgery, Athens Medical Center, Athens, Greece

ABSTRACT

Background: Lateral recess stenosis (LRS) represents a major etiology of pain and disability in recent years. The aim of the present study was to compare the clinical outcomes of full-endoscopic ventral facetectomy (FEVF) vs conventional open laminectomy (OL) for surgical treatment of lumbar LRS.

Methods: Ninety individuals with diagnosed LRS according to clinical and radiological criteria were included in this study. Patients were appropriately classified into 2 distinct groups according to received treatment. Group A was constituted from 48 patients subjected to FEVF. Contrariwise, the 42 patients of Group B underwent OL. All patients were consecutively evaluated with particular clinical scores preoperatively and at 6 weeks, 3, months, 6 months, 12 months, and 2 years postoperatively. Clinical assessment was conducted with the visual analog scale for leg pain (VAS-LP) and back pain (VAS-BP) and with the Short-Form 36 (SF-36) medical questionnaire.

Results: Values of all studied indices in both groups featured a major clinical improvement in 6 weeks with subsequent quantitatively minor albeit still statistically significant amelioration until the end of follow-up at 2 years. Comparative evaluation of recorded parameters between the 2 groups disclosed that VAS-BP, bodily pain, and role emotional indices of SF-36 were quantitatively and statistically differentiated in favor of Group A in 6 weeks, featuring an amelioration that persisted until the end of follow-up. Registered values of the other parameters were not found to demonstrate a quantitatively and clinically noteworthy differentiation between the 2 groups.

Conclusions: FEVF represents a feasible, safe, and beneficial alternative for surgical therapy of patients with LRS, featuring comparable outcomes with conventional OL.

Clinical Relevance: Lumbar LRS represents a frequent entity with remarkable clinical sequelae. FEVF represents a novel, groundbreaking and minimally invasive technique that should be considered as a safe and efficacious alternative over conventional open surgery in specific patients with LRS.

Level of Evidence: 3.

Endoscopic Minimally Invasive Surgery

Keywords: lumbar spinal stenosis, lateral recess stenosis, laminectomy, percutaneous endoscopic ventral facetectomy, percutaneous transforaminal endoscopic surgery

INTRODUCTION

Lumbar spinal stenosis (LSS) is defined as the narrowing of the spinal canal that is associated with subsequent neurovascular impingement and emergence of clinical symptomatology.¹⁻³ LSS may be divided into 3 distinct subcategories according to anatomic representation: central stenosis (CS), lateral recess stenosis (LRS), and foraminal stenosis (FS), with especial clinical implications in each case.^{2,4} Development of LSS may be robustly attributed to congenital, degenerative, or miscellaneous conditions.⁵

LSS is often characterized by the complete absence of symptoms, demonstrating an insidious evolution.³

However, the appearance of clinical symptomatology dictates implementation of medical treatment. The first line of therapeutic regimen is generally constituted by conservative measures such as drug administration (nonsteroidal anti-inflammatory drugs and analgesics), physiotherapy, and epidural steroid injections. The primary target of these treatment methods is to provide recession of pain and associated symptoms. Nevertheless, clinical failure of these measures obligates spine surgeons to recommend surgical intervention.¹ In these cases, posterior open decompression surgery with or without fusion is currently considered the gold standard.^{1,6}

Transforaminal full-endoscopic surgery (TFES) institutes a novel, minimally invasive and full-endoscopic surgical approach that is established as a substantial technique in spine surgeon's armamentarium in current years. TFES was initially primarily recruited for surgical excision of lumbar disc herniation. Nevertheless, multifarious advantages of this approach have substantially contributed to expansion of its indications' spectrum. Therefore, TFES is currently increasingly implemented for LRS surgical treatment, being known as full-endoscopic ventral facetectomy (FEVF) in these cases.^{4,7-9} FEVF is associated with observable advantages over the conventional open decompression procedures as preservation of dorsal spine elements, minimization of tissue traumatization, and intraoperative hemorrhage as well as rapid postoperative rehabilitation and return to daily activities.^{10,11}

To our best knowledge, there is no study clearly comparing the clinical outcomes of FEVF vs conventional open decompression surgery for LRS surgical treatment in current literature. A general comparison of endoscopic vs open decompression procedures for various nonparticularly defined types of LSS was attempted in one recently published retrospective analysis.¹² Nevertheless, no specific analysis of FEVF vs open laminectomy (OL) was conducted, and it included a small number of patients treated endoscopically with no publication of follow-up outcomes.

The aim of the present study was to directly compare the clinical results of FEVF vs conventional OL for the surgical treatment of LRS. The relatively considerable number of enrolled patients in conjunction with implementation of follow-up evaluation and health-related quality of life (HRQoL) analysis underline the originality of our study.

MATERIALS AND METHODS

Study Population and Approvements

All patients enrolled in this study were diagnosed with LRS based on clinical and imaginary criteria. Non-elderly as well as elderly patients (according to World Health Organization definition)¹³ were included for assessment. Theoretically, all patients were candidates for conventional open decompression surgery, fulfilling all current indications. Patients were meticulously informed about the study's primordial scopes provided their consent to participate by signing written informed consent document. Furthermore, special approval from Institutional Review Board of the hospital was received. All distinct aspects of this specific study were

in concordance with the Code of Ethics of the World Medical Association for experiments involving humans, as defined in Declaration of Helsinki (1975) and in its later amendments (2008).

Inclusion and Exclusion Criteria

Inclusion criteria were (1) radiculopathy, (2) neurogenic claudication, (3) sensory or motor neurologic deficit, (4) LRS confirmed by magnetic resonance imaging (MRI) of the lumbar spine, in compliance with clinical findings, and (5) failure of 12-week typical conservative treatment (analgesic administration, spinal injections, physical therapy).

Exclusion criteria were as follows: (1) noncontained disc hernia exceeding the one-third of the spinal canal on the sagittal MRI scans, (2) sequestration of the disc, (3) recurrent herniated disc or previous surgery at the affected level, (4) segmental instability or spondylo-listhesis, (5) vertebral fracture, and (6) spinal tumor or infection.

Study Design and Rationale

This study was prospectively conducted and included 90 non-elderly and elderly individuals. Forty-eight of these patients (Group A) featured severe comorbidities such as coronary insufficiency, heart failure, diabetes mellitus, and respiratory failure, demonstrating a strong contraindication for general anesthesia administration. Primary etiology of LRS in these patients was also the excessive osseous growth and not yellow ligament hypertrophy/ossification, as confirmed by MRI. After the careful and thorough consideration of the anesthesiologist and radiologist, selected patients received FEVF under local anesthesia and controlled sedation. The remaining 42 patients (Group B) had no particular patient-related contraindications for general anesthesia administration and were thus considered appropriate candidates for conventional OL. LRS emergence in these patients was the combining result of excessive osseous growth as well as yellow ligament hypertrophy/ossification. Hence, surgical selection of FEVF vs OL was equally driven by the subsistence of severe underlying comorbidities and the anatomic background of LRS in each case. All surgical procedures were conducted in 2017 to 2018 by the same senior spine surgeon (S.K.) experienced in both techniques. Patients were meticulously evaluated preoperatively as well as at 6 weeks, 3 months, 6 months, 12 months, and finally in 2 years postoperatively. Objective evaluation of studied individuals was accomplished with particular clinical scales. The visual analog scale (VAS) was distinctly for lower

limb (VAS-LP) and low back pain (VAS-BP) evaluated. Furthermore, the Short-Form 36 (SF-36) medical health survey was implemented for HRQoL assessment.

Surgical Procedures

FEVF

As mentioned above, all patients of Group A in this study underwent successful FEVF. Surgical technique was full endoscopic and conducted under local anesthesia and mild controlled sedation. Patients were initially placed in lateral decubitus position lying down on the opposite side, in order to accomplish maximal enlargement of foraminal space. Sequential implemented steps for conduction of technique in all cases were:

1. Surgical field disinfection and skin marking of midline and iliac crest ipsilateral to disc pathology.
2. Identification of needle (15 cm, 16G) entrance point (11 cm laterally of midline).
3. Infiltration of skin with local anesthesia at the point of needle entrance.
4. Insertion of needle under a more cranial angulation in comparison with classic endoscopic discectomy surgery and fluoroscopic verification of its position in anteroposterior and lateral views (tip of needle was promoted to the ipsilateral to disc pathology posterolateral edge of superior endplate of underlying vertebra, with transit corridor leading thus in Kambin's triangle)¹⁴ (Figure 1).
5. Insertion of guidewire (45 cm, 0.7 mm) through needle trajectory with subsequent vigilant removal of needle and mild extension of skin incision with a scalpel.
6. Insertion of 2 muscle dilators (of 235 mm length with external diameter of 3 and 6.3 mm, respectively).
7. Sequential insertion of reamers with gradually increasing diameters (4, 5, 6, 7, 8, and even 9 mm in selected cases) so that satisfactory foraminotomy/foraminoplasty and osseous decompression of lateral recess via ventral facetectomy (less than one-third of facet joint was removed in each case) was accomplished (Figure 2). Performance of this step was escorted with administration of mild sedation and analgesia (fentanyl ampoule) by the anesthesiologist.
8. Insertion of working cannula and endoscope to remove any herniated disc material that contributed to nerve root impingement and visualize nerve root decompression.

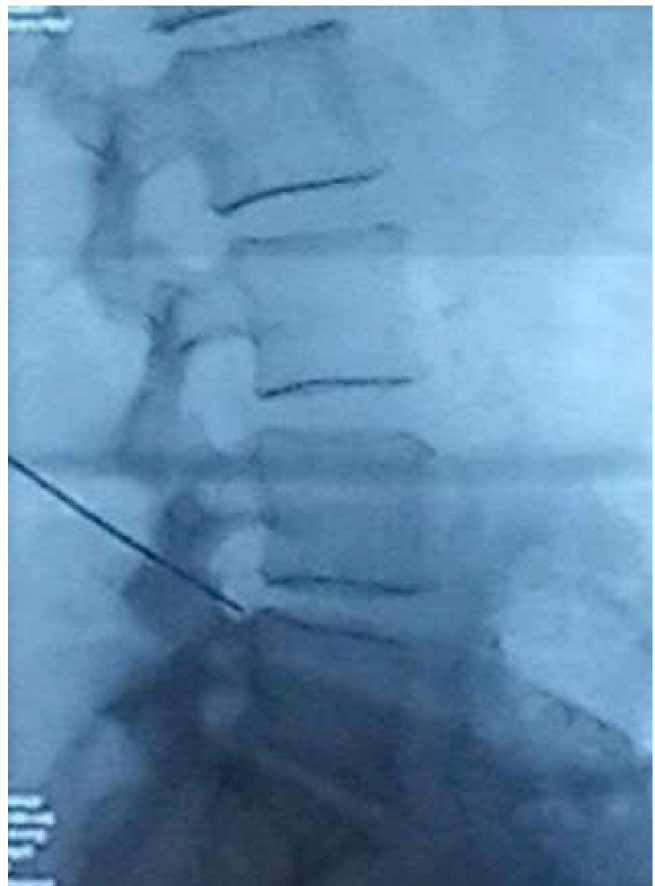


Figure 1. Fluoroscopic corroboration of needle position (lateral view).

Open Laminectomy

OL under general anesthesia was successfully performed in all patients in Group B. A routine posterior decompression approach was applied in all cases. Patients were logrolled in the prone position in a Jackson table with appropriate transverse placement of bolsters under the thoracic wall and pelvic girdle to ensure freedom of the entire abdomen. Hips were flexed to achieve a satisfactory increase in interlaminar distance. Operated level was verified via fluoroscopic imaging. A midline longitudinal skin incision (3–5 cm) superficially to the spinous processes of the pathologic level was initially performed. Surgical dissection of subcutaneous fat and lumbodorsal fascia with parallel control of hemorrhage was subsequently conducted with cautery. Paraspinal muscles were detached subperiostally as a single unit with Cobb elevator. After repetitive verification of pathologic level with fluoroscopy, the removal of osseous lamina and adjacent ligamentum flavum was gently performed with Kerrison rongeurs. Visualization of epidural fat, dural sac, and nerve roots was subsequently

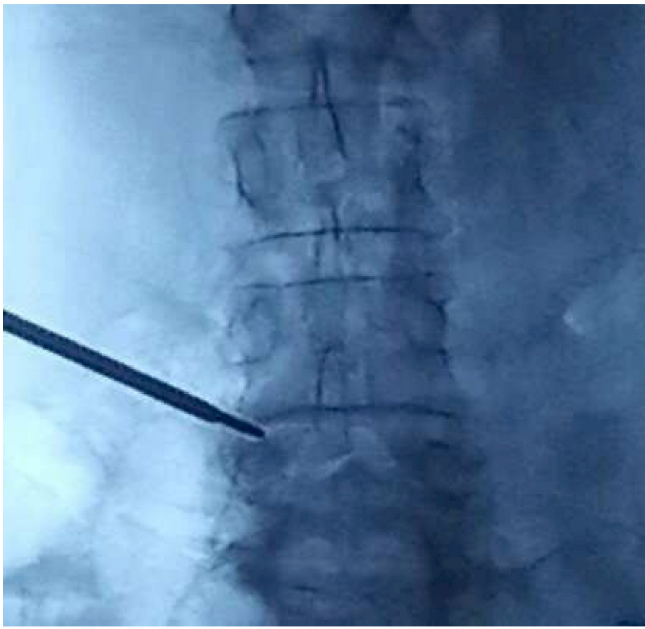

Figure 2. Sequential implementation of increasing diameter reamers and foraminotomy.

accomplished in all cases. Foraminal decompression via foraminotomy and mobilization of the nerve root were then performed. Adequate decompression was, therefore, ensured. After meticulous control of any hemorrhage source, suturing of lumbarodorsal fascia, subcutaneous fat, and skin was performed.

VAS

VAS represents a convenient and punctual method for pain intensity assessment.¹⁵ A unipolar horizontal line of 100 mm length was utilized in all cases. Patients pointed out the level of subjectively perceived pain with a mark, stating separate outcomes for lower limb and low back pain in each interval evaluation (VAS-LP and VAS-BP, respectively). Recorded scores were estimated in millimeters, adopting an 1-decimal place approach. Lower clinically important alteration was defined at the level of 9 mm. Related parameters such as gender, age, and underlying etiology of pain were not distinctly assessed.¹⁶

SF-36 Medical Health Survey Questionnaire

SF-36 questionnaire is routinely implemented for HRQoL assessment in the field of spine surgery.¹⁷ SF-36 is constituted by 36 distinct objects, overall evaluating 8 parameters regarding patients' general health (GH) and daily routine circumstances: physical function (PF); role-physical (RP); bodily pain

(BP); GH; energy, fatigue, and vitality (V); social function (SF); role-emotional (RE); and mental health (MH). This particular questionnaire was completed by all patients in each distinct follow-up interval. Results were processed so that they were represented by a specific percentage. A higher score was generally associated with favorable HRQoL.

Statistical Methods

Statistical analyses of collected data were conducted with statistical package SPSS, version 23.00 (SPSS Inc., Chicago, IL, USA). Recorded continuous variables were expressed as mean \pm SD, and registered categorical variables were calculated as percentages. Paired-sample *t* test and Student *t* test for independent samples (depending on the comparison of specific data in 1 distinct group or between the 2 groups, respectively) were implemented for statistical comparison of continuous indices in cases of normal distribution presence. Otherwise, Wilcoxon signed-rank or Mann-Whitney *U* test were respectively employed. Level of statistical significance was determined at a *P* value of 0.05. All studied indices were initially assessed preoperatively and subsequently at specific regular follow-up intervals postoperatively.

RESULTS

No specific intraoperative complications were observed in either group. All operated patients were transferred to the monitoring chamber for an hour and subsequently to the inpatient clinic. All patients were discharged on the same day of surgery.

Postoperative assessment demonstrated that, considering Group A, 1 patient (2.08%) exhibited temporary dysesthesia in the distribution of L5 nerve root (being operated in L5-S1 level). However, clinical symptoms were completely resolved after 6 weeks postoperatively. On the contrary, 1 patient (2.4%) in Group B presented with surgical site infection on the fourth postoperative day, which was treated uneventfully with wound drainage and oral antibiotics. Two other patients (4.8%) in the same group expressed transient neurogenic dysesthesia (1 in distribution of L4 and 1 in L5 nerve root), which was completely resolved after 6 weeks in both cases.

All patients successfully completed the follow-up interval of 2 years. Demographic data of enrolled individuals are depicted in Table 1.

Initial comparison of studied indices in each group separately indicated the presence of clinically

Table 1. Demographic data of enrolled individuals.

Characteristic	Total (N = 90)	Group A (n = 48)	Group B (n = 42)
Sex n (%)			
Men	46 (51.1)	26 (54.2)	20 (47.6)
Women	44 (48.9)	22 (45.8)	22 (52.4)
Age, y, mean ± SD	73.0 ± 7.2	73.8 ± 6.1	72.0 ± 8.2
Operated level, n (%)			
L3-L4	20 (22.2)	12 (25.0)	8 (19.0)
L4-L5	49 (54.4)	25 (52.1)	24 (57.1)
L5-S1	21 (23.3)	11 (22.9)	10 (23.8)

significant amelioration in 6 weeks with subsequent minimal enhancement and stabilization of each distinct parameter until the end of follow-up (Figures 3 and 4). Statistical comparison of various values for each index between follow-up intervals demonstrated further that, except for the statistical significance of the recorded major improvement in 6 weeks for all indices, the overwhelming majority of values of studied parameters persisted in exhibiting statistically significant amelioration

in all examined follow-up checkpoints when compared with respective values in the previous chronic interval.

Statistical comparison of numerical data of studied indices between the 2 groups is demonstrated in Table 2. No statistically significant differences was observed in either recorded parameter between the 2 groups during comparison of preoperative values. Regarding recorded VAS values, VAS-LP values were almost quantitatively equal between the 2 groups in the determined follow-up intervals, resulting in the absence of statistical significance in comparative evaluation in the vast majority of follow-up intervals. A statistical significance in favor of Group B was recorded at the 2-year assessment, but there was no substantial clinical correlation (Table 2). Contrariwise, VAS-BP values were statistically and quantitatively significantly ameliorated in Group A in all follow-up intervals, displaying therefore also clinical sententiousness (Figure 5 and Table 2).

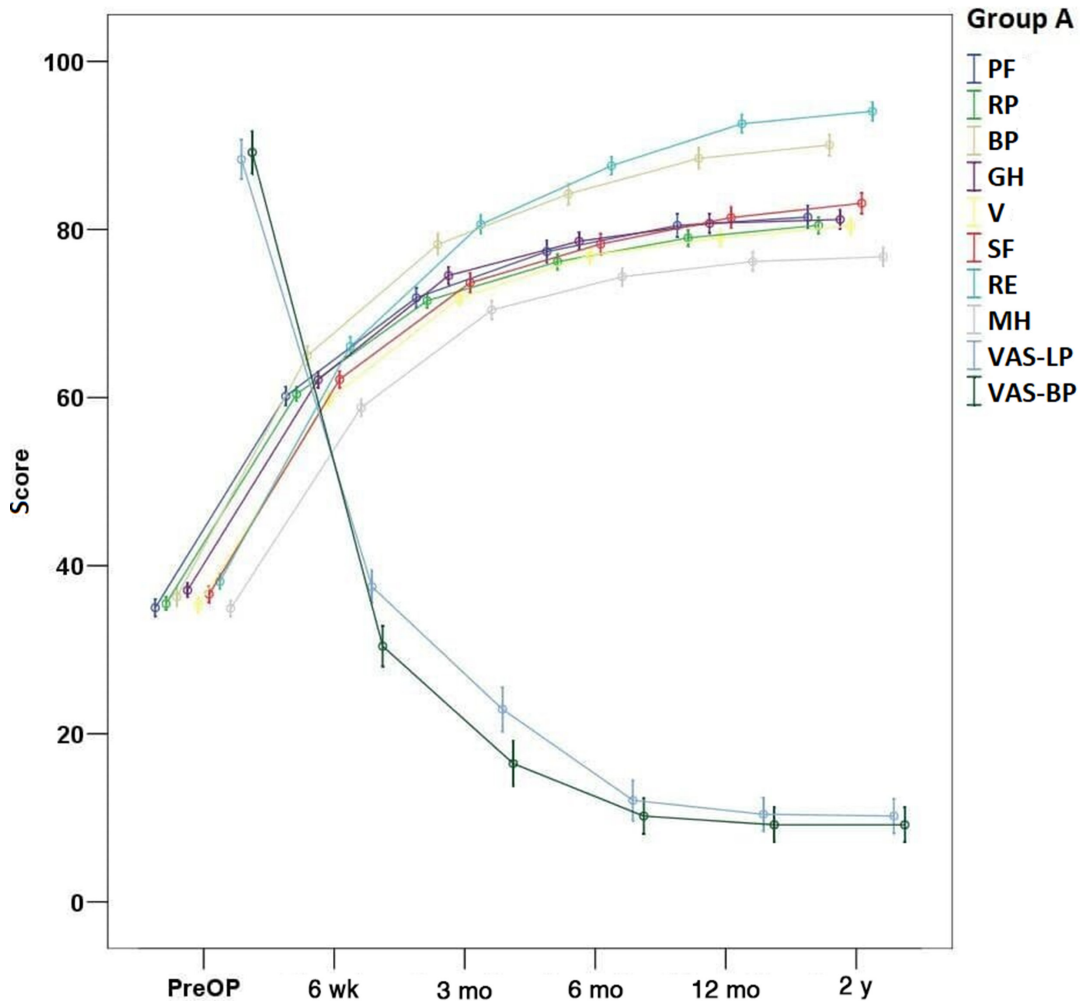


Figure 3. Schematic representation of studied indices course during various follow-up intervals (Group A). Abbreviations: BP, bodily pain; GH, general health; MH, mental health; PF, physical function; PreOP, preoperative; RE, role-emotional; RP, role-physical; SF, social function; V, energy, fatigue, and vitality; VAS-BP, visual analog scale for low back pain; VAS-LP, visual analog scale for lower limb pain.

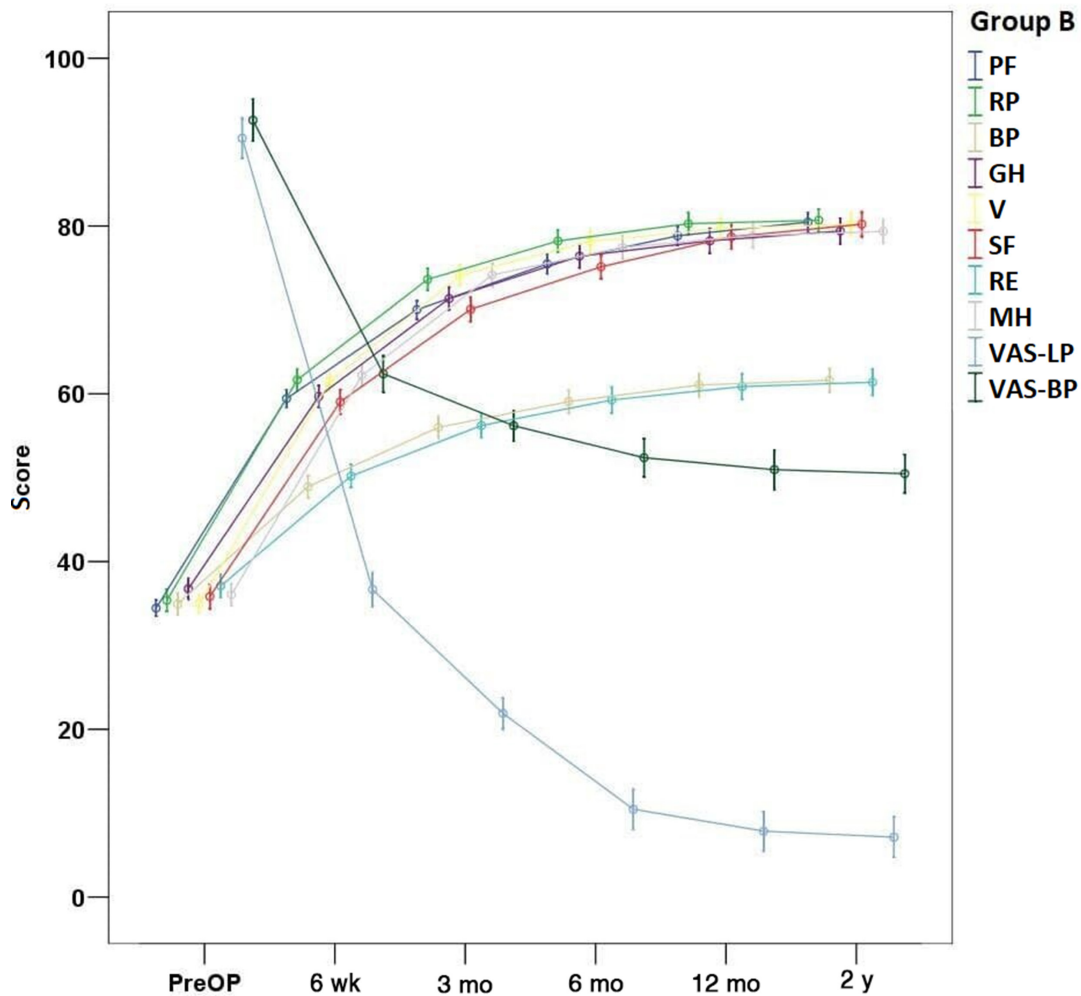


Figure 4. Schematic representation of studied indices course during various follow-up intervals (Group B). Abbreviations: BP, bodily pain; GH, general health; MH, mental health; PF, physical function; PreOP, preoperative; RE, role-emotional; RP, role-physical; SF, social function; V, energy, fatigue, and vitality; VAS-BP, visual analog scale low back pain; VAS-LP, visual analog scale lower limb pain.

Considering the values of SF-36 in the 2 groups, BP and RE parameters were statistically significantly ameliorated in Group A in all follow-up intervals. This differentiation was quantitatively and hence clinically remarkable (Figure 6 and Table 2). Values of the other recorded indices featured similar quantitative characteristics between the 2 groups in the various follow-up intervals, despite the recorded relative existence of statistically significant differentiation in all parameters during 1 or more follow-up checkpoints. Hence, the subsistence of statistical differentiation was not associated with clinically evaluable discrepancy (Table 2).

DISCUSSION

LSS is currently theorized as a principal etiology of pain and disability in elderly individuals. Prevalence of this pathologic entity has been said to vary from 5% to 47% in adults after the fourth decade of life with

gradual increasing of recorded incidence with age.^{1,5} LSS has demonstrated to have a considerable impact on socioeconomics, representing one of the frequently diagnosed spine disorders and a major etiology of surgery in older adults.^{1,18}

Clinical emergence of LSS is the final outcome of consecutive biomechanical alterations in the entire spinal segment. Intervertebral disc degeneration represents the inaugural process in LSS pathogenesis. Disc degeneration is associated with perdition of its unique biomechanical properties regarding mechanical loading. Hence, an increment in loading pressure of posterior lumbar facet joints occurs. This excessive mechanical stimulation of facet joints and adjacent articular processes is consecutively related to hypertrophy and localized stiffness. The abnormal and surplus osseous growth institutes, in conjunction with ligamentum flavum condensation or ossification, the anatomic

Table 2. Recorded values of each outcome measure in all studied indexes during before surgery and at various follow-up visits.

Parameter	Preoperative		6 wk		3 mo		6 mo		12 mo		2 y	
	Group A	Group B	Group A	Group B	Group A	Group B	Group A	Group B	Group A	Group B	Group A	Group B
PF	35.0 ± 3.5 <i>P</i> = 0.396	34.5 ± 3.1	60.2 ± 3.8 <i>P</i> = 0.286	59.4 ± 3.3	71.9 ± 4.2 <i>P</i> = 0.018	70.0 ± 3.6	77.4 ± 4.6 <i>P</i> = 0.018	75.5 ± 3.6	80.5 ± 4.7 <i>P</i> = 0.041	78.8 ± 3.6	81.5 ± 4.8 <i>P</i> = 0.163	80.5 ± 3.6
RP	35.5 ± 2.6 <i>P</i> = 0.661	35.4 ± 4.3	60.4 ± 2.9 <i>P</i> = 0.188	61.7 ± 4.1	71.5 ± 2.9 <i>P</i> = 0.014	73.6 ± 4.1	76.2 ± 3.2 <i>P</i> = 0.023	78.2 ± 4.2	79.0 ± 3.3 <i>P</i> = 0.164	80.3 ± 4.3	80.5 ± 3.3 <i>P</i> = 0.926	80.7 ± 4.3
BP	36.3 ± 3.8 <i>P</i> = 0.104	35.0 ± 4.1	65.0 ± 3.9 <i>P</i> < 0.001	48.9 ± 4.1	78.2 ± 4.3 <i>P</i> < 0.001	56.0 ± 4.1	84.2 ± 4.4 <i>P</i> < 0.001	59.1 ± 4.3	88.5 ± 4.3 <i>P</i> < 0.001	61.1 ± 4.4	90.1 ± 4.3 <i>P</i> < 0.001	61.6 ± 4.6
GH	37.1 ± 2.9 <i>P</i> = 0.829	36.8 ± 4.0	62.1 ± 3.2 <i>P</i> = 0.006	59.7 ± 4.1	74.5 ± 3.5 <i>P</i> = 0.001	71.4 ± 4.3	78.6 ± 3.6 <i>P</i> = 0.021	76.4 ± 4.4	80.7 ± 4.0 <i>P</i> = 0.011	78.2 ± 4.7	81.2 ± 4.0 <i>P</i> = 0.084	79.4 ± 4.9
V	35.3 ± 2.8 <i>P</i> = 0.626	35.0 ± 3.3	59.8 ± 3.0 <i>P</i> = 0.310	61.5 ± 3.7	71.8 ± 3.1 <i>P</i> = 0.005	74.1 ± 4.0	76.9 ± 3.4 <i>P</i> = 0.121	78.2 ± 4.2	79.0 ± 3.5 <i>P</i> = 0.412	79.7 ± 4.2	80.4 ± 3.6 <i>P</i> = 0.729	80.2 ± 4.4
SF	36.6 ± 3.2 <i>P</i> = 0.503	35.8 ± 4.6	62.2 ± 3.8 <i>P</i> = 0.001	59.1 ± 4.6	73.7 ± 3.9 <i>P</i> < 0.001	70.1 ± 4.6	78.3 ± 4.2 <i>P</i> = 0.003	75.1 ± 4.5	81.4 ± 4.2 <i>P</i> = 0.008	78.7 ± 4.6	83.1 ± 4.2 <i>P</i> = 0.005	80.2 ± 4.7
RE	38.1 ± 3.2 <i>P</i> = 0.209	37.1 ± 4.4	66.1 ± 3.8 <i>P</i> < 0.001	50.2 ± 4.4	80.6 ± 3.8 <i>P</i> < 0.001	56.2 ± 4.6	87.6 ± 3.7 <i>P</i> < 0.001	59.3 ± 4.9	92.6 ± 3.7 <i>P</i> < 0.001	60.9 ± 5.0	94.1 ± 3.8 <i>P</i> < 0.001	61.4 ± 4.9
MH	34.9 ± 3.2 <i>P</i> = 0.158	36.1 ± 4.1	58.8 ± 3.5 <i>P</i> < 0.001	62.2 ± 4.2	70.4 ± 3.7 <i>P</i> < 0.001	74.2 ± 4.4	74.4 ± 3.6 <i>P</i> = 0.001	77.5 ± 4.5	76.2 ± 3.8 <i>P</i> = 0.004	78.9 ± 4.6	76.8 ± 3.9 <i>P</i> = 0.005	79.4 ± 4.5
VAS-LP	88.3 ± 8.1 <i>P</i> = 0.191	90.5 ± 7.6	37.5 ± 6.7 <i>P</i> = 0.555	36.7 ± 6.5	22.9 ± 9.0 <i>P</i> = 0.523	21.9 ± 5.9	12.1 ± 8.2 <i>P</i> = 0.318	10.5 ± 7.6	10.4 ± 6.8 <i>P</i> = 0.086	7.9 ± 7.5	10.2 ± 7.0 <i>P</i> = 0.043	7.1 ± 7.7
VAS-BP	89.2 ± 8.7 <i>P</i> = 0.058	92.6 ± 8.0	30.4 ± 8.2 <i>P</i> < 0.001	62.4 ± 6.9	16.5 ± 9.1 <i>P</i> < 0.001	56.2 ± 5.8	10.2 ± 7.3 <i>P</i> < 0.001	52.4 ± 7.3	9.2 ± 7.1 <i>P</i> < 0.001	51.0 ± 7.6	9.2 ± 7.1 <i>P</i> < 0.001	50.5 ± 7.3

Abbreviations: BP, bodily pain; GH, general health; MH, mental health; PF, physical function; RE, role-emotional; RP, role-physical; SF, social function; V, energy, fatigue, and vitality; VAS-BP, visual analog scale for low back pain; VAS-LP, visual analog scale for lower limb pain.

P value indicates statistical comparison of recorded values between the 2 groups in the given interval. Statistically significant *P* values are in boldface.

Values of SF-36 indexes represent percentages, whereas recorded VAS values constitute millimeters.

hallmarks of LSS.³ The emergence of classical LSS symptoms as intermittent neurogenic claudication, low back pain, and radiating lower limb pain indicates the presence of neurovascular impingement.^{1,3} Potential pathogenetic mechanisms of abovementioned symptomatology appearance involve congestion of epidural venous plexus, neural ischemia, and central pain perception sensitization in cases of nerve root injury.³

TFES represents a full-endoscopic surgical approach with noteworthy recognition in the field of spine surgery in recent years. Technical adjustment of TFES for LRS surgical treatment results in FEVF technique. The constant widening of TFES indications spectrum in current years may be related to its prodigious advantages in contrast to the respective open surgery counterparts. Technically speaking, TFES warrants an exceptional visualization of foraminal anatomy and related structures, abating alongside surgery duration and, therefore, operation-related complications. Moreover, minimal skin incision and intraoperative hemorrhage, preservation of dorsal musculature, osseous, and ligamentous structures as well as diminished perioperative morbidity and hospitalization duration all synthesize the advantageous hallmarks of TFES.^{4,7–11,19–21}

Implementation of TFES for LSS surgical treatment has been related to favorable outcomes in recent literature reports. Kapetanakis et al⁴ were the first to conduct a prospective study in order to determine the multifarious outcomes of the special FEVF procedure in LRS surgical treatment. Eighty-five consecutive non-elderly individuals with diagnosed LRS according to clinical and radiologic

criteria were enrolled. Authors evaluated pain (utilizing VAS-LP and VAS-BP as also determined in the present study) as well as HRQoL (via SF-36 questionnaire) in a 2-year follow-up. Values of all routinely studied indices of SF-36 in conjunction with VAS-LP featured a constant statistically significant amelioration in all follow-up intervals. VAS-BP was statistically remarkably enhanced in 6 weeks, demonstrating no further alterations. It was concluded that performance of FEVF in non-elderly individuals with LRS represents a satisfactory alternative in terms of safety and effectiveness.⁴ Auspicious outcomes of TFES in LRS as well as in other anatomic types of LSS as CS and FS were also verified from later clinical studies.^{22,23} Appropriate technical modifications regarding foraminoplasty in FEVF procedure may be associated with ameliorated outcomes in patients with LRS.²⁴

FEVF implementation in elderly individuals with LRS should be distinctly theorized, concerning its executively great incidence in this patient subpopulation. Elderly patients with LRS often display strong contraindications for conventional open decompression surgery with or without fusion as age and severe underlying comorbidities. Furthermore, the inherent surgical characteristics of open procedures such as extensive tissue injury, increased perioperative complication rate, and relatively lingering rehabilitation make these surgeries a detrimental and potentially hazardous treatment strategy for elderly patients.²⁵ In this context, a novel minimally invasive alternative to open decompression procedures would represent a more logical and beneficial selection.

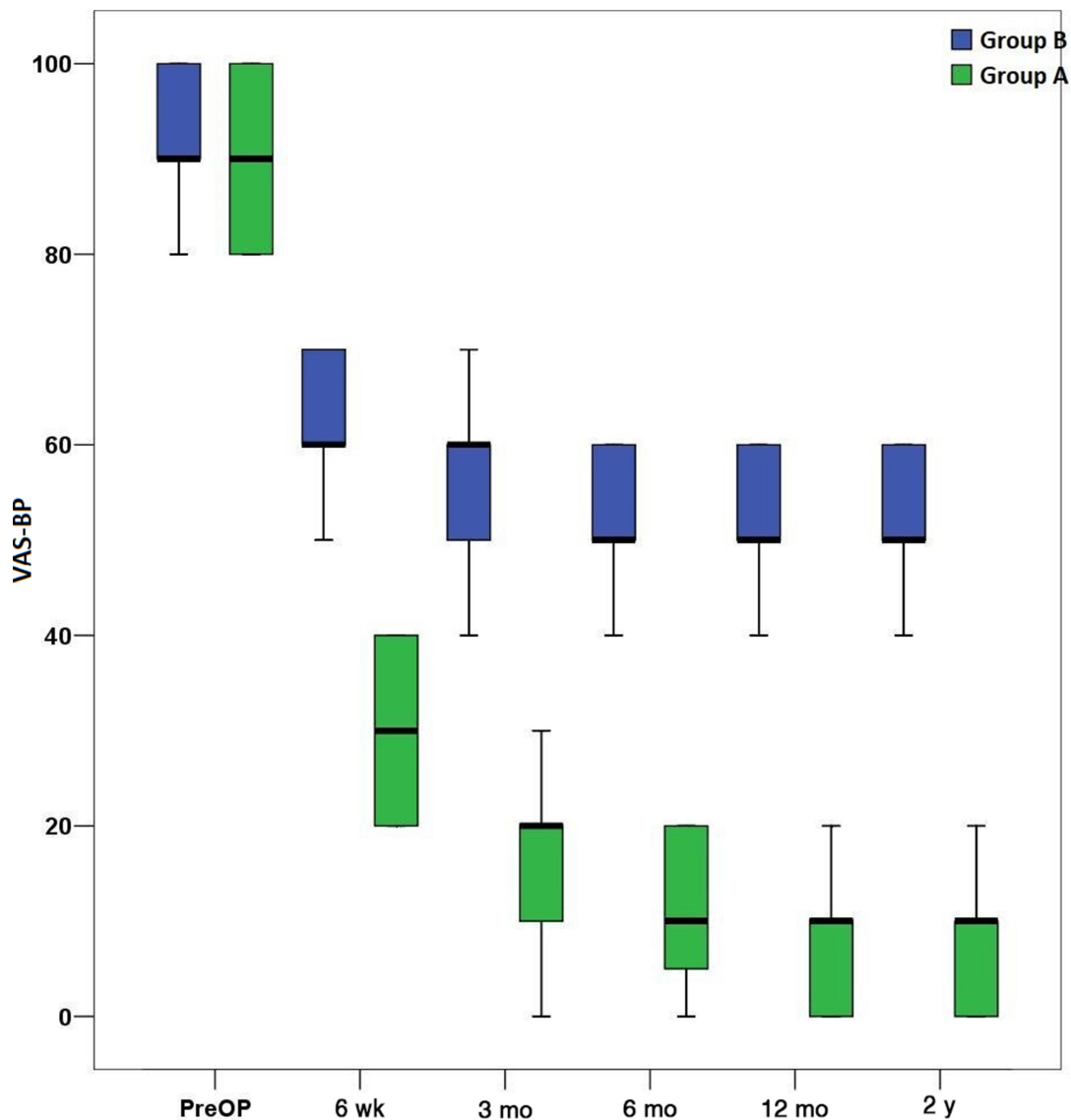


Figure 5. Presentation of visual analog scale for low back pain (VAS-BP) values change in studied follow-up intervals. Abbreviation: PreOP, preoperative.

Several studies have attempted to delineate the special effects of FEVF in elderly individuals with LRS. Kapetanakis et al²⁰ prospectively studied 65 elderly individuals with severe accompanying comorbidities and LRS to determine the precise outcomes of FEVF in these patients through 2-year follow-up. Implementing evaluation measures similar to those in their previous study,⁴ they found that all recorded parameters featured a statistically significant amelioration in all follow-up intervals, advocating for the veritable effectiveness of FEVF. Furthermore, no major perioperative complications were registered.²⁰ In another retrospective study, Lin et al studied 65 consecutive elderly individuals with LRS and FS who were subjected to TFES with foraminoplasty and discectomy using a visualization reamer. VAS scores for lower limb and low back pain,

Oswestry Disability Index (ODI), and modified McNab criteria were evaluated in a mean follow-up of 16.12 months. Recorded results indicated that VAS scores and ODI were statistically significantly improved post-operatively. Moreover, outcomes were published to be “excellent” or “good” in the overwhelming majority (89.23%) of patients. Authors thus concluded that TFES is associated with favorable outcomes in elderly patients with LRS and FS.²⁶ Analogous results regarding the substantially beneficial outcomes of FEVF in patients with LRS and other comorbidities were reported from another recently published study.²⁷

Considering the aggregated data from the above-mentioned studies, FEVF seems to constitute a non-inferior technique in terms of safety and effectiveness when compared with conventional open decompression

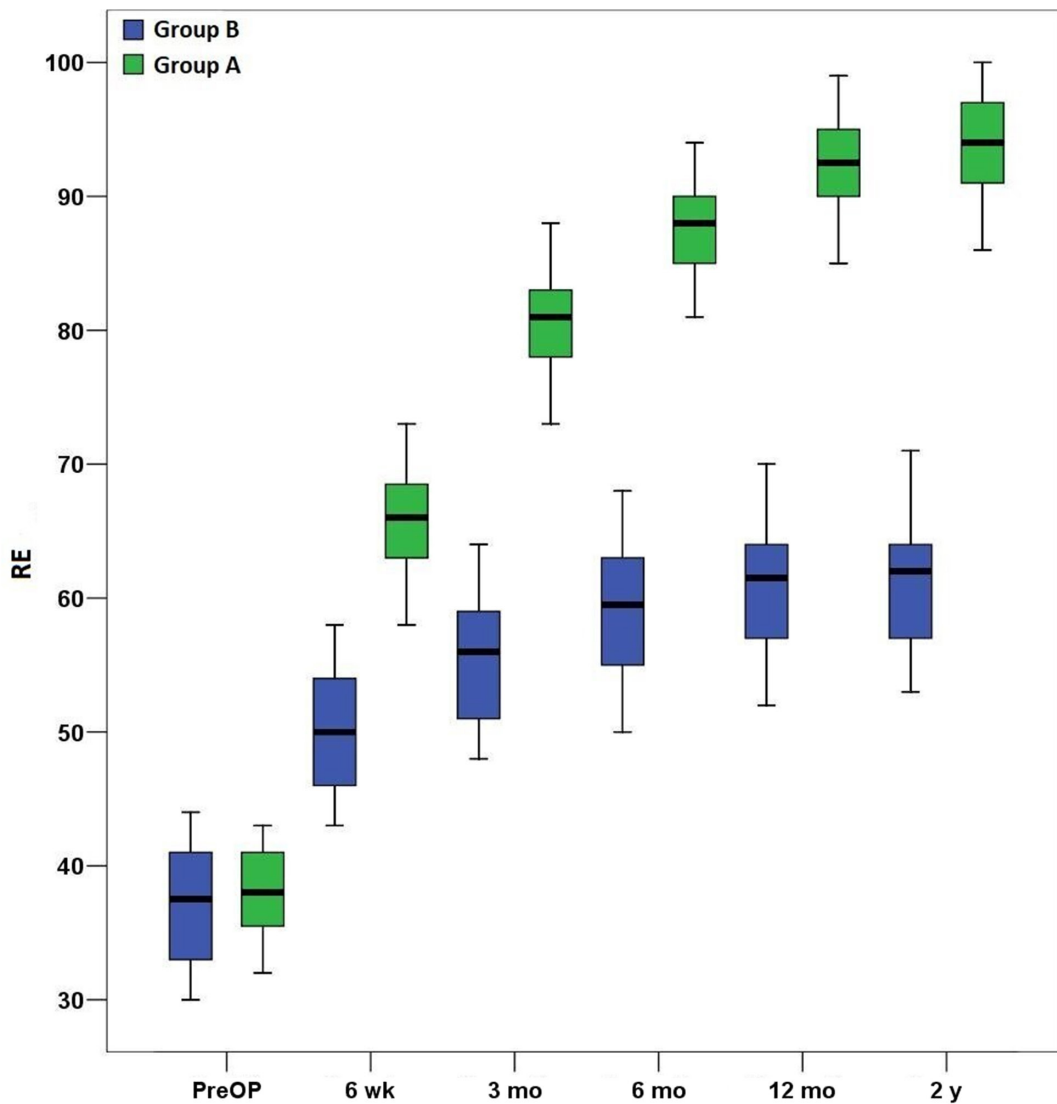


Figure 6. Role-emotional (RE) parameter assessment in the determined follow-up intervals. Abbreviation: PreOP = preoperative.

procedures for LRS surgical treatment. However, there is a noticeable paucity of studies comparing outcomes of these different procedures for LRS treatment in current literature as, to our best knowledge, no such studies exist.

Chiu et al were the only to publish relative outcomes on this issue, comparing endoscopic vs open nonendoscopic decompression procedures for surgical treatment of LSS. A total number of 10,726 patients with single-level LSS were included for retrospective evaluation. Endoscopic decompression was performed in 34 patients, whereas the other 10,692 were subjected to open decompression surgery. Recorded outcomes demonstrated the absence of evaluable discrepancy in operative and hospitalization times, surgical complications rate, and overall mortality between the 2 groups. Authors therefore concluded that endoscopic

decompression is not related to considerable advantageous differentiations vs specific nonendoscopic techniques for surgical treatment of LSS.¹²

In our study, 90 elderly and non-elderly patients were prospectively evaluated with specific clinical scales, in order to identify the presence of specific differential characteristics of FEVF vs OL for LRS surgical treatment. Implemented criteria for surgical strategy selection were the potential existence of underlying comorbidities and the anatomic type of stenosis. All patients with accompanying comorbidities were automatically included in Group A, since general anesthesia administration would bear significant hazards for these patients. On the contrary, otherwise healthy individuals were included in Group B. Regarding the anatomic features and underlying etiology of stenosis, patients in Group A displayed primarily excessive osseous growth, whereas patients in Group B also demonstrated

ligamentum flavum hypertrophy or ossification. This particular criterion was applied after thorough deliberation with radiologists so that optimal outcomes of the 2 procedures were ensured. FEVF represents a purely lateral-transforaminal approach. Hence, it is inherently incapable of removing a pathologic ligamentum flavum, which is a routine surgical step in OL.

Regarding clinical evaluation, we decided not to be confined to VAS-LP and VAS-BP scores. As a distinct LSS anatomic type, LRS is associated with considerable pain and disability.¹ From this point of view, a more multifaceted evaluation, as conducted via SF-36, would be much more representative. Hence, the degree of perceived pain in conjunction with its unique implication in sociopsychological status was assessed for each patient in this study.

The overwhelming majority of registered values of all studied indices in both groups were statistically significantly ameliorated in determined follow-up intervals when compared with previous. This finding generally demonstrates the relative effectiveness of both techniques in pain relief and HRQoL improvement.

Nonetheless, comparative assessment of utilized parameters between the 2 groups demonstrated an overt superiority of FEVF vs OL in VAS-BP, BP, and RE indices amelioration. We hypothesize that skin incision with the associate extensive deeper tissue traumatization in OL constitutes the primary etiology of this finding. Patients in Group B expressed, therefore, persistent back pain in all follow-up intervals in comparison with their Group A counterparts. VAS-BP and BP indices were thus relatively deteriorated in these patients. In addition, the multifarious effects of perceived pain in individual's emotional status may be responsible for the comparative discordance of RE values between the 2 groups. The presence of quantitatively equal VAS-LP values between the groups indicates the effectiveness of both techniques in foraminal decompression.

It is of crucial importance to mention that our study exhibits fundamental differences compared with that of Chiu et al,¹² which considerably limit their comparability. First and foremost, neither anatomic characteristics of underlying pathologic entity nor precise description of conducted endoscopic and open surgical procedures in enrolled individuals were provided in the published study of Chiu et al. Hence, patients with all types of LSS subjected to different types of surgery were evaluated, without exceptions. Second, a number of treated patients in the endoscopic group were enormously disproportionate when compared with the respective number in open group in the aforementioned study. Except for the great numerical incongruity, this fact may reflect a lesser experience

of surgeons with the novel FEVF procedure, thus influencing the final outcomes. Third, the retrospective design of that study in conjunction with the absence of follow-up application may also limit generalizability of its principal findings. For these reasons, we theorize that comparison of the results of the 2 studies would be venturesome and misleading.

Despite the demonstrated favorable outcomes of FEVF for LRS in this study, implementation of technique may feature considerable pitfalls in specific cases. Hence, conduction of technique without meticulous preoperative planning may substantially undermine its safety and efficacy, thereby increasing the risk of complications. Excessive hypertrophy of facet joints with associated severe FS may be present in particular cases of LRS. Preoperative evaluation of foraminal anatomy in radiologic examinations may be, especially for these patients, critical for surgical success.²⁸ Furthermore, ipsilateral disc space height should be also considered during preoperative planning. Severe diminution of intervertebral space craniocaudal diameters due to disc collapse may contribute to decrease of lumbar lordosis and substantial alteration of foraminal anatomy with reduction of foraminal diameters, rendering thus uncomplicated conduction of technique arduous to impossible. These parameters should be thoroughly preoperatively considered by spine surgeon in order to minimize the risk of intraoperative complications and accomplish optimal clinical outcomes.

Noninferior outcomes of FEVF over OL for LRS demonstrated in this study should be cautiously interpreted, considering the framework of absence of relative comparative investigations in the literature. In this study, presence of severe underlying comorbidities represented an especial parameter that determined surgical treatment method selection. Hence, it constitutes a distinct confounder that may have substantially influenced final outcome. Nevertheless, this was not obvious from SF-36 statistical assessment, as representative parameters of overall health status (as GH, V, and MH) were not depicted to feature noteworthy differentiation between the 2 groups. Moreover, limited sample size and follow-up duration constitute relative limitations of this study that should be overcome in future wider clinical studies.

CONCLUSIONS

Results of present study demonstrated that FEVF represents a safe and effective technique for LRS surgical treatment, featuring comparable results with conventional OL. FEVF may constitute an ideal surgical alternative for patients with LRS and severe underlying comorbidities, warranting ameliorated outcomes

in overall emotional and pain status. Nevertheless, proper selection of surgical strategy should be carefully decided on a patient-by-patient basis. Outcomes of this preliminary study should be, in our opinion, cautiously interpreted, concerning the absolute absence of relative studies in the literature. Multicenter studies with greater population sizes and even more extended follow-up assessment are required to verify the noninferiority of FEVF vs OL for LRS surgical treatment.

REFERENCES

1. Anderson DB, Luca KD, Jensen RK, et al. A critical appraisal of clinical practice guidelines for the treatment of lumbar spinal stenosis. *Spine J.* 2021;21(3):455–464. doi:10.1016/j.spinee.2020.10.022
2. Jensen RK, Lauridsen HH, Andresen ADK, Mieritz RM, Schiøtz-Christensen B, Vach W. Diagnostic screening for lumbar spinal stenosis. *Clin Epidemiol.* 2020;12:891–905. doi:10.2147/CLEP.S263646
3. Lee BH, Moon SH, Suk KS, Kim HS, Yang JH, Lee HM. Lumbar spinal stenosis: pathophysiology and treatment principle: a narrative review. *Asian Spine J.* 2020;14(5):682–693. doi:10.31616/asj.2020.0472
4. Kapetanakis S, Gkantsinikoudis N, Papatheanasiou JV, Charitoudis G, Thomaidis T. Percutaneous endoscopic ventral facetectomy: an innovative substitute of open decompression surgery for lateral recess stenosis surgical treatment? *J Craniovertebr Junction Spine.* 2018;9(3):188–195. doi:10.4103/jcvjs.JCVJS_76_18
5. Chen B, Yao LV, Wang ZC, Guo XC, Chao CZ. Decompression with fusion versus decompression in the treatment of lumbar spinal stenosis: a systematic review and meta-analysis. *Medicine (Baltimore).* 2020;99(38):e21973. doi:10.1097/MD.00000000000021973
6. Kitagawa T, Ogura Y, Kobayashi Y, et al. Improvement of lower back pain in lumbar spinal stenosis after decompression surgery and factors that predict residual lower back pain. *Global Spine J.* 2021;11(2):212–218. doi:10.1177/2192568220905617
7. Yeung AT. The evolution and advancement of endoscopic foraminal surgery: one surgeon's experience incorporating adjunctive technologies. *SAS J.* 2007;1(3):108–117. doi:10.1016/SASJ-2006-0014-RR
8. Ahn Y. Percutaneous endoscopic decompression for lumbar spinal stenosis. *Expert Rev Med Devices.* 2014;11(6):605–616. doi:10.1586/17434440.2014.940314
9. Fan N, Yuan S, Du P, et al. Design of a robot-assisted system for transforaminal percutaneous endoscopic lumbar surgeries: study protocol. *J Orthop Surg Res.* 2020;15(1):479. doi:10.1186/s13018-020-02003-y
10. Kapetanakis S, Gkantsinikoudis N, Charitoudis G. The role of full-endoscopic lumbar discectomy in surgical treatment of recurrent lumbar disc herniation: a health-related quality of life approach. *Neurospine.* 2019;16(1):96–104. doi:10.14245/ns.1836334.167
11. Kapetanakis S, Gkantsinikoudis N, Thomaidis T, Theodosiadis P. The role of full-endoscopic lumbar discectomy in patients with neurodegenerative disorders: technical note and short literature review. *Surg Neurol Int.* 2020;11:23. doi:10.25259/SNI_581_2020
12. Chiu RG, Patel S, Zhu A, Aguilar E, Mehta AI. Endoscopic versus open laminectomy for lumbar spinal stenosis: an international, multi-institutional analysis of outcomes and adverse events. *Global Spine J.* 2020;10(6):720–728. doi:10.1177/2192568219872157
13. Powell JB, Gach JE. Phototherapy in the elderly. *Clin Exp Dermatol.* 2015;40(6):605–610. doi:10.1111/ced.12626
14. Kambin P, Bracer MD. Percutaneous posterolateral discectomy. *Clin Orthop Relat Res.* 1987;223:145. doi:10.1097/00003086-198710000-00016
15. Lee JJ, Lee MK, Kim JE, et al. Pain relief scale is more highly correlated with numerical rating scale than with visual analogue scale in chronic pain patients. *Pain Physician.* 2015;18(2):E195–200. doi:10.36076/ppj/2015.18.E195
16. Kelly AM. Does the clinically significant difference in visual analog scale pain scores vary with gender, age, or cause of pain? *Acad Emerg Med.* 1998;5(11):1086–1090. doi:10.1111/j.1553-2712.1998.tb02667.x
17. Zanolli G, Jönsson B, Strömquist B. SF-36 scores in degenerative lumbar spine disorders: analysis of prospective data from 451 patients. *Acta Orthop.* 2006;77(2):298–306. doi:10.1080/17453670610046064
18. Marcolina A, Vu K, Annaswamy TM. Lumbar spinal stenosis and potential management with prostaglandin E1 analogs. *Am J Phys Med Rehabil.* 2021;100(3):297–302. doi:10.1097/PHM.0000000000001620
19. Kapetanakis S, Gkantsinikoudis N, Chaniotakis C, Charitoudis G, Givissis P. Percutaneous transforaminal endoscopic discectomy for the treatment of lumbar disc herniation in obese patients: health-related quality of life assessment in a 2-year follow-up. *World Neurosurg.* 2018;113:e638–e649. doi:10.1016/j.wneu.2018.02.112
20. Kapetanakis S, Gkantsinikoudis N, Thomaidis T, Charitoudis G, Theodosiadis P. The role of percutaneous transforaminal endoscopic surgery in lateral recess stenosis in elderly patients. *Asian Spine J.* 2019;13(4):638–647. doi:10.31616/asj.2018.0179
21. Kapetanakis S, Gkantsinikoudis N, Gkadaris G, Charitoudis G. Treatment of adjacent segment disease with percutaneous transforaminal endoscopic discectomy: early experience and results. *J Orthop Surg (Hong Kong).* 2020;28(3):2309499020960560. doi:10.1177/2309499020960560
22. Lewandrowski KU, Ransom NA. Five-year clinical outcomes with endoscopic transforaminal outside-in foraminoplasty techniques for symptomatic degenerative conditions of the lumbar spine. *J Spine Surg.* 2020;6(Suppl 1):S54–S65. doi:10.21037/jss.2019.07.03
23. Xie P, Feng F, Chen Z, et al. Percutaneous transforaminal full endoscopic decompression for the treatment of lumbar spinal stenosis. *BMC Musculoskelet Disord.* 2020;21(1):546. doi:10.1186/s12891-020-03566-x
24. Yang J-S, Chu L, Chen C-M, et al. Foraminoplasty at the tip or base of the superior articular process for lateral recess stenosis in percutaneous endoscopic lumbar discectomy: a multicenter, retrospective, controlled study with 2-year follow-up. *Biomed Res Int.* 2018;2018:7692794. doi:10.1155/2018/7692794
25. Li H, Ou Y, Xie F, Liang W, Tian G, Li H. Linical efficacy of percutaneous endoscopic lumbar discectomy for the treatment of lumbar spinal stenosis in elderly patients: a retrospective study. *J Orthop Surg Res.* 2020;15(1):441. doi:10.1186/s13018-020-01968-0
26. Lin Y-P, Wang S-L, Hu W-X, et al. Percutaneous full-endoscopic lumbar foraminoplasty and decompression by using a visualization reamer for lumbar lateral recess and foraminal stenosis in elderly patients. *World Neurosurg.* 2020;136:e83–e89. doi:10.1016/j.wneu.2019.10.123

27. Li X, Liu T, Fan J, et al. Outcome of lumbar lateral recess stenosis with percutaneous endoscopic transforaminal decompression in patients 65 years of age or older and in younger patients. *Medicine (Baltimore)*. 2020;99(29):e21049. doi:10.1097/MD.00000000000021049

28. Gkardaris G, Hourmouzi D, Chaniotakis C, et al. CT assessment of the in vivo osseous lumbar intervertebral foramen: a radiologic study with clinical applications. *Maedica (Bucur)*. 2018;13(4):294–304.

Funding: The author(s) received no financial support for the research, authorship, and/or publication of this article.

Declaration of Conflicting Interests: The authors report no financial disclosures or conflicts of interest related to this work.

Institutional Review Board Approval: This study received approval from the Institutional

Review Board of Interbalkan European Medical Center, Thessaloniki, Greece.

Corresponding Author: Stylianos Kapetanakis, Spine Department and Deformities, Interbalkan European Medical Center, Asclepiou 10 Str., 55535, Thessaloniki, Greece, Athens Medical Center, Democritus University of Thrace, Interbalkan European Medical Center, Asclepiou 10 Str., 55535, Thessaloniki, Greece; stkapetanakis@yahoo.gr

Published 15 March 2022

This manuscript is generously published free of charge by ISASS, the International Society for the Advancement of Spine Surgery. Copyright © 2022 ISASS. To see more or order reprints or permissions, see <http://ijssurgery.com>.