

Health-Related Quality of Life Assessment in Idiopathic Early-Onset Scoliosis Treated by Serial Mehta Casting

Ahmed Sleem

Int J Spine Surg 2022, 16 (3) 554-558

doi: <https://doi.org/10.14444/8253>

<https://www.ijssurgery.com/content/16/3/554>

This information is current as of May 17, 2025.

Email Alerts Receive free email-alerts when new articles cite this article. Sign up at:
<http://ijssurgery.com/alerts>

Health-Related Quality of Life Assessment in Idiopathic Early-Onset Scoliosis Treated by Serial Mehta Casting

AHMED SLEEM, MD¹

¹Orthopedic Department, Sohag University Hospital, Sohag, Egypt

ABSTRACT

Background: This was a retrospective clinical study of patients with idiopathic early-onset scoliosis (IEOS) treated by serial Mehta derotational cast in a single facility.

Methods: A standardized casting protocol was used for patients aged ≤ 5 years with IEOS (curve $\geq 20^\circ$). Patients' demographics, clinical and radiological outcomes, and major curve Cobb angle were recorded, and health-related quality of life (HRQoL) using the 24-item early-onset scoliosis questionnaire (EOSQ-24) was assessed.

Results: A total of 15 patients with IEOS were managed by serial Mehta cast between October 2014 and September 2018 with a mean follow-up period of 42.33 ± 6.37 (range 32–55) months. The mean precast curve was $56.8^\circ \pm 12.01^\circ$, and the mean final postcast curve was $26.4^\circ \pm 19.12^\circ$ ($P = 0.0008$). The EOSQ-24 was inversely proportional to the magnitude of the residual curve. There were 2 cases with superficial skin irritation and a single case with repeated vomiting after casting.

Conclusion: IEOS can be managed effectively by serial Mehta cast, which is proved not only by the clinical and radiological outcome but also by the improvement of the quality of life of the patients and their families as measured by the EOSQ-24.

Level of Evidence: 3.

Other and Special Categories

Keywords: quality of life, early-onset scoliosis, mehta cast

INTRODUCTION

Early-onset scoliosis has a significant adverse impact on patient's quality of life due to its progressive nature and severe complications, such as cardiopulmonary deterioration and poor cosmesis.^{1,2} Additionally, the treatment of early-onset scoliosis remains a challenging area of pediatric orthopedics. The risk of repeated surgeries, spinal autofusion, and the lack of bone stock sufficient for good anchorage, especially in the very young age group (< 5 years old), encourage physicians to lean toward treatment modalities that can correct or even control curve progression until the patient is of appropriate age and size for surgery.^{3,4}

Several studies have proved that the Mehta derotational cast had good results when started early (first 2 years of life).^{5–7} However, to the best of our knowledge, all of these studies included a heterogeneous group of different etiologies (idiopathic, neuromuscular, syndromic, or congenital) of early-onset scoliosis; moreover, the assessment of the results depends on radiological parameters and complication rate without taking the health-related quality of life (HRQoL) of the patients and their families into consideration.

The purpose of the present work is to study a homogeneous group of patients with idiopathic early-onset scoliosis (IEOS) treated by a standardized treatment protocol using serial Mehta derotational cast and to evaluate HRQoL using a validated version of the 24-item early-onset scoliosis questionnaire (EOSQ-24).¹

METHODS

After obtaining Institutional Review Board approval, all patients with IEOS undergoing serial Mehta derotational cast were enrolled in this retrospective study. All participants were informed about the purpose of the study, and a consent was obtained. Our indication for serial casting is a major curve Cobb angle $\geq 20^\circ$ in a patient aged ≤ 5 years. Pediatric consultation and pre-casting magnetic resonance imaging were done for every patient to exclude nonidiopathic etiology.

Casting Technique

With the help of a custom-designed table, the cast is applied under general anesthesia and endotracheal intubation with an oropharyngeal Guedel airway to prevent tongue and tube biting. Halter traction is placed around the occiput and under the chin. Long straps are placed

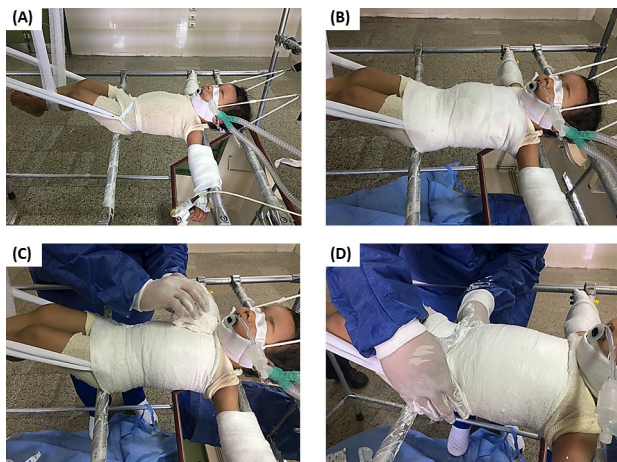

Figure 1. Casting technique.

above the iliac crests on both sides over the stockinet. Gentle traction were applied from the halter and the pelvic straps, with more traction applied to the pelvic strap of the concave side of the curve, and both hips were slightly flexed (Figure 1A).

Enough padding with particular attention to the bony prominences was applied (Figure 1B). Several layers of well-molded plaster of Paris are applied especially at the level of both iliac crests making a stable pelvic foundation of the cast (Figure 1C&D). The correction is achieved by upward and medialward pushing by the palm of one hand on the apex of the curve on the convex side and downward pressure by the palm of the other hand on the concave side creating curve derotation. Counterrotation should be done during this maneuver by 2 trained assistants; one assistant stabilizes the shoulder at the side of convexity, and the other stabilizes the pelvis (Figure 2A).

Once the plaster of Paris is set, a thin layer of fiberglass is applied for additional strength (Figure 2B).

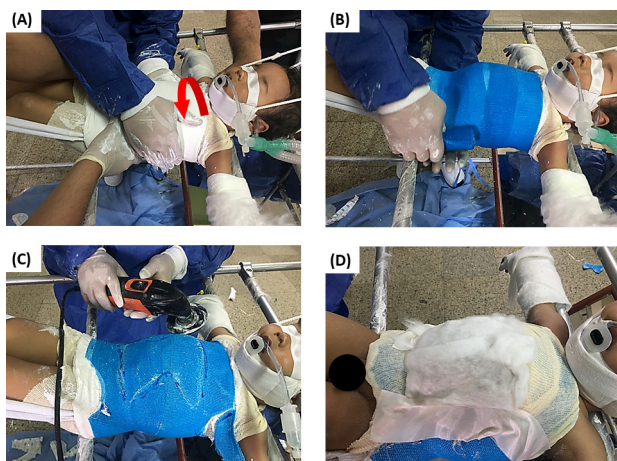


Figure 2. Casting technique, cont.

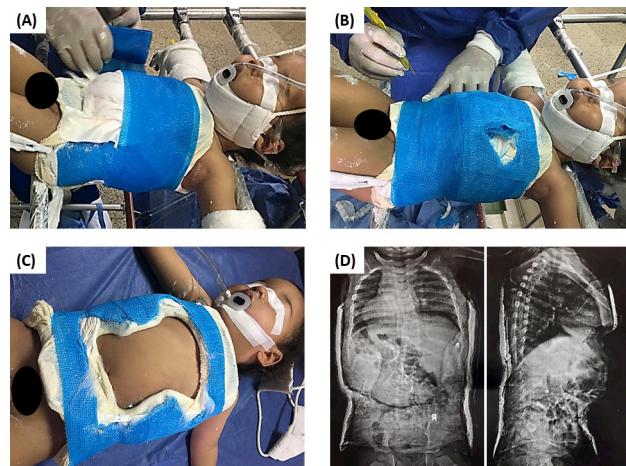


Figure 3. Casting technique, cont.

A wide anterior window is cut to allow for chest and abdominal expansion. The cast is also trimmed to allow free movement at both axillae and hip joints (Figure 2C).

In the first early few cases, we tended to cover the free edges of the cast by reflecting the stockinet and fixing it to the plaster edges, but soon we found this impractical due to early stripping of the adhesive tapes, so in the next cases, after window cutting the stockinet is reflected on the edges and fixed by adhesive tapes and covered by additional layer of fiberglass after covering the skin by a thin layer of padding to avoid skin irritation (Figures 2D and 3A). The window is recut on the edge of the old window, and so we had a smooth cast edges (Figure 3B&C). Patients were generally discharged the same day after obtaining postcast x-ray images (Figure 3D) and clinical assessment of respiration and bowel movement.

Casts were changed every 2 months for patients ≤ 2 years old, every 3 months for patients ≤ 3 years, and every 4 months for patients ≥ 4 years until 1 of 2 ends were reached: either the curve was corrected ($\leq 10^\circ$) followed by brace or the curve was not corrected or even progressed, in which case casting was continued as a tactic to delay surgery till the age of 6 years.

We analyzed the patients' sex, age at initial cast application, major curve magnitude precast and at last follow-up, and any complications. The percentage of curve correction was calculated as follows:

$$\frac{(\text{precast Cobb angle} - \text{final Cobb angle})}{\text{precast Cobb angle}} \%$$

The EOSQ-24¹ was used to assess the quality of life of our patients and their families. The questionnaire consisted of 24 questions in 11 domains. Patients and their parents were asked to complete the questionnaire at the final follow-up visit. There were 5 responses, which ranged between 1 and 5 (poor to excellent) for

each question. The average value of the responses for the questions in each domain was utilized to calculate each domain score as follows:

$$(\text{average of responses} - 1) / 4 \times 100$$

The score ranged from 0 (poor) to 100 (excellent). The EOSQ-24 total score was the average of the 11 domains score.

Statistical Analysis

Data were analyzed using STATA version 14.2 (Stata Statistical Software: Release 14.2 College Station, TX: StataCorp LP). Quantitative data were represented as mean \pm SD and median (range). Wilcoxon matched paired signed ranked test was used to compare precast Cobb angle and final Cobb angle. Correlation analysis was done using Spearman correlation test. $P < 0.05$ was considered significant.

RESULTS

A total of 15 patients (10 women and 5 men) were treated by serial Mehta cast for IEOS at a single institution by a single surgeon between October 2014 and September 2018. The mean age at initial casting was 23.8 ± 9.88 (range 11–39) months, and the mean age at final casting was 66.13 ± 7.03 (range 53–75) months with a mean follow-up period of 42.33 ± 6.37 (range 32–55) months.

The mean precast Cobb angle was $56.8^\circ \pm 12.01^\circ$ (range 40–73) which improved to $26.4^\circ \pm 19.12^\circ$ (range 8–75) following final cast removal ($P = 0.0008$), representing a mean curve correction of $54.68\% \pm 28.37\%$ (range –20.97% to 83.82%) (Table 1) (Figure 4).

EOSQ-24 correlation with the final Cobb angle revealed that the correlation of the financial impact was insignificant ($P = 0.19$) and that there was a strong significant negative correlation in daily living, satisfaction, pulmonary function, general health, pain/discomfort, and emotion domains. There was a moderate correlation in the other domains (Table 2).

Table 1. Demographic and radiological data.

Demographic and Radiological Data	Mean \pm SD	Median (Range)
Age at initial cast, mo	23.8 ± 9.88	24 (11–39)
Age at final cast, mo	66.13 ± 7.03	67 (53–75)
Follow-up period, mo	42.33 ± 6.37	42 (32–55)
Precast Cobb angle, $^\circ$	56.8 ± 12.01^a	61 (40–73)
Final Cobb angle, $^\circ$	26.4 ± 19.12^a	22 (8–75)
% of correction	54.68 ± 28.37	61.40 (–20.97 to 83.82)

^aThe difference between the precast Cobb and final Cobb angle was statistically significant ($P = 0.0008$).

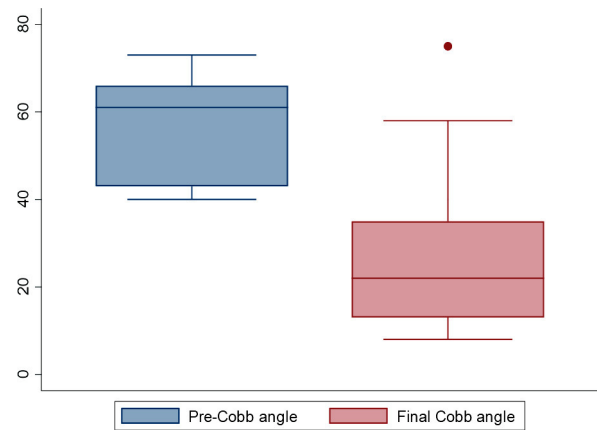


Figure 4. Comparison between the precast Cobb angle and final Cobb angle.

Moreover, the mean of the EOSQ-24 total score of all patients (72.38 ± 18.43 , range 34.32–95) had a strong negative correlation with the final Cobb angle (-0.79 , $P = 0.0005$) (Figure 5).

There were 2 cases with superficial skin sores, which resolved with skin care and cast holiday of less than 2 weeks. One case had postcast repeated vomiting, which improved after overnight observation.

DISCUSSION

Considering that the length of the spine increases 50% in the first 5 years of age,⁸ neglected early-onset scoliosis can lead to poor thoracic development with subsequent thoracic insufficiency and early mortality.⁹ Therefore, proper treatment objectives should include correction of spinal deformity without compromising normal spinal and pulmonary growth.

Repeated surgeries have devastating psychosocial consequences on patients and their families.^{10,11} As a result, enthusiasm for serial casting is increasing, as it has the advantage of leaving the spine “virgin” and avoiding spinal fusion in about two-thirds of cases.¹² In our series, the final Cobb angle reflected a correction of more than 50% in all but 1 patient, who was a 39-month-old girl with a precast curve of 62° , which reached to 75° at 73 months. This result can be explained by the delayed treatment and the large initial curve.

It is of paramount importance that the outcome assessment include not only the assessment of deformity correction and complication rate but also assessment of quality of life of patients and their families. The EOSQ-24 was introduced by Corona et al to measure HRQoL of patients with early-onset scoliosis and the burden on their families,² and it has been validated in multiple languages.^{1,13–16} In our series, the improvement in the quality of life of patients and their families

Table 2. EOSQ-24 score of each domain and correlation with the final Cobb angle arranged in ascending manner according to the strength of correlation.

EOSQ-24 Domain	EOSQ-24 Score			
	Mean \pm SD	Median (Range)	Correlation Coefficient With Final Cobb Angle	P Value
Financial impact	75.00 \pm 23.15	75 (25–100)	-0.36	0.19
Fatigue /energy level	74.17 \pm 19.17	75 (37.5–100)	-0.57	0.03
Transfer	75.00 \pm 18.90	75 (50–100)	-0.58	0.02
Parental impact	74.00 \pm 20.55	75 (35–95)	-0.65	0.008
Physical function	75.56 \pm 19.79	75 (25–100)	-0.67	0.006
Daily living	75.00 \pm 20.59	75 (37.5–100)	-0.70	0.004
Satisfaction	60.83 \pm 24.03	75 (12.5–87.5)	-0.76	0.0009
Pulmonary function	75.83 \pm 23.84	75 (37.5–100)	-0.78	0.0006
General health	65.0 \pm 19.02	62.5 (37.5–87.5)	-0.80	0.0003
Pain/discomfort	73.33 \pm 17.59	75 (50–100)	-0.82	0.0002
Emotion	72.5 \pm 29.20	75 (12.5–100)	-0.92	< 0.0001

Abbreviation: EOSQ-24, 24-item early-onset scoliosis questionnaire.

was significantly correlated with the improvement of curve magnitude in all aspects except for the financial impact. This finding can be explained by the fact that the same maneuver was done for all patients and that the frequency of cast changing was related to the patient's age, not the curve magnitude, so the final Cobb angle had insignificant effect on the financial impact.

The limitation of this study is the lack of precast EOSQ-24 results to be compared with the postcast result, which is attributed to the late release of the translated version of the EOSQ-24.¹ Additionally, the study was conducted retrospectively.

CONCLUSION

With particular attention to the application technique, serial Mehta cast is an effective tool to manage IEOS with negligible complications, and this is obvious not only from the improvement of the final curve magnitude, but also from the proportional significant improvement of the quality of life of the patients and their families as measured by EOSQ-24. Additional

studies that include baseline HRQoL values should be conducted in the future.

ACKNOWLEDGMENTS

The author expresses his gratitude to Dr. Moataz H. Ata for his generous assistance in manufacturing our casting traction table.

REFERENCES

- Hanbali Y, Perry T, Hanif A, et al. Reliability and validity of the Arabic version of the early onset scoliosis 24 items questionnaire (EOSQ-24). *SICOT J.* 2019;5:7. doi:10.1051/sicotj/2019001
- Corona J, Matsumoto H, Roye DP, Vitale MG. Measuring quality of life in children with early onset scoliosis: development and initial validation of the early onset scoliosis questionnaire. *J Pediatr Orthop.* 2011;31(2):180–185. doi:10.1097/BPO.0b013e3182093f9f
- Vitale MG, Matsumoto H, Roye DP, et al. Health-related quality of life in children with thoracic insufficiency syndrome. *J Pediatr Orthop.* 2008;28(2):239–243. doi:10.1097/BPO.0b013e31816521bb
- Waldron SR, Poe-Kochert C, Son-Hing JP, Thompson GH. Early onset scoliosis: the value of serial risser casts. *J Pediatr Orthop.* 2013;33(8):775–780. doi:10.1097/BPO.0000000000000072
- Mehta MH. Growth as a corrective force in the early treatment of progressive infantile scoliosis. *J Bone Joint Surg Br.* 2005;87(9):1237–1247. doi:10.1302/0301-620X.87B9.16124
- Sanders JO, D'Astous J, Fitzgerald M, Khoury JG, Kishan S, Sturm PF. Derotational casting for progressive infantile scoliosis. *J Pediatr Orthop.* 2009;29(6):581–587. doi:10.1097/BPO.0b013e3181b2f8df
- Smith JR, Samdani AF, Pahys J, et al. The role of bracing, casting, and vertical expandable prosthetic titanium rib for the treatment of infantile idiopathic scoliosis: a single-institution experience with 31 consecutive patients. Clinical article. *J Neurosurg Spine.* 2009;11(1):3–8. doi:10.3171/2009.1.SPINE08253
- Dimeglio A, Canavese F. The growing spine: how spinal deformities influence normal spine and thoracic cage growth: official publication of the european spine society, the european spinal deformity society, and the european section of the cervical spine research society. *Eur Spine J.* 2012;21(1):64–70. doi:10.1007/s00586-011-1983-3

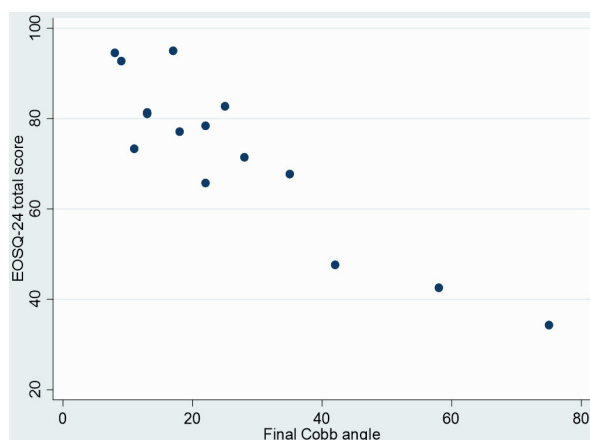


Figure 5. Scatter diagram showing correlation between 24-item early-onset scoliosis questionnaire (EOSQ-24) total score and the final Cobb angle.

9. Goldberg CJ, Gillic I, Connaughton O, et al. Respiratory function and cosmesis at maturity in infantile-onset scoliosis. *Spine (Phila Pa 1976)*. 2003;28(20):2397–2406. doi:10.1097/01.BRS.0000085367.24266.CA
10. Matsumoto H, Williams BA, Corona J, et al. Psychosocial effects of repetitive surgeries in children with early-onset scoliosis: are we putting them at risk? *J Pediatr Orthop*. 2014;34(2):172–178. doi:10.1097/BPO.0b013e3182a11d73
11. Sankar WN, Acevedo DC, Skaggs DL. Comparison of complications among growing spinal implants. *Spine (Phila Pa 1976)*. 2010;35(23):2091–2096. doi:10.1097/BRS.0b013e3181c6edd7
12. Morin C, Kulkarni S. ED plaster-of-Paris jacket for infantile scoliosis: official publication of the European Spine Society, the European Spinal Deformity Society, and the European Section of the Cervical Spine Research Society. *Eur Spine J*. 2014;23(4):412–418. doi:10.1007/s00586-014-3336-5
13. Matsumoto H, Williams B, Park HY, et al. The final 24-item early onset scoliosis questionnaires (EOSQ-24): validity, reliability and responsiveness. *J Pediatr Orthop*. 2018;38(3):144–151. doi:10.1097/BPO.0000000000000799
14. Demirkiran HG, Kinikli GI, Olgun ZD, et al. Reliability and validity of the adapted turkish version of the early-onset scoliosis-24-item questionnaire (EOSQ-24). *J Pediatr Orthop*. 2015;35(8):804–809. doi:10.1097/BPO.0000000000000378
15. Cheung JPY, Cheung PWH, Wong CKH, et al. Psychometric validation of the traditional chinese version of the early onset scoliosis-24 item questionnaire (EOSQ-24). *Spine (Phila Pa 1976)*. 2016;41(24):1460–1469. doi:10.1097/BRS.0000000000001673
16. Del Mar Pozo-Balado M, Matsumoto H, Vitale MG, Praena-Fernández JM, Farrington DM. Reliability and validity of the adapted spanish version of the early-onset scoliosis-24 questionnaire. *Spine (Phila Pa 1976)*. 2016;41(10):625–631. doi:10.1097/BRS.0000000000001322

Funding: The author received no financial support for the research, authorship, and/or publication of this article.

Declaration of Conflicting Interests: The author(s) report no conflicts of interest or financial disclosures with respect to the research, authorship, and/or publication of this article.

Ethics Approval: IRB approval was obtained

Corresponding Author: Ahmed Sleem, Orthopedic Department, Sohag University Hospital, Sohag, 82524 Sohag, Egypt; ahmed_sleem@med.sohag.edu.eg

Published 27 April 2022

This manuscript is generously published free of charge by ISASS, the International Society for the Advancement of Spine Surgery. Copyright © 2022 ISASS. To see more or order reprints or permissions, see <http://ijssurgery.com>.