

Freehand Regional Techniques for Subaxial Cervical Pedicle Screw Placement

Kepeng Li, Jun Miao, Ye Han and Jie Lan

Int J Spine Surg 2022, 16 (5) 863-867

doi: <https://doi.org/10.14444/8339>

<https://www.ijssurgery.com/content/16/5/863>

This information is current as of May 17, 2025.

Email Alerts Receive free email-alerts when new articles cite this article. Sign up at:
<http://ijssurgery.com/alerts>

Freehand Regional Techniques for Subaxial Cervical Pedicle Screw Placement

KEPENG LI, PhD¹; JUN MIAO, PhD²; YE HAN, PhD³; AND JIE LAN, PhD²

¹Second Central Hospital of Baoding, Hebei Province, China; ²Tianjin Hospital, Tianjin, China; ³The Affiliated Hospital of Hebei University, Baoding, China

ABSTRACT

Background: Although various subaxial cervical pedicle screw implantation techniques have been proposed, clinical operators have been unable to exactly determine the entry points and trajectory. The objective of this article is to propose freehand regional techniques (FRT) for subaxial cervical pedicle screw placements and to investigate the clinical effectiveness of FRT.

Methods: A total of 80 consecutive patients who underwent open subaxial cervical pedicle screw fixation using FRT from January 2015 to December 2020 were retrospectively reviewed, and preoperative cervical computed tomography (CT) images were used to observe the entry point and screw trajectory. The horizontal and vertical lines at the center of the cervical lateral mass was marked, and the entry point was chosen at the outer upper quadrant of the lateral mass. Both sagittal and axial trajectories were determined by CT images, generally perpendicular to the cervical laminae. Screw implantation accuracy was assessed using postoperative CT.

Results: After virtually inserting pedicle screws by FRT on preoperative cervical CT images, all of the entry points were located in the outer upper quadrant of the lateral mass and the trajectory perpendicular to the cervical laminae was just parallel to the pedicle's axis. A total of 694 pedicle screws were placed by FRT clinically, with a 96% accuracy rate.

Conclusions: Pedicle screw implantation by FRT for subaxial cervical spine can be performed with acceptable safety and accuracy.

Cervical Spine

Keywords: freehand regional techniques, subaxial cervical, pedicle screws

INTRODUCTION

With the development of modern cervical spinal surgery technology, pedicle screw fixation has become the preferred choice to treat cervical trauma, deformity, tumor, and degeneration because of its stabilizing capability of all 3 columns.¹ Biomechanical research has shown that the 3-dimensional fixation effect of the pedicle screw is better than the lateral mass screw.² However, pedicle screw implantation remains technically complicated to implant in the subcervical area because of its smaller diameter and circumambient neurovascular structures. Misplacement of cervical pedicle screws can lead to several kinds of complications, including screw loosening, neurological damage, and vertebral artery injuries.^{3–5}

Successful freehand implantation of subaxial cervical pedicle screws requires adequate experience of the surgeon, who needs a long learning curve.⁶ As the subaxial cervical freehand pedicle screw implantation technique relies solely on anatomy, local anatomical marks are crucially important to select an appropriate entry point. Various subaxial cervical pedicle screw implantation techniques have been proposed to improve screw placement accuracy.^{7,8}

However, these methods are technically complicated and require surgeons to remember a large amount of data. The status increases the operative difficulty, prolongs the operative time, and extends the learning curve accordingly. A reliable method for subcervical pedicle screw implantation is prerequisite for reducing operative difficulty, reducing the operative time, and shortening the learning curve.

Although different entry points at the subcervical spine have been proposed, they are all located in a limited area. This area is easier to identify than the accurate entry points of traditional techniques as well as not influenced by individual differences. The purpose of this study was (1) to employ freehand regional techniques (FRT) for successful subaxial cervical freehand pedicle screw implantation and (2) to clinically determine the accuracy of FRT.

METHODS

Introduction of FRT

The anatomic landmark of lateral mass was determined, including the inner and outer edges and the superior and inferior articulating processes. The horizontal and vertical lines at the center of the lateral

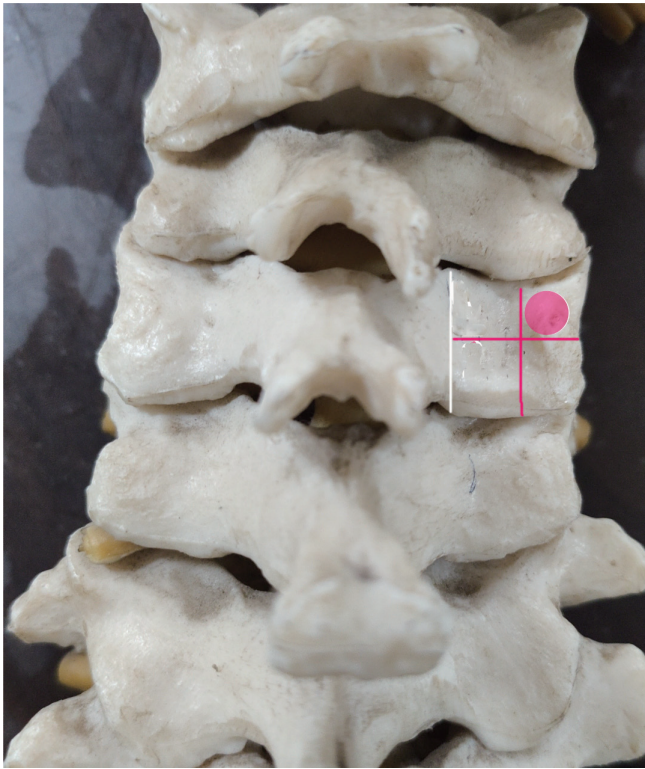

Figure 1. Diagram of freehand regional techniques (FRT). The entry point of FRT was located in outer upper quadrant of lateral mass.

mass of the subaxial cervical spine were labeled, dividing the lateral mass into 4 quadrants. The entry point was located in the outer upper quadrant of the lateral mass. The surface of cervical laminae should be exposed to determinate screws trajectories. The exposed area should extend from the medial edge of lateral mass to the spinous process. Screw trajectory should be perpendicular to the laminae (Figure 1). (Figure 2)

Clinical Assessment

Eighty patients who underwent subaxial cervical pedicle screw implantation from January 2015 to December 2020 were retrospectively analyzed. In these 80 patients (61 men and 19 women), the etiologic diagnosis included: trauma (12 cases), tumor (13 cases), deformity (15 cases), spinal infection (4 cases), and spinal degenerative diseases (36 cases). The distribution of the cervical level was from C3 to C7, and the age ranged from 20 to 71 years.

Inclusion criteria were as follows: (1) lower cervical tumor, trauma, or congenital deformity; (2) completed perioperative cervical x-ray imaging, computed tomography (CT), and magnetic resonance imaging; and (3) patients with high compliance and complete follow-up data.

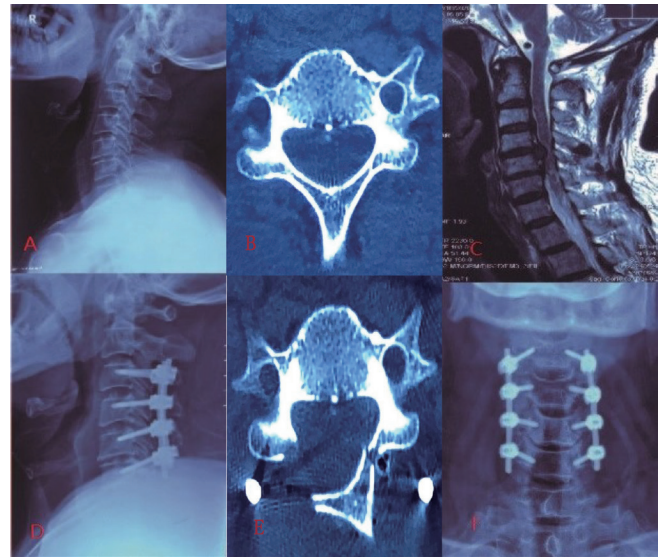


Figure 2. Typical cases. (A-C) Preoperative imaging shows cervical spondylotic myelopathy. (D-F) postoperative imaging shows good pedicle screw position.

Exclusion criteria were as follows: (1) severe osteoporosis; (2) cervical infection; (3) vertebral pedicle damage or absence caused by trauma or tumor invasion; (4) small vertebral pedicle caused by congenital malformations or local adjacent neuro-vessel variation.

Assessment on Preoperative CT Images

Cervical CT images from 80 cases were obtained. The images were reconstructed using Mimics software (Mimics Research 20.0). Reconstructed subaxis cervical vertebrae were used to test the entry point and sagittal and axial trajectories described above. According to the vertebral anatomic structure, the surfaces of the laminae of the isthmus and lateral mass were determined with Mimics software. The planes perpendicular to the subaxis cervical laminae were established to virtually determine the pedicle screw trajectory. Next, the established virtual trajectory was 3-dimensionally observed to assess the accuracy of FRT.

Surgical Technique

All cases were performed by the author (J.M.). All pedicle screws were inserted using FRT. The prone position was taken under general anesthesia with tracheal intubation. The head was positioned neutrally with moderate cervical flexion. The surgical segments were confirmed with fluoroscopy if necessary. The middle incision was taken, and the length of the incision was determined by fixation segments. The

lower edge of the superior articular process, the upper edge of the inferior articular process, and the medial and lateral edges of the lateral mass were exposed.

After exposure, pedicle screws were implanted with FRT, and the horizontal and vertical lines were drawn at the center of lateral mass. A straight awl was used to disrupt the cortical bone at the outer upper quadrant. A straight, blunt-ended gearshift was employed to cannulate the pedicle to the desired depth based on the sagittal and axial trajectories described above. In this process, the resistance feeling changes were carefully felt and the direction was adjusted if resistance increases substantially. A ball-ended feeler was used to contact breaches. After the typical tapping and probing was repeated, an appropriate size screw was placed. Intraoperative fluoroscopy was used for initial localization and then again for a final anteroposterior and lateral radiograph. After the surgery, standard x-ray imaging and CT were taken to assess safety and accuracy for all 80 patients.

Postoperative Assessment of Pedicle Screw Safety and Accuracy

Placements of pedicle screws were assessed using CT data and outcome-based classifications: Type 0 (good)—screw within the pedicle medullary canal; Type 1 (acceptable)—minimal penetration of the pedicle wall by the screw (<2 mm of medial or lateral cortical perforation or anterior cortex perforation); Type 2 (unacceptable)—less than half of the diameter of the screw was outside the pedicle wall (2–4 mm of perforation); and Type 3 (grievous)—more than half of the diameter of the screw was outside the pedicle wall (>4 mm of perforation) (spinal cord injury or screw abutting the aorta or vertebral artery). Types 2 and 3 were classified as grades of perforation or misplacements.

Statistical Methods

Statistical analyses were performed using SPSS 25.0 software (IBM SPSS Statistics 25) to evaluate the accuracy of screw placement.

RESULTS

Trajectory Observation in Preoperative CT Images

In the pedicle's axial view, the extension line of the cervical pedicle axis was located at outer upper quadrant of the lateral mass and was approximately perpendicular to the ipsilateral laminae.

Clinical Accuracy

Among the 80 postoperative CT patients, which included trauma (12), tumor (13), deformity (15), spinal infection (4), and spinal degenerative disease (36) cases, a total of 694 pedicle screws were placed.

The operation time was 2.4–4.1 hours (average 3.2 hours); the intraoperative operative blood loss was 120–1300 mL (average 325 mL); there were no vascular or nerve injuries during the operation, and patients with neurological symptoms improved to different degrees after surgery. The postoperative hospital stay time was 5–14 days (average 7.4 days).

It was found that 4% of the screws had penetrated the pedicle wall (Types 2 and 3). There were no screws with any neurological, vascular, or visceral complications in the 80 patients.

DISCUSSION

The subaxial cervical pedicle screw placement technology was proposed by scholars in 1996, which was recognized by spine surgeons for its obvious superiority to other internal fixation systems.⁹

By measuring specimens cervical spine, it was concluded that the cervical pedicle has little distance from the vertebral artery.¹⁰ Therefore, accurate cervical pedicle screw placement is particularly important. The key to accurate implantation of cervical pedicle screw is to determine the entry point and sagittal and axial trajectories. Scholars have proposed various methods for determining the entry point and sagittal and axial trajectories.

According to the Abumi method,¹¹ the entry point was located laterally to the midpoint of the lateral mass, 1–2 mm from the superior articular process. The cortex bone was ground with a drill to reveal the entry point. Next, the path was explored with a probe before inserting the screw. As a classic freehand cervical pedicle screw placement technology, this method is a direct exposure method, and the penetration rate is 6.7%.⁹

To reduce the amount of removed cortex and reduce the risk of vertebral artery damage by screw perforation, Lee et al proposed the medial funnel technique,¹² and the entry point was selected on the inside of the lateral mass. Basing on the cervical pedicle anatomy, the subcervical pedicle screw entry point was recommended at 2 mm medially to the outer edge depression of lateral mass with an average inclination of 45° at C3–5 and 38° at C6. The entry point at C7 is 2 mm superior-laterally to the middle point of the lateral mass with an inclination at 28°, parallel to the upper

end plate. The pedicle penetration rate of this technique is 5.2%.

According to the pedicle exposure technique proposed by Mingsheng Tan,¹³ the data of width and length of cervical pedicle and the angle between cervical pedicle axis and sagittal surface should be measured perioperatively. Rongeur or power drill was used to remove the cortical bone at the entry point of lateral mass. Then cancellous bone was scraped to expose the trumpet-shaped portal of the pedicle. The cancellous bone in the pedicle was also scraped to determine the direction and the correct angle of pedicle screw.

Jeanneret et al proposed another planting method¹⁴ in which the tilt angle was determined preoperatively according to the CT measurement results. A small part of the lamina was removed to reveal the inner and upper edge of the pedicle. The entry point was located at the intersection between 3 mm from the superior articular process and the perpendicular bisector of the lateral mass, with an inclination of 45°. At the sagittal plane, the screw should enter the upper one-third of the vertebra. They found that the probability of screw penetration is greater at the outer wall than at the inner wall. Thus, Jeanneret et al concluded that large inclination angles offer greater safety than smaller ones and suggested that an inclination angle of 45° is safer.

Using these methods, the cortical bone of the lateral mass is basically destroyed to implant the pedicle screw. Although these technologies can accurately explore the pedicle, the lost bone loss between the pedicle and the cortex of the lateral mass reduces the holding strength of the pedicle screw, especially in patients with osteoporosis. Some of the above methods need complicated data, whereas some rely on more advanced equipment to provide high quality imaging data.

We marked the specimen according to the entry points described in the literature and found that the entry points identified by various methods were always located in a certain region. Through clinical practice, we propose use of FRT, where the entry point is determined by the lower edge of the superior articular process and the upper edge of the inferior articular process. The medial and lateral edge of the lateral mass is exposed so that 2 vertical and 2 horizontal lines form a rectangle, and a right angle coordinate system is established at the rectangular midpoint so that the entry point is located in the outer upper quadrant of the coordinate system.

The entry points obtained from FRT take into account individual differences. For example, for the larger vertebrae, the corresponding entry area will become larger, and for the smaller vertebrae, the entry area will also

narrow. The FRT has no fixed data range and fixed entry point, and the entry area changes with anatomic landmarks. The operator does not need to remember extensive data but only needs to find anatomic landmarks during the operation.

The inclination mentioned in the literature was focused on 35°–55° and 0° on the sagittal plane. However, in the actual operation, due to the body position, exposure range, individual variation, and other reasons, the angle was not accurately determined and ultimately depends on the experience of the operator. By measuring the inclination of pedicle screws based on the CT axis image of each cervical vertebra, we found that inclination was around 45° and sagittal angle was around 0°. In the process of screw placement, the operator needs to experience the change of resistance feeling; if the resistance becomes hard, the direction should be adjusted appropriately.

As technology advances, computer navigation-aided planting technology has become more common in clinical practice. Takahashi et al reported that the misimplanting rate of screws was 8%, and Scheufler reported 7%.^{15,16} However, some scholars still have a high penetrating rate with the help of computer navigation, 12% reported by Ludwig and 20% by Uehara.^{17,18} The high penetrating rate should be attributed to individual differences and the complex operation of computer navigation assistance systems. It can be seen that, with the assistance of computer navigation, the impact of individual differences can still not be excluded. The technology still has defects such as complex operation, high price, machine failure, navigation drift, and so on. Therefore, freehand screw planting technology is particularly important.

The penetration rate of FRT was 4% in the present study. The FRT has significant advantages over the screw planting technology reported in the literature. Routine CT is required to understand the form of the vertebral pedicle; because female patients are typically smaller than male patients, it is necessary to examine how they feel during the operation. When vertebral artery deformity is discovered, pedicle screws should be abandoned.

The present study has some limitations. First, this was a retrospective study with a relatively small sample size. Second, no corresponding cadaveric measurements were performed.

CONCLUSION

It is feasible to employ FRT for subaxial cervical pedicle screw placements. The FRT fully takes into

account individual differences, improving the success rate of screw placement as well as simplifying the operative process. While other techniques are effective and widely employed, this particular method may be easier to learn and adopt.

REFERENCES

- Jung YG, Lee S, Jeong SK, Kim M, Park JH. Subaxial pedicle screw in traumatic spinal surgery. *Korean J Neurotrauma*. 2020;16(1):18–27. doi:10.13004/kjnt.2020.16.e13
- Duan Y, Wang HH, Jin AM, et al. Finite element analysis of posterior cervical fixation. *Orthop Traumatol Surg Res*. 2015;101(1):23–29. doi:10.1016/j.otsr.2014.11.007
- Shi H, Zhu L, Ma J, Zhu Y-C, Wu X-T. The accuracy of a novel pedicle screw insertion technique assisted by a special angular scale in the subaxial cervical spine using lateral mass as a reference marker. *J Orthop Surg Res*. 2020;15(1):551. doi:10.1186/s13018-020-02054-1
- Moser M, Farshad M, Farshad-Amacker NA, Betz M, Spirig JM. Accuracy of patient-specific template-guided versus freehand cervical pedicle screw placement from C2 to C7: a randomized cadaveric study. *World Neurosurg*. 2019;126:e803–e813. doi:10.1016/j.wneu.2019.02.152
- Nakashima H, Yukawa Y, Imagama S, et al. Complications of cervical pedicle screw fixation for nontraumatic lesions: a multicenter study of 84 patients. *J Neurosurg Spine*. 2012;16(3):238–247. doi:10.3171/2011.11.SPINE11102
- Heo Y, Lee SB, Lee BJ, et al. The learning curve of subaxial cervical pedicle screw placement: how can we avoid neurovascular complications in the initial period? *Oper Neurosurg (Hagerstown)*. 2019;17(6):603–607. doi:10.1093/ons/ozp070
- Liu B, Liu X, Shen X, Wang G, Chen Y. The “slide technique”—a novel free-hand method of subaxial cervical pedicle screw placement. *BMC Musculoskelet Disord*. 2020;21(1):399. doi:10.1186/s12891-020-03420-0
- Zhang ZF. Freehand pedicle screw placement using a universal entry point and sagittal and axial trajectory for all subaxial cervical, thoracic and lumbosacral spines. *Orthop Surg*. 2020;12(1):141–152. doi:10.1111/os.12599
- Abumi K, Kaneda K. Pedicle screw fixation for nontraumatic lesions of the cervical spine. *Spine (Phila Pa 1976)*. 1997;22(16):1853–1863. doi:10.1097/00007632-199708150-00010
- Clifton W, Vlasak A, Damon A, Dove C, Pichelmann M. Freehand C2 pedicle screw placement: surgical anatomy and operative technique. *World Neurosurg*. 2019;132:113. doi:10.1016/j.wneu.2019.08.198
- Abumi K. Cervical spondylotic myelopathy: posterior decompression and pedicle screw fixation. *Eur Spine J*. 2015;24 Suppl 2:186–196. doi:10.1007/s00586-015-3838-9
- Lee JH, Choi BK, Han IH, Choi WG, Nam KH, Kim HS. Cervical pedicle screw placement using medial funnel technique. *Korean J Spine*. 2017;14(3):84–88. doi:10.14245/kjs.2017.14.3.84
- Tan M, Dong L, Wang W, et al. Clinical application of the “pedicle exposure technique” for atlantoaxial instability patients with a narrow c1 posterior arch. *J Spinal Disord Tech*. 2015;28(1):25–30. doi:10.1097/BSD.0000000000000078
- Jeanneret B, Gebhard JS, Magerl F. Transpedicular screw fixation of articular mass fracture-separation: results of an anatomical study and operative technique. *J Spinal Disord*. 1994;7(3):222–229. doi:10.1097/00002517-199407030-00004
- Uehara M, Takahashi J, Mukaiyama K, et al. Mid-term results of computer-assisted cervical pedicle screw fixation. *Asian Spine J*. 2014;8(6):759–767. doi:10.4184/asj.2014.8.6.759
- Scheufler KM, Franke J, Eckardt A, Dohmen H. Accuracy of image-guided pedicle screw placement using intraoperative computed tomography-based navigation with automated referencing, part I: cervicothoracic spine. *Neurosurgery*. 2011;69(4):782–795. doi:10.1227/NEU.0b013e318222ae16
- Ludwig SC, Kramer DL, Vaccaro AR, Albert TJ. Transpedicle screw fixation of the cervical spine. *Clin Orthop Relat Res*. 1999;(359):77–88. doi:10.1097/00003086-199902000-00009
- Uehara M, Takahashi J, Hirabayashi H, et al. Perforation rates of cervical pedicle screw insertion by disease and vertebral level. *Open Orthop J*. 2010;4:142–146. doi:10.2174/1874325001004010142

Funding: S&T Program of Hebei:21377762D.

Declaration of Conflicting Interests: The authors report no conflicts of interest in this work.

Consent for publication: Written informed consent for publication was obtained from all participants.

Ethics Approval: Ethics approval was obtained from Tianjin hospital.

Data availability statement: J.M. conceived and designed the study. Y.H. and J.L. analyzed the data. K.P.L. wrote the manuscript. All authors read and approved the final manuscript.

Corresponding Author: Jun Miao, Tianjin Hospital, 406 Jiefang S Rd, Hexi District, Tianjin, China; likepeng19801@163.com

Published 31 August 2022

This manuscript is generously published free of charge by ISASS, the International Society for the Advancement of Spine Surgery. Copyright © 2022 ISASS. To see more or order reprints or permissions, see <http://ijssurgery.com>.