

## When to Consider Stand-Alone Lateral Lumbar Interbody Fusion: Is There a Role for a Comeback With New Implants?

Cristiano Magalhães Menezes, Érica Godinho Menezes, Jahangir Asghar and Alfredo Guiroy

*Int J Spine Surg* 2022, 16 (S1) S69-S75

doi: <https://doi.org/10.14444/8238>

<https://www.ijssurgery.com/content/16/S1/S69>

This information is current as of May 5, 2025.

---

**Email Alerts** Receive free email-alerts when new articles cite this article. Sign up at:  
<http://ijssurgery.com/alerts>

# When to Consider Stand-Alone Lateral Lumbar Interbody Fusion: Is There a Role for a Comeback With New Implants?

CRISTIANO MAGALHÃES MENEZES, MD, PHD<sup>1</sup>; ÉRICA GODINHO MENEZES, MD, PHD<sup>2</sup>; JAHANGIR ASGHAR, MD<sup>3</sup>; AND ALFREDO GUIROY, MD<sup>3</sup>

<sup>1</sup>Columna Institute, Hospital Vila da Serra – Belo Horizonte, Nova Lima, Brazil; <sup>2</sup>Columna Institute, University Center of Belo Horizonte – UNIBH, Belo Horizonte, Brazil; <sup>3</sup>The Paley Orthopedic and Spine Institute at Saint Mary's Medical Hospital, West Palm Beach, Florida, USA

## ABSTRACT

**Objective:** To perform a comprehensive review of the literature about the role of stand-alone lateral lumbar interbody fusion (LLIF).

**Methods:** A MEDLINE review was conducted including studies about stand-alone LLIF for any condition. The opinions of the authors were also considered. Studies that included biomechanical, cadaveric, or clinical aspects of stand-alone cages were revised to obtain data about the pros, cons, and limitations of the technique. Comparative studies with 360° (lateral + posterior) fusions were also analyzed.

**Results:** A total of 36 studies were identified. After reviewing the abstracts, 18 full articles of interest for the objective of this review were analyzed. Recommendations based on the literature were made. Although most of the recommendations in the literature were about augmentation with pedicle screws, there may be a role for stand-alone LLIF in some particular cases. Specific technical aspects should be considered to reduce the failure rate.

**Conclusion:** Although there might be some specific indications for stand-alone LLIF, it should be considered an exception rather than the rule.

**Level of Evidence:** 4.

Focus Issue Article

Keywords: stand-alone, lumbar interbody fusion, lateral transposas approach, lumbar spine, LLIF fusion

## INTRODUCTION

Degenerative disc disease is one of the most common conditions treated by spine surgeons and is a common cause of dysfunction with a negative impact on quality of life. Lateral lumbar interbody fusion (LLIF) is a minimally invasive technique proven to be useful for indirect decompression of the spinal canal and foramina with high fusion rates and a very low risk of complications.<sup>1</sup>

The principle of indirect decompression implies stretching the ligaments by restoring disc height. This maneuver is very effective in mobile spines but depends on many factors, such as position and height of the interbody device, and the stiffness and support of the vertebral end plates. The weakest part of the lumbar end plates is the central portion, so placing interbody implants that span the apophyseal ring provides better support.<sup>2</sup>

Indirect decompression depends on the sparing of the disc height obtained with the interbody cages. Subsidence will affect decompression and might impact patient outcomes. Due to the high rates of subsidence with the first designed implants, adding posterior screw instrumentation

became popular. That confers better biomechanical properties, particularly for restricting axial rotation and lateral bending. With technological advances, wider implants with an increased footprint on the end plates and LLIF with in situ screws have been developed, which theoretically might reduce subsidence rates. The rationale behind considering stand-alone LLIF includes decreasing surgical time, avoiding use of the posterior approach and its complications, lower blood loss, cost-effectiveness, and higher fusion rates.<sup>3</sup>

Traditionally, the interbody for an LLIF is inserted in the lateral position, and then the patient is repositioned to a prone position for pedicle screw adding. Repositioning the patient and repreparing the surgical field adds time to the procedure. To reduce time, single-position surgery has evolved and has been increasing in popularity over the past few years, with both the lateral cage and posterior instrumentation occurring in the same position (lateral or prone).

Although single position seems promising, there is a learning curve to inserting screws in the lateral decubitus position (lateral single position) and for

inserting a lateral cage in the prone position (prone lateral surgery) with the low but still undeniable risks and morbidity associated with the pedicle screws placement. Stand-alone lateral cages are attractive to avoid both repositioning and the posterior instrumentation step.

Today, the rationale for the use of stand-alone LLIF has not yet been defined. Thus, the objective of this study was to provide a comprehensive, up-to-date review of the literature to better define which group of patients may benefit from the use of this technique.

## MATERIAL AND METHODS

A literature review was performed using PubMed.gov (<https://www.ncbi.nlm.nih.gov/pubmed>) to identify articles published in English that included stand-alone LLIF patient outcomes or related biomechanical features. We sought to determine which patients may benefit from a stand-alone LLIF and which have high risk of failure/revision and the potential associated risk factors.

### Literature Search Strategy

The following questions were asked to guide our review: “Are the results of stand-alone LLIF similar or better than those supplemented with posterior instrumentation? In which groups of patients were the outcomes for stand-alone LLIF similar to the outcomes of patients undergoing LLIF + posterior instrumentation?”

The following search terms were used: “stand alone” and “LLIF or lateral interbody or XLIF or transposas” and “circumferential fusion or pedicle screws or 360° fusion or percutaneous screws.” All articles found were reviewed for eligibility.

Eligibility criteria for study selection were as follows:

- Articles published in English in the past 10 years.
- Articles published in peer-reviewed journals.
- Articles describing either retrospective or prospective human trials, systematic reviews, and meta-analyses.
- Biomechanical articles that compared stand-alone vs LLIF + posterior instrumentation.
- Articles describing risk factors for failure of stand-alone instrumentation.
- Articles that were not of interest for the objective of this article, articles that did not meet the previous inclusion criteria, book chapters, and other documents were excluded.

## RESULTS

Thirty-six articles were identified in our PubMed search. After reading the abstracts, 18 were eligible for full text review and are described in the following paragraphs.

### Literature Search Findings

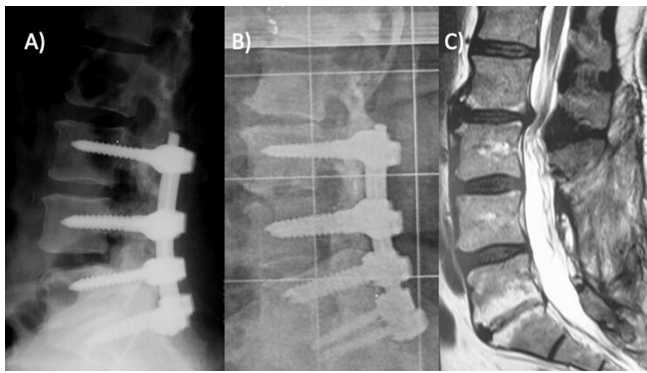
Agarwal et al studied the impact of the end plate-implant area mismatch on rates and grades of subsidence in stand-alone LLIF. They analyzed 623 levels in 297 patients with an 11.4% subsidence rate. The subsidence group was found to have a lower bone mineral density based on DEXA scans  $t$  scores when compared to the control group ( $-1.7$  subsidence group and  $-0.8$  control group  $P = 0.016$ ). A strong correlation was noted between the use of 18-mm wide implants and the development of high grade (over 50%) subsidence requiring revision surgery. No statistical significance was found between implant size (18 or 22 mm) and reoperation rates.<sup>4</sup>

Le et al compared the rates of subsidence between 18- and 22-mm-wide cages and showed significantly higher subsidence rates in patients with 18-mm (14.1%) vs 22-mm (1.9%) cages.<sup>5</sup> Additionally, Marchi et al demonstrated that the incidence of subsidence between the standard and wide (22-mm cage) groups was higher for the 18-mm-wide cage (grades 2 and 3 of subsidence).<sup>6</sup>

In a biomechanical study, Shasti et al described several different lateral-based interbody strategies for managing ASD in a multilevel pre-existing posterior fusion specimen. The results showed that LLIF instrumentation alone reduces the range of motion in all bending planes when implanted proximal to an existing fusion model. Addition of a lateral plate or anterior screws with rod constructs provided further reduction in all bending moves most apparent in lateral bending. They concluded, consistent with previous studies, that the most stable construct included was pedicle screw fixation.<sup>7</sup> (Figures 1 and 2).

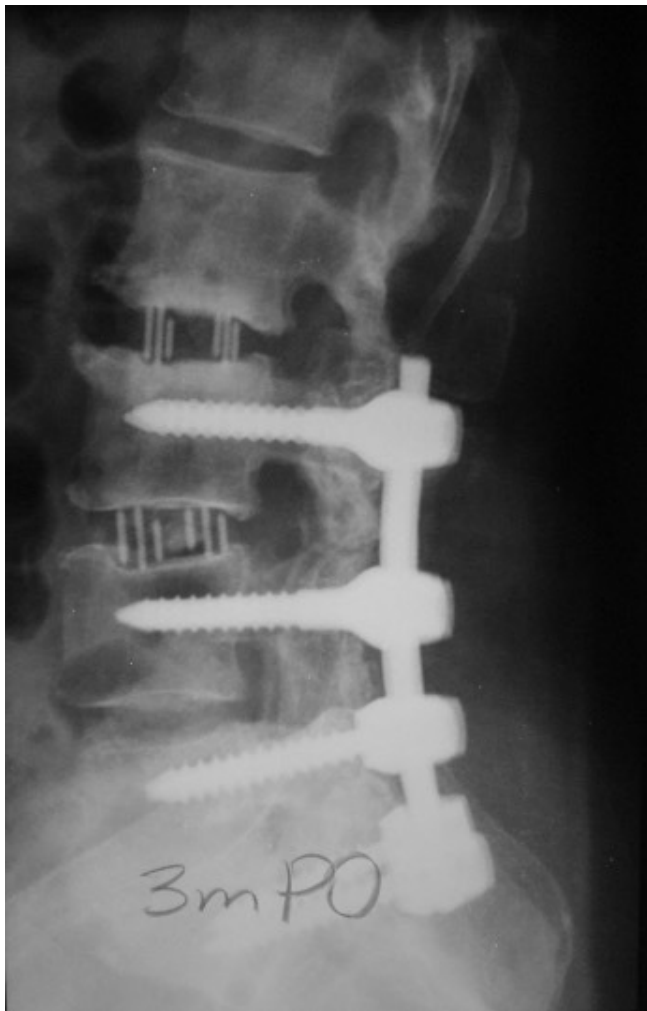Liang et al also described the need to use pedicle screw constructs in ASD using LLIF and found that the biomechanical model considering stand-alone construct provided a minimal restriction of the range of motion (18.3% compared to 90.1% of augmented pedicle screw construct).<sup>8</sup>

With the biomechanical hypothesis of “going wider for going stiffer,” Pimenta et al investigated whether even wider cages (26 mm wide) may be the final solution to achieve enough stability in stand-alone constructs.



**Figure 1.** (A) Immediate postoperative images after posterolateral fusion L3-S1, without changes in the level L2-L3. (B, C) 5-year postoperative images with adjacent segment disease at L2-L3 levels and pseudoarthrosis at L3-L4 level.

Based on biomechanical tests, they suggested that the stability provided by the extreme lateral interbody fusion spacers with adequate cage height sizing and good bone quality may allow for less supplemental



**Figure 2.** Extreme lateral interbody fusion (XLIF) L3-L4 to correct pseudoarthrosis and stand-alone XLIF at L2-L3 to address adjacent segment disease.

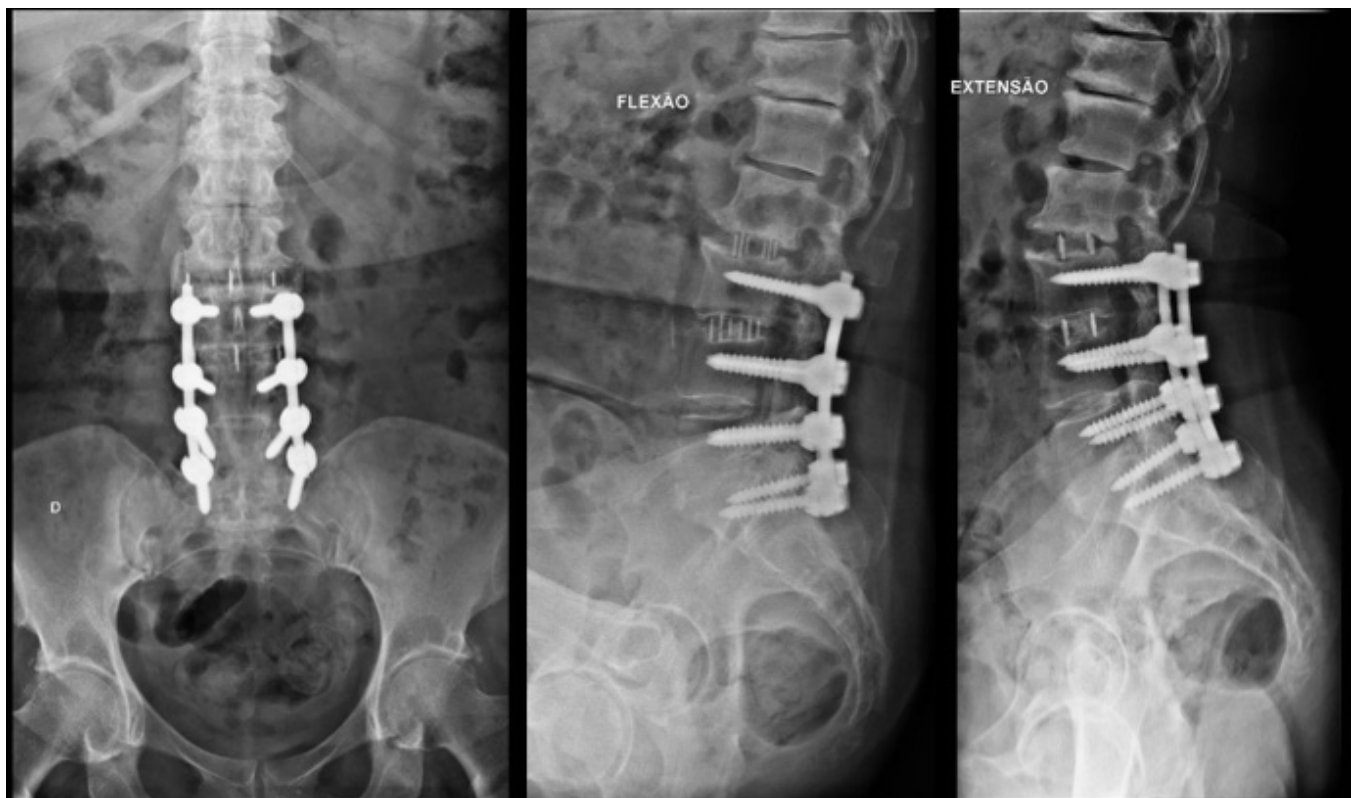fixation (Figure 3). Stand-alone constructs have proven to be biomechanically insufficient to provide stabilization in all directions, but the 26-mm spacer may provide 1.5 (flexion-extension) to 2.7 (axial rotation) times as much stability as a transforaminal lateral interbody fusion construct with bilateral pedicle screws. They also discussed the inherent limitations in their study. The tests were performed in L2-L3 levels instead of more caudal levels, such as L4-L5, which would represent immediate postoperative stability instead of long-term impact of cage settling, bone ingrowth, and cyclic loading. In their conclusion, the authors warned that in some cases this may be sufficient to allow bone growth for fusion; however, other factors such as existing instability, bone quality, and patient activity level should first be evaluated when considering fixation options.<sup>9</sup>

Of note, most studies describing subsidence as a complication of LLIF were based on the Marchi classification. This subsidence grading classification was based on the percentage of disc space or vertebral body collapse around the interbody graft compared to that seen on immediate postoperative imaging. Low-grade subsidence is considered for grade 0 (0%–24% collapse) and grade 1 (25%–49% collapse), which, in practice, would never be mild. This concept underestimates the complications for stand-alone interbody cages in the transposas approach. The clinical implications of subsidence in stand-alone LLIF may be more pronounced than those in more traditional posterior and transforaminal approaches given that it does not take the advantage of load sharing provided by posterior pedicle screws; additionally, the area of subsidence tends to be larger in the end plates with characteristics of a real vertebral fracture.<sup>5,10,11</sup>

Mechanisms for vertebral body fractures in patients undergoing LLIF may be multifactorial and related to technique, implant material, graft size, and patient bone quality.<sup>11,12</sup> Satake et al found in their consecutive case series of 201 levels of LLIF a risk of intraoperative end plate injury of more than 10%, and the injury group had significantly higher rates of women ( $P = 0.002$ ), lower bone mineral density ( $P = 0.02$ ), higher rate of polyetheretherketone (PEEK) as cage material ( $P = 0.04$ ), and taller cage heights ( $P = 0.03$ ).<sup>13</sup>

Moreover, many authors reported good results using stand-alone LLIF for different indications. Rentenberger et al, in a study to assess which perioperative factors were related for early revisions in stand-alone LLIF, stated that although these procedures have been shown to be a safe treatment option with good outcomes, the reoperation rate may vary significantly, ranging from 3.4% to 26%. One





**Figure 3.** Long term follow-up demonstrating solid fusion in both levels treated with extreme lateral interbody fusion (XLIF).

reason for that variation may be the heterogeneity of the study populations, which might have different preoperative diagnoses. Their study showed that patients with a preoperative diagnosis of foraminal stenosis were more likely to require revision surgery due to loss of indirect decompression with subsidence.<sup>14</sup>

Nguyen et al, in a cohort of 529 patients, demonstrated a revision rate at the index level of stand-alone anterior lateral interbody fusion and LLIF of 3.8%. Marchi reported a revision rate of 13.5% in 74 patients in a prospective, comparative single center study.<sup>6,15</sup>

While there are potential benefits to stand-alone LLIF that have encouraged clinicians to use this approach to manage ASD, some complications should also be considered. In another study, Marchi et al tried to identify which patients may undergo the stand-alone procedure without cage subsidence and created a score with risk factors, considering age over 61, female gender, and the presence of spondylolisthesis and scoliosis as the main determinant factors.<sup>16</sup>

With the technological advances and the less invasive approaches, at least 2 disruptive alternatives have emerged to make the posterior-based pedicle screw fixation additional to LLIF possible, without the need to flip the patient for a different decubitus: single-position surgery in lateral and prone position. They involve inserting percutaneous

pedicle screws with the patient in a lateral position or performing the LLIF in prone position. Both have the advantage to avoid the time required to change patients from one decubitus position to another and provide the stability of a 360° reconstruction.<sup>17-21</sup>

Nonunion is a concern when any fusion procedure has been performed. Watkins et al found a nonunion rate of 19% per level and 27% per patient.<sup>22</sup> In a systematic review of fusion rate for stand-alone LLIF, Manzur et al found a reoperation rate of 11.1% and a pooled fusion rate of 80.4%.<sup>23</sup>

Overall, patient-related factors (bone quality, age older than 60 years, smoking status, high demand levels, female gender, spondylolisthesis, and scoliosis) and technical-related factors (intraoperative end plate violation, smaller cages, apophyseal ring contact of the implants, material of the cage, and type of graft used) combine to determine the outcomes of stand-alone LLIF.<sup>5-7,10-22</sup>

## DISCUSSION

The lateral transpsoas approach is an excellent option for interbody fusion, since a sufficiently large, wide, and stable cage may be placed to enable a solid fusion in the surgically treated segment. Revision surgery using stand-alone LLIF for adjacent segment disease (ASD) is particularly attractive, because it

prevents many of the complications related to revision procedures, such as dural tears, excessive bleeding, scar tissue manipulation, and wound-related complications.<sup>3</sup>

As traditional instrumentation is based on pedicle screws and LLIF is performed in lateral decubitus, the challenge that many surgeons faced was the need to flip the patient from a lateral to a prone position to perform instrumentation after LLIF. Due to this specific drawback, many surgeons made an attempt at proving the efficacy and safety of stand-alone stabilization with a cage that, in theory, would be sufficiently stable to allow fusion without instrumentation.<sup>8,9,23–28</sup> However, complications may occur despite the many advantages of the LLIF procedure. Graft subsidence is of particular concern and may lead to loss of the indirect decompression, sagittal alignment, and adjacent segment degeneration.<sup>4,6</sup>

The newly designed cages for LLIF promise to decrease the subsidence rate and possibly expand the stand-alone indications. They are represented by devices manufactured by 3-dimensional (3D) printing. Geometric mismatch between the implant and vertebral end plates has been suggested as one major cause of cage subsidence based on findings from finite element studies.<sup>29,30</sup> Recent mechanical testing using 3D-printed cages and anatomically representative surrogate models also showed significantly reduced subsidence resistance with increased geometric mismatch between the implant and vertebral end plates.<sup>31</sup> These 3D-printed devices are designed so that they adapt exactly to the patients' end plate anatomy, offering an attractive solution to reduce the implant-end plate mismatch. Clinical data also appear to support this concept, as a recent review study of 17 clinical studies on 3D-printed patient-specific spine implants showed favorable subsidence and pseudarthrosis rates.<sup>32</sup> Additionally, 3D printing technology enabled the introduction of novel porous concepts in modern cage designs. Despite the scarcity of available data, early clinical outcome studies suggested that the 3D-printed porous titanium cages achieved satisfactory subsidence and fusion performance.<sup>33,34</sup> Recent mechanical testing data of a 3D-printed porous titanium cage, compared to traditional solid titanium or PEEK cages, showed a significantly reduced subsidence displacement under simulated spine loading conditions within a period of 3 months postoperatively.<sup>35</sup> There are potential impacts in the newer designed implants to promote immediate stability and better capacity to stimulate early ongrowth and ingrowth of bone tissue. This represents an issue to be observed in future studies,

once all the stand-alone literature is based on smooth PEEK technology.

Additionally, the new designed cages for LLIF include the new generation of expandable modular cages. These new generation cages have independent expandable properties, anterior, posterior, and even coronal, which might fit in more anatomically in the intervertebral space, avoiding too much pressure in specific points of the end plate and reducing the risks of subsidence. However, contradictory findings were suggested in early clinical outcome studies of expandable cages for transforaminal lateral interbody fusion procedure.<sup>36,37</sup> Data remain lacking for expandable LLIF cages. Therefore, further well-conducted biomechanical and clinical research with these new devices, associated with a detailed knowledge of bone density and its biological responses, will determine in the future the exact role of stand-alone use for LLIF. In the current practice, based on this literature review and the authors' experience, it should be used with caution in specific cases.

## CONCLUSION

There might be some specific indications for stand-alone LLIF, but despite its high subsidence rates and low fusion rates, it should be considered an exception and not the rule.

## REFERENCES

1. Ozgur BM, Aryan HE, Pimenta L, Taylor WR. Extreme lateral interbody fusion (XLIF): a novel surgical technique for anterior lumbar interbody fusion. *Spine J*. 2006;6(4):435–443. doi:10.1016/j.spinee.2005.08.012
2. Grant JP, Oxland TR, Dvorak MF. Mapping the structural properties of the lumbosacral vertebral endplates. *Spine (Phila Pa 1976)*. 2001;26(8):889–896. doi:10.1097/00007632-200104150-00012
3. Louie PK, Haws BE, Khan JM, et al. Comparison of stand-alone lateral lumbar interbody fusion versus open laminectomy and posterolateral instrumented fusion in the treatment of adjacent segment disease following previous lumbar fusion surgery. *Spine (Phila Pa 1976)*. 2019;44(24):E1461–E1469. doi:10.1097/BRS.0000000000003191
4. Agarwal N, White MD, Zhang X, et al. Impact of endplate-implant area mismatch on rates and grades of subsidence following stand-alone lateral lumbar interbody fusion: an analysis of 623 levels. *J Neurosurg Spine*. 2020;6:1–5. doi:10.3171/2020.1.SPINE19776
5. Le TV, Baaj AA, Dakwar E, et al. Subsidence of polyetheretherketone intervertebral cages in minimally invasive lateral retroperitoneal transpsoas lumbar interbody fusion. *Spine (Phila Pa 1976)*. 2012;37(14):1268–1273. doi:10.1097/BRS.0b013e3182458b2f
6. Marchi LM, Abdala N, Oliveira L, Amaral R, Coutinho E, Pimenta L. Radiographic and clinical evaluation of cage subsidence after stand-alone lateral interbody fusion. *J Neurosurg Spine*. 2013;19(1):110–118. doi:10.3171/2013.4.SPINE12319

7. Shasti M, Koenig SJ, Nash AB, et al. Biomechanical evaluation of lumbar lateral interbody fusion for the treatment of adjacent segment disease. *Spine J.* 2019;19(3):545–551. doi:10.1016/j.spinee.2018.09.002
8. Liang Z, Cui J, Zhang J, et al. Biomechanical evaluation of strategies for adjacent segment disease after lateral lumbar interbody fusion: is the extension of pedicle screws necessary? *BMC Musculoskelet Disord.* 2020;21(1):117. doi:10.1186/s12891-020-3103-1
9. Pimenta L, Turner AWL, Dooley ZA, Parikh RD, Peterson MD. Biomechanics of lateral interbody spacers: going wider for going stiffer. *ScientificWorldJournal.* 2012;2012:381814. doi:10.1100/2012/381814
10. Closkey RF, Parsons JR, Lee CK, Blacksin MF, Zimmerman MC. Mechanics of interbody spinal fusion. Analysis of critical bone graft area. *Spine (Phila Pa 1976).* 1993;18(8):1011–1015. doi:10.1097/00007632-199306150-00010
11. Tempel ZJ, Gandhoke GS, Bolinger BD, Okonkwo DO, Kanter AS. Vertebral body fracture following stand-alone lateral lumbar interbody fusion (LLIF): report of two events out of 712 levels. *Eur Spine J.* 2015;24 Suppl 3:409–413. doi:10.1007/s00586-015-3845-x
12. Hou Y, Luo Z. A study on the structural properties of the lumbar endplate: histological structure, the effect of bone density, and spinal level. *Spine (Phila Pa 1976).* 2009;34(12):E427–33. doi:10.1097/BRS.0b013e3181a2ea0a
13. Satake K, Kanemura T, Yamaguchi H, Segi N, Ouchida J. Predisposing factors for intraoperative endplate injury of extreme lateral interbody fusion. *Asian Spine J.* 2016;10(5):907–914. doi:10.4184/asj.2016.10.5.907
14. Rentenberger C, Okano I, Salzmann SN, et al. Perioperative risk factors for early revisions in stand-alone lateral lumbar interbody fusion. *World Neurosurg.* 2020;134:e657–e663. doi:10.1016/j.wneu.2019.10.164
15. Nguyen AQ, Harvey JP, Khanna K, et al. Reasons for revision following stand-alone anterior lumbar interbody fusion and lateral lumbar interbody fusion. *J Neurosurg Spine.* 2021;30:1–7. doi:10.3171/2020.10.SPINE201239
16. Marchi L, Pimenta L, Amaral R, et al. In which patients is it possible to perform stand-alone lateral lumbar interbody fusion without cage subsidence? *Coluna/Columna.* 2016;15(3):226–229. <http://dx.doi.org/10.1590/S1808-185120161503162720>. doi:10.1590/S1808-185120161503162720
17. Guiroy A, Carazzo C, Camino-Willhuber G, et al. Single-position surgery versus lateral-then-prone-position circumferential lumbar interbody fusion: a systematic literature review. *World Neurosurg.* 2021;151:e379–e386. doi:10.1016/j.wneu.2021.04.039
18. Buckland AJ, Ashayeri K, Leon C, et al. Single position circumferential fusion improves operative efficiency, reduces complications and length of stay compared with traditional circumferential fusion. *Spine J.* 2021;21(5):810–820. doi:10.1016/j.spinee.2020.11.002
19. Ouchida J, Kanemura T, Satake K, Nakashima H, Ishikawa Y, Imagama S. Simultaneous single-position lateral interbody fusion and percutaneous pedicle screw fixation using O-arm-based navigation reduces the occupancy time of the operating room. *Eur Spine J.* 2020;29(6):1277–1286. doi:10.1007/s00586-020-06388-6
20. Hiyama A, Katoh H, Sakai D, Sato M, Tanaka M, Watanabe M. Comparison of radiological changes after single-position versus dual-position for lateral interbody fusion and pedicle screw fixation. *BMC Musculoskelet Disord.* 2019;20(1):601. doi:10.1186/s12891-019-2992-3
21. Ziino C, Konopka JA, Ajiboye RM, Ledesma JB, Koltsov JCB, Cheng I. Single position versus lateral-then-prone positioning for lateral interbody fusion and pedicle screw fixation. *J Spine Surg.* 2018;4(4):717–724. doi:10.21037/jss.2018.12.03
22. Watkins R, Watkins R, Hanna R. Non-union rate with stand-alone lateral lumbar interbody fusion. *Medicine (Baltimore).* 2014;93(29):e275. doi:10.1097/MD.0000000000000275
23. Manzur MK, Steinhilber ME, Virk SS, et al. Fusion rate for stand-alone lateral lumbar interbody fusion: a systematic review. *Spine J.* 2020;20(11):1816–1825. doi:10.1016/j.spinee.2020.06.006
24. Grant JP, Oxland TR, Dvorak MF. Mapping the structural properties of the lumbosacral vertebral endplates. *Spine (Phila Pa 1976).* 2001;26(8):889–896. doi:10.1097/00007632-200104150-00012
25. Berjano P, Balsano M, Buric J, Petrucci M, Lamartina C. Direct lateral access lumbar and thoracolumbar fusion: preliminary results. *Eur Spine J.* 2012;21 Suppl 1(Suppl 1):S37–42. doi:10.1007/s00586-012-2217-z
26. Palejwala SK, Sheen WA, Walter CM, Dunn JH, Baaj AA. Minimally invasive lateral transposas interbody fusion using a stand-alone construct for the treatment of adjacent segment disease of the lumbar spine: review of the literature and report of three cases. *Clin Neurol Neurosurg.* 2014;124:90–96. doi:10.1016/j.clineuro.2014.06.031
27. Screven R, Pressman E, Rao G, Freeman TB, Alikhani P. The safety and efficacy of stand-alone lateral lumbar interbody fusion for adjacent segment disease in a cohort of 44 patients. *World Neurosurg.* 2021;149:e225–e230. doi:10.1016/j.wneu.2021.02.046
28. Rentenberger C, Okano I, Salzmann SN, et al. Perioperative risk factors for early revisions in stand-alone lateral lumbar interbody fusion. *World Neurosurg.* 2020;134:e657–e663. doi:10.1016/j.wneu.2019.10.164
29. Chatham LS, Patel VV, Yakacki CM, Dana Carpenter R. Interbody spacer material properties and design conformity for reducing subsidence during lumbar interbody fusion. *J Biomech Eng.* 2017;139(5). doi:10.1115/1.4036312
30. Calvo-Echenique A, Cegoñino J, Chueca R, Pérez-Del Palomar A. Stand-alone lumbar cage subsidence: a biomechanical sensitivity study of cage design and placement. *Comput Methods Programs Biomed.* 2018;162:211–219. doi:10.1016/j.cmpb.2018.05.022
31. Fogel GR, Yee-Yanagishita C, Malik J, Douglas B, Peng Y, Jekir M. P17. Investigating the effects of cage width and placement on subsidence performance using anatomically representative models. *Spine J.* 2020;20(9):S155–S156. doi:10.1016/j.spinee.2020.05.415
32. Wallace N, Schaffer NE, Aleem IS, Patel R. 3D-printed patient-specific spine implants: a systematic review. *Clin Spine Surg.* 2020;33(10):400–407. doi:10.1097/BSD.0000000000001026
33. Krafft PR, Osburn B, Vivas AC, Rao G, Alikhani P. Novel titanium cages for minimally invasive lateral lumbar interbody fusion: first assessment of subsidence. *Spine Surg Relat Res.* 2020;4(2):171–177. doi:10.22603/ssrr.2019-0089
34. Amini DA, Okano I, Oezel L, et al. Evaluation of cage subsidence in standalone lateral lumbar interbody fusion: novel 3D-printed titanium versus polyetheretherketone (PEEK) cage. *Brain and Spine.* 2021;1:100153. doi:10.1016/j.bas.2021.100153
35. Fogel GR, Martin N, Malik J, Unger J, Peng Y, Jekir M. *Characterizing the effect of cage material and novel porosity design on the cage subsidence performance under clinically relevant*

*dynamic loading conditions*. 2021. <https://www.ors.org/Transactions/67/1457.pdf>.

36. Chang C-C, Chou D, Pennicooke B, et al. Long-term radiographic outcomes of expandable versus static cages in transforaminal lumbar interbody fusion. *J Neurosurg Spine*. 2020;34(3):1–10. doi:10.3171/2020.6.SPINE191378

37. Stickley C, Philipp T, Wang E, et al. Expandable cages increase the risk of intraoperative subsidence but do not improve perioperative outcomes in single level transforaminal lumbar interbody fusion. *Spine J*. 2021;21(1):37–44. doi:10.1016/j.spinee.2020.08.019

**Funding:** The author(s) received no financial support for the research, authorship, and/or publication of this article.

**Declaration of Conflicting Interests:** Cristiano Menezes, MD, PhD, reports consulting, research grants, and product development at Nuvasive; education AOSPINE; and Board of Directors for the Brazilian

Spine Society (SBC), Brazilian Orthopedic Society (SBOT), and AOSPINE (Brazilian Chapter). Jahangir Asghar, MD, reports education at Nuvasive, Medtronic, and Immertec. Alfredo Guiroy, MD, reports conducting educational seminars at meetings at AOSPINE.

**Corresponding Author:** Cristiano Magalhães Menezes, Columna Institute, Hospital Vila da Serra, Alameda Oscar Niemeyer, 499 - Vila da Serra, Nova Lima - MG, 34000-000, Brazil; [cristiano@vertebral.com.br](mailto:cristiano@vertebral.com.br); [cristianomenezes@me.com](mailto:cristianomenezes@me.com)

Published 05 April 2022

This manuscript is generously published free of charge by ISASS, the International Society for the Advancement of Spine Surgery. Copyright © 2022 ISASS. To see more or order reprints or permissions, see <http://ijssurgery.com>.