

Full-Endoscopic Removal of Migrated and Pseudoarthrotic Lumbar Interbody Cages: Case Reports and Technical Note

Christian Morgenstern and Rudolf Morgenstern

Int J Spine Surg 2023, 17 (3) 370-379

doi: <https://doi.org/10.14444/8451>

<http://ijssurgery.com/content/17/3/370>

This information is current as of May 6, 2024.

Email Alerts Receive free email-alerts when new articles cite this article. Sign up at:
<http://ijssurgery.com/alerts>

Full-Endoscopic Removal of Migrated and Pseudoarthrotic Lumbar Interbody Cages: Case Reports and Technical Note

CHRISTIAN MORGENSTERN, MD, PhD¹ AND RUDOLF MORGENSTERN, MD, PhD¹

¹Morgenstern Institute of Spine, Centro Médico Teknon, Barcelona, Spain

ABSTRACT

Background: The removal of a lumbar interbody cage in revision spine surgery can be challenging, as there is an increased risk of nerve injury and a protracted outcome. The aim of this study was to evaluate the feasibility and preliminary results of uniportal full-endoscopic surgery for the removal of migrated and/or pseudoarthrotic lumbar interbody cages.

Methods: Three complex revision surgery cases with migrated and pseudoarthrotic lumbar interbody cages are presented, and the endoscopic surgical technique is described. The clinical outcome was assessed with a visual analog scale and Oswestry Disability Index (ODI) at 1-, 3-, 6-, and 12-month follow-up, while the radiologic outcome was assessed with pre- and postoperative x-ray and computed tomographic images. Full-endoscopic surgery was performed to extract the interbody cage, bypassing scar tissue of previous surgeries with the trans-Kambin approach. Foraminoplasty with manual reamers and/or a high-speed burr under direct endoscopic vision was performed to ensure the safety of the exiting nerve root during cage extraction. The retrieved cage was replaced with a large footprint, expandable titanium cage using the trans-Kambin approach.

Results: In all 3 cases, different types of interbody cages (1 titanium, 2 polyetheretherketone, and 1 expandable titanium cage) were removed under direct endoscopic view. In 1 case, we were only able to partially remove an impacted polyetheretherketone cage from the interbody disc endoscopically. The postoperative outcome significantly ($P < 0.05$) improved compared with preoperative scores in all 3 cases with a follow-up of 6 and 12 months, respectively.

Conclusion: In most cases, lumbar interbody cages can be safely removed with endoscopic surgery with good preliminary clinical outcome. Nonetheless, further clinical research with long-term follow-up is required.

Clinical Relevance: Results indicate the feasibility of full-endoscopic removal of migrated and pseudoarthrotic lumbar interbody cages.

Level of Evidence: 3.

Endoscopic Minimally Invasive Surgery

Keywords: endoscopic surgery, trans-Kambin fusion, transforaminal approach, migrated interbody cage, pseudoarthrosis, revision spine surgery

INTRODUCTION

Endoscopic spine surgery has experienced a remarkable rise in indications and applications over the past decade, including discectomy and decompression of the lumbar,^{1–4} thoracic,⁵ and cervical spine⁶ as well as percutaneous/endoscopic fusion surgery.^{7–12} As endoscopic surgery continues to advance, an increasing number of new applications and indications are explored, such as full-endoscopic surgery for gunshot/bullet injuries,¹³ spondylodiscitis,^{14,15} and spinal tumors.^{16,17} The sustained expansion and addition of new applications underline the versatility and ongoing dynamism of endoscopic spine surgery.

In revision spine surgery, failed fusion cases usually require the removal of a migrated and/or

pseudoarthrotic lumbar interbody cage. The removal of an interbody cage can be challenging, as there is an increased risk of nerve injury and a protracted outcome.^{18–20} One of the main features of uniportal endoscopic spine surgery is the posterolateral, transforaminal approach using Kambin's triangle (trans-Kambin approach) as it allows bypassing posterior scar tissue from previous surgeries (Figure 1). This offers an alternative approach that allows reducing the risk of infection and dural tear, especially for revision surgery cases.^{18–20} Hence, we hypothesized that the full-endoscopic trans-Kambin approach could be useful for revision spine surgery cases that require the removal of an interbody cage.

In this study, we intended to determine the feasibility and preliminary results of uniportal endoscopic spine

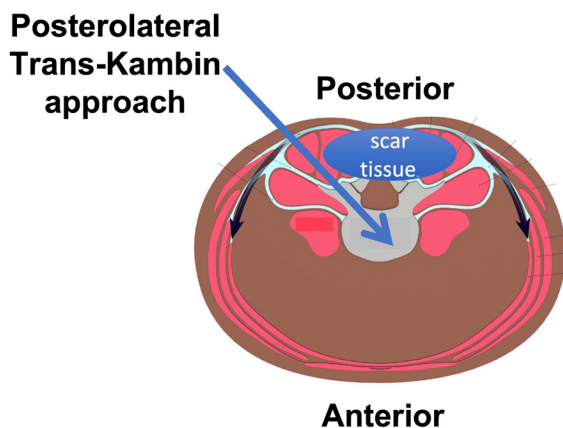


Figure 1. An axial view of the lumbar spine and abdomen. In revision surgery cases after open transforaminal lumbar interbody fusion surgery, scar tissue can be usually found at the posterior part of the spine. The trans-Kambin approach to the disc allows bypassing of posterior scar tissue (arrow).

surgery for the removal of interbody cages in revision surgery cases after failed transforaminal lumbar interbody fusion (TLIF) surgery.

CASE REPORTS

First Clinical Case

A 68-year-old man presented to our practice with acute onset of radiating right leg pain during the past month (Table) that did not decrease despite taking high-dosed analgesia (tramadol 100 mg 1/8 hours, pregabalin 75 mg 1/8 hours, nonsteroidal anti-inflammatory drugs [NSAIDs], etc). He had the following surgical history:

- lumbar discectomy at L4-L5, which occurred 10 years before (elsewhere)
- lumbar instrumented surgery with transpedicular screws from L4 to L5, which occurred 3 years before (elsewhere)
- revision TLIF surgery at L3-L4 and L4-L5 due to adjacent segment degeneration at L3-L4, which occurred 6 months before

In the physical examination, we found a positive Lasegue test at 45° on the right side and no motor weakness. X-ray control images of the lumbar spine from

a few months before showed an undersized interbody titanium cage at L3-L4 (Figure 2A) that had migrated into the right neuroforamen when the patient presented to our practice (Figure 2B). A preoperative computed tomography (CT) image of the lumbar spine showed fusion of the disc at L4-L5 and did not show signs of osteolysis of the transpedicular screws. Endoscopic removal of the migrated, undersized interbody cage and replacement with an endoscopic, expandable TLIF cage at L3-L4 were planned. Given that no loosening signs were present, we considered it not necessary to remove the posterior fixation. Should it not have been possible to remove the cage endoscopically, we had considered the possibility to convert to open surgery with a complete hardware removal as a back-up plan.

Surgical Technique

The patient was operated on in a prone position under general anesthesia. Neuromonitoring with somatosensory-evoked potentials and motor-evoked potentials was performed by an independent neurophysiologist to monitor any involved peripheral nerves. If required, direct probe stimulation was performed for transpedicular screws, considering a safety threshold of >15 mA. Patient positioning on the surgical table was controlled with C-arm fluoroscopic control.

An 18G needle was placed under fluoroscopic control into the L3-L4 disc using a right-sided transforaminal approach. Soft tissue was progressively dilated, and a patented, beveled sleeve (MaxmoreSpine fusion dilator, Hoogland Spine Products GmbH, Munich, Germany) was inserted into the disc to protect the exiting nerve root (Figure 3A; see also Figure 6A,D in case 2). Foraminoplasty was performed progressively with manual reamers from 8 to 12 mm diameter (Hoogland Spine Products GmbH, Munich, Germany; refer to Figure 6A in case 2). Endoscopic view of the intervertebral disc allowed direct visual localization of the migrated intervertebral cage (Figure 3B and Supplemental Video 1). The cage's handle was inserted through the endoscope's working channel and screwed into the cage under direct

Table. Pre- and postoperative VAS for back and leg scores and ODI scores for all 3 reported full-endoscopic revision surgery cases.

Case	Preoperative Scores	VAS Back/VAS Leg/ODI Scores			
		Postoperative Scores at Hospital Discharge	Postoperative Scores at Latest Follow-up	P Value	Follow-up
Case 1	1/6/36	2/0/26	1/1/14	<0.05 ^a	12 mo
Case 2	6/10/31	6/7/33	5/4/25	<0.05 ^a	12 mo
Case 3	7/4/29	4/2/25	0/3/16	<0.05 ^a	6 mo

Abbreviations: ODI, Oswestry Disability Index; VAS, visual analog scale.

^aSignificant difference (paired Student *t* test).

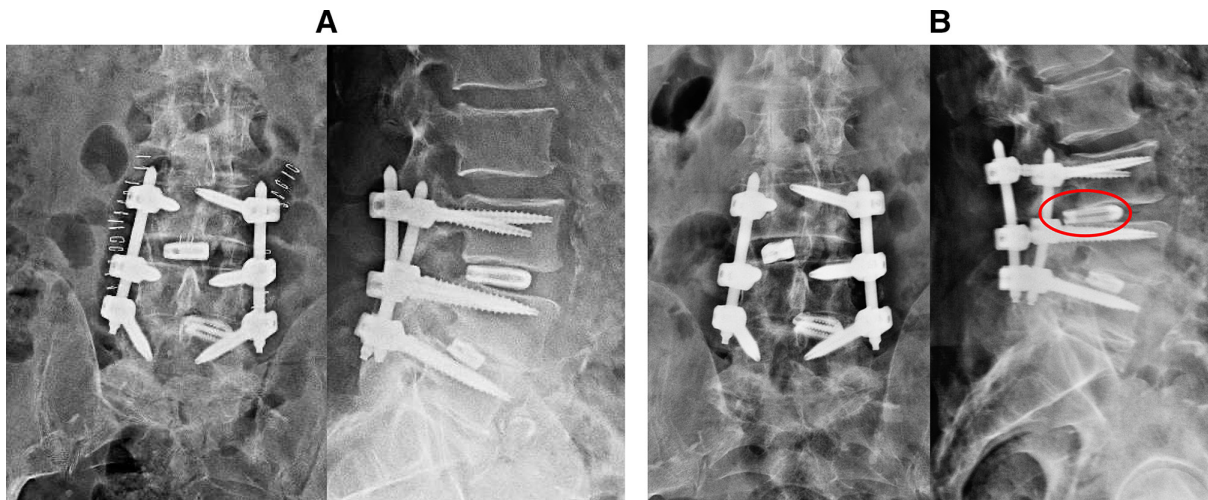


Figure 2. (A) X-ray images of the lumbar spine in anterior/posterior (A/P) (left side) and lateral (right side) views for case 1, 3 mo before he presented to our clinic. Notice the undersized interbody cage at level L3-L4. (B) X-ray images of the lumbar spine in A/P (left side) and lateral (right side) views for case 1 at the time when he presented to our clinic. Also notice the migrated interbody cage into the right neuroforamen at level L3-L4 (marked with a red oval).

endoscopic view (Supplemental Video 1). Once the cage was securely tightened on the handle, it was carefully removed under endoscopic and fluoroscopic view (Figure 3C and Supplemental Video 1).

Then, a percutaneous/endoscopic TLIF was performed as previously reported⁷⁻¹² using the same trans-Kambin approach. Standard disc preparation with nucleotomy and endplate cartilage scratching with curettes and rasps

were performed. Demineralized bone matrix (DBM) was placed into the anterior part of the intervertebral disc, and a large footprint (39 × 13 × 15 mm) expandable interbody cage (Vertacorect, Signus Medizintechnik GmbH, Alzenau, Germany) was filled with DBM and placed in the intervertebral disc (refer to Figure 6D in case 2). After confirming a correct position, the cage was expanded under C-arm fluoroscopic control (Figure 3D).

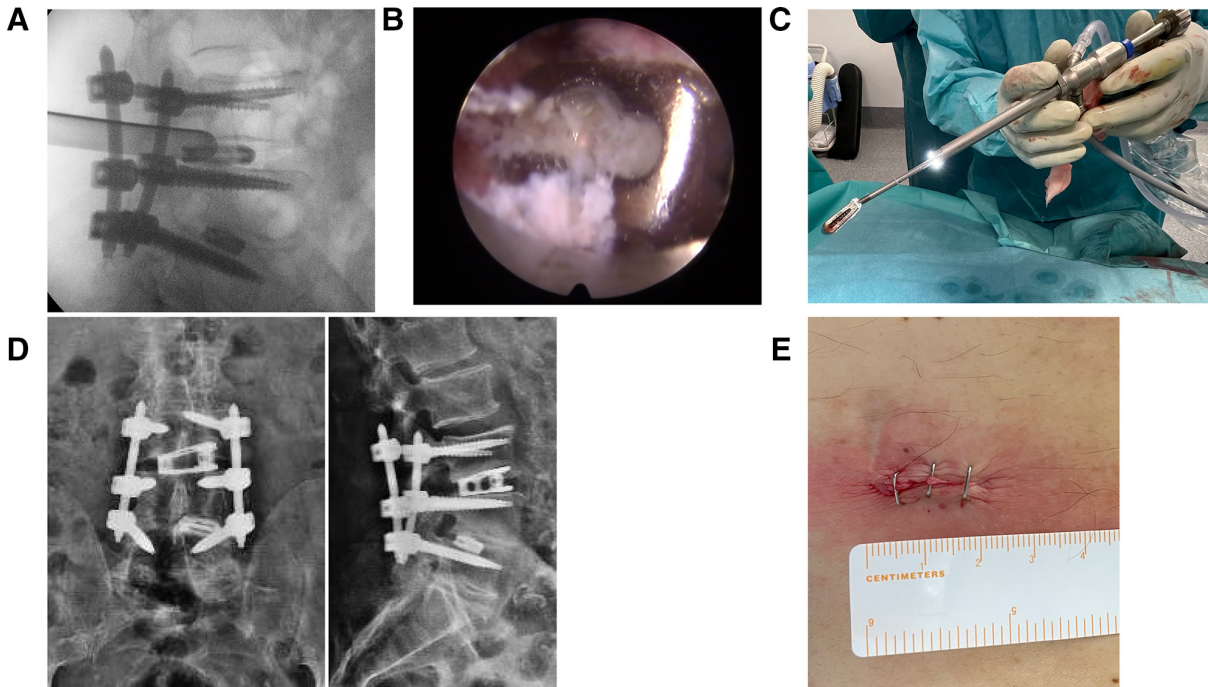


Figure 3. (A) Lateral intraoperative fluoroscopic image of the specialized fusion dilator sleeve positioned into the disc close to the migrated cage at L3-L4. The sleeve protects the right L3 exiting nerve root. (B) Endoscopic view of the migrated titanium interbody cage. (C) Photo of the removed interbody cage attached to the cage handle. The cage handle can be seen looking out the working channel of the endoscope. (D) Postoperative x-ray control images of the lumbar spine in anterior/posterior (left side) and lateral (right side) views. Notice the large footprint, expandable titanium cage that was placed as a substitute at L3-L4. (E) Skin incision of 2-cm length through which the migrated interbody cage was removed, and the substitute large footprint expandable cage was placed into L3-L4 with the trans-Kambin approach.

The removal of the migrated cage and the placement of a new expandable cage were all performed through 1 single skin incision of 2-cm length (Figure 3E). Postoperative x-ray images and CT control images showed correct placement of the expandable interbody cage at L3-L4 (Figure 3D). Postoperatively, the patient resumed walking 4 hours after surgery and was discharged from the hospital within 24 hours after surgery (Table).

Second Clinical Case

A 58-year-old man presented to our practice with chronic low back pain and chronic, exacerbated left leg pain for the past year (Table) that did not decrease despite ongoing conservative treatment (fentanyl transdermal patch, pregabalin 75 mg 1/8 hours, NSAIDs, physiotherapy, etc). He had the following surgical history:

- lumbar discectomy at L4-L5, which occurred 9 years before (elsewhere)
- lumbar redisection at L4-L5, which occurred 4 years before (elsewhere)
- lumbar instrumented fusion surgery with transpedicular screws from L4 to S1, which occurred 3 years before (elsewhere)
- Revision TLIF surgery at L3-L4, L4-L5, and L5-S1 with 3 polyetheretherketone (PEEK) cages, which occurred 2 years before (elsewhere)

During the physical examination, we found an existing motor weakness of the left tibialis anterior muscle grade 1/5, the left hallucis longus extensor muscle grade 3/5, and the left quadriceps muscle grade 3/5. The patient was only able to walk with the help of a cane.

Preoperative x-ray images and a preoperative CT image of the lumbar spine showed pseudarthrosis of L3-L4 and L5-S1 and bilateral screw loosening signs of the S1 screws (Figure 4A,B), respectively. The transpedicular screws were removed from posterior with a posterolateral Wiltse approach. Initially, an anterior retroperitoneal approach was planned to remove the cage at L5-S1 and to be replaced with an anterior lumbar interbody fusion cage. However, the vascular situation assessed with an abdominal angio-CT image, as well as the patient's history of thrombosis of the left iliac common vein, advised against an anterior approach at this level. Hence, the PEEK cages at L3-L4 and L5-S1 were planned to be removed endoscopically and replaced with an expandable titanium cage using the trans-Kambin approach.

Surgical Technique

The same surgical setup and technique were employed as previously described for case 1. The cage at L5-S1 was visualized endoscopically (Figure 5A). As the interbody cage was loosened, we were able to mobilize

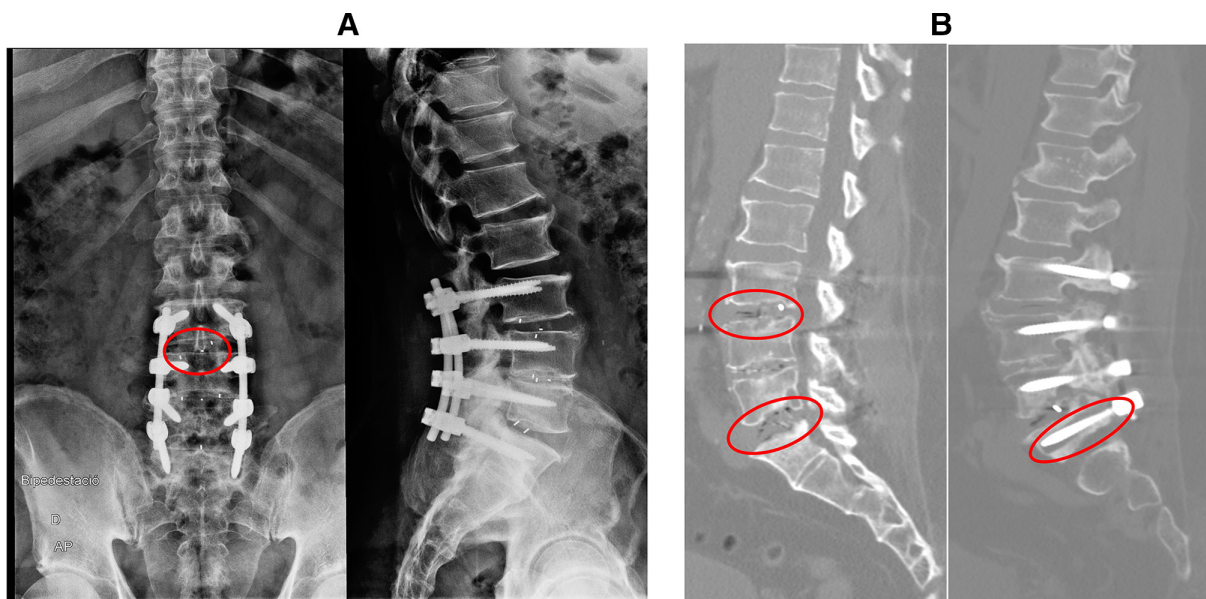


Figure 4. (A) Preoperative x-ray control images of the lumbar spine in anterior/posterior (A/P) (left side) and lateral (right side) views for case 2. Notice the impacted interbody cage into the upper endplate of L4 at L3-L4 (marked with red circle). (B) Preoperative computed tomography image of the lumbar spine. Notice the vacuum sign suggestive of pseudarthrosis in L3-L4 and L5-S1 in the A/P view (marked with red circles), as well as the osteolysis due to screw loosening at S1 in the lateral view (marked with a red circle).

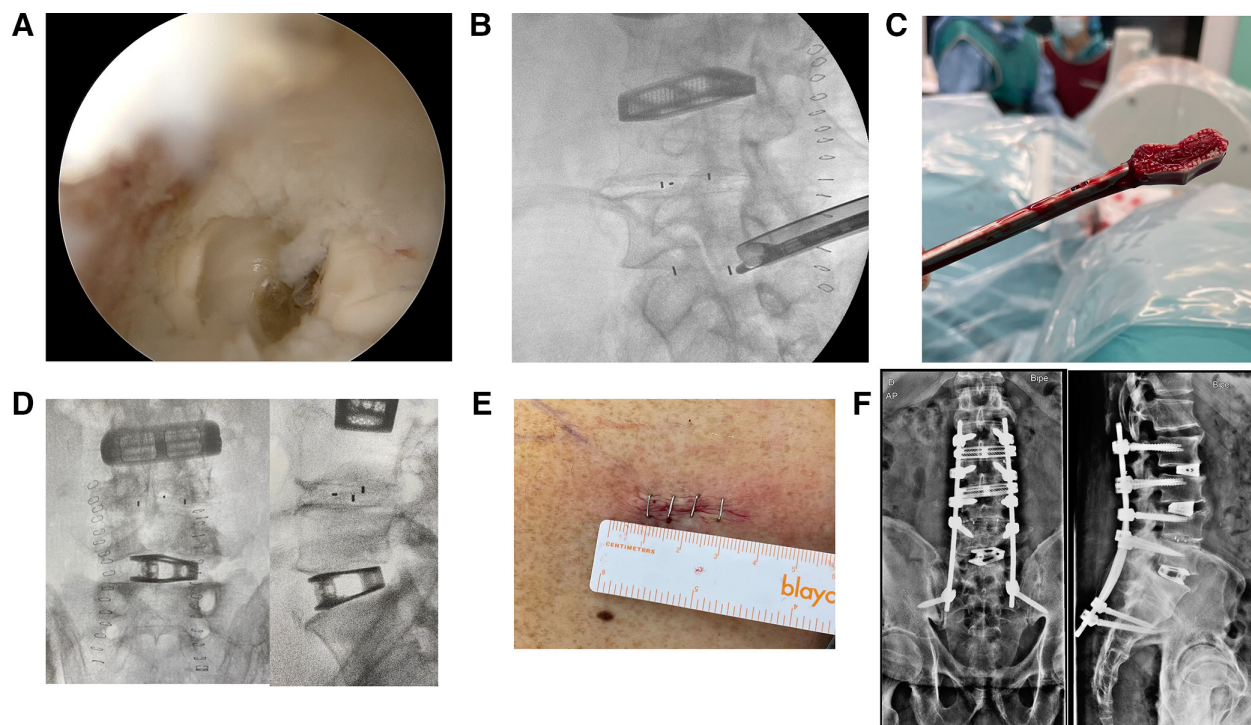


Figure 5. (A) An endoscopic view of the pseudarthrotic PEEK interbody cage. (B) Fluoroscopic lateral intraoperative view of a forceps grasping the interbody cage. A protective sleeve keeps the exiting nerve root protected. (C) Photograph of the removed interbody PEEK cage attached to the forceps. (D) Intraoperative fluoroscopic images of the lumbar spine in anterior/posterior (A/P) (left side) and lateral (right side) views. Notice the large footprint, expandable titanium cage that was placed as a substitute at L5-S1. (E) Skin incision of 2-cm length through which the PEEK interbody cage was removed, and the substitute large footprint expandable cage was placed into L5-S1 with the trans-Kambin approach. (F) Postoperative x-ray control images of the lumbar spine in A/P (left side) and lateral (right side) views.

it with our instruments under endoscopic view. Given the small size of this PEEK cage, a standard endoscopic forceps was employed to carefully grasp (Figure 5B) and remove the cage under fluoroscopic view, while protecting the exiting nerve root with a patented sleeve (MaxmoreSpine fusion dilator, Hoogland Spine Products GmbH, Munich, Germany) (Figure 5C). A percutaneous/endoscopic TLIF technique was then performed as previously described, see case 1, at L5/S1 with a large footprint expandable interbody cage (Vertaconnect, Signus Medizintechnik GmbH, Alzenau, Germany) (Figures 5D and Figure 6A). Given the evident radiologic pseudarthrosis, we employed bone morphogenic protein-2 as graft. The removal of the pseudarthrotic PEEK cage and the placement of a new expandable cage were all performed through 1 single skin incision of 2-cm length (Figure 5E).

The PEEK cage at L3-L4 was impacted into the lower endplate (Figure 4A), and after careful dissection under endoscopic view, it was not possible to mobilize the cage. We employed a high-speed diamond drill directly on the PEEK cage, with which we were able to split the cage and partially remove the cage from the interbody disc. However, despite our best efforts, it was not

possible to remove the impacted fragment of the cage with the endoscope. Therefore, we converted to open surgery and performed an anterior-to-pectoral lateral approach. The cage was successfully removed and replaced with a lateral titanium cage, see Figures 5D,F and 6B. Finally, posterior fixation with percutaneous transpedicular screws (ROMEO 2 MIS, Spineart SA, Switzerland) from L2 to L5 was performed. Due to the massive osteolysis present after removing the loosened screws at S1, S2 alar iliac screws were placed. Intraoperative neuromonitoring did not report any changes at any time during surgery compared with the preoperative status.

Postoperative x-ray and CT control showed correct placement of the expandable interbody cage at L5-S1 (Figure 5F). Postoperatively, the patient resumed walking 6 hours after surgery and was discharged from the hospital 48 hours after surgery (Table). During follow-up, the patient reported a temporary and transitory postoperative radiculitis that completely resolved after 7 weeks with intramuscular dexamethasone 4 mg 1/24 hours treatment for 2 weeks and oral pregabalin 75 mg 1/8 hours treatment.

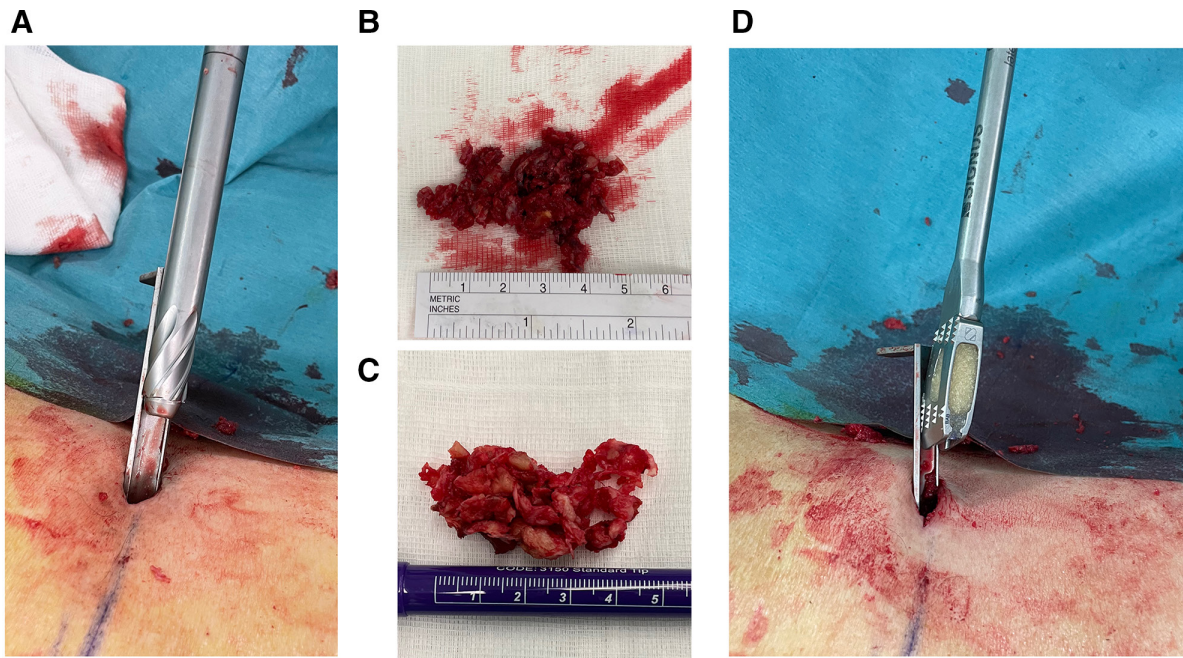


Figure 6. (A) Image depicting a protective sleeve that has been placed through Kambin's triangle into the disc to protect the exiting nerve root, while a foraminoplasty is performed with manual reamers with progressively increasing diameters. (B) Removed disc material after careful disc preparation of level L5-S1 using the trans-Kambin approach. (C) Removed disc material after careful disc preparation for level L3-L4 using the anterior-to-psoas open lateral approach. (D) Image depicting a protective sleeve that has been placed to protect the exiting nerve root while it allows inserting a large footprint interbody cage into the disc.

At 1-year follow-up, a postoperative CT image control of the lumbar spine shows solid fusion of the operated intervertebral discs, see Figure 7.

Third Clinical Case

A 54-year-old woman presented to our practice with chronic radiating right leg pain for the past year (Table), with repetitive falls because of subjective weakness in her right leg. The pain did not decrease despite conservative treatment (tramadol 100 mg 1/8 hours, pregabalin 75 mg 1/8 hours, NSAIDs, physiotherapy, etc). She referred a

surgical history with lumbar instrumented fusion surgery at levels L2-L3 and L4-L5, 1 year before.

On physical examination, on visual inspection, there was a considerable atrophy of the right quadriceps, but no motor weakness could be found compared with the left side. Preoperative x-ray images and a CT image of the lumbar spine showed a tilted expandable interbody titanium cage at L4-L5 (Figure 8A), that had migrated into the right neuroforamen (Figure 8B). Endoscopic removal of the migrated, expandable interbody cage and replacement with a large

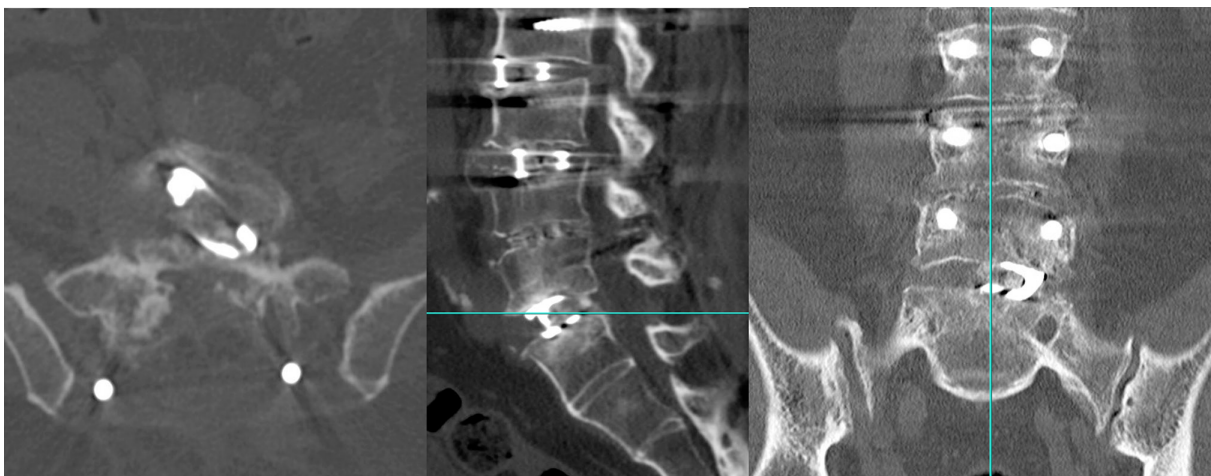


Figure 7. Postoperative computed tomography image at 1-year follow-up showing spinal fusion at all operated levels.

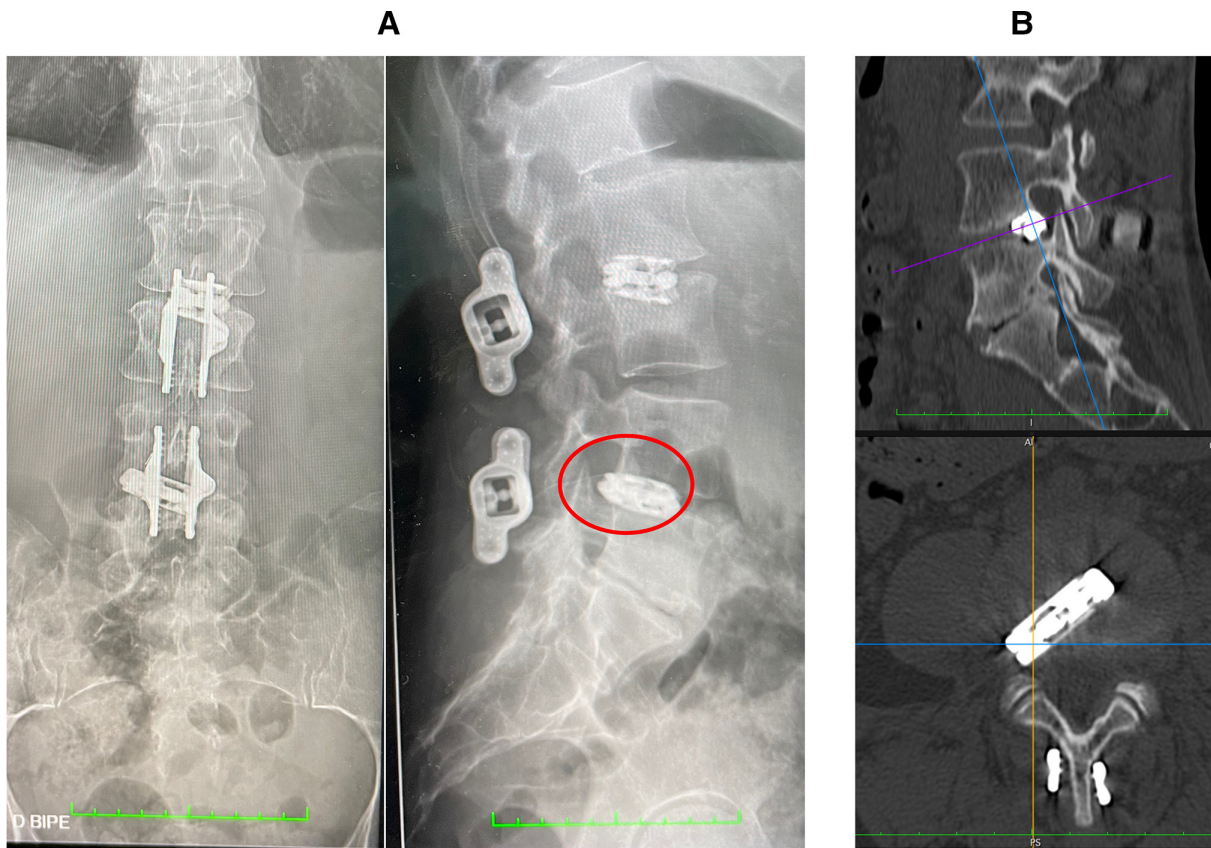


Figure 8. (A) Preoperative x-ray control images of the lumbar spine in anterior/posterior (left side) and lateral (right side) views for case 3. Notice the migrated interbody cage into the right neuroforamen of L4-L5 (marked with red circle). (B) Preoperative computed tomography image of the lumbar spine with lateral (above) and axial (below) views of L4-L5 showing a migrated interbody cage into the right neuroforamen of L4-L5.

footprint, expandable interbody cage with posterior percutaneous screws at L4-L5 were planned.

Surgical Technique

The same surgical setup and technique were employed as previously described for cases 1 and 2. The cage at L4-L5 was visualized endoscopically (Figure 9A). An extensive foraminoplasty was performed progressively with a 3.7-mm high-speed drill (Nouvag GmbH, Switzerland) under direct endoscopic view (Supplemental Video 2). The expanded cage was collapsed with the corresponding cage's screwdriver (Figure 9B). Finally, the collapsed titanium cage was carefully removed using an endoscopic forceps under direct endoscopic view (Figure 9C and Supplemental Video 2).

A percutaneous/endoscopic TLIF technique was performed as previously described at L4-L5 with a large footprint expandable interbody cage (Vertaconnect, Signus Medizintechnik GmbH, Alzenau, Germany) filled with DBM (Figure 9D). Finally, posterior fixation with percutaneous transpedicular screws (ROMEIO 2 MIS, Spineart SA, Switzerland) was performed.

Postoperative x-ray and CT control of the lumbar spine showed the expandable interbody cage with posterior fixation at L4-L5 (Figure 9D). Postoperatively, the patient resumed walking 4 hours after surgery and was discharged from the hospital within 24 hours after surgery (Table). During follow-up, the patient reported a temporary and transitory postoperative radiculitis that completely resolved after 8 weeks with intramuscular dexamethasone 4 mg 1/24 hours treatment for 2 weeks and oral pregabalin 75 mgr 1/8 hours treatment.

DISCUSSION

Pseudarthrosis rate after TLIF surgery has been reported to be as high as 23%.¹⁹ Most of these cases require revision surgery with the removal of the pseudarthrotic and/or migrated interbody cage. However, revision spine surgery can be challenging. Anterior and anterolateral approaches are usually the method of choice for revision spine surgery, as they permit a rigorous disc preparation removal of previous hardware, as well as placement of a large footprint interbody cage while avoiding the posterior scar of a prior surgery.

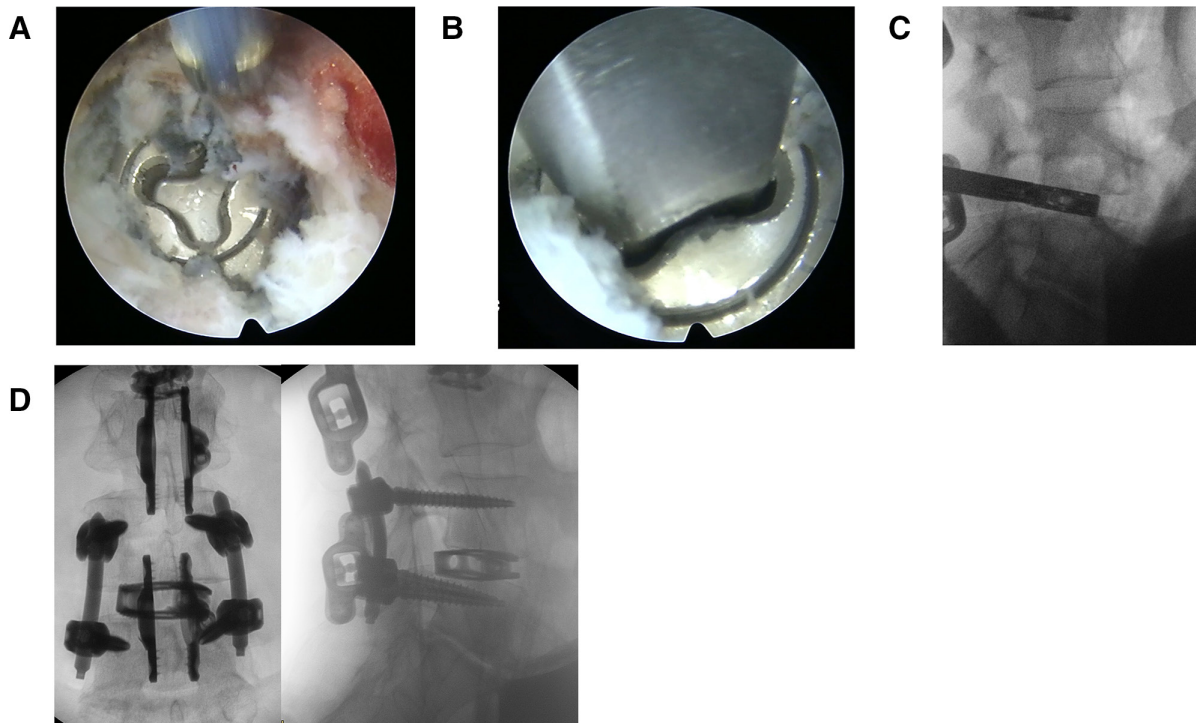


Figure 9. (A) An endoscopic view of a migrated titanium expandable cage. (B) An endoscopic view of the screwdriver docked into the mechanism of the expandable cage used to collapse the cage and reduce its footprint. (C) Fluoroscopic lateral intraoperative view of a forceps grasping the collapsed expandable cage. (D) Postoperative x-ray control images of the lumbar spine in anterior/posterior (left side) and lateral (right side) views with a large footprint expandable cage placed into L4-L5 and a posterior fixation.

However, sometimes an anterior approach is not possible, like that is in case 2, and an alternative revision surgery technique is required.

There have been previous attempts to employ endoscopic spine surgery for revision of a pseudarthrotic and/or migrated lumbar interbody cage: Telfeian et al²¹ reported successful revision endoscopic spine surgery for a case with pseudarthrosis after lumbar fusion. However, even though they endoscopically placed an additional interbody cage, they did not remove the pseudarthrotic PEEK cage. McGrath et al²² reported 3 cases with foraminal stenosis after lumbar fusion surgery. One of the reported cases presented a migrated lumbar cage that was partially resected with an endoscopic interlaminar approach. However, also in this study, the migrated interbody cage was not removed completely.

In this study, we have shown, to the best of our knowledge for the first time, the feasibility of full-endoscopic lumbar interbody cage removal using the trans-Kambin approach in 3 complex revision surgery cases with a pseudarthrotic and/or migrated interbody cage. Moreover, we also used the trans-Kambin approach to safely place a large footprint interbody device (39-mm length, 13-mm width, and 15-mm height after expansion). The full-endoscopic, trans-Kambin approach allowed

reducing invasiveness and bleeding with early postoperative ambulation and hospital discharge. The postoperative outcome after hospital discharge and at latest follow-up of all 3 cases improved significantly compared with preoperative scores.

Nonetheless, cases 2 and 3 presented with a postoperative, temporary radiculitis. The cause for the radiculitis is usually the irritation of the dorsal root ganglion. This can occur, especially, with excessive manipulation while trying to extract an interbody cage. Usually, this type of radiculitis will not be registered by neuromonitoring, as was the case here. There have been attempts to use direct stimulation inside Kambin's triangle to establish a safety threshold for endoscopic interbody fusion.^{23,24} However, literature is still scarce, and results are mostly experimental. Even though the described radiculitis was transitory and completely resolved after a few weeks, it is important to underline that exiting nerve root injury can occur while working in the neuroforamen, especially during the extraction of an interbody cage. Hence, an extensive foraminoplasty, either with manual reamers under fluoroscopic view (see Figure 6A) or with a high-speed drill under direct endoscopic view, is mandatory to protect the exiting nerve root. Here, we also introduced a special, patented sleeve to protect the

exiting nerve root during the removal of the interbody cage, see Figure 6A and D, and perform extensive disc preparation using standard instruments, that is, curettes, forceps, spoons, etc, used for open surgery. This sleeve also allowed us placing an expandable, large footprint interbody cage, see Figure 6D), overcoming one of the most important limitations of endoscopic fusion surgery which usually requires specialized small footprint interbody cages to fit through Kambin's triangle.^{7–12}

Nonetheless, case 2 also shows the current limitations of full-endoscopic endoscopic cage removal, as we were able to only partially remove an impacted interbody cage at L3-L4. Improved and specialized instruments are required to allow the removal of impacted interbody cages and other complex scenarios.

According to our preliminary results, full-endoscopic surgery can be effective for interbody cage removal in revision surgery cases, as it allows the following:

- avoiding posterior scar tissue, reducing the risk of intraoperative infection and dural tear (Figure 1)
- performing an extensive foraminoplasty to protect the exiting nerve root
- removing the migrated/pseudarthrotic cage under direct endoscopic view (especially in cases with an expandable interbody cage, the cage can be first collapsed under endoscopic view, thus reducing its footprint and, consequently, the risk of injury during its removal)
- minimally invasively placing an expandable, large footprint interbody cage into the disc using the same trans-Kambin approach, with minimal bleeding, a small skin incision, and early postoperative ambulation and hospital discharge

It should be noted that this full-endoscopic revision surgery should be performed by spine surgeons with extensive endoscopic training and experience.

CONCLUSION

This study shows the feasibility of full-endoscopic interbody cage removal, which could prove valuable, especially in cases for which an anterior and/or lateral approach is not possible. However, a prospective study with long-term follow-up is required before this technique is systematically used in clinical practice.

REFERENCES

1. Wu PH, Kim HS, Jang IT. A narrative review of development of full-endoscopic lumbar spine surgery. *Neurospine*. 2020;17(Suppl 1):S20–S33. doi:10.14245/ns.2040116.058

2. Khandge AV, Sharma SB, Kim JS. The evolution of transforaminal endoscopic spine surgery. *World Neurosurg*. 2021;145:643–656. doi:10.1016/j.wneu.2020.08.096

3. Gadraj PS, Broulikova HM, van Dongen JM, et al. Cost-effectiveness of full endoscopic versus open discectomy for sciatica. *Br J Sports Med*. 2022;56(18):1018–1025. doi:10.1136/bjsports-2021-104808

4. Morgenstern R, Morgenstern C, Yeung AT. The learning curve in foraminal endoscopic discectomy: experience needed to achieve a 90% success rate. *SAS J*. 2007;1(3):100–107. doi:10.1016/SASJ-2007-0005-RR

5. Choi G, Munoz-Suarez D. Transforaminal endoscopic thoracic discectomy: technical review to prevent complications. *Neurospine*. 2020;17(Suppl 1):S58–S65. doi:10.14245/ns.2040250.125

6. Wu PH, Kim HS, Lee YJ, et al. Posterior endoscopic cervical foraminotomy and discectomy: clinical and radiological computer tomography evaluation on the bony effect of decompression with 2 years follow-up. *Eur Spine J*. 2021;30(2):534–546. doi:10.1007/s00586-020-06637-8

7. Kim HS, Wu PH, Sairyo K, Jang IT. A narrative review of uniportal endoscopic lumbar interbody fusion: comparison of uniportal facet-preserving trans-kambin endoscopic fusion and uniportal facet-sacrificing posterolateral transforaminal lumbar interbody fusion. *Int J Spine Surg*. 2021;15(suppl 3):S72–S83. doi:10.14444/8166

8. Ishihama Y, Morimoto M, Tezuka F, et al. Full-endoscopic trans-kambin triangle lumbar interbody fusion: surgical technique and nomenclature. *J Neurol Surg A Cent Eur Neurosurg*. 2022;83(4):308–313. doi:10.1055/s-0041-1730970

9. Lee SH, Erken HY, Bae J. Percutaneous transforaminal endoscopic lumbar interbody fusion: clinical and radiological results of mean 46-month follow-up. *Biomed Res Int*. 2017;2017:3731983. doi:10.1155/2017/3731983

10. Morgenstern C, Yue JJ, Morgenstern R. Full percutaneous transforaminal lumbar interbody fusion using the facet-sparing, trans-kambin approach. *Clin Spine Surg*. 2020;33(1):40–45. doi:10.1097/BSD.0000000000000827

11. Morgenstern R, Morgenstern C. Percutaneous transforaminal lumbar interbody fusion (pTLIF) with a posterolateral approach for the treatment of degenerative disk disease: feasibility and preliminary results. *Int J Spine Surg*. 2015;9:41:41. doi:10.14444/2041

12. Nakamura S, Ito F, Ito Z, Shibayama M. Methods and early clinical results of percutaneous lumbar interbody fusion. *Neurospine*. 2020;17(4):910–920. doi:10.14245/ns.2040302.151

13. Kravtsov MN, Manukovsky VA, Bulyschenko GG, Mirzametov SD, Byvaltsev VA. Case report: full-endoscopic surgery for bullet wounds of the spine: a report of three cases. *Front Surg*. 2022;9:873365. doi:10.3389/fsurg.2022.873365

14. Krishnan A, Barot M, Dave B, et al. Percutaneous transforaminal endoscopic discectomy and drainage for spondylodiscitis: a technical note and review of literature. *J Orthop Allied Sci*. 2018;6(3):16. doi:10.4103/joas.joas_57_17

15. Ito M, Abumi K, Kotani Y, Kadoya K, Minami A. Clinical outcome of posterolateral endoscopic surgery for pyogenic spondylodiscitis: results of 15 patients with serious comorbid conditions. *Spine (Phila Pa 1976)*. 2007;32(2):200–206. doi:10.1097/01.brs.0000251645.58076.96

16. Şentürk S, Ünsal ÜÜ. Percutaneous full-endoscopic removal of lumbar intradural extramedullary tumor via translaminar approach. *World Neurosurg*. 2019;125:146–149. doi:10.1016/j.wneu.2019.01.206

17. Konakondla S, Sofoluke N, Xia J, et al. Transforaminal endoscopic approach for large-sample tumor biopsy using beveled working channel for core technique: a technical note. *World Neurosurg.* 2020;141:346–351. doi:10.1016/j.wneu.2020.05.096

18. Cho SK, Bridwell KH, Lenke LG, et al. Major complications in revision adult deformity surgery: risk factors and clinical outcomes with 2- to 7-year follow-up. *Spine (Phila Pa 1976).* 2012;37(6):489–500. doi:10.1097/BRS.0b013e3182217ab5

19. Faundez AA, Schwender JD, Safriel Y, et al. Clinical and radiological outcome of anterior-posterior fusion versus transforaminal lumbar interbody fusion for symptomatic disc degeneration: a retrospective comparative study of 133 patients. *Eur Spine J.* 2009;18(2):203–211. doi:10.1007/s00586-008-0845-0

20. Park MK, Kim KT, Bang WS, et al. Risk factors for cage migration and cage retropulsion following transforaminal lumbar interbody fusion. *Spine J.* 2019;19(3):437–447. doi:10.1016/j.spinee.2018.08.007

21. Telfeian AE, Moldovan K, Shaaya E, et al. Awake, endoscopic revision surgery for lumbar pseudarthrosis after transforaminal lumbar interbody fusion: technical notes. *World Neurosurg.* 2020;136:117–121. doi:10.1016/j.wneu.2020.01.048

22. McGrath LB, Madhavan K, Chieng LO, Wang MY, Hofstetter CP. Early experience with endoscopic revision of lumbar spinal fusions. *Neurosurg Focus.* 2016;40(2):E10. doi:10.3171/2015.10.FOCUS15503

23. Li Y, Wang MY. Safe electromyography stimulation thresholds within kamin's triangle during endoscopic transforaminal lumbar interbody fusion. *Neurosurgery.* 2022;91(1):150–158. doi:10.1227/neu.0000000000001959

24. Wang TY, Than KD. Commentary: safe electromyography stimulation thresholds within kamin's triangle during

endoscopic transforaminal lumbar interbody fusion. *Neurosurgery.* 2022;91(1):e5–e6. doi:10.1227/neu.0000000000002012

Funding: The authors received no financial support for the research, authorship, and/or publication of this article.

Declaration of Conflicting Interests: Christian Morgenstern reports consulting fees and royalties from Hoogland Spine Products GmbH and Signus Medizintechnik GmbH

Disclosures: C.M. reports consulting fees from Spineart SA as well as consulting fees and royalties from Hoogland Spine Products GmbH and Signus Medizintechnik GmbH. R.M. reports royalty fees from DePuy/Synthes and Interventional Spine Inc. and royalty fees from Joimax GmbH outside of the submitted work.

Corresponding Author: Christian Morgenstern, Morgenstern Institute of Spine, Centro Médico Quirón Teknon, C/ Vilana 12, 08022 Barcelona, Spain; info@morgenstern.es

Published 01 May 2023

This manuscript is generously published free of charge by ISASS, the International Society for the Advancement of Spine Surgery. Copyright © 2023 ISASS. To see more or order reprints or permissions, see <http://ijssurgery.com>.