INTERNATIONAL JOURNAL of SPINE SURGERY

Durotomy- and Irrigation-Related Serious Adverse Events During Spinal Endoscopy: Illustrative Case Series and International Surgeon Survey

Roth A.A. Vargas, Vincent Hagel, Zhang Xifeng, Huilin Yang, Jorge Felipe Ramírez León, Morgan Lorio, Albert E. Telfeian, Paul Houle, Raymond Gardocki, Álvaro Dowling, Paulo Sérgio Teixeira de Carvalho, Anthony Yeung, Martin Knight, Stefan Hellinger and Kai-Uwe Lewandrowski

Int J Spine Surg 2023, 17 (3) 387-398
doi: https://doi.org/10.14444/8454
https://www.ijssurgery.com/content/17/3/387

This information is current as of October 12, 2024.

Email Alerts Receive free email-alerts when new articles cite this article. Sign up at: http://ijssurgery.com/alerts

The International Journal of Spine Surgery
2397 Waterbury Circle, Suite 1,
Aurora, IL 60504, Phone: +1-630-375-1432
© 2023 ISASS. All Rights Reserved.
Downloaded from https://www.ijssurgery.com/ by guest on October 12, 2024

International Journal of Spine Surgery, Vol. 17, No. 3, 2023, pp. 387–398
https://doi.org/10.14444/8454
© International Society for the Advancement of Spine Surgery

Durotomy- and Irrigation-Related Serious Adverse Events During Spinal Endoscopy: Illustrative Case Series and International Surgeon Survey

ROTH A.A. VARGAS, MD[1]; VINCENT HAGEL, MD[2]; ZHANG XIFENG, MD[3]; HUILIN YANG, MD, PhD[4]; JORGE FELIPE RAMÍREZ LEÓN, MD[5,6,7]; MORGAN LORIO, MD[8]; ALBERT E. TELFEIAN, MD, PhD[9]; PAUL HOULE, MD[10]; RAYMOND GARDOCKI, MD[11]; ÁLVARO DOWLING, MD[12]; PAULO SÉRGIO TEIXEIRA DE CARVALHO, MD, PhD[13]; ANTHONY YEUNG, MD[14]; MARTIN KNIGHT, MD[15]; STEFAN HELLINGER, MD[16]; AND KAI-UWE LEWANDROWSKI, MD[17]

[1]Neurosurgeon, Department of Neurosurgery, Foundation Hospital Centro Médico Campinas, Campinas, SP, Brazil; [2]Asklepios Hospital Lindau, Spine Center, Lindau, Germany; [3]Department of Orthopedics, First Medical Center, PLA General Hospital, Beijing, China; [4]The First Affiliated Hospital of Soochow University, Suzhou, China; [5]Minimally Invasive Spine Center, Bogotá, DC, Colombia; [6]Reina Sofía Clinic, Bogotá, DC, Colombia; [7]Department of Orthopaedics, Fundación Universitaria Sanitas, Bogotá, DC, Colombia; [8]Advanced Orthopedics, Altamonte Springs, FL, USA; [9]Department of Neurosurgery, Rhode Island Hospital, The Warren Alpert Medical School of Brown University, Providence, RI, USA; [10]Boston University School of Medicine, Cape Cod Healthcare, Hyannis, MA, USA; [11]Vanderblit Orthopaedics, Nashville, TN, USA; [12]Department of Orthopaedic Surgery, USP, Ribeirão Preto, Brazil; [13]Pain and Spine Minimally Invasive Surgery Service at Gaffre e Guinle University Hospital, Rio de Janeiro, Brazil; [14]Desert Institute for Spine Care, Phoenix, AZ, USA; [15]The Weymouth Hospital, Weymouth, London; [16]Department of Orthopedic Surgery, Arabella Klinik, Munich, Germany; [17]Departmemt of Orthopaedics, Fundación Universitaria Sanitas, Bogotá, DC, Colombia

ABSTRACT

Background: Durotomy during endoscopic spine surgery can cause a patient's neurological or cardiovascular status to deteriorate unexpectedly intra- or postoperatively. There is currently limited literature regarding appropriate fluid management strategies, irrigation-related risk factors, and clinical consequences of incidental durotomy during spinal endoscopy, and no validated irrigation protocol exists for endoscopic spine surgery. Thus, the present article sought to (1) describe 3 cases of durotomy, (2) investigate standard epidural pressure measurements, and (3) survey endoscopic spine surgeons on the incidence of adverse effects believed to result from durotomy.

Materials and Methods: The authors first reviewed clinical outcomes and analyzed complications in 3 patients with intraoperatively recognized incidental durotomy. Second, the authors conducted a small case series with intraoperative epidural pressure measurements during gravity-assisted irrigated video endoscopy of the lumbar spine. Measurements were conducted on 12 patients with a transducer assembly that was introduced through the endoscopic working channel of the RIWOSpine Panoview Plus and Vertebris endoscope to the decompression site in the spine. Third, the authors conducted a retrospective, multiple-choice survey of endoscopic spine surgeons to better understand the frequency and seriousness of problems they attributed to irrigation fluid escaping from the surgical decompression site into the spinal canal and neural axis. Descriptive and correlative statistical analyses were performed on the surgeons' responses.

Results: In the first part of this study, durotomy-related complications during irrigated spinal endoscopy were observed in 3 patients. Postoperative head computed tomographic (CT) images revealed massive blood in the intracranial subarachnoid space, the basal cisterns, the III and IV ventricle, and the lateral ventricles characteristic of an arterial fisher grade IV subarachnoid hemorrhage, and hydrocephalus without evidence of aneurysms or angiomas. Two additional patients developed intraoperative seizures, cardiac arrhythmia, and hypotension. The head CT image in 1 of these 2 patients had intracranial air entrapment.

In the second part, epidural pressure measurements in 12 patients who underwent uneventful routine lumbar interlaminar decompression for L4-L5 and L5-S1 disc herniation showed an average epidural pressure of 24.5 mm Hg.

In the third part, the online survey was accessed by 766 spine surgeons worldwide and had a response rate of 43.6%. Irrigation-related problems were reported by 38% of responding surgeons. Only 11.8% used irrigation pumps, with 90% running the pump above 40 mm Hg. Headaches (4.5%) and neck pain (4.9%) were observed by nearly a 10th (9.4%) of surgeons. Seizures in combination with headaches, neck and abdominal pain, soft tissue edema, and nerve root injury were reported by another 5 surgeons. One surgeon reported a delirious patient. Another 14 surgeons thought that they had patients with neurological deficits ranging from nerve root injury to cauda equina syndrome related to irrigation fluid. Autonomic dysreflexia associated with hypertension was attributed by 19 of the 244 responding surgeons to the noxious stimulus of escaped irrigation fluid that migrated from the decompression site in the spinal canal. Two of these 19 surgeons reported 1 case associated with a recognized incidental durotomy and another with postoperative paralysis.

Conclusions: Patients should be educated preoperatively about the risk of irrigated spinal endoscopy. Although rare, intracranial blood, hydrocephalus, headaches, neck pain, seizures, and more severe complications, including life-threatening autonomic dysreflexia with hypertension, may arise if irrigation fluid enters the spinal canal or the dural sac and migrates from the endoscopic site along the neural axis rostrally. Experienced endoscopic spine surgeons suspect a correlation between

Downloaded from https://www.ijssurgery.com/ by guest on October 12, 2024

durotomy and irrigation-related extra- and intradural pressure equalization that could be problematic if associated with high volumes of irrigation fluid

Level of Evidence: 3.

Endoscopic Minimally Invasive Surgery

Keywords: Lumbar endoscopic surgery, irrigation flow and pressure, adverse events and complications

INTRODUCTION

There is anecdotal evidence of irrigation-related adverse events and complications after spinal endoscopy in patients with incidental durotomy. This modern version of minimally invasive spinal surgery is getting significant traction among a new generation of spine surgeons who are learning endoscopic procedures in their postgraduate training programs.[1,2] Leading endoscopic spine surgeons have emphasized that good clinical outcomes depend on mastering the learning curve.[3] Training and credentialing standards are evolving, and the debate on who should perform this minimally invasive spine operation continues. The growing number of endoscopic spine surgery procedures also increases awareness of its potential pitfalls and procedure-specific pearls and complications.[4]

This team of investigators suspected that the rate of unrecognized durotomy is higher than the 1% rate previously reported.[3] Several of the authors who have practiced endoscopic surgery for decades have observed rare but severe neurological and cardiovascular complications after endoscopic spine surgery that they associate with durotomy. Stipulating that intradural spread of irrigation fluid caused the observed hypertensive episodes, seizures, neurological deficits, and cauda equina syndrome or could even be responsible for milder symptoms, including spinal headaches and neck pain suggestive of unrecognized smaller durotomies, they performed epidural pressure measurements. They also solicited information regarding irrigation-related adverse events and complications experienced by other endoscopic spine surgeons via a survey application.

Because the irrigation fluid is clear, the surgeon cannot easily assess its flow pattern and direction intraoperatively. Only limited and indirect intraoperative assessments can be made by observing, for example, the quantity and vector of bleeding from epidural vessels or the magnitude of the movement of intrathecal rootlets within the semitransparent nerve sac. Following the flow patterns of blood leaking from small epidural vessels is the most useful intraoperative tool allowing the surgeon to determine at least the flow direction if one considers them the equivalent of small dye injectors used in aero- or fluid-dynamics study of objects. Other helpful tell-tale signs are the direction and extent of rootlet herniations in and out of the dural sac through an incidental durotomy or annular fibers through an annular tear.

The literature on fluid management and irrigation-related problems during lumbar spinal endoscopy is scarce. Therefore, the authors provide the reader with a detailed description of the symptoms and clinical course of a small case series of patients who had severe complications that were proven to be related to the intradural spread of irrigation fluid through incidental durotomy and results of intraoperative epidural pressure measurements taken at the surgical decompression site in the spine. Furthermore, the authors report the results of a survey of busy endoscopic spine surgeons regarding their usage patterns and any problems they perceived related to irrigation fluid. Ultimately, the authors were interested in alerting unsuspecting and novice endoscopic spine surgeons to the potential for sudden and unexpected severe intra- and postoperative decline of neurological and cardiovascular function in patients with intradural spread of irrigation fluid irrespective of whether a durotomy was encountered or not.

CASE EXAMPLES OF DUROTOMY AND IRRIGATION-RELATED ADVERSE EVENTS

The first and senior author encountered several patients undergoing routine endoscopic decompression surgery of the spine in whom the intradural spread of irrigation fluid through an incidental durotomy caused neurological and cardiovascular complications. For example, neck pain, headache, and diplopia were reported by a 52-year-old woman who underwent routine interlaminar C6-C7 endoscopic decompression for unrelenting arm pain due to disc herniation. The patient suffered from severe C7 radiculopathy, with a 3/5 reduction of motor strength in the wrist extensors with associated decreased sensation in the ulnar forearm. The preoperative magnetic resonance images showed a C6-C7 posterolateral disc herniation with apparent root compression (Figure 1). The patient underwent a full-endoscopic posterior interlaminar decompression following the technique described by Ruetten et al.[5–7] The patient was prone and operated on under general anesthesia with endotracheal intubation. The distorted exiting C7 nerve root was decompressed by removing the ventrally located disc fragment. During the operation, it was challenging to control the bleeding. A small 3-mm lesion in the dura mater was noted. The first author and primary surgeon partially

Downloaded from https://www.ijssurgery.com/ by guest on October 12, 2024

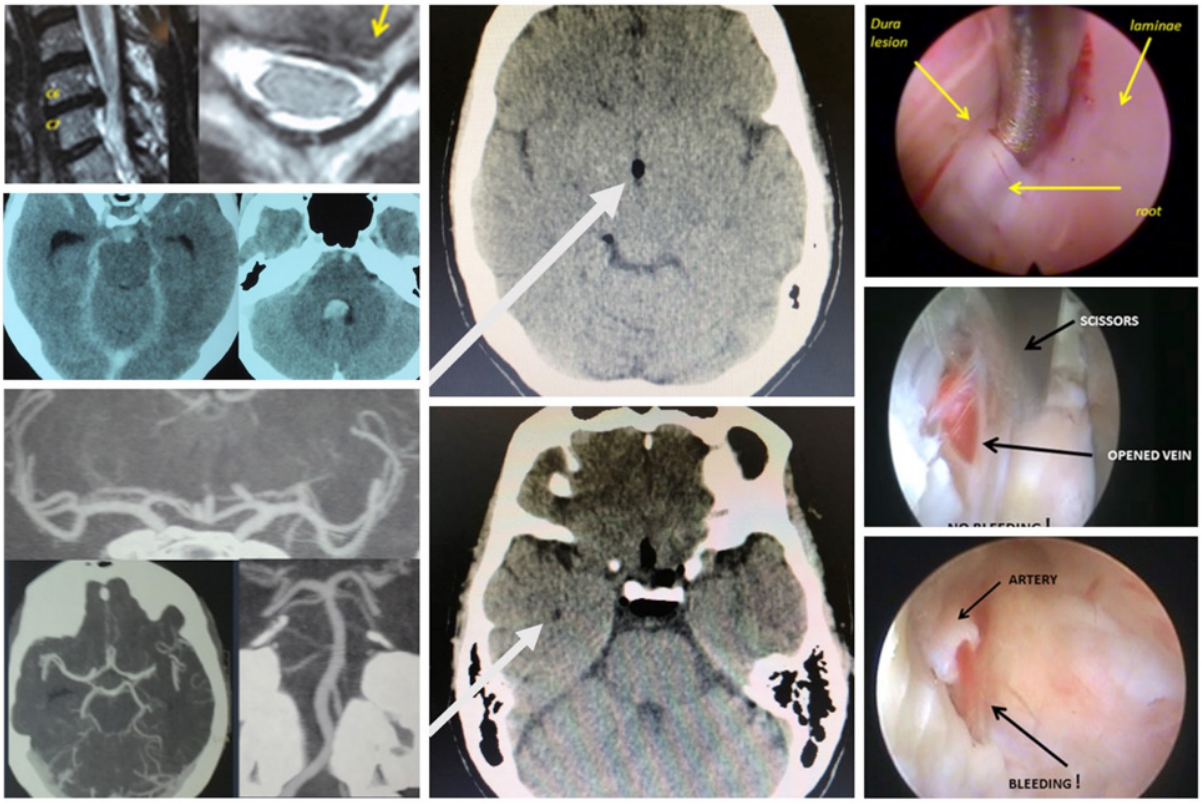

Figure 1. Shown are examples of postoperative scans and videoendoscopic views of patients with incidental durotomy and neurological complications following gravity-irrigated interlaminar full-endoscopic spinal endoscopy. The left column shows a postoperative sagittal and an axial magnetic resonance imaging of the cervical spine of a 52-y-old female patient demonstrating hemorrhage spreading anteriorly and laterally distant from the posterior decompression site. The head computed tomography (CT) revealed massive blood in the subarachnoid space and the basal cisterns, the III, IV, and lateral ventricles, and ventricular dilatation consistent with hydrocephalus and arterial subarachnoid Fisher grade IV hemorrhage. However, the CT angiography of the head via femoral catheterization did not reveal any bleeding from possible vascular malformation such as an aneurysm or angioma or any source suggesting that the blood traveled with the irrigation fluid rostrally and intracranially. The center column shows head CT images of ar male patient who underwent lumbar L4-L5 interlaminar gravity-irrigated full-endoscopic decompression surgery with an incidental lumbar durotomy. This patient developed intraoperative seizures, cardiac arrhythmia, and hypotension. His head CT showed intracranial air entrapment. Both illustrated patients were medically stabilized and discharged from the hospital 10 and 3 days postoperatively, respectively. Images in the right column show an exemplary incidental lumbar durotomy that was recognized in the second patient. Consistent with the observed pressure gradients, injury to an epidural vein typically may not cause much bleeding compared with bleeding from an injured arterial vessel.

attributed it to poor visualization because of uncontrolled bleeding. The bleeding was effectively controlled with bipolar coagulation. A dural repair was not deemed necessary after the decompression.

Postoperatively, the patient complained of neck pain, headache, and diplopia. Neurological examination revealed a paresis of the right-sided lateral rectus muscle suggestive of a nervus abducens paresis. The motor weakness in the right arm initially persisted. A postoperative head computed tomography revealed massive blood in the intracranial subarachnoid space, the basal cisterns, the III and IV ventricle, the lateral ventricles characteristic of an arterial fisher grade IV subarachnoid hemorrhage, and hydrocephalus. Cerebral angiography through femoral catheterization did not reveal the presence of aneurysms, angiomas, or any other source of intracranial bleeding (Figure 1). The patient was hospitalized for 10 days for supportive care. Symptoms eventually resolved. Two additional male patients with incidental lumbar durotomy developed intraoperative seizures, cardiac arrhythmia, and hypotension. On a head computed tomography image, 1 of the 2 latter patients had intracranial air entrapment. These 2 patients were medically stabilized and discharged from the hospital 3 days postoperatively (Figure 1).

MATERIALS AND METHODS

Epidural Pressure Measurements

For epidural pressure measurements, a Baxter 2-way arterial line kit with a transducer assembly was introduced through the endoscopic working channel of the RIWOSpine Panoview Plus and Vertebris endoscope to the decompression site in the spine. Epidural pressure measurements were conducted on another 12 patients who underwent routine L4-L5 and L5-S1 endoscopic discectomy. All measurements were done without an irrigation pump but with a gravity-assisted system positioning

Downloaded from https://www.ijssurgery.com/ by guest on October 12, 2024

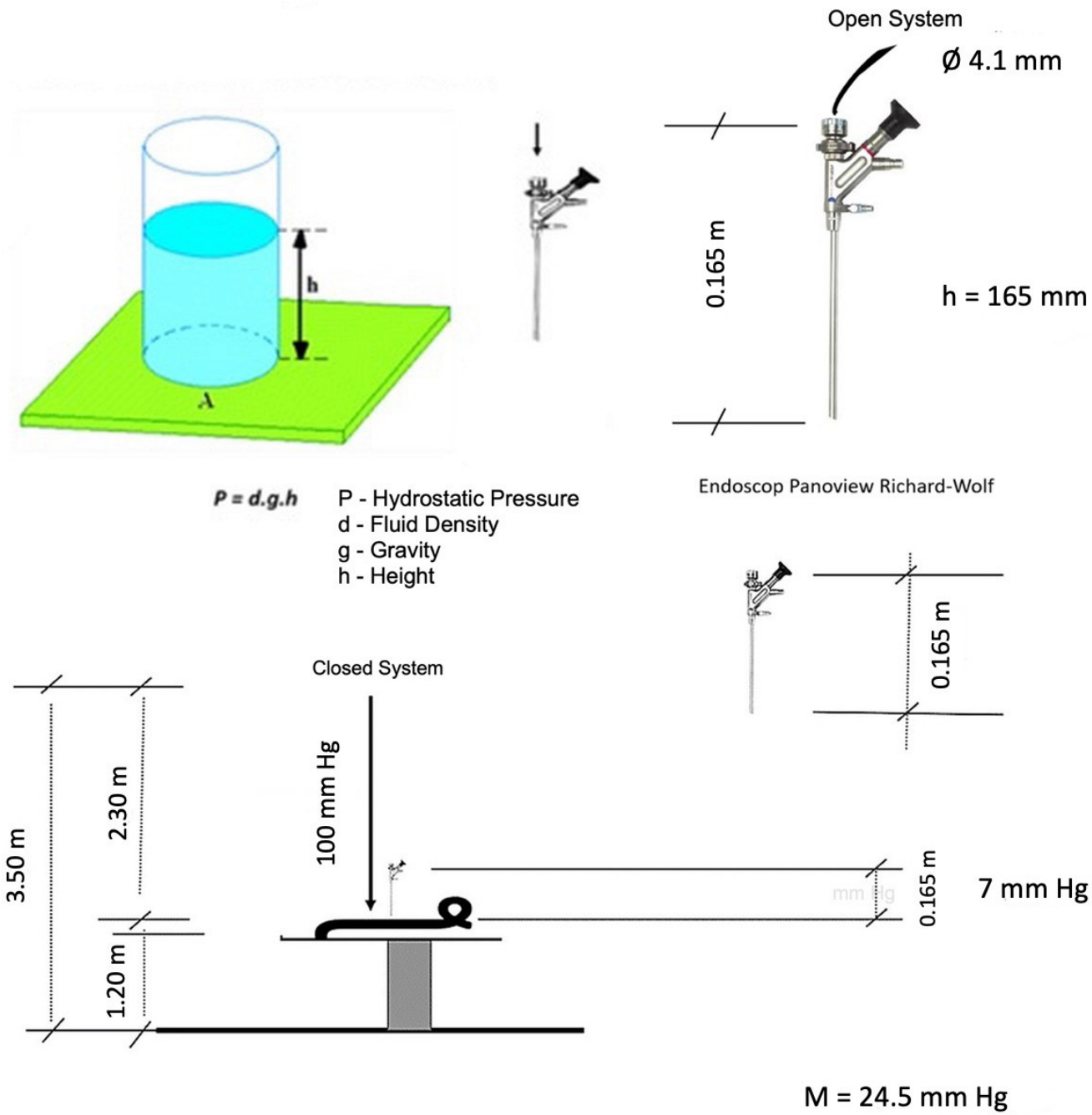

Figure 2. The hydrostatic pressure of a static fluid column varies with the height of the liquid column (h), the viscosity or density (d) of the fluid, and the force of gravity (g). It does not depend on area (A) or the shape of the liquid column. For the intraoperative hydrostatic pressure measurements during full-endoscopic lumbar spinal surgery, 2 L bags of physiological saline were hung 2.30 m above the patient and 3.50 m above the floor, considering the height of the operating table of 1.20 m. The fluid bags were connected with flexible tubing via a 2-way connector to the endoscope (Panoview Plus 25°, length 165 mm, working channel Ø 4.1 mm Richard-Wolf Vertebris). The Baxter transducer assembly was registered at the height of the physiological saline bags at 3.50 m. An irrigation pump was not used to ensure that the hydrostatic pressure column remained constant throughout the intraoperative epidural hydrostatic pressure measurements.

the fluid bags at a 2.3-m height above the level of the patient (Figure 2). For result interpretation, the authors considered the occurrence of the Venturi effect, which explains the expected reduction in fluid pressure that results when a fluid flows through a constricted section (or choke) of a pipe (Figure 3). In a gravity-assisted fluid irrigation system, a further decrease in the downstream pressure environment would not be expected to increase velocity unless the fluid is compressed.[8,9]

Surgeon Survey

The authors sent an online survey (Typeform) to 766 prospective respondent surgeons via email, chat

Downloaded from https://www.ijssurgery.com/ by guest on October 12, 2024

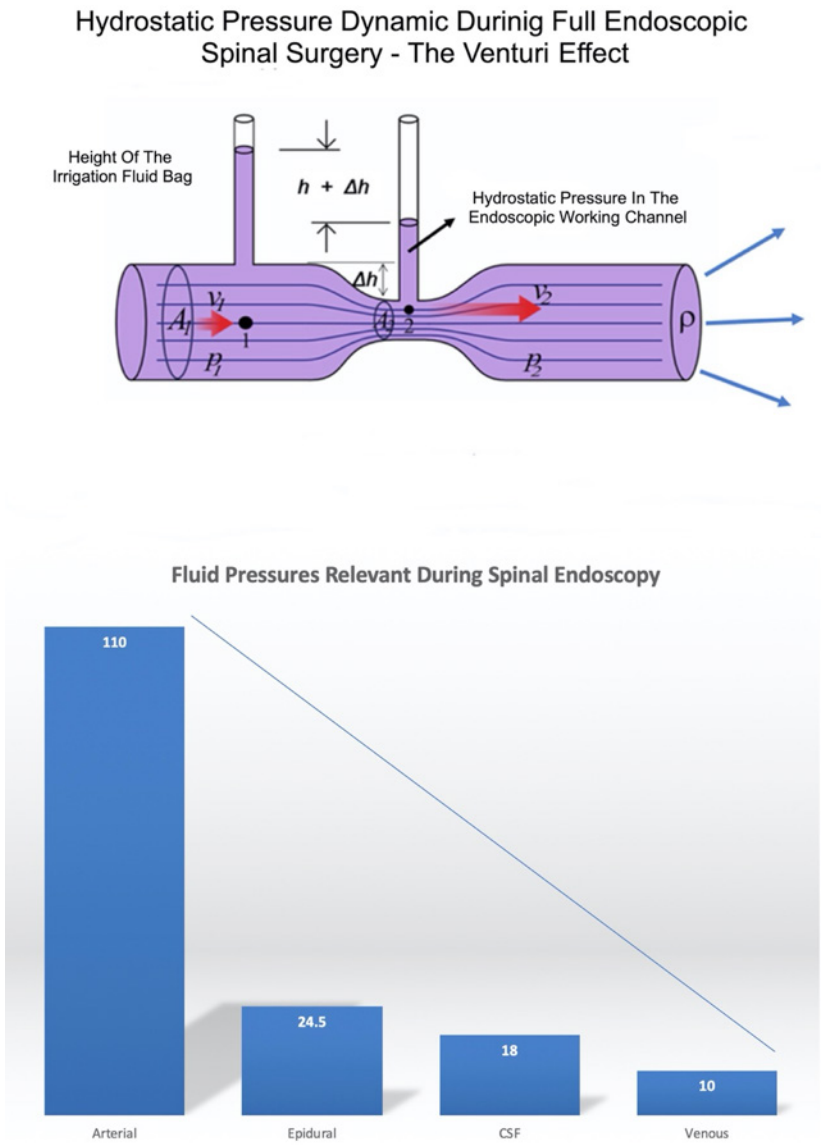

Figure 3. The difference in the hydrostatic pressure measurement between the measurement on the back of the patient (103 mm Hg) and the average epidural pressure measured of 24.5 mm Hg is due to the occurrence of a Venturi effect, which is illustrated in the top panel as a reduction in fluid pressure that results when a fluid flows through a constricted section (or choke) of a pipe (top panel). In a typical gravity-assisted tubing set-up for spinal endoscopy, this occurs as the fluid runs from the back through the tubing system into the narrow irrigation channel of the spinal endoscope and then into the epidural space and from there runs out through the larger working channel of the endoscope (Ø 4.1 mm). Considering the choked flow in an open system gravity-assisted irrigation setup during spinal endoscopy, various diameter changes occur as the fluid runs through it, and the fluid velocity approaches the local speed of sound. When a liquid system is in a state of choked flow, a further decrease in the downstream pressure environment will not increase velocity unless the fluid is compressed. Our measurements revealed an average drop of 78.5 mm Hg from the initial hydrostatic pressure of 103 mm Hg at the patient level before entering the spinal endoscope down to 24,5 mm Hg in the epidural space. The average epidural hydrostatic pressure of 24.5 mm Hg was higher than the reported intradural cerebrospinal fluid (CSF) or intravenous pressures (bottom panel).

groups on social networks, and messenger apps such as WhatsApp. Surgeons were asked to answer 14 clinical multiple-choice questions regarding their utilization of irrigation systems during routine lumbar endoscopy. Responding spine surgeons were also asked to provide demographic information regarding their practice setting, type, and extent of postgraduate training and endoscopic surgery experience. To improve the survey completion rate, minimize the impact of geographic bias, and overcome language barriers, the survey questions were written by this international team of authors in English and Chinese. The survey ran from 18 October to 28 October 2022. The authors were blinded to the responding surgeons' identity.

Upon termination of the survey, responses were downloaded in an Excel file format and imported into IBM SPSS (version 27) statistical software package for further data analysis. Descriptive statistic measures were used to count responses and calculate the means, ranges, SDs, and percentages. χ^2 statistics were used

Downloaded from https://www.ijssurgery.com/ by guest on October 12, 2024

Table 1. Hydrostatic epidural pressure measurements in patients who underwent routine L4-L5 and L5-S1 interlaminar full-endoscopic discectomy.

Patient	Gender	Age, y	Weight, kg	Measured Hydrostatic Pressure, mm Hg
1	M	54	82	26.5
2	M	62	71	20.0
3	F	46	131	22.5
4	M	65	92	26.0
5	M	72	86	23.0
6	F	58	61	29.0
7	F	51	65	20.0
8	F	46	90	28.0
9	M	39	78	23.5
10	M	40	89	21.0
11	M	36	70	29.0
12	M	52	62	25.5

Abbreviations: F, female; M, male.

to determine the strength of the association between factors. Missing answers were included for accurate percentage calculation and are listed at the top of each data table. Wherever applicable, a *P*-value of 0.05 or less was considered statistically significant, and a confidence interval of 95% was employed for all statistical tests.

RESULTS

Hydrostatic Epidural Pressure Measurements

The results of the hydrostatic epidural pressure measurements in 12 patients who underwent routine L4-L5 or L5-S1 are listed in Table 1. The hydrostatic epidural pressure ranged from 20.0 to 29 mm Hg and averaged 24.5 mm Hg. The hydrostatic pressure delivered to the endoscope by the gravity-assisted irrigation setup via the irrigation tubing from a total height of 3.5 m to the level of the patient at 1.2 m averaged 103 mm Hg (Figure 2). Our measurements revealed an average drop of 78.5 mm Hg from this initial hydrostatic pressure at the patient level before entering the spinal endoscope down to 24.5 mm Hg in the epidural space.

Surgeon Survey

A total of 766 spine surgeons accessed the online survey. Of those, 44 submitted a valid survey in English at a completion rate of 43.1 % (Figure 4A). Two hundred submitted a valid survey in Chinese at a completion rate of 44.0% (Figure 4B). The demographics of the responding surgeons are shown in Table 2. The majority were orthopedic spine surgeons (86.1%), followed by neurosurgeons (6.5%) and pain management physicians (5.7%). Nearly half (49%) of all respondents indicated that up to 40% of their practice was entirely dedicated to endoscopic spine surgery. Most Asian-responding surgeons were hospital employed, whereas most European and Latin American surgeons were either in private practice or in private practice with an academic appointment at a university (Table 2). Approximately one-fifth (21.7%) of respondents had up to 4 years of clinical experience with lumbar spinal endoscopy, and more than half (53.2%) practiced this minimally invasive spinal surgery technique for 10 years or less (Table 3). The remaining 25% of surgeons had more than 10 years of professional experience with the endoscopic spinal surgery platform. Orthopedic spine surgeons and pain management physicians had significantly more experience than neurosurgeons (Pearson $\chi^2 = 125.896$, $df = 84$, $P = 0.002$), with the majority having performed lumbar endoscopy between 5 and 10 years compared with neurosurgeons with 3 to 5 years of hands-on experience. The majority of surgeons resided in China (78%), followed by Brazil (7.8%), Mexico (2.4%), Germany (2.0%), Colombia (1.2%), Thailand (1.2%), and the United States (1.2%). The remaining responding surgeons (3.2%) were from Angola, Canada, Chile, Croatia, Ecuador, South Korea, and the United Kingdom.

Only 4 Chinese surgeons admitted using an irrigation pump during spinal endoscopy. Another 186 Chinese surgeons indicated that they performed this surgery by using gravity-assisted irrigation. The use of an irrigation pump (25 respondents) vs gravity-assisted irrigation (29 respondents) was split relatively evenly without any statistically significant difference between surgeons from Europe, North and Latin America, and all other Asian countries. Sixteen surgeons (6.5%) admitted to using the pump's leveling function, and another 19 (7.8%) surgeons admitted that they have the pump positioned at the same level as the patient. Twelve percent of all responding surgeons indicated a pump-irrigation pressure setting of 40 mm Hg or higher during routine lumbar endoscopy. The highest pressure setting given by 1 surgeon was 110 mm Hg. The commonly reported flow rate was 0.4 L/min. Half of the pump users indicated using different pump settings for interlaminar and transforaminal endoscopic discectomy vs stenosis decompression. Nonpump users were unaware of the pressure and flow scenarios played out during their endoscopic lumbar spine surgeries.

Over one-third of surgeons (38%) reported that some patients experienced adverse events or complications during routine irrigated lumbar endoscopic spine surgery. Headaches (4.5%) and neck pain (4.9%) were reported as having been observed by nearly a 10th (9.4%) of surgeons (Table 4). However, 5 surgeons reported having witnessed seizures in combination with

Downloaded from https://www.ijssurgery.com/ by guest on October 12, 2024

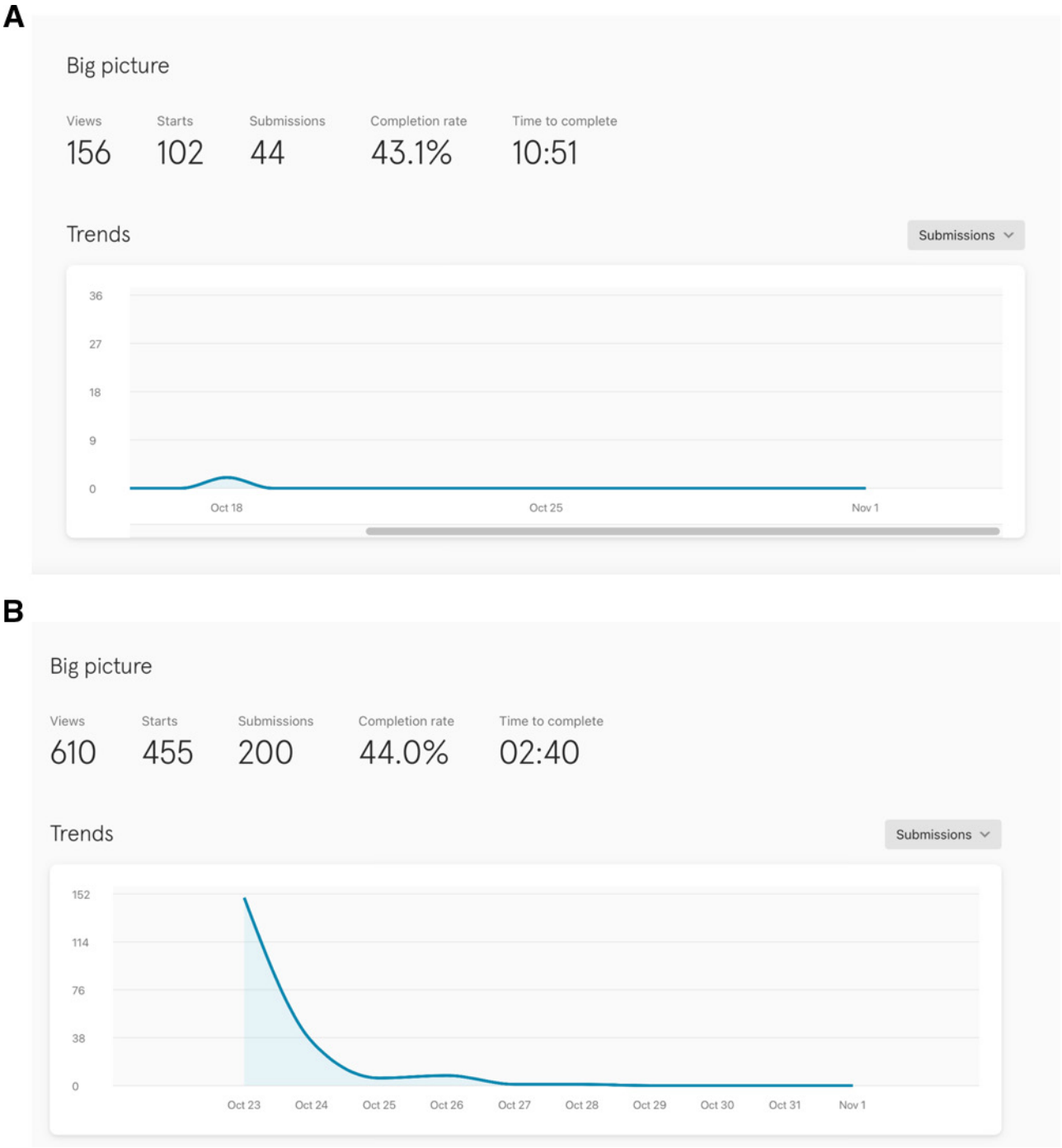

Figure 4. Seven hundred sixty-six spine surgeons accessed the online survey. Forty-four submitted a valid survey recording in English at the completion rate 43.1% (A—top panel). Two hundred submitted a valid survey recording at a completion rate of 44.0% (B—bottom panel).

headaches, neck and abdominal pain, soft tissue edema, and nerve root injury, and another surgeon reported having seen a delirious patient postoperatively, which they also attributed to excessive irrigation of the spinal canal during the lumbar endoscopic decompression surgery. Another 14 surgeons reported irrigation-related neurological deficits ranging from postoperative symptomatic nerve root injury to cauda equina syndrome. Incidental durotomy was also reported as associated with overutilization of irrigation during prolonged surgeries. Five surgeons thought that the risk of neurological deficits is higher when dural tears occur during irrigated directly visualized lumbar endoscopy. Autonomic spinal dysreflexia associated with hypertension was reported by 19 of the 244 responding surgeons. Two of these 19 surgeons reported 1 case associated

Downloaded from https://www.ijssurgery.com/ by guest on October 12, 2024

Table 2. Training, experience, and practice setting of responding spine surgeons.

Question	*n*	%	Cumulative %
What is your postgraduate training background?			
Missing response	1	0.4	.4
Not applicable	2	0.8	1.2
Neurosurgeon	16	6.6	7.8
Orthopedic surgeon	211	86.5	94.3
Pain management	14	5.7	100.0
Total	244	100.0	
What percentage of your practice is endoscopic spine surgery?			
0%	3	1.2	1.2
1%–5%	26	10.7	11.9
5%–20%	61	25.9	70.5
21%–40%	59	24.2	36.1
41%–60%	23	9.4	45.5
61%–80%	34	13.9	84.4
81%–100%	38	15.6	100.0
Total	244	100.0	
What is your practice setting?			
Employed by large physician group	5	2.0	2.0
Hospital employed	187	76.6	78.7
Private practice	30	12.3	91.0
Private practice with academic appointment	12	4.9	95.9
University employed	10	4.1	100.0
Total	244	100.0	

with an incidental durotomy and another with postoperative paralysis. Five surgeons reported irrigation-related adverse events that were ultimately of no consequence. These ranged from soft tissue edema to prolonged anesthesia recovery and epidural hematoma.

χ^2 cross-tabulation testing could not establish a statistically significant association between the use of gravity vs irrigation pump and complications (P = 0.581). There was a statistically significant association between self-reported adverse events and complications and training background (Pearson $\chi^2 = 248.319$, $df = 10$, $P < 0.001$). The ratio of responding orthopedic surgeons to neurosurgeons was 13.19:1 and to pain management physicians was 15.07:1. Cross-tabulating training and years of practicing endoscopic spine surgery, the majority of irrigation-related complications were reported by surgeons with less than 6 years of hands-on experience. They were less frequently reported by surgeons with more than 6 years of experience at a statistically significant level (Pearson $\chi^2 = 55.792$, $df = 30$, $P = 0.003$).

Table 3. Demographic data of responding spine surgeons.

Question	*n*	%	Cumulative %
Years performing spinal endoscopy			
0	3	1.2	1.2
1–4	50	20.5	21.7
5	53	21.8	43.5
6	23	9.4	52.9
7	20	8.2	61.1
8	25	10.2	71.3
9	9	3.7	75.0
10–32 y	60.0	25.0	100.0
Total	244	100.0	
Country			
Missing response	6	2.5	2.5
Angola	1	0.4	2.9
Brazil	19	7.8	10.7
Canada	1	0.4	11.1
Chile	2	0.8	11.9
China	191	78.3	90.2
Colombia	3	1.2	91.4
Croatia	1	0.4	91.8
Ecuador	1	0.4	92.2
Germany	5	2.0	94.3
Mexico	6	2.5	96.7
South Korea	1	0.4	97.1
Thailand	3	1.2	98.4
United Kingdom	1	0.4	98.8
United States	3	1.2	100.0
Total	244	100.0	

DISCUSSION

The unexpected dramatic clinical course of 3 patients in whom the observed problems were attributed to the intradural spread of irrigation fluid, blood, and air through an incidental durotomy motivated the authors to report their experience, perform intraoperative hydrostatic epidural pressure measurements, and survey their peers to inquire about their experience with the problem. The 3 illustrative cases described in this article corroborate the authors' opinion that irrigation in combination with a durotomy may be associated with a higher risk of neurological and cardiovascular complications that could blindsight the endoscopic spine surgeon if the surgeon is unprepared to manage this rare event. The authors observed intracranial blood, hydrocephalus, headaches, neck pain, seizures, and more severe complications, including life-threatening autonomic dysreflexia with hypertension. It is conceivable that irrigation fluid enters the spinal canal or the dural

Downloaded from https://www.ijssurgery.com/ by guest on October 12, 2024

Table 4. Adverse events and complications related to irrigation during lumbar spinal endoscopy reported by responding spine surgeons.

Adverse Events or Complications	*n*	%	Cumulative %
None	172	70.5	70.5
Headaches and seizures			
Headache	11	4.5	75
Headache and seizure	2	0.8	75.8
Headache and seizure, and abdominal pain	1	0.4	76.2
Headache and seizure, nerve root injury	1	0.4	76.6
Headache, neck pain	3	1.2	77.8
Neck pain and seizures			
Neck pain	12	5	82.8
Neck pain and seizure	1	0.4	83.2
Neck pain and seizure, soft tissue edema	1	0.4	83.6
Neck pain and stiffness	1	0.4	84
Neck pain, delirium	1	0.4	84.4
Nerve damage and neurological deficit			
Nerve root injury	3	1.2	85.6
Nerve root injury, infection	1	0.4	86
Nerve root injury, seizure	1	0.4	86.4
Dural edema	1	0.4	86.8
Numbness in lower extremities	2	0.8	87.6
Durotomy	5	2	89.6
Cauda equina syndrome	1	0.4	90
Autonomic dysreflexia with hypertension			
Autonomic dysreflexia with hypertension	17	7.2	97.2
Durotomy, headache, and autonomic dysreflexia with hypertension	1	0.4	97.6
Paralysis, autonomic dysreflexia with hypertension	1	0.4	98
Other adverse events			
Prolonged wakeup from general anesthesia	1	0.4	98.4
Prolonged postoperative recovery due to hypovolemia	17	0.4	98.8
Soft tissue edema	2	0.8	99.6
Epidural hematoma	1	0.4	100
Missing response	1	0.4	100.4
Total	244	100.0	

[a]The cumulative total exceeds 100 due to rounding.

sac via a durotomy and migrates from the endoscopic site along the neural axis rostrally. This experienced author team of endoscopic spine surgeons suspects that a correlation between durotomy and irrigation-related extra- and intradural pressure equalization exists that could be particularly problematic if associated with high volumes of irrigation fluid or prolonged operative times. It is also possible that the actual rate of durotomy with interlaminar endoscopic decompression surgery is higher than recognized and previously reported. The authors' survey data appear to support this notion.

The authors' practical experience is that excessive or prolonged irrigation at high flow rates and pressures appears to be associated with headaches, neck pain, prolonged anesthesia wakeup, and in worse cases, seizures, nerve injury, and neurological deficit when associated with durotomies. For that reason, many of this article's surgeon authors do not use irrigation pumps because in an open system, such pumps would virtually guarantee higher fluid pressures and velocities. In this context, the novice may assume that gravity-assisted irrigation endoscopy may result in lower pressure and flow scenarios than irrigation pumps or that irrigation pumps can maintain the irrigation pressure constantly. We know these assumptions are false from shoulder and knee arthroscopy studies.[10] In a gravity-feed setup, a 4 L bag of saline is typically hung at 5 to 6 feet above the patient's surgical site, producing a starting pressure in a large joint of approximately 120 mm Hg.[11,12] However, the pressure will bleed off as soon as the fluid begins to run through the semiclosed tubing system in and out of the joint. In shoulder and knee arthroscopy, a modest outflow was shown to reduce the starting pressure by approximately 70 mm Hg, yielding an intra-articular working pressure of about 50 mm Hg.[10] Nowadays, the latter is considered the sweet spot between safety and visualization for large joint arthroscopy.

Fluid mechanics principles dictate that the pressure in static fluids, that is, nonmoving—tubing clamped or pump in the off position, is constant and higher. In dynamic flow scenarios, that is, tubing open or pump running, true pressures will drop drastically and quickly as there is an outflow from the surgical site. In addition, frictional reduction in flow and pressure also adds to this well-documented phenomenon, which is also consistent with the Venturi effect[13] in choked systems discussed earlier.[12] The initial pressure reduction from the fluid reservoir to the surgical site in gravity-assisted large joint

Downloaded from https://www.ijssurgery.com/ by guest on October 12, 2024

arthroscopy and spinal endoscopy systems is similar and on the order of 75 mm Hg. This can likely be explained by the fact that the tubing systems are very similar. In a gravity-assisted fluid irrigation system, such as ours, the hydrostatic pressure drop from the elevated fluid reservoir to the epidural decompression site was 78.5 mm Hg to an average epidural hydrostatic pressure of 24.5 mm Hg. In contrast, many pumps exhibit a sinusoidal pressure wave pattern,[10] often decreasing the average intraoperative pressure compared with gravity-feed setups, where escape of irrigation fluid from the surgical site reportedly is more frequent when combined with long surgery time because of higher average pressures.[12]

The purpose of using irrigation fluid during spinal endoscopy is to improve visualization and control bleeding by managing the hydrostatic pressure at the decompression site.[14] However, increasing the space available for the neural elements as a result of a successful endoscopic decompression of a lumbar spinal motion segment could allow the irrigation fluid to enter the spinal canal.[15,16] From there, it can travel caudally, where it can cause lower motor neuron symptoms, as reported by several surgeons in the form of nerve root injury and cauda equina syndrome. It can also travel rostrally and cause upper motor neuron symptoms, as reported by at least 1 surgeon who admitted to having a case of paralysis. In 1 reported case, irrigation fluid has even been found as free fluid in the abdominal cavity.[17] Another investigative team expressed their concern of undue intracranial pressure increases during biportal endoscopic spinal surgery and measured the cervical epidural pressure as a proxy in a limited scope study of 20 patients. However, none of their patients had any neurological deficits.[18]

In an attempt to better formalize the use of irrigation during spinal endoscopy, the authors were interested in determining (1) whether other spine surgeons also encounter these problems; (2) what the usage patterns are regarding pump- or gravity-assisted irrigated endoscopic decompression surgeries; (3) what the commonly used flow and pressure settings are, if any; (4) whether there is any association between irrigation-induced problems and experience or skill level, implying that more prolonged or more complex surgeries may put the patient at increased risk; and, finally, (5) whether there are, perhaps, any clinically relevant irrigation technology parameters that should be further investigated to arrive at best practice recommendations for their application in lumbar spinal endoscopy?

While specific established standards exist for large joint arthroscopy,[19] this latter question has yet to be answered in the clinical context of cervical and lumbar spine endoscopy to avoid adverse events and complications. In reality, some spine surgeons may use automated irrigation pumps designed for large joints at standard flow and pressure settings for knee or shoulder arthroscopy. Other spine surgeons may not use an irrigation pump specifically designed for spinal endoscopy. What our survey showed though is that the vast majority of spine surgeons do not use irrigation pumps and prefer gravity-assisted irrigation during their lumbar endoscopy. In some cases, spine surgeons add a level 1 pressure device to their gravity-assisted system to temporarily increase the flow and velocity of the irrigation fluid manually. However, pure gravity-assisted irrigation setups are unlikely to cause high peak pressure and flow scenarios due to the choke effect (Venturi effect), where reduction in hydrostatic pressure is to be expected when the irrigation fluid flows through constricted sections (or choke) in the spinal endoscope.

Irrigation-related problems were reported by 38% of responding surgeons. The majority of surgeons used normal saline (94.3%). Only 11.8% of responding surgeons used irrigation pumps, with 90% running the pump above 40 mm Hg. Therefore, it is reasonable to assume that most of our survey respondents have their foundation in the hydrostatic epidural pressure range observed in our measurements ranging from 20 to 29 mm Hg and averaging 24.5 mm Hg, as dictated by the Venturi effect. The survey reached far more orthopedic spine surgeons than neurosurgeons or pain management physicians. Orthopedic surgeons also had statistically significantly more professional experience with endoscopic surgery—on average, 5 to 10 years—compared with their neurosurgeon counterparts, who averaged 3 to 5 years. Hence, most of the irrigation-related adverse events and complications were reported by orthopedic surgeons. This observation could be related to more complex decompression surgeries with, perhaps, a higher rate of unrecognized incidental durotomy being performed by these more experienced surgeons. They also indicated that a higher percentage of their practice was dedicated to endoscopic surgery—more than 40% according to more than half of the respondents. Another third (29.4%) of surgeons performed between 60% and 100% of their surgeries endoscopically. It is conceivable that these endoscopy enthusiasts attempt to treat more complex problems that are more difficult to address endoscopically, require a higher skill level, and therefore may take longer, are inherently riskier, and use more fluid.

Downloaded from https://www.ijssurgery.com/ by guest on October 12, 2024

Limitations

Unfortunately, our retrospective survey data cannot account for surgical time, patient mean arterial pressure, or procedure complexity. Another limitation of our hydrostatic epidural pressure measurements with a gravity-assisted irrigation setup is the small number of patients in whom they were performed. Nonetheless, the survey data suggest that the majority of surgeons use gravity-assisted irrigation. Therefore, a pressure recommendation for pump-irrigation setups cannot be made from our studies. Real-world scenarios are likely much more complex. They cannot be reduced to a simple pressure recommendation.[12] Pressure at the lumbar decompression site is only 1 aspect to be considered in any problem-solving algorithm. Surgical time, canal opening, patient blood pressure fluctuations, and intraoperative recognition of dural and nerve root injuries are also relevant in predicting fluid complications in spinal endoscopy. An experienced surgeon-anesthesiologist team should rely on protocol-driven and interactive choreography between direct visualization of intraoperative pathology and its associated complications while conversing with the patient who is managed with local anesthesia. Sedation and adaptive surgical care may be required if intraoperative problems are encountered to minimize their negative impact postoperatively.[20–26] Only a prospective study examining the true intraoperative pressure data while controlling the relevant boundary conditions across multiple institutions may give us more insight into the answers to the questions raised in this article. It should be the necessary next step.

CONCLUSIONS

Our study suggests that headaches, neck pain, seizures, and more severe complications, including autonomic dysreflexia with hypertension, may result from irrigation fluid entering the spinal canal or the dural sac. Further research should be conducted to determine low-risk threshold numbers for pressure, flow, and total volume delivered to maximize the benefits of endoscopic irrigation systems in the lumbar spine while mitigating risks. Our study established that unlimited irrigation at will should be avoided during lumbar spinal endoscopy. The endoscopic spine surgeon should be prepared to manage unexpected neurological decline and cardiovascular compromise, mainly when encountering an incidental durotomy. Unrecognized durotomies may be more frequent and should be considered if the patient worsens after a seemingly uneventful endoscopic spinal decompression surgery.

REFERENCES

1. Kim J-S, Yeung A, Lokanath YK, Lewandrowski K-U. Is Asia truly a hotspot of contemporary minimally invasive and endoscopic spinal surgery *J Spine Surg*. 2020;6(S1):S224–S236. doi:10.21037/jss.2019.12.13
2. Lin G-X, Kotheeranurak V, Mahatthanatrakul A, et al. Worldwide research productivity in the field of full-endoscopic spine surgery: a bibliometric study. *Eur Spine J*. 2020;29(1):153–160. doi:10.1007/s00586-019-06171-2
3. Lewandrowski KU. Incidence, management, and cost of complications after transforaminal endoscopic decompression surgery for lumbar foraminal and lateral recess stenosis: a value proposition for outpatient ambulatory surgery. *Int J Spine Surg*. 2019;13(1):53–67. doi:10.14444/6008
4. Lewandrowski K-U, Soriano-Sánchez J-A, Zhang X, et al. Regional variations in acceptance, and utilization of minimally invasive spinal surgery techniques among spine surgeons: results of a global survey. *J Spine Surg*. 2020;6(S1):S260–S274. doi:10.21037/jss.2019.09.31
5. Ruetten S. Full-endoscopic operations of the spine in disk herniations and spinal stenosis. *Surg Technol Int*. 2011;21:284–298.
6. Komp M, Oezdemir S, Hahn P, Ruetten S. Full-endoscopic posterior foraminotomy surgery for cervical disc herniations. *Oper Orthop Traumatol*. 2018;30(1):13–24. doi:10.1007/s00064-017-0529-1
7. Oezdemir S, Komp M, Hahn P, Ruetten S. Decompression for cervical disc herniation using the full-endoscopic anterior technique. *Oper Orthop Traumatol*. 2019;31(Suppl 1):1–10. doi:10.1007/s00064-018-0531-2
8. Kuroda R, Nakajima T, Yamaguchi T, Watanabe E. A new irrigation system (Endosplash) for a rigid endoscope in trans-sphenoidal endoscopic surgery. *Neurol Med Chir (Tokyo)*. 2016;56(7):409–415. doi:10.2176/nmc.tn.2015-0218
9. Tatsuki H, Yokobori T, Katayama C, et al. A novel one-step lens cleaning device using air and water flow for endoscopic surgery. *PLoS One*. 2018;13(7):e0200749. doi:10.1371/journal.pone.0200749
10. Mayo M, Wolsky R, Baldini T, Vezeridis PS, Bravman JT. Gravity fluid flow more accurately reflects joint fluid pressure compared with commercial peristaltic pump systems in a cadaveric model. *Arthroscopy*. 2018;34(12):3132–3138. doi:10.1016/j.arthro.2018.05.033
11. Ross JA, Marland JD, Payne B, Whiting DR, West HS. Do arthroscopic fluid pumps display true surgical site pressure during hip arthroscopy? *Arthroscopy*. 2018;34(1):126–132. doi:10.1016/j.arthro.2017.08.290
12. West HS. Editorial commentary: to pump or not to pump? Gravity versus fluid pumps for shoulder and knee arthroscopy. *Arthroscopy*. 2018;34(12):3139–3140: . doi:10.1016/j.arthro.2018.10.010
13. Aldoukhi AH, Black KM, Shields J, Ghani KR. Ambulatory tubeless mini-percutaneous nephrolithotomy using moses technology and dusting technique. *Urology*. 2019;124:306. doi:10.1016/j.urology.2018.11.007
14. Soliman HM. Irrigation endoscopic discectomy: a novel percutaneous approach for lumbar disc prolapse. *Eur Spine J*. 2013;22(5):1037–1044. doi:10.1007/s00586-013-2701-0
15. Hong Y-H, Kim S-K, Hwang J, et al. Water dynamics in unilateral biportal endoscopic spine surgery and its related

Downloaded from https://www.ijssurgery.com/ by guest on October 12, 2024

factors: an in vivo proportional regression and proficiency-matched study. *World Neurosurg*. 2021;149:e836–e843. doi:10.1016/j.wneu.2021.01.086

16. Li X, Huang H, Zheng Z, et al. Clinical efficacy of endoscopic-assisted resection of single-segment ossification of the posterior longitudinal ligament in the treatment of thoracic spinal stenosis. *Front Surg*. 2022;9:897182. doi:10.3389/fsurg.2022.897182

17. Hilbert T, Boehm O, Pflugmacher R, Wirtz DC, Baumgarten G, Knuefermann P. Rare complication after endoscopic discectomy. *Anaesthesist*. 2014;63(1):41–46. doi:10.1007/s00101-013-2279-2

18. Kang T, Park SY, Lee SH, Park JH, Suh SW. Assessing changes in cervical epidural pressure during biportal endoscopic lumbar discectomy. *J Neurosurg Spine*. 2020:1–7. doi:10.3171/2020.6.SPINE20586

19. Taha ME, Schneider K, Smith MM, Cunningham G, Young AA, Cass B. Accuracy of arthroscopic fluid pump systems in shoulder surgery: a comparison of 3 different pump systems. *J Shoulder Elbow Surg*. 2020;29(12):2626–2631. doi:10.1016/j.jse.2020.03.039

20. Tsou PM, Alan Yeung C, Yeung AT. Posterolateral transforaminal selective endoscopic discectomy and thermal annuloplasty for chronic lumbar discogenic pain: a minimal access visualized Intradiscal surgical procedure. *Spine J*. 2004;4(5):564–573. doi:10.1016/j.spinee.2004.01.014

21. Yeung AT, Yeung CA. In-vivo endoscopic visualization of patho-anatomy in painful degenerative conditions of the lumbar spine. *Surg Technol Int*. 2006;15:243–256.

22. Gore S, Yeung A. The "inside out" transforaminal technique to treat lumbar spinal pain in an awake and aware patient under local anesthesia: results and a review of the literature. *Int J Spine Surg*. 2014;8:28. doi:10.14444/1028

23. Yeung A, Kotheeranurak V. Transforaminal endoscopic decompression of the lumbar spine for stable isthmic spondylolisthesis as the least invasive surgical treatment using the YESS surgery technique. *Int J Spine Surg*. 2018;12(3):408–414. doi:10.14444/5048

24. Yeung AT, Roberts A, Shin P, Rivers E, Paterson A, Paterson A. Suggestions for a practical and progressive approach to endoscopic spine surgery training and privileges. *J Spine*. 2018;07(02). doi:10.4172/2165-7939.1000414

25. Yeung A, Roberts A, Zhu L, Qi L, Zhang J, Lewandrowski K-U. Treatment of soft tissue and bony spinal stenosis by a visualized endoscopic transforaminal technique under local anesthesia. *Neurospine*. 2019;16(1):52–62. doi:10.14245/ns.1938038.019

26. Yeung A, Lewandrowski KU. Early and staged endoscopic management of common pain generators in the spine. *J Spine Surg*. 2020;6(Suppl 1):S1–S5. doi:10.21037/jss.2019.09.03

Funding: The authors received no financial support for the research, authorship, and/or publication of this article.

Declaration of Conflicting Interests: The authors report no conflicts of interest in this work.

Disclaimer: The views expressed in this article represent those of the authors and no other entity or organization. The authors are accountable for all aspects of the work in ensuring that questions related to the accuracy or integrity of any part of the work are appropriately investigated and resolved. This manuscript is not meant for or intended to endorse any products or push any other agenda other than researching the clinical utilization data of irrigation methods during spinal endoscopy. The motive for compiling this clinically relevant information is by no means created and/or correlated to directly enrich anyone due to its publication.

Corresponding Author: Kai-Uwe Lewandrowski, Center For Advanced Spine Care of Southern Ariizona, 4787 E Camp Lowell Drive, Tucson, AZ 85712, USA; business@tucsonspine.com

This manuscript is generously published free of charge by ISASS, the International Society for the Advancement of Spine Surgery. Copyright © 2023 ISASS. To see more or order reprints or permissions, see http://ijssurgery.com.

COMMENTARY:

This reported experience from Vargas and colleagues illustrates a collection of serious adverse events potentially causally related to durotomy and irrigation techniques during endoscopic spinal surgery. As the global interest and experience with endoscopic spinal surgery rises, reports of potential concerns with this technique are increasingly important. In this article, although the authors cannot unequivocally link the visualization of incidental durotomy with an adverse event, these reports raise the specter of concern to the level that increased awareness and reporting is mandated. This report anecdotally illustrates a potential normative irrigation pressure and illuminates the wide global variation in irrigation techniques and pressure. An effort to further understand safe irrigation technique and to standardize this technique across spinal endoscopic experience and training is also mandated. Although this report does not carry a high level of scientific evidence, the observations raise concerns that merit further investigation to elevate the level of safety for patients undergoing endoscopic spinal surgery.

Charles Branch, MD
IJSS Editor in Chief

Downloaded from https://www.ijssurgery.com/ by guest on October 12, 2024