

Microcervical Foraminotomy for Cervical Juxtafacet Cysts: Case Series and Literature Review

Yuki Kido, Naosuke Kamei, Yuki Fujioka, Toshio Nakamae, Nobuo Adachi and Masanobu Sasaki

Int J Spine Surg 2023, 17 (3) 407-417

doi: <https://doi.org/10.14444/8440>

<http://ijssurgery.com/content/17/3/407>

This information is current as of April 28, 2024.

Email Alerts Receive free email-alerts when new articles cite this article. Sign up at:
<http://ijssurgery.com/alerts>

Microcervical Foraminotomy for Cervical Juxtafacet Cysts: Case Series and Literature Review

YUKI KIDO, MD^{1,2*}; NAOSUKE KAMEI, MD, PhD^{1*}; YUKI FUJIOKA, MD, PhD^{2,3}; TOSHIO NAKAMAE, MD, PhD¹; NOBUO ADACHI, MD, PhD¹; AND MASANOBU SASAKI, MD, PhD^{2,4}

¹Department of Orthopaedic Surgery, Graduate School of Biomedical and Health Sciences, Hiroshima University, Hiroshima, Japan; ²Department of Orthopaedic Surgery, JR Hiroshima Hospital, Hiroshima, Japan; ³Department of Orthopaedic Surgery, National Hospital Organization Higashihiroshima Medical Center, Higashihiroshima, Japan; ⁴Nishi-Hiroshima Rehabilitation Hospital, Hiroshima, Japan

*Yuki Kido and Naosuke Kamei contributed equally to this article and are thus co-first authors.

ABSTRACT

Background: Juxtafacet cysts are located near or contiguous with the facet joints, and their occurrence is rare in the cervical spine. We report 4 cases of cervical juxtafacet cysts operated by microcervical foraminotomy (MCF) or a combination of MCF and laminoplasty. We simultaneously review previously reported cases in terms of location, clinical findings, and surgical technique.

Methods: Among the patients who underwent spine surgery at our hospital from 2015 to 2019, 4 had cervical juxtafacet cysts. The images and clinical records of the patients were retrospectively assessed. Relevant previous English literature was searched and reviewed using PubMed.

Results: In our series, all 4 patients presented with unilateral upper extremity muscle weakness preoperatively. Two patients underwent MCF, and the other 2 underwent a combination of MCF and laminoplasty with resection of the cyst. All showed improvement in muscle strength. In previously reported cases, the rate of muscle weakness was high. A review of previous cases showed that 75 of 139 patients had cysts at C7-T1. The most common surgical techniques consisted of a hemilaminectomy or laminectomy with the addition of posterior fusion in 28 patients. The number of male patients was twice that of female patients; however, the male-to-female ratio was almost the same in patients with cysts in C7-T1. On pathological diagnosis, there were 3 times more synovial cysts than ganglion cysts. The percentage of synovial cysts was higher in patients with radiculopathy, and the percentage of ganglion cysts was higher in patients with myelopathy.

Conclusions: Cervical juxtafacet cysts tend to occur in C7-T1 and cause muscle weakness. Surgical therapy is strongly recommended due to good postoperative improvement.

Clinical Relevance: The results of this study suggest that microcervical foraminotomy for cervical juxtafacet cysts can provide favorable symptomatic improvement.

Level of Evidence: 3.

Cervical Spine

Keywords: cervical, juxtafacet cyst, facet cyst, synovial cyst, ganglion cyst, surgery

INTRODUCTION

A juxtafacet cyst is a synovial or ganglion cyst located near or contiguous with the facet joint of the spine.¹ Most juxtafacet cysts occur in the lumbar spine but rarely in the cervical spine, with a reported incidence of approximately 1% to 4%.^{2,3} Juxtafacet cysts in the cervical spine can cause compression of the spinal cord and nerve roots, leading to myelopathy and radiculopathy.⁴ Surgical resection is the most common treatment for symptomatic juxtafacet cysts. Laminectomy or hemilaminectomy to remove the cyst is the most common procedure, but further posterior fusion interventions have also been documented.^{5,6}

For cervical radiculopathy, good results have been reported with microcervical foraminotomy (MCF).⁷ In addition, a combination of open-door laminoplasty

and MCF for cervical myeloradiculopathy has been reported.^{8,9} Here, we document the case of 4 patients who underwent MCF or laminoplasty with MCF. We also review previous reports on cervical juxtafacet cysts to elucidate their clinical features on these lesions.

MATERIALS AND METHODS

Case Series

This study was a retrospective case series. Among the patients who underwent cervical spine surgery in our hospital from September 2015 to February 2019, 4 patients had cervical juxtafacet cysts. The clinical records and images of these patients were retrospectively examined. Data collection included patient age, sex, symptoms, muscle weakness, surgical procedure,

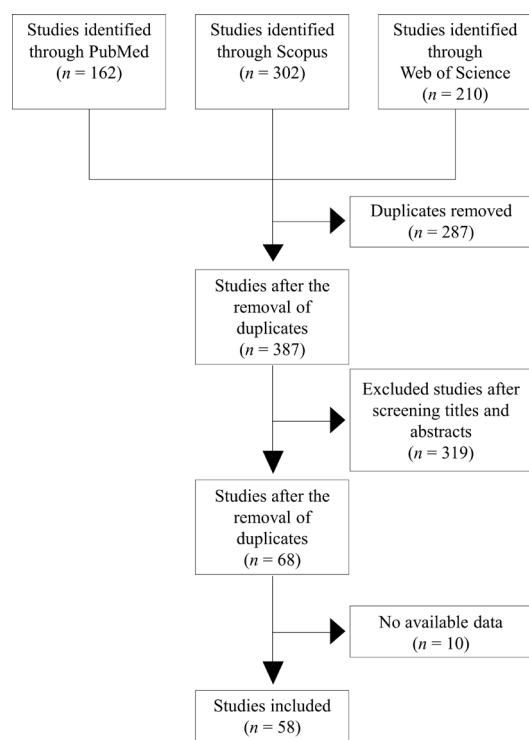


Fig. 1

Figure 1. Flow diagram of the study search and selection process.

pathological diagnosis, and manual muscle test (MMT) scores before and after surgery.

Literature Review

In addition, we reviewed several articles related to cervical juxtafacet cysts. We searched for articles with the appropriate word combinations, including “juxtafacet” or “synovial” or “ganglion” and “cervical” and “cyst” not “tumor” in PubMed, Scopus, and Web of Science. Among the articles retrieved, cases of cysts originating from the ligament posterior to the odontoid process or cysts in areas other than the cervical spine were excluded. Age, sex, location of the cyst, symptoms (myelopathy, radiculopathy, or a combination of both), presence of muscle weakness,

surgical procedure, and pathological diagnosis were investigated in 144 cases from 58 articles selected in this manner (Figure 1).^{1–6,10–51}

RESULTS

The age, sex, symptoms, muscle weakness, surgical procedure, pathological diagnosis, and MMT scores before and after surgery of the 4 patients included in this study are summarized in Table 1. The mean age of the patients was 66.0 years (range 50–73 years). Three patients were men and 1 was a woman. All had radiculopathy; 1 had C5, another had C6, and 2 had C8 radiculopathies. C5 radiculopathy was reflected as muscle weakness in the deltoid and biceps, C6 radiculopathy was reflected as muscle weakness in the biceps, and C8 radiculopathy was reflected as muscle weakness during finger extension or flexion. At 6 months postoperatively, all patients showed an improvement in muscle strength. Of the surgeries performed on these patients, 2 consisted of an MCF, and 2 consisted of a combined laminoplasty and MCF. All patients underwent operation through a posterior midline skin incision approach. In the MCF-only cases, only 1 side of the lamina and the medial portion of the lateral mass were exposed; in cases where laminoplasty was added, the opposite side was also exposed. The pathological diagnosis was that of a ganglion cyst in 3 cases and a synovial cyst in 1 case.

The data from previously reported cases are summarized in Table 2. The 144 cases from 58 articles published from 1974 to 2022 were included. All of these patients were treated by either neuro or orthopedic surgeons. These articles were reported from Australia, Brazil, Finland, France, Germany, Hungary, India, Israel, Italy, Japan, Korea, Mexico, Portugal, Singapore, Taiwan, Tunisia, Thailand, Turkey, the United Kingdom, and the United States. Juxtafacet cysts occurred frequently at C7-T1 (55.9%). In terms of symptoms, radiculopathy cases (51.8%)

Table 1. Summary of 4 patients.

| Age | Sex | Location | Symptom | Muscle Weakness | Surgery | Pathology | Manual Muscle Test (Preoperative/6 mo) |
|-----|-------|----------|--------------------|-----------------|----------|-----------|--|
| 69 | Man | C4-C5 | Radiculopathy (C5) | Deltoid, biceps | MCF | Ganglion | 1/5 |
| 72 | Man | C7-T1 | Radiculopathy (C8) | Wrist flexor | LP + MCF | Ganglion | 3/4 |
| 73 | Woman | C5-C6 | Radiculopathy (C6) | Biceps | MCF | Ganglion | 4/5 |
| 50 | Man | C7-T1 | Radiculopathy (C8) | Finger extensor | LP + MCF | Synovial | 4/5 |

Abbreviations: LP, laminoplasty; MCF, microcervical foraminotomy.

Table 2. Summary of previously reported cases (*N* = 144).

| Characteristic | <i>n</i> |
|----------------------------|--------------|
| Gender, <i>n</i> | |
| Men | 92 |
| Women | 51 |
| NA | 1 |
| Age, y, mean (range) | 65.2 (40–86) |
| Cyst location | |
| C2–3 | 4 |
| C3–4 | 17 |
| C4–5 | 18 |
| C5–6 | 10 |
| C6–7 | 15 |
| C7–T1 | 80 |
| Symptoms | |
| Myelopathy | 53 |
| Myeloradiculopathy | 15 |
| Radiculopathy | 74 |
| NA | 2 |
| Motor weakness | |
| Yes | 84 |
| No | 17 |
| NA | 43 |
| Surgery | |
| Hemilaminectomy | 59 |
| Laminectomy | 43 |
| Posterior fusion | 28 |
| Laminoplasty | 3 |
| Endoscopic hemilaminectomy | 7 |
| Endoscopic foraminotomy | 2 |
| Needle aspiration | 1 |
| NA | 1 |
| Pathologic findings | |
| Synovial cyst | 96 |
| Ganglion cyst | 32 |
| NA | 16 |

Abbreviation: NA, not available.

Note: Data presented as *n* except where otherwise noted.

were slightly more common than myelopathy cases (37.6%), with 10.6% of patients harboring both. Many patients also had muscle weakness (84.0%). The most common surgical procedure was hemilaminectomy

(41.5%) followed by laminectomy (30.3%). A total of 19.7% of the patients had an additional 1-level posterior fusion. Laminoplasty was performed in only 3 cases (2.1%), and endoscopic surgery was reported in 6.3% of the patients. The ratio of synovial to ganglion cysts was 3:1. The data of previously reported cases are summarized in Table 3 based on cyst location. Patients with cysts in the upper cervical spine tended to be slightly older, but the difference was not statistically significant. The male-to-female ratio was nearly the same in those with cysts in C7-T1, although there were more men in cases with cysts in C2-C3 to C5-C6. Symptoms in those with cysts at C1-C2 to C3-C4 mostly involved myelopathy, but radiculopathy increased below the C4-C5 level. The percentage of patients with muscle weakness was high, regardless of the location of the cyst, although it was slightly lower when the cyst was located at the C4-C5 and C7-T1 levels. No apparent difference was observed in the proportion of synovial and ganglion cysts due to the different cyst locations. The data of previously reported cases are summarized in Table 4 based on symptoms. No obvious age differences were observed across the different symptoms, but there was a higher percentage of women with radiculopathy. Laminectomy was more common in patients with myelopathy and myeloradiculopathy, and hemilaminectomy was more common in patients with radiculopathy. The proportion of patients who underwent posterior fusion was higher in those with myeloradiculopathy and radiculopathy than in those with myelopathy. The pathological diagnosis revealed a higher percentage of ganglions in patients with

Table 3. Summary of previously reported cases by location of the cyst.

| Location | Age, y, Mean (Range) | Sex, Men/Women | Symptom | Motor Weakness, With/Without | Pathology |
|----------|----------------------|------------------|---|------------------------------|---------------------------------------|
| C2-C3 | 72.0 (58–79) | 4/0 | Myelopathy: 2 Myeloradiculopathy: 1 Radiculopathy: 1 | 2/0 (100%) (NA: 2) | Synovial: 4 Ganglion: 0 |
| C3-C4 | 70.7 (60–81) | 14/3 | Myelopathy: 12 Myeloradiculopathy: 4 Radiculopathy: 1 | 11/0 (100%) (NA: 6) | Synovial: 11 Ganglion: 5 NA: 6 |
| C4-C5 | 65.6 (42–86) | 15/3 | Myelopathy: 5 Myeloradiculopathy: 2 Radiculopathy: 11 | 7/3 (70.0%) (N/A: 8) | Synovial: 12 Ganglion: 5 NA: 1 |
| C5-C6 | 62.5 (40–74) | 9/1 | Myelopathy 3 Myeloradiculopathy 2 Radiculopathy 5 | 7/0 (100%) (NA: 3) | Synovial: 7 Ganglion: 2 NA: 1 |
| C6-C7 | 62.4 (48–83) | 9/6 | Myelopathy: 4 Myeloradiculopathy: 2 Radiculopathy: 9 | 13/1 (92.9%) (NA: 1) | Synovial: 7 Ganglion: 4 NA: 4 |
| C7-T1 | 64.5 (41–84) | 42/37 (NA: 1) | Myelopathy: 27 Myeloradiculopathy: 4 Radiculopathy: 47 NA: 2 | 45/13 (77.6%) (NA: 22) | Synovial: 55 Ganglion: 16 NA: 9 |

Abbreviation: NA, not available.

Table 4. Summary of previously reported cases by symptom.

| Symptom | Age, y, Mean (Range) | Sex, Men/Women | Motor Weakness, With/Without | Surgery | Pathology |
|--------------------|----------------------|----------------|------------------------------|---|---------------------------------------|
| Myelopathy | 65.4 (41–86) | 41/11 (NA: 1) | 35/3 (92.1%) (NA: 15) | Hemilaminectomy: 13 Laminectomy: 31 Fusion: 3 Laminoplasty: 1 Endoscopic hemilaminectomy: 5 | Synovial: 34 Ganglion: 15 NA: 4 |
| Myeloradiculopathy | 66.1 (56–82) | 11/4 | 11/1 (91.7%) (NA: 3) | Laminectomy: 8 Fusion: 5 Laminoplasty: 2 | Synovial: 3 Ganglion: 8 NA: 4 |
| Radiculopathy | 64.7 (40–84) | 39/35 | 38/13 (74.5%) (NA: 23) | Hemilaminectomy: 44 Laminectomy: 4 Fusion: 20 Endoscopic hemilaminectomy: 2 Endoscopic foraminotomy: 2 Needle aspiration: 1 NA: 1 | Synovial: 58 Ganglion: 8 NA: 8 |

Abbreviation: NA, not available.

myelopathy and myeloradiculopathy than in those with radiculopathy.

Case Presentations

Case 1

A 69-year-old man complained of pain in his left shoulder and upper arm (Numerical Rating Scale [NRS] score of 8). He was unable to raise his left upper limb (Figure 2A). Deep tendon reflexes of the extremities revealed no abnormalities or pathological reflexes. Weakness was observed in the left deltoid and infraspinatus muscles, and the MMT score was 2 in the deltoid (Figure 2A). Magnetic resonance imaging (MRI) T2-weighted images showed a low- to high-signal lesion in the left C4-C5 intervertebral foramen (Figure 2B). Computed tomography (CT) myelography showed significant osteoarthritis in the left C4-C5 facet joints and contrast loss at the entrance of the left C4-C5 intervertebral foramen (Figure 2C). Preoperative CT imaging revealed significant osteoarthritis not only in the left C4-C5 facet joint but also in the left C5-C6 facet joint (Figure 2D). MCF of the left C4-C5 was carried out using a surgical microscope (Figure 3A and B). A cyst was found on the left lateral and ventral sides of the left C5 nerve root (Figure 3A), and the cyst was removed (Figure 3B). Histopathological sections showed increased collagen fibers, fibroblasts, and acidic mucus with positive Alcian blue staining, leading to the diagnosis of a ganglion cyst (Figure 3C). The pain in the left upper limb improved immediately after surgery (NRS 4) and disappeared immediately after surgery (NRS 0). The strength of the left deltoid muscle improved to 5 on the MMT score 6 months following surgery

(Figure 2D). There was no symptom recurrence at the 2-year postoperative follow-up.

Case 2

A 72-year-old man complained of pain in his right scapula and right upper extremity (NRS 10) accompanied by numbness in his right upper extremity. Deep tendon reflexes of the extremities demonstrated no abnormalities or pathological reflexes. Muscle weakness was observed in wrist and finger flexion, with MMT scores of 3 and 4, respectively. The grip strength was 16.3 kg on the right and 43.4 kg on the left. MRI T2-weighted images revealed an iso- to high-signal mass on the left dorsal side within the C7-T1 spinal canal (Figure 4A). Left C6-C7 laminoplasty and left C7-T1 MCF were performed. Intraoperatively, a cyst originating from the left C7-T1 ligamentum flavum was observed (Figure 4B). A hematoma was also observed within the cyst (Figure 4C). The pathological diagnosis was that of a ganglion cyst containing erythrocytes and fibrin (Figure 4D). The pain in the right upper extremity disappeared immediately following the surgery (NRS 0). The muscle strength of the right wrist and finger flexions improved to 5 on the MMT score 6 months following the surgery. There was no symptom recurrence at the 2-year postoperative follow-up.

Case 3

A 73-year-old woman complained of right shoulder pain (NRS 4) and numbness in her right upper extremity. Deep tendon reflexes of the extremities demonstrated no abnormalities or pathological reflexes. Muscle weakness was observed in her right biceps muscle with an MMT score of 4. MRI T2-weighted images

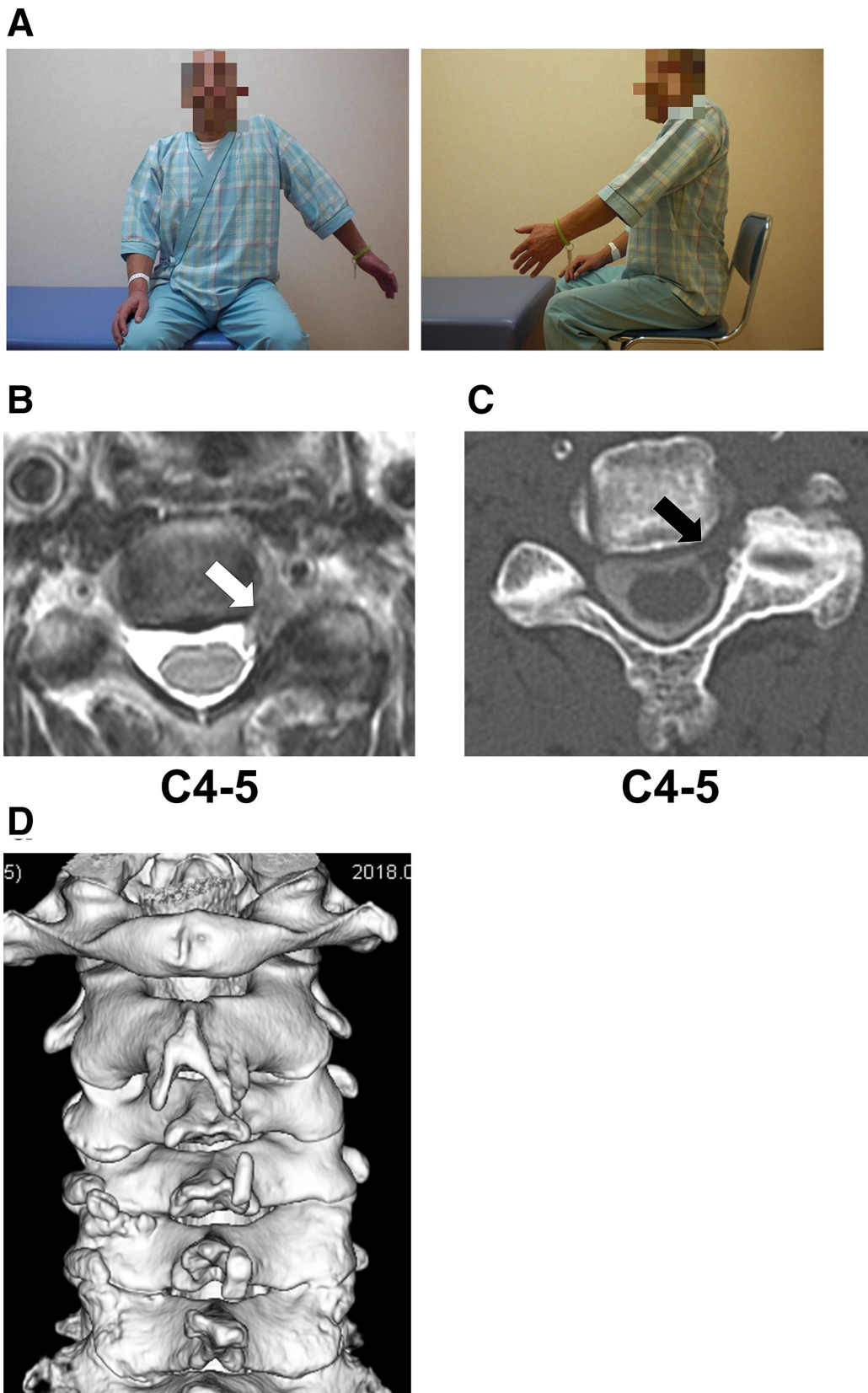


Figure 2. Snapshots of the patient, magnetic resonance imaging (MRI) and computed tomography (CT) images prior to the surgery in Case 1. (A) The patient was unable to raise his left upper extremity. (B) T2-weighted axial MRI image in C4-5. The white arrow points to the lesion in the left C4-5 foramen. (C) C4-5 axial CT myelogram image. The black arrow points to the loss of contrast as a result of the lesion. (D) Preoperative 3D CT image of the cervical spine. It shows marked osteophyte formation at the left C4-5 and C5-6 facet joints.

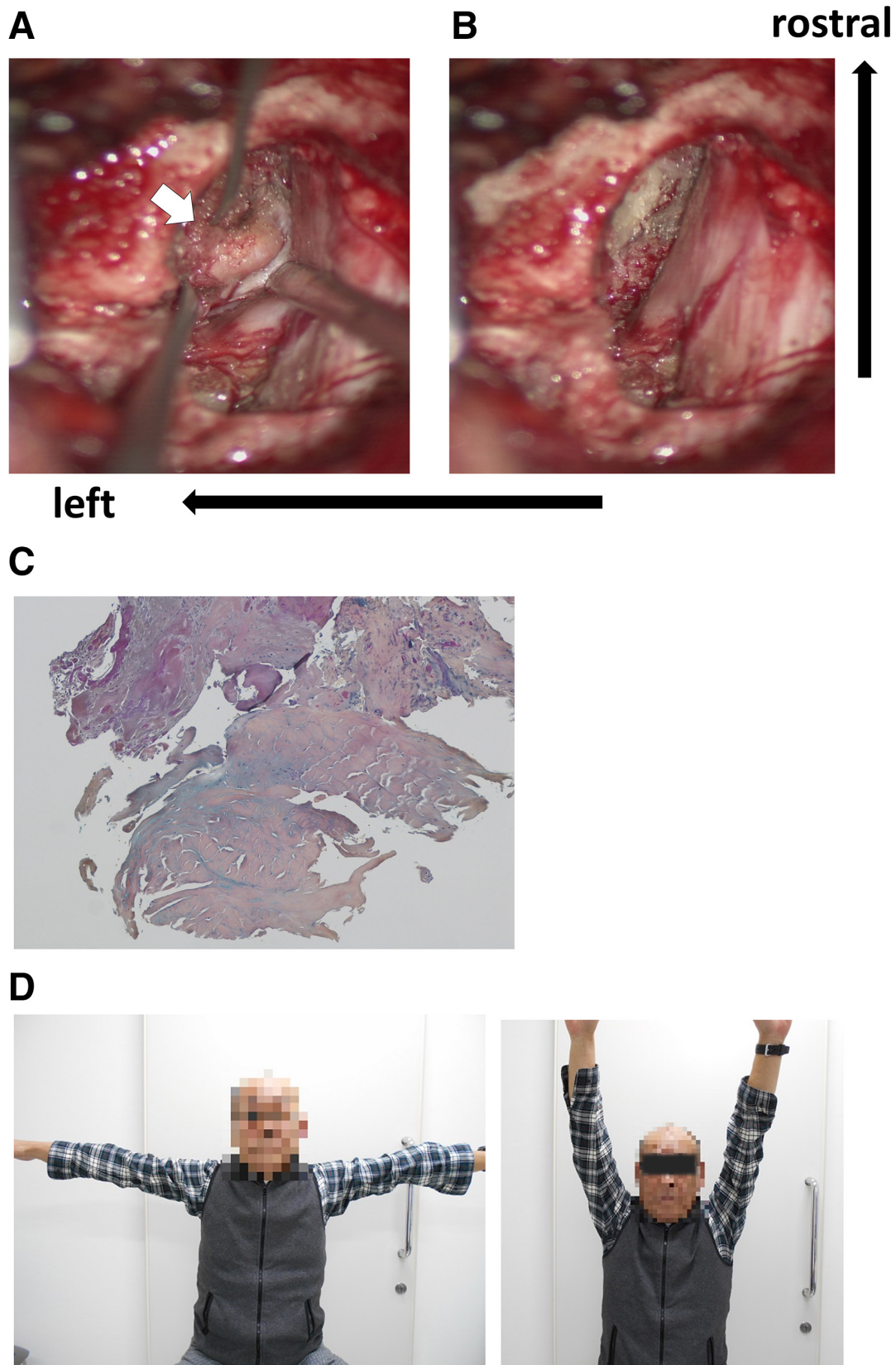


Figure 3. Intraoperative photographs, histopathological images and postoperative photographs of the patient. (A) A photograph following microcervical foraminotomy before cyst removal. The white arrow points to the cyst. (B) A photograph following cyst removal. The left C5 nerve root is well decompressed. (C) A pathological image of resected cyst. Increased collagen fibers, fibroblasts and acidic mucus with positive Alcian blue staining point to the diagnosis of a ganglion cyst. (D) Six months following the surgery, the patient was able to raise his left upper extremity.

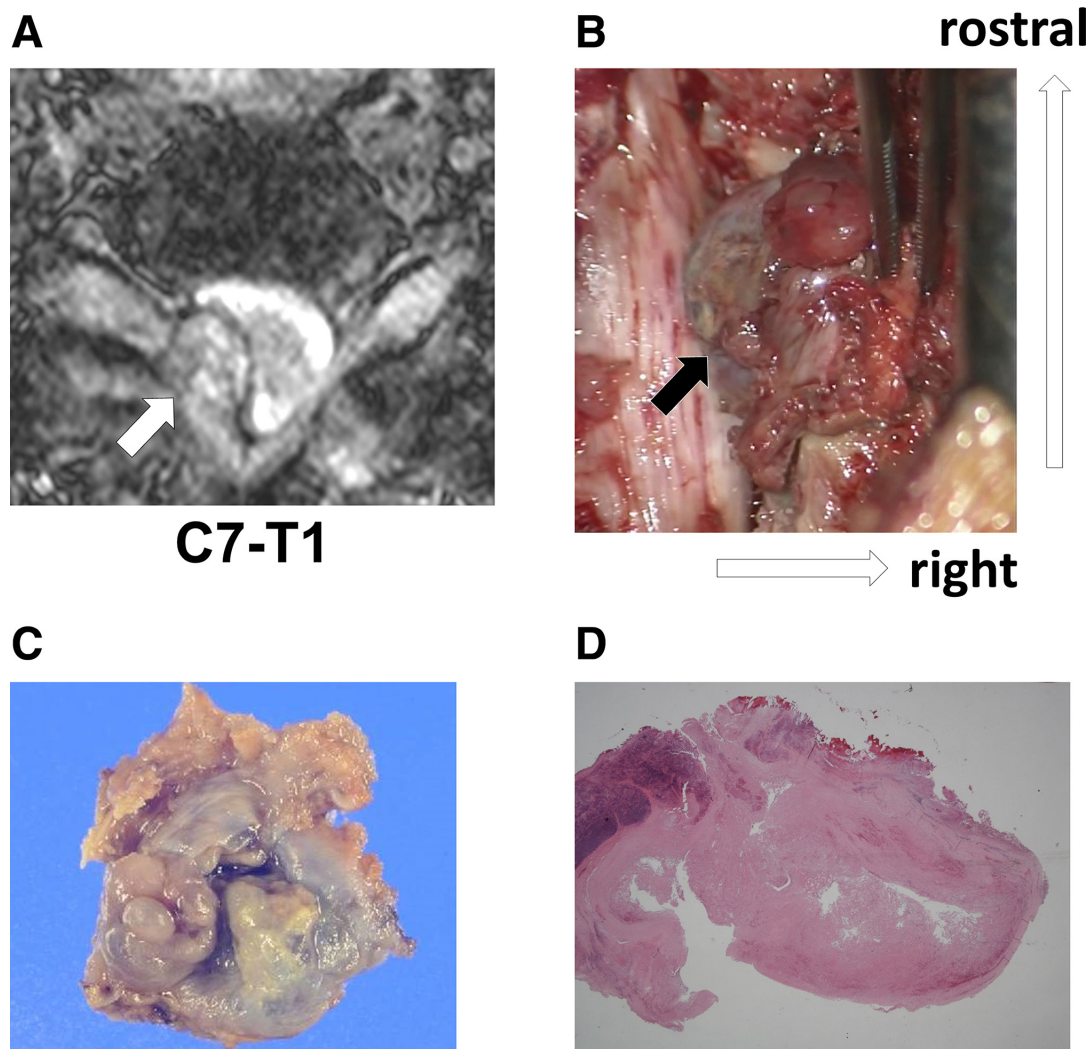


Figure 4. A magnetic resonance image (MRI), an intraoperative photograph, a macrograph, and a pathological image of the resected cyst in Case 2. (A) T2-weighted axial MRI image in C7-T1. The white arrow points to the cyst. (B) An intraoperative photograph. The black arrow points to the cyst in ligamentum flavum. (C) A macrograph of the resected cyst. The color is dark red due to bleeding into the cyst. (D) A pathological image of the resected cyst. A ganglion cyst containing red blood cells and fibrin.

(Figure 5A) and CT myelography (Figure 5B) revealed a mass lesion at the border between the intervertebral foramen and spinal canal on the right side of C5-C6. The pain in the right shoulder disappeared immediately after surgery (NRS 0), and the strength of the right biceps muscle improved to 5 on the MMT score 1 year following surgery. There was no symptom recurrence at the 2-year postoperative follow-up.

Case 4

A 50-year-old man complained of pain in his left scapula and left anterior thoracic region (NRS 6). Muscle weakness was observed in his left finger extensor with an MMT score of 4. T2-weighted MRI showed a mass lesion from the spinal canal to the intervertebral foramen at the C7-T1 on the left side (Figure 5C). The

pain in the left upper limb disappeared immediately after surgery (NRS 0), and the strength of the left finger extensor improved to 5 on the MMT score 3 months following surgery. There was no symptom recurrence at the 2-year postoperative follow-up.

DISCUSSION

Cervical juxtafacet cysts tended to occur more frequently at C7-T1 and were characterized by a tendency to cause muscle weakness. Cervical juxtafacet cysts often present with myelopathy, radiculopathy, or both, depending on their location. They are associated with muscle weakness, which can be treated surgically, yielding good results. Muscle weakness was observed in all 4 cases, and the patients underwent MCF or

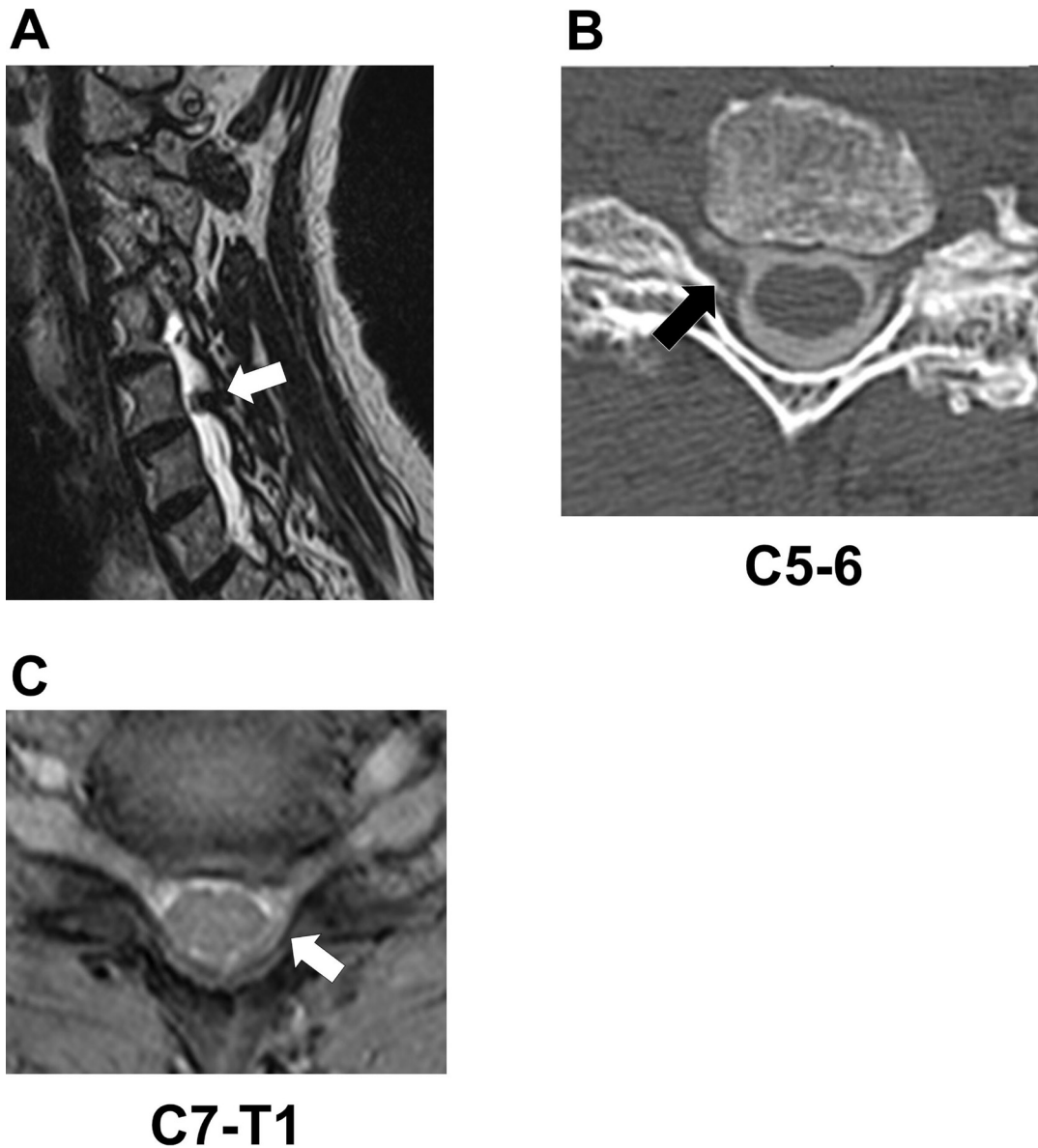


Figure 5. Magnetic resonance imaging (MRI) and computed tomography (CT) images prior to the surgery in Case 3 and 4. (A) T2-weighted sagittal MRI image of Case 3. The white arrow points to the lesion at C5-C6. (B) C5-6 axial CT myelogram image of Case 3. The black arrow points to the loss of contrast as a result of the lesion at the border between the intervertebral foramen and spinal canal on the right side. (C) T2-weighted axial MRI image of Case 4. The white arrow points to the lesion from the spinal canal to the intervertebral foramen at the C7-T1 on the left side.

MCF combined with laminoplasty. The patient's symptoms, including muscle weakness, improved following surgery.

Etiology and Location

The relationship between juxtafacet cysts and facet joint degeneration has been previously documented.^{10,13} Osteoarthritis was found in the intervertebral joints near the cyst in our 4 patients. Mucous degeneration of collagen connective tissue or weakening of the joint capsule due to degeneration of the facet joints is thought to be related to

cyst formation.^{10,13,17} However, while cervical spondylotic myelopathy and radiculopathy, which also result from the degeneration of the cervical spine, mainly occur in the C4-C5 to C6-C7 regions,⁵²⁻⁵⁴ juxtafacet cysts occur more frequently in the C7-T1 region. Chronic stress associated with degeneration of the facet joints is thought to be one of the causes underlying cyst development.¹² There have been reports of cysts occurring adjacent to spines fixed by spinal fusion or ankylosing spines.^{14,17,19,24,26} The mechanical properties of C7-T1 at the cervicothoracic junction may be involved in cyst development.

Spinal instability has been reportedly associated with cyst development, and cysts have reportedly occurred at sites associated with spondylolisthesis.^{11,12,15,16,20} In our cases, when there was a cyst at C4-C5 or C5-C6, although there was no spondylolisthesis, there was significant facet joint degeneration not only at the site of the cyst but also at the adjacent site. Mechanical features associated with spondylosis may underlie the development of cysts at sites other than C7-T1. Cervical juxtafacet cysts were more common in men, but the percentage of women was higher in cases with cysts at the C7-T1 level than in those with cysts at other sites. It has been reported that cervical spondylosis is more likely to occur in men than in women.⁵⁵ The higher percentage of men in cases with cysts in sites other than the C7-T1 region may be related to sex differences in cervical spondylosis.

Midline/paracentral-type cysts are assumed to cause myelopathy, while foraminal-type cysts cause radiculopathy. Patients with myelopathy were more often treated with laminectomy, while patients with radiculopathy were more often treated with hemilaminectomy and had a higher rate of additional posterior fusion. All our patients had foraminal cysts with radiculopathy and could be treated with MCF without additional fusion. Moreover, patients with cysts extending into the spinal canal could be treated with the addition of laminoplasty.

Symptoms

Most cases with cysts from C1-C2 to C3-C4 showed signs of myelopathy, but there was a higher incidence of radiculopathy below the C4-C5 level. This is thought to result from the fact that each nerve root functions differently; therefore, symptoms are unlikely to occur even if the C2-C4 nerve roots are compressed. Patients with cervical juxtafacet cysts have a higher rate of muscle weakness, even when symptoms include radiculopathy. However, good postoperative improvement has been reported.^{11,20} Muscle weakness was observed, but the patient recovered well after surgery. Surgical treatment is strongly recommended for cases of cervical juxtafacet cysts with neurological symptoms.

Surgical Procedure

In previous reports, the most common surgical methods included laminectomy and hemilaminectomy; however, in our cases, it was also possible to remove the cyst by MCF or a combination of MCF

and laminoplasty. MCF or a combination of MCF and laminoplasty can preserve more bone tissue than laminectomy alone. Regarding the addition of posterior fusion, since juxtafacet cysts were probably caused by degeneration of the facet joint due to mechanical stress, some suggested that spinal fusion would be necessary as the definitive treatment.^{6,12,17} However, the high rate of fusion in patients with radiculopathy, rather than myelopathy, may have been influenced by the addition of facetectomy to laminectomy.^{19,24,25} In our cases, complete resection of the cyst with decompression of the intervertebral foramen and the sufficient preservation of the lateral portion of the facet joint by MCF without spinal fusion resulted in symptoms improvement without recurrence during at least 2 years of follow-up. Endoscopic surgery was reported in 9 cases as a minimally invasive surgery. Eight patients underwent full-endoscopic surgery,^{14,15} and 1 underwent a microendoscopic surgery using a tubular retractor.¹¹ Although endoscopic surgery is minimally invasive, it remains very difficult and requires skilled surgical techniques. In a case series of 7 patients who underwent full-endoscopic surgery, surgery-related complications were reported in 2 cases (transient hypesthesia and dural leak).¹⁵ Although MCF is more invasive than endoscopic surgery, it does not require skilled surgical techniques, such as endoscopic surgery, and the cyst can be clearly seen and easily removed, as shown in Figures 2A and 3B.

Pathology

Pathological examination revealed that synovial cysts were 3 times more common than ganglion cysts. The relationship between pathological diagnoses and sites of occurrence remains unclear. However, the percentage of ganglion cysts was higher in patients with myelopathy and myeloradiculopathy than in patients with radiculopathy. This may be because ganglion cysts in the ligamentum flavum tend to compress the spinal cord and cause myelopathy. In some cases, as in Case 2, bleeding can be seen within the ganglion cyst; it may be necessary to differentiate it from spontaneous epidural hematoma.¹²

CONCLUSIONS

Cervical juxtafacet cysts are characterized by their tendency to result in muscle weakness. Surgical treatment is strongly recommended to improve

the symptoms. MCF, or a combination of MCF and laminoplasty, does not require additional fixation and is minimally invasive; thus, it can be a viable surgical option.

ACKNOWLEDGMENTS

We would like to thank Editage (www.editage.com) for English language editing.

REFERENCES

1. Kao CC, Winkler SS, Turner JH. Synovial cyst of spinal facet. Case report. *J Neurosurg*. 1974;41(3):372–376. doi:10.3171/jns.1974.41.3.0372
2. Gandhoke CS, Mak SKD, Primalani NK, Goh ET, Lee HY, Nolan CP. Cervical C7 ganglion cyst causing compressive myelopathy: a rare case report. *Surg Neurol Int*. 2019;10:61. doi:10.25259/SNI-153-2019
3. Sameshima T, Shibahashi K, Nozaki T, et al. Atlantoaxial intraspinal juxtafacet cyst. *Neurol Med Chir (Tokyo)*. 2013;53(2):125–128. doi:10.2176/nmc.53.125
4. Krauss WE, Atkinson JL, Miller GM. Juxtafacet cysts of the cervical spine. *Neurosurgery*. 1998;43(6):1363–1368. doi:10.1097/00006123-199812000-00058
5. Lyons MK, Birch BD, Krauss WE, Patel NP, Nottmeier EW, Boucher OK. Subaxial cervical synovial cysts: report of 35 histologically confirmed surgically treated cases and review of the literature. *Spine (Phila Pa 1976)*. 2011;36(20):E1285–9. doi:10.1097/BRS.0b013e31820709a8
6. Bydon M, Lin JA, de la Garza-Ramos R, et al. The role of spinal fusion in the treatment of cervical synovial cysts: a series of 17 cases and meta-analysis. *J Neurosurg Spine*. 2014;21(6):919–928. doi:10.3171/2014.8.SPINE13897
7. Williams RW. Microcervical foraminotomy. A surgical alternative for intractable radicular pain. *Spine (Phila Pa 1976)*. 1983;8(7):708–716. doi:10.1097/00007632-198310000-00005
8. Ishiguro H, Takenaka S, Kashii M, et al. Direct involvement of concomitant foraminotomy for radiculomyelopathy in postoperative upper limb palsy in cervical laminoplasty. *World Neurosurg*. 2021;146:e14–e21. doi:10.1016/j.wneu.2020.09.105
9. Marcó Del Pont F, Giovannini SJM, Ries Centeno T, Caffaratti G, Loreface E, Cervio A. Cervical laminoplasty with unilateral C4-5 foraminotomy: technical note and case series. *Neurocirugia (Astur: Engl Ed)*. 2021;32(5):224–230. doi:10.1016/j.neucie.2021.06.001
10. Ruggeri L, Brunasso L, Urrico G, et al. Waste not, want not: report of a completely calcified C1–C2 juxtafacet cyst and literature review. *Surg Neurol Int*. 2021;12:369. doi:10.25259/SNI_574_2021
11. Soriano Sánchez JA, Lewandrowski KU, Franco Jiménez JA, et al. Minimally invasive posterior tubular microsurgical approach for the management of symptomatic synovial cysts of the lumbar and cervical spine. *Int J Spine Surg*. 2021;15(5):1014–1024. doi:10.14444/8134
12. Tanishima S, Mihara T, Takeda C, Ogawa S, Nagashima H. Fast-growing cervical juxtafacet cyst mimicking epidural hematoma. *JBJS Case Connector*. 2020;10(3):e20. doi:10.2106/JBJS.CC.20.00237
13. Jitpun E, Narischat P. Hemorrhagic cervical synovial cyst presented with acute brown-sequard syndrome: a case report and review of literature. *Clin Neurol Neurosurg*. 2020;195:106055. doi:10.1016/j.clineuro.2020.106055
14. Kim HS, Damani N, Singh R, et al. Endoscopic resection of symptomatic cervical facet cyst in ankylosing spondylitis. *World Neurosurg*. 2019;127:99–102. doi:10.1016/j.wneu.2019.03.220
15. Ruetten S, Hahn P, Oezdemir S, Baraliakos X, Godolias G, Komp M. Surgical treatment of cervical subaxial intraspinal extradural cysts using a full-endoscopic uniportal posterior approach. *J Orthop Surg (Hong Kong)*. 2018;26(2):2309499018777665. doi:10.1177/2309499018777665
16. Kim J, Choi JG, Son BC. Bilateral ganglion cysts of the ligamentum flavum in the cervical spine causing a progressive cervical radiculomyelopathy and literature review. *Case Rep Neurol Med*. 2017;2017:3953641. doi:10.1155/2017/3953641
17. Corredor JA, Quan G. Cervical synovial cyst causing cervical radiculomyelopathy: case report and review of the literature. *Global Spine J*. 2015;5(4):e34–e38. doi:10.1055/s-0034-1396758
18. Sasamori T, Hida K, Anzai K, et al. A case of cervical juxtafacet cyst with extensive rim enhancement on Gd-DTPA MRI. *Clin Imaging*. 2014;38(2):199–201. doi:10.1016/j.clinimag.2013.10.002
19. Uschold T, Panchmatia J, Fusco DJ, Abila AA, Porter RW, Theodore N. Subaxial cervical juxtafacet cysts: single institution surgical experience and literature review. *Acta Neurochir (Wien)*. 2013;155(2):299–308. doi:10.1007/s00701-012-1549-0
20. Bisson EF, Sauri-Barraza JC, Niaz T, Schmidt MH. Synovial cysts of the cervicothoracic junction causing myelopathy: report of 3 cases and review of the literature. *Neurosurg Focus*. 2013;35(1):E3. doi:10.3171/2013.3.FOCUS1385
21. Pikus S, Cohen JE, Barzilay Y, Hasharoni A, Kaplan L, Itshayek E. Symptomatic facet cysts of the subaxial cervical spine. *J Clin Neurosci*. 2013;20(7):928–932. doi:10.1016/j.jocn.2012.10.018
22. Machino M, Yukawa Y, Ito K, Kato F. Cervical degenerative intraspinal cyst: a case report and literature review involving 132 cases. *BMJ Case Rep*. 2012;2012:bcr2012007126. doi:10.1136/bcr-2012-007126
23. Tofuku K, Koga H, Komiya S. Facet arthrography of a cervical synovial cyst. *J Neurointerv Surg*. 2012;4(4):e17. doi:10.1136/neurintsurg-2011-010017
24. Sivakumar W, Elder JB, Bilsky MH. Cervical juxtafacet cyst after anterior cervical discectomy and fusion. *Neurosurg Focus*. 2011;31(4):E19. doi:10.3171/2011.8.FOCUS11119
25. Found E, Bewyer D. Cervical synovial cyst: case report. *Iowa Orthop J*. 2011;31:215–218.
26. Moon HJ, Kim JH, Kim JH, Kwon TH, Chung HS, Park YK. Cervical juxtafacet cyst with myelopathy due to postoperative instability. Case report. *Neurol Med Chir (Tokyo)*. 2010;50(12):1129–1131. doi:10.2176/nmc.50.1129
27. Costa F, Menghetti C, Cardia A, Fornari M, Ortolina A. Cervical synovial cyst: case report and review of literature. *Eur Spine J*. 2010;19(Suppl 2):S100–S102. doi:10.1007/s00586-009-1094-6
28. Akhaddar A, Qamouss O, Belhachmi A, et al. Cervicothoracic juxtafacet cyst causing spinal foraminal widening. *Joint Bone Spine*. 2008;75(6):747–749. doi:10.1016/j.jbspin.2008.04.009
29. Vastagh I, Palásti A, Nagy H, et al. Cervical juxtafacet cyst combined with spinal dysraphism. *Clin Imaging*. 2008;32(5):387–389. doi:10.1016/j.clinimag.2008.02.034
30. Christophis P, Asamoto S, Kuchelmeister K, Schachenmayr W. “Juxtafacet cysts”, a misleading name for cystic formations of mobile spine (CYFMOS). *Eur Spine J*. 2007;16(9):1499–1505. doi:10.1007/s00586-006-0287-5

31. Song JK, Musleh W, Christie SD, Fessler RG. Cervical juxtafacet cysts: case report and literature review. *Spine J*. 2006;6(3):279–281. doi:10.1016/j.spinee.2005.09.006
32. McGuigan C, Stevens J, Gabriel CM. A synovial cyst in the cervical spine causing acute spinal cord compression. *Neurology*. 2005;65(8):1293. doi:10.1212/01.wnl.0000182291.35242.2e
33. Fonoff ET, Dias MP, Tarico MA. Myelopathic presentation of cervical juxtafacet cyst: a case report. *Spine (Phila Pa 1976)*. 2004;29(23):E538–E541. doi:10.1097/01.brs.0000146510.09305.6f
34. Miwa M, Doita M, Takayama H, Muratsu H, Harada T, Kurosaka M. An expanding cervical synovial cyst causing acute cervical radiculopathy. *J Spinal Disord Tech*. 2004;17(4):331–333. doi:10.1097/01.bsd.0000095892.46978.6e
35. Cho BY, Zhang HY, Kim HS. Synovial cyst in the cervical region causing severe myelopathy. *Yonsei Med J*. 2004;45(3):539–542. doi:10.3349/ymj.2004.45.3.539
36. Cheng Y-Y, Chen CC-C, Yang M-S, Hung H-C, Lee S-K. Intraspinal extradural ganglion cyst of the cervical spine. *J Formos Med Assoc*. 2004;103(3):230–233.
37. Jost SC, Hsien Tu P, Wright NM. Symptomatic intraosseous synovial cyst in the cervical spine: a case report. *Spine (Phila Pa 1976)*. 2003;28(17):E344–E346. doi:10.1097/01.BRS.0000090501.42188.2A
38. Shima Y, Rothman SLG, Yasura K, Takahashi S. Degenerative intraspinal cyst of the cervical spine: case report and literature review. *Spine (Phila Pa 1976)*. 2002;27(1):E18–E22. doi:10.1097/00007632-200201010-00029
39. Yamamoto A, Nishiura I, Handa H, Kondo A. Ganglion cyst in the ligamentum flavum of the cervical spine causing myelopathy: report of two cases. *Surg Neurol*. 2001;56(6):390–395. doi:10.1016/s0090-3019(01)00639-5
40. Hatem O, Bedou G, Nègre C, Bertrand JL, Camo J. Intraspinal cervical degenerative cyst. *Journal of Neurosurgery*. 2001;95(1):139–142. doi:10.3171/spi.2001.95.1.0139
41. Stoodley MA, Jones NR, Scott G. Cervical and thoracic juxtafacet cysts causing neurologic deficits. *Spine (Phila Pa 1976)*. 2000;25(8):970–973. doi:10.1097/00007632-200004150-00012
42. Lunardi P, Acqui M, Ricci G, Agrillo A, Ferrante L. Cervical synovial cysts: case report and review of the literature. *Eur Spine J*. 1999;8(3):232–237. doi:10.1007/s005860050164
43. Cudlip S, Johnston F, Marsh H. Subaxial cervical synovial cyst presenting with myelopathy. Report of three cases. *J Neurosurg*. 1999;90(1 Suppl):141–144. doi:10.3171/spi.1999.90.1.0141
44. Kotilainen E, Marttila RJ. Paraparesis caused by a bilateral cervical synovial cyst. *Acta Neurol Scand*. 1997;96(1):59–61. doi:10.1111/j.1600-0404.1997.tb00239.x
45. Freidberg SR, Fellows T, Thomas CB, Mancall AC. Experience with symptomatic spinal epidural cysts. *Neurosurgery*. 1994;34(6):989–993. doi:10.1227/00006123-199406000-00006
46. Epstein NE, Hollingsworth R. Synovial cyst of the cervical spine. *J Spinal Disord*. 1993;6(2):182–185. doi:10.1097/00002517-199304000-00014
47. Takano Y, Homma T, Okumura H, Takahashi HE. Ganglion cyst occurring in the ligamentum flavum of the cervical spine. A case report. *Spine (Phila Pa 1976)*. 1992;17(12):1531–1533. doi:10.1097/00007632-199212000-00020
48. Nijensohn E, Russell EJ, Milan M, Brown T. Calcified synovial cyst of the cervical spine: CT and MR evaluation. *J Comput Assist Tomogr*. 1990;14(3):473–476. doi:10.1097/00004728-199005000-00031
49. Patel SC, Sanders WP. Synovial cyst of the cervical spine: case report and review of the literature. *AJNR Am J Neuroradiol*. 1988;9(3):602–603.
50. Jabre A, Shahbadian S, Keller JT. Synovial cyst of the cervical spine. *Neurosurgery*. 1987;20(2):316–318. doi:10.1227/00006123-198702000-00020
51. Cartwright MJ, Nehls DG, Carrion CA, Spetzler RF. Synovial cyst of a cervical facet joint: case report. *Neurosurgery*. 1985;16(6):850–852. doi:10.1227/00006123-198506000-00024
52. Suetomi Y, Kanchiku T, Nishijima S, et al. Application of diffusion tensor imaging for the diagnosis of segmental level of dysfunction in cervical spondylotic myelopathy. *Spinal Cord*. 2016;54(5):390–395. doi:10.1038/sc.2015.192
53. Imajo Y, Kanchiku T, Suzuki H, Nishida N, Funaba M, Taguchi T. Factors associated with an excellent outcome after conservative treatment for patients with proximal cervical spondylotic amyotrophy using electrophysiological, neurological and radiological findings. *J Spinal Cord Med*. 2020;43(6):862–870. doi:10.1080/10790268.2019.1587246
54. Hirai S, Kato S, Nakajima K, et al. Anatomical study of cervical intervertebral foramen in patients with cervical spondylotic radiculopathy. *J Orthop Sci*. 2021;26(1):86–91. doi:10.1016/j.jos.2020.01.017
55. Ikegami S, Uehara M, Tokida R, et al. Cervical spinal alignment change accompanying spondylosis exposes harmonization failure with total spinal balance: a Japanese cohort survey randomly sampled from a basic resident registry. *J Clin Med*. 2021;10(24):5737. doi:10.3390/jcm10245737

Funding: The authors received no financial support for the research, authorship, and/or publication of this article.

Declaration of Conflicting Interests: The authors report no conflicts of interest in this work.

Informed Consent: All patients consented to the treatment with written consent.

Ethics Approval: This study was conducted in accordance with the ethical standards of our institutional and national research committees and the 1964 Declaration of Helsinki and its subsequent amendments or comparable ethical standards.

Corresponding Author: Naosuke Kamei, Department of Orthopaedic Surgery, Graduate School of Biomedical and Health Sciences, Hiroshima University, 1-2-3 Kasumi, Minami-ku, Hiroshima 734-8551, Japan; nahkamei@hiroshima-u.ac.jp

Published 24 February 2023

This manuscript is generously published free of charge by ISASS, the International Society for the Advancement of Spine Surgery. Copyright © 2023 ISASS. To see more or order reprints or permissions, see <http://ijssurgery.com>.