

Clinical Outcomes Following Treatment of Cervical Spondylotic Radiculopathy With Cervical Posterior Decompression Using Unilateral Biportal Endoscopic Technique: A Single Center Retrospective Series of 20 Patients

Keyur K. Akbari, Teo Hong Lee Terry, Umesh Kanade and John Choi

Int J Spine Surg 2025, 19 (1) 19-26

doi: <https://doi.org/10.14444/8690>

<https://www.ijssurgery.com/content/19/1/19>

This information is current as of May 10, 2025.

Email Alerts Receive free email-alerts when new articles cite this article. Sign up at:
<http://ijssurgery.com/alerts>

Clinical Outcomes Following Treatment of Cervical Spondylotic Radiculopathy With Cervical Posterior Decompression Using Unilateral Biportal Endoscopic Technique: A Single Center Retrospective Series of 20 Patients

KEYUR K. AKBARI, MS¹; TEO HONG LEE TERRY, MRCSI, MMED, FRCSEd²; UMESH KANADE, MS¹; AND JOHN CHOI, FRACS¹

¹Spine Ortho Clinic, Mornington, Australia; ²Changi General Hospital, Simei, Singapore

 KKA, 0000-0001-8833-8556;  THLT, 0000-0003-1052-4847;  UK, 0000-0002-5419-5179

ABSTRACT

Background: Unilateral biportal endoscopy (UBE) is a minimally invasive approach to treat cervical spondylotic radiculopathy (CSR), which is a common condition caused secondary to disc herniation, disc degeneration, uncal osteophytes, and other conditions manifesting as neuropathic radicular pain. Anterior cervical discectomy and fusion (ACDF) is the gold standard surgical technique for treating CSR. However, it has several disadvantages, including loss of mobile segment, adjacent segment degeneration (ASD), implant- and approach-related complications, and high hospitalization costs.

Objective: The current study aimed to evaluate the safety and efficacy of UBE decompression for CSR.

Methods: After obtaining IRB approval, a single-center retrospective study was undertaken. Included patients underwent UBE decompression for CSR with a minimum of 6 months of follow-up. Patient demographics, perioperative data, and length of hospital stay were reviewed. Clinical outcomes were assessed using VAS scores for neck and arm pain, and NDI scores were measured preoperatively and at 1 and 6 months after UBE decompression. A repeated analysis of variance test was performed to measure the difference between VAS and NDI scores.

Results: Twenty patients (M: 15, F: 5) with a mean age of 56.7 ± 10.2 years were included. The mean follow-up period was 8.4 ± 1.8 months. The mean surgical time was 64.3 ± 10.6 minutes. The average length of hospital stay was 1 day. At the final follow-up, the mean VAS for arm pain improved from 6.4 ± 0.7 to 0.6 ± 0.5 (92% improvement) and the mean VAS for neck pain improved from 3.3 ± 0.4 to 2.0 ± 0.2 (40% improvement). NDI score improved from 23.2 ± 1.95 to 5.7 ± 0.6 at the final follow-up (75% improvement). There were no complications.

Conclusion: UBE is a safe and effective surgical treatment option for patients with CSR with excellent clinical outcomes.

Clinical Relevance: Clinical relevance of this case series study is to demonstrate the safety and efficacy of the novel unilateral biportal endoscopic decompression of cervical spondylotic radiculopathy and its short term clinical outcomes.

Level of Evidence: 4.

Endoscopic Minimally Invasive Surgery

INTRODUCTION

Cervical spondylotic radiculopathy (CSR) is a common degenerative spinal disease with an increasing prevalence. CSR may be caused by nerve root compression from disc degeneration, herniation, segmental instability, or other disorders, resulting in neuropathic radicular pain.¹ Most CSR patients respond well with conservative management in the form of medications and physiotherapy.² Surgery is reserved for patients who are refractory to conservative management or who

have neurological deterioration. Anterior cervical discectomy and fusion (ACDF) has been considered a gold standard surgical treatment option for the management of CSR.^{3,4} However, it is associated with increased risk of adjacent segment disease, loss of motion, implant-related complications, nonunion, increased length of hospital stay, and cost.^{5–8} In addition, the anterior approach to the cervical spine is associated with an increased risk of postoperative dysphagia,^{9,10} esophageal perforation,¹¹ and iatrogenic injury to major neurovascular structures.¹² Cervical disc replacement

emerged as a novel technique to address certain issues associated with ACDF.¹³ However, it has its limitations of subsidence, expulsion, heterotrophic ossification, persistent neck pain, increased cost, and approach-related complications.¹⁴

The other option to treat CSR is posterior cervical foraminotomy. It addresses the issues associated with anterior surgery; however, it has its drawbacks in the form of axial neck pain, inadequate decompression, operative bleeding, paraspinal muscle spasm, and loss of normal alignment after surgery.^{15,16} Recently, the percutaneous endoscopic foraminotomy technique emerged as a safe minimally invasive surgical treatment option to conventional microsurgical techniques.¹⁷ Unilateral biportal endoscopy (UBE) is a newer endoscopic technique that uses 2 portals (scope portal and working portal) on the same side of the spine to provide excellent magnification and visualization of the spinal structures.¹⁸ There is a paucity of literature on the application of the UBE cervical foraminotomy technique for CSR patients. The current study sought to evaluate the short-term clinical outcomes of the UBE decompression technique for CSR patients by a single surgeon.

MATERIALS AND METHODS

After obtaining Institutional Review Board approval, we performed a single-center retrospective study and included patients who underwent UBE for CSR from April 2023 to May 2024 with a minimum of 6 months of follow-up. A total of 25 patients underwent UBE for CSR during this period. The inclusion criteria were as follows: (1) Patients with cervical radicular symptoms without severe neck pain and refractory to conservative management for at least 6 to 8 weeks; (2) a diagnosis of CSR based on clinical history, physical examination, and imaging studies; (3) single-level pathology; (4) absence of central pathology causing myelopathy; (5) the absence of significant instability, infection, fracture, or previous spinal surgery history; and (6) minimum of 6 months of follow up. Patients with cervical spondylodiscitis, cervical myelopathy due to ossification of the posterior longitudinal ligament, or cervical spine trauma were excluded. Five patients were excluded due to shorter follow-up; thus, 20 patients were included in the study. Patient's demographic data, perioperative data, and length of hospital stay were reviewed. Clinical outcomes were assessed using visual analog scale (VAS)¹⁹ scores for neck and arm pain and Neck Disability Index (NDI)²⁰ preoperatively and at 1 and 6 months. Written informed consent was obtained from the patient and their family.




Figure 1. Patient prone on Jackson table with Gillespie pillow support to reduce abdominal pressure.

Surgical Technique

Patient Position

Under general anesthesia, the patient is positioned prone on a radiolucent table. Eyes and chin are protected from direct pressure using foam blocks, and the neck is slightly flexed and fixed with plaster tapes. Traction is applied on the shoulders bilaterally and fixed with plaster tapes as well. The abdomen is relaxed using an H-shaped pillow to avoid increased abdominal pressure. A head-end-up, feet-end-down slanted position is applied to ensure good venous return to reduce chances of intraoperative bleeding (Figure 1).

Level Marking and Incisions

After proper positioning of the patient, the surgical level is marked under fluoroscopic guidance in both anteroposterior (AP) and lateral projection. Sometimes it becomes difficult to localize the C6 to C7 and C7 to T1 level under lateral fluoroscopy view due to overlapping soft tissues of the shoulders; thus, a proper AP view is necessary. To mark 2 portals, two 18-gauge spinal needles are placed on the cranial and caudal midpoint of the lateral mass of the target level under the guidance of true AP and lateral fluoroscopy projection (Figure 2). The distance between the 2 portals is normally kept around 2 cm to avoid crossinterference. We inject around 0.5 mL methylene blue dye through the spinal needles to help in identifying the level intraoperatively as the dye stains the area. Alternatively, a check c-arm fluoroscopic image can be taken with an instrument inside to confirm the level. Next step is to make the incisions for the portals. In our practice, we make the camera portal incision first, and

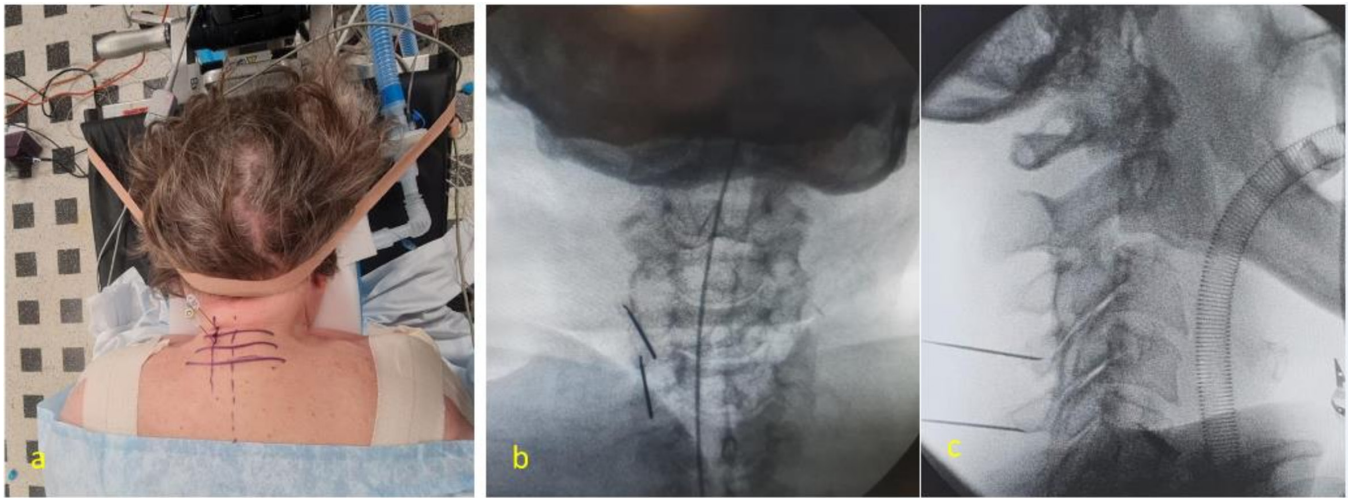


Figure 2. (a) Showing two 18 gauge spinal needles inserted on midpoint of C4 and C5 lateral masses. (b and c) Showing AP and lateral fluoroscopic images, respectively, of needle placement.

then, we proceed to make the incision on the working portal. The cervical fascia must be incised with a size 10 blade to ensure proper functioning of portals and also for adequate drainage of irrigation fluid. At our center, we use 3000 cc saline bag and placed it at a height of around 40 cm above the operation area and adjust as per the flow. This height normally keeps flow pressure below 30 mm Hg and avoids damage to the cord. Serial dilators are inserted to dissect the neck muscle and acquire operative space around the V-point (junction of superior and inferior lamina with the medial point of facet joint). Triangulation is done

with a 0° scope inserted through the scope portal and a surgical instrument through the working portal.

Foraminotomy and Decompression

With the radiofrequency probe, soft tissues around the V-point are cleared, bleeding is controlled, and the surgical field is exposed. Partial laminectomy-facetectomy is done using a 3.5-mm diamond tip burr starting from the V-point (Figure 3). The inferolateral portion of the cranial lamina is drilled in a craniolateral direction until the attachment of ligament flavum.

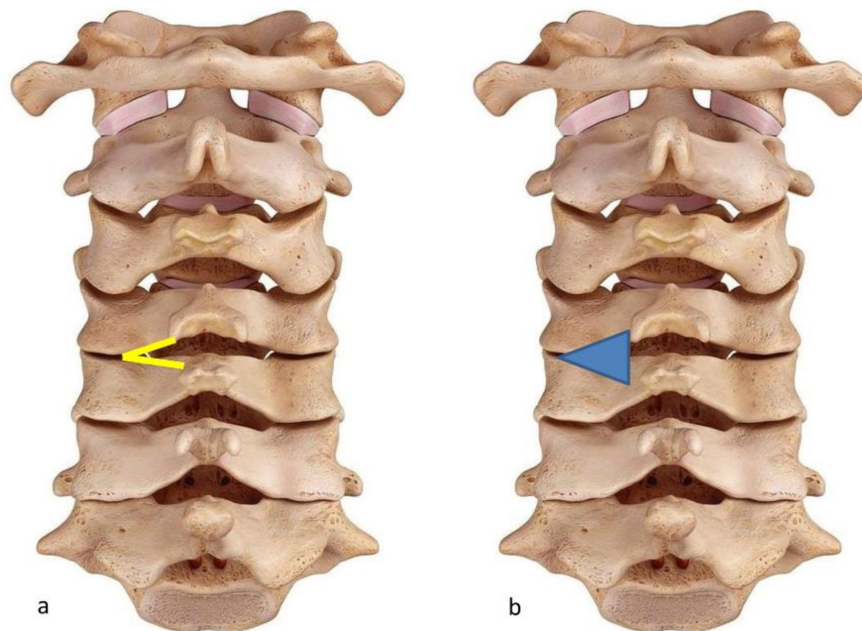


Figure 3. (a) V-point which is the junction of superior and inferior lamina with the medial aspect of facet joint. (b) Area marked is the extent of partial laminectomy-facetectomy.

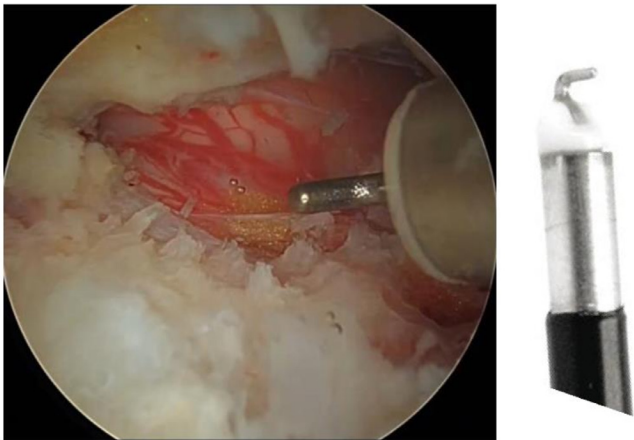


Figure 4. Hook-tipped radiofrequency probe to coagulate epidural vessels.

Similarly, the superolateral portion of the caudal lamina is drilled in a caudolateral direction until the bone is thin like an eggshell. Following this, the medial one-third to one-half is progressively removed. Up to 50% of the facet joint can be removed without causing iatrogenic instability.^{21,22} The ligamentum flavum is preserved until the bone work is done to prevent accidental injury to the neural structures while drilling. Once the flavum is removed, the medial border of the pedicle is identified first to establish the surgical anatomy of the dura and the nerve root. At this stage, we normally used hook-tipped radiofrequency probe to achieve hemostasis safely (Figure 4). The exiting nerve root is identified and decompressed with a 1-mm Kerrison punch. If the pathology is a disc herniation, the nerve root is safely retracted using the scope cannula sheath (Figure 5), and the disc herniation is safely removed. If there is less workspace to remove the disc, pediculotomy can be done to achieve more space around the nerve root so

that it can be retracted safely. Using a ball tip hook, the lateral margin of the pedicle is palpated to ensure adequate foraminal decompression. Irrigation flow is stopped, and a hemostatic agent (FloSeal- Baxter) is injected through the working portal and kept for 2 minutes before flushing out. The FloSeal consists of a bovine-derived gelatin component and a human-derived thrombin component mixed with prefilled sodium chloride solution. The patient is checked again for any bleeders before closure. We normally do not put in a drain. Closure is done with subcutaneous suture with monocryl and steristrips applied over it.

Illustrated Case 1: C6 to C7 Left Discectomy

A 37-year-old man came to our outpatient clinic with neck pain radiating to the left upper limb and pins and needles for 8 weeks. Neck pain had a VAS score of 3, while upper limb pain had a score of 7. Examination results showed a positive Spurling sign, a Medical Research Council grade 4 for triceps, and hypoaesthesia in the left C7 dermatome. Conservative care, which included medication, rest, and physical therapy, did not work. An MRI revealed that the C7 nerve root was compressed by a left C6 to C7 paracentral disc herniation (Figure 6). V-point and the left C6 to C7 interlaminar space were identified. The underlying flavum was exposed with a partial hemilaminectomy and facetectomy of C6 to C7. The ligamentum flavum was removed, and the C7 nerve root was retracted gently using a scope cannula sheath to expose the bulging disc. Prolapsed disc fragment was removed, and C7 nerve root was decompressed (Figure 6). On the first postoperative day, the VAS was 3 for neck pain and 1 for pain

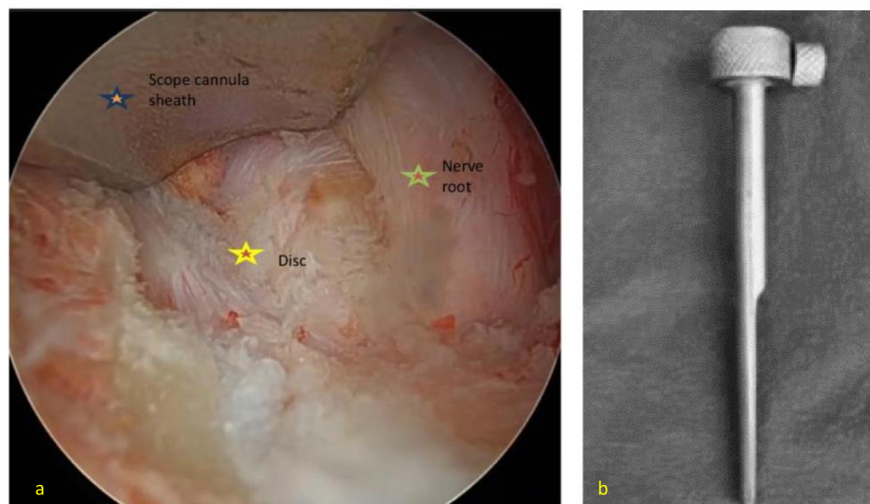


Figure 5. (a) Scope cannula sheath safely retracting nerve root to expose the disc. (b) Scope cannula sheath.

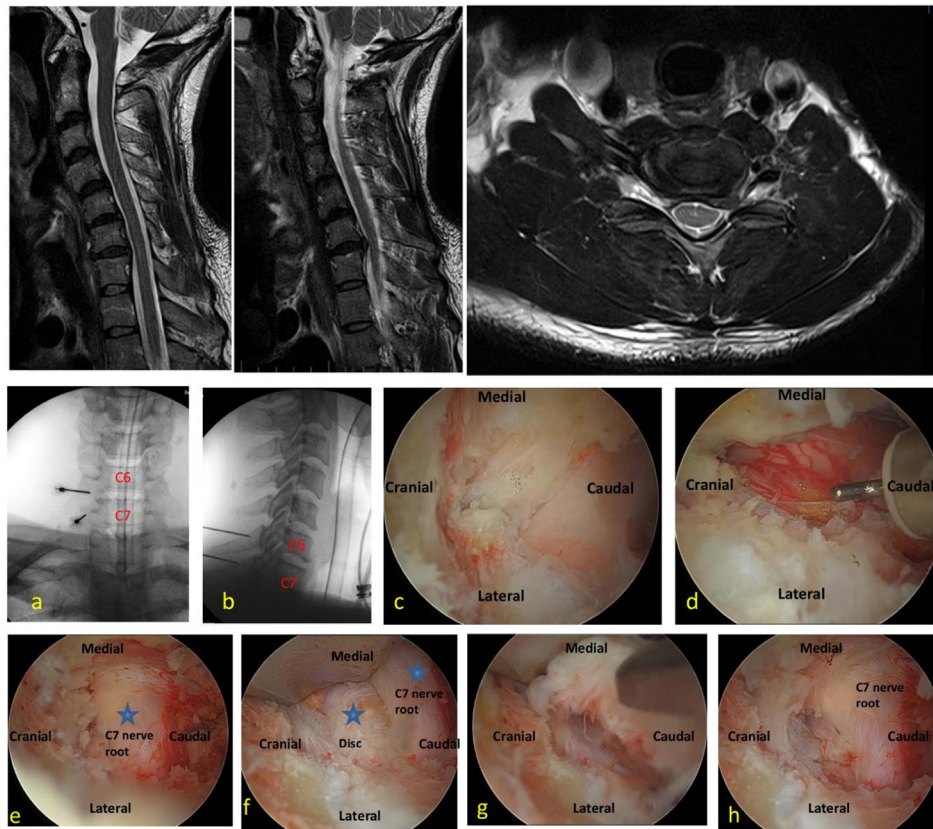


Figure 6. T2-weighted magnetic resonance images with sagittal, left oblique, and axial views showing C6–C7 left-sided paracentral disc herniation compressing the left C7 nerve root. (a and b) Spinal needle placement and level marking. (c) Identifying the V point and drilling the C6 inferior lamina and C7 superior lamina along with C6–C7 facet joint till the bone is like an eggshell. (d) The ligamentum flavum is exposed and epidural vessels coagulated with a hook-tipped radiofrequency probe. (e) The C7 nerve root is exposed. (f) Scope cannula sheath retracting the C7 nerve root to expose the disc. (g and h) Disc fragment removed and C7 nerve root decompressed.

in the left upper limb. Three weeks after surgery, C7 motor function was back to normal.

Statistical Analysis

Data were presented as mean \pm SD or SEM. Data analysis was done using SPSS version 13. Repeated analysis of variance test was used to assess statistical significance. P value < 0.05 was considered statistically significant.

RESULTS

The cohort consisted of 20 patients. The demographic parameters are shown in Table 1. The mean follow-up period was 8.4 ± 1.8 months (7–11 months).

Table 1. Demographic data of patients ($n = 20$) undergoing unilateral biportal endoscopic decompression for cervical spondylotic radiculopathy.

Demographic	Value
Age, y, mean \pm SD	56.7 ± 10.2
Sex, n , male/female	15/5
Preoperative duration of symptoms, mo, mean \pm SD	4.6 ± 2.3
Follow-up, mo, mean \pm SD	8.4 ± 1.8

The pathology causing cervical nerve root compression is summarized in Table 2. The mean length of hospital stay was 1 day. The mean duration of surgery was 64.3 ± 10.6 minutes (Table 3). Exact estimated blood loss could not be recorded due to continuous water irrigation throughout the procedure. The majority of the patients were ambulatory within 24 hours. No immediate or delayed complications were recorded.

Clinical outcome measures are listed in Table 4. At the final follow-up, the mean VAS for arm pain improved from 6.4 ± 0.7 to 0.6 ± 0.5 (92% improvement), and the mean VAS for neck pain improved from 3.3 ± 0.4 to 2.0 ± 0.2 (40% improvement). NDI score significantly improved from 23.2 ± 1.95 to 5.7 ± 0.6 (75% improvement).

Table 2. Pathology causing cervical nerve root compression.

Cause	n
Disc herniation	14
Disc osteophyte complex	4
Facet hypertrophy	2

DISCUSSION

CSR is 1 of the most commonly seen conditions in an outpatient spine clinic. Most patients experience neuropathic radicular pain, which is typically managed conservatively. However, if conservative treatment fails, surgical decompression is recommended to alleviate symptoms. The most important aspect of CSR surgical therapy is the effective decompression and release of nerve structures. This can be accomplished by a variety of surgical procedures, including ACDF, cervical disc replacement, conventional posterior foraminotomy, microscopic posterior cervical foraminotomy, and more recently discovered endoscopic approaches. Percutaneous endoscopic cervical discectomy with a small single portal was developed a decade ago and has been found to lessen surgical trauma while effectively reducing compression.¹⁷ Nonetheless, accessing and working through the same small doorway offered several obstacles, including difficulty maneuvering.²³

UBE decompression is a novel minimally invasive endoscopic procedure for decompressing spinal neuronal tissues. UBE with 2 portals has substantial advantages over uniportal endoscopic surgery, including a larger surgical field and greater freedom of working instruments as the viewing and working portals are separate and independent of each other. The surgeon has discrete viewing and working ports for easy maneuvering with working instruments. Continuous irrigation helps to minimize intraoperative complications, alleviates postoperative pain,²⁴ and reduces the chance of infection.^{24,25} Another advantage is that this procedure allows the surgeon to utilize the same conventional instruments as open decompression techniques.

Our sample included 20 patients with a male predominance, and the most common levels involved were C5 to C6 and C6 to C7. This is consistent with previous research on the natural history of cervical spondylosis.^{26,27} Our study found more clinical improvement than other studies, as evidenced by improved VAS scores for arm and neck pain and NDI. At the final follow-up, the mean VAS for arm pain improved from 6.4 ± 0.7 to 0.6 ± 0.5 (92% improvement), whereas the mean VAS for neck pain improved from 3.3 ± 0.4 to 0.6 ± 0.5 (92% improvement), whereas the mean VAS for neck pain improved from 3.3 ± 0.4 to 0.6 ± 0.5 (92% improvement).

Table 3. Operative and perioperative data.

Variable	Value
Level, <i>n</i>	
C1–C2	0
C2–C3	1
C3–C4	1
C4–C5	2
C5–C6	7
C6–C7	8
C7–T1	1
Surgical time, min, mean \pm SD	64.3 ± 10.6
Complications, <i>n</i>	0
Length of stay, d, mean	1

2.0 ± 0.2 (40% improvement). The NDI score improved from 23.2 ± 1.95 to 5.7 ± 0.6 (75% improvement). The clinical outcomes were similar to prior research by Park et al.²⁸ In their series of 13 patients, Park et al found that the mean length of stay in the hospital was 2.5 days (2–5 days). Our cohort's mean length of stay in the hospital was 1 day, which can be attributed to shorter surgical times and consequently lower usage of general anesthesia. Zheng et al²⁹ reported on the outcomes of UBE foraminotomy combined with piezosurgery in 12 CSR patients. Instead of a rotating burr, they employed a piezosurgery instrument that uses microvibrations to cut bone precisely while avoiding neurovascular damage. Their study found that VAS and NDI scores improved after a mean follow-up of 16.8 months, indicating positive clinical outcomes. Their study found a mean operation time of 251.2 ± 14.6 minutes, approximately 4 times that of ours (64.3 ± 10.6 minutes).

There were no intraoperative complications reported in our cohort. Throughout the follow-up period, none of the patients reported persistent or worsening discomfort. None of the patients underwent revision surgery throughout the follow-up period. Possible complications documented in the literature include a dural tear, nerve root injury, increased intraoperative bleeding, epidural hematoma, and an increase in epidural pressure resulting from increased irrigating saline pressure, which can cause postoperative headache, seizures, intracranial hematoma, and blindness.^{30–35} These complications can be reduced by taking the following precautions during surgery:

Table 4. Clinical outcome measures: VAS score for arm and neck pain and NDI score.

Outcome Measure	Preoperative	1 mo Postoperatively	6 mo Postoperatively	Improvement at 6 mo	<i>P</i>
VAS arm pain	6.4 ± 0.7	1.3 ± 0.5	0.6 ± 0.5	92%	0.001
VAS neck pain	3.3 ± 0.4	2.5 ± 0.2	2.0 ± 0.2	40%	0.001
NDI	23.2 ± 1.95	11.5 ± 2.7	5.7 ± 0.6	75%	0.001

Abbreviations: NDI, neck disability index; VAS, visual analog scale.

Note: VAS and NDI scores are provided as mean \pm SD.

1. Intraoperative bleeding: (a) Proper positioning of the patient with head up and feet down to ensure patent venous return; (b) mean arterial pressure around 90 mm Hg and heart rate <60 beats per minute; (c) use of diamond burr to reduce bone bleeding; (d) bone wax can also be used to stop persistent bone bleed; and (e) use of small tip radiofrequency probe to control epidural vessel bleeding and muscular bleeding.
2. Dural tear: (a) Keep the ligament flavum intact until the bone drill work is done; (b) drill work following flavectomy should be judiciously done as dust obscures clear vision; (c) Kerrison punch should be used cautiously under clear vision; (d) small dural tear can be closed with a fibril sealant or sutureless nonpenetrating clips;^{36,37} and (e) if the tear is large or primary repair fails, the procedure should be converted to open microscopic surgery for repair.³⁴
3. Epidural hematoma: (a) Control of bleeders with radiofrequency coagulation throughout the procedure; (b) use of hemostatic agent³⁸ (FloSeal; Baxter) at the end and flush it after 2 minutes and check for any bleeders before closure; and (c) use of drain for a day or 2.
4. Increased epidural pressure: (a) Keep the irrigating saline pressure below 30 mm Hg and (b) keep the surgical duration to optimum as excessive and prolonged irrigation can cause meningeal irritation and headache.^{33,39}
5. Nerve root injury: (a) Avoid excessive traction while retracting nerve root during discectomy; (b) careful use of burr and Kerrison punch while doing pediculotomy; and (c) small tip radiofrequency probe should be carefully used while coagulating epidural vessels near the nerve root.

Limitations

There are several limitations to this study: (1) It was a single-center retrospective study with a small sample size; (2) a brief follow-up period, making it unable to establish long-term results; (3) no radiological outcomes; (4) no comparison group. Future research should carry out a bigger multicenter prospective comparative analysis to establish the long-term outcomes of this novel technique.

CONCLUSION

The current study suggests that UBE decompression is a safe and effective surgical treatment option for CSR

patients with good short-term clinical outcomes, shorter duration of surgery, and reduced length of hospital stay. It provides a clear and magnified view of the surgical field, as well as easy handling and manipulation of the operating equipment, reducing the risk of iatrogenic neurovascular injury. UBE minimizes the risk of post-operative instability and deterioration in sagittal parameters by avoiding iatrogenic damage to the posterior cervical musculoligamentous tissues and minimizing facet joint violation.

REFERENCES

1. Hu J, Chen F, Qiu G, et al. Jingshu keli for treating cervical spondylotic radiculopathy: the first multicenter, randomized, controlled clinical trial. *J Orthop Translat.* 2021;27:44–56. doi:10.1016/j.jot.2020.10.010
2. Childress MA, Becker BA. Nonoperative management of cervical radiculopathy. *Am Fam Physician.* 2016;93(9):746–754.
3. Kelly MP, Eliasberg CD, Riley MS, Ajiboye RM, SooHoo NF. Reoperation and complications after anterior cervical discectomy and fusion and cervical disc arthroplasty: a study of 52,395 cases. *Eur Spine J.* 2018;27(6):1432–1439. doi:10.1007/s00586-018-5570-8
4. Sudprasert W, Kunakornsawat S. A preliminary study of three and four levels degenerative cervical spondylosis treated with peek cages and anterior cervical plate. *J Med Assoc Thai.* 2012;95(7):909–916.
5. Hacker RJ, Cauthen JC, Gilbert TJ, Griffith SL. A prospective randomized multicenter clinical evaluation of an anterior cervical fusion cage. *Spine.* 2000;25(20):2646–2655. doi:10.1097/00007632-200010150-00017
6. Skeppholm M, Lindgren L, Henriques T, Vavrouch L, Löfgren H, Olerud C. The discover artificial disc replacement versus fusion in cervical radiculopathy--a randomized controlled outcome trial with 2-year follow-up. *Spine J.* 2015;15(6):1284–1294. doi:10.1016/j.spinee.2015.02.039
7. Alhashash M, Shousha M, Boehm H. Adjacent segment disease after cervical spine fusion: evaluation of a 70 patient long-term follow-up. *Spine.* 1976;43(9):605–609. doi:10.1097/BRS.0000000000002377
8. Shriver MF, Lewis DJ, Kshettry VR, Rosenbaum BP, Benzel EC, Mroz TE. Pseudoarthrosis rates in anterior cervical discectomy and fusion: a meta-analysis. *Spine J.* 2015;15(9):2016–2027. doi:10.1016/j.spinee.2015.05.010
9. Lee MJ, Bazaz R, Furey CG, Yoo J. Risk factors for dysphagia after anterior cervical spine surgery: a two-year prospective cohort study. *Spine J.* 2007;7(2):141–147. doi:10.1016/j.spinee.2006.02.024
10. Cho SK, Lu Y, Lee DH. Dysphagia following anterior cervical spinal surgery: a systematic review. *Bone Joint J.* 2013;95-B(7):868–873. doi:10.1302/0301-620X.95B7.31029
11. Patel NP, Wolcott WP, Johnson JP, et al. Esophageal injury associated with anterior cervical spine surgery. *Surg Neurol.* 2008;69(1):20–24. doi:10.1016/j.surneu.2007.05.006
12. Netterville JL, Koriwchak MJ, Winkle M, Courey MS, Ossoff RH. Vocal fold paralysis following the anterior approach to the cervical spine. *Ann Otol Rhinol Laryngol.* 1996;105(2):85–91. doi:10.1177/000348949610500201

13. Maharaj MM, Mobbs RJ, Hogan J, Zhao DF, Rao PJ, Phan K. Anterior cervical disc arthroplasty (ACDA) versus anterior cervical discectomy and fusion (ACDF): a systematic review and meta-analysis. *J Spine Surg.* 2015;1(1):72–85. doi:10.3978/j.issn.2414-469X.2015.09.01
14. Parish JM, Asher AM, Coric D. Complications and complication avoidance with cervical total disc replacement. *Int J Spine Surg.* 2020;14(s2):S50–S56. doi:10.14444/7091
15. Hosono N, Yonenobu K, Ono K. Neck and shoulder pain after laminoplasty. A noticeable complication. *Spine.* 1976;21(17):1969–1973. doi:10.1097/00007632-199609010-00005
16. Jagannathan J, Sherman JH, Szabo T, Shaffrey CI, Jane JA. The posterior cervical foraminotomy in the treatment of cervical disc/osteophyte disease: a single-surgeon experience with a minimum of 5 years' clinical and radiographic follow-up. *SPI.* 2009;10(4):347–356. doi:10.3171/2008.12.SPINE08576
17. Ruetten S, Komp M, Merk H, Godolias G. Full-endoscopic cervical posterior foraminotomy for the operation of lateral disc herniations using 5.9-mm endoscopes. *Spine.* 2008;33(9):940–948. doi:10.1097/BRS.0b013e31816c8b67
18. Choi J, Akbari K, Amaya J, Rizkalla J. Interlaminar laminectomy/discectomy techniques and outcomes. *Semin Spine Surg.* 2024;36(1). doi:10.1016/j.semss.2024.101082
19. Gallagher EJ, Liebman M, Bijur PE. Prospective validation of clinically important changes in pain severity measured on a visual analog scale. *Ann Emerg Med.* 2001;38(6):633–638. doi:10.1067/mem.2001.118863
20. Vernon H, Mior S. The neck disability index: a study of reliability and validity. *J Manipul Physiol Ther.* 1991;14(7):409–415.
21. Voo LM, Kumaresan S, Yoganandan N, Pintar FA, Cusick JF. Finite element analysis of cervical facetectomy. *Spine.* 1997;22(9):964–969. doi:10.1097/00007632-199705010-00006
22. Zdeblick TA, Zou D, Warden KE, McCabe R, Kunz D, Vanderby R. Cervical stability after foraminotomy. A biomechanical in vitro analysis. *J Bone Joint Surg Am.* 1992;74(1):22–27.
23. Ahn Y. Percutaneous endoscopic decompression for lumbar spinal stenosis. *Expert Rev Med Devices.* 2014;11(6):605–616. doi:10.1586/17434440.2014.940314
24. Park S-R, Yoon Y-H, Kim N-H, et al. Effect of saline irrigation temperature difference on postoperative acute pain and hypothermia during biportal endoscopic spine surgery. *Eur Spine J.* 2024;27. doi:10.1007/s00586-024-08322-6
25. Soliman HM. Irrigation endoscopic discectomy: a novel percutaneous approach for lumbar disc prolapse. *Eur Spine J.* 2013;22(5):1037–1044. doi:10.1007/s00586-013-2701-0
26. Kelly JC, Groarke PJ, Butler JS, Poynton AR, O'Byrne JM. The natural history and clinical syndromes of degenerative cervical spondylosis. *Adv Orthop.* 2012. doi:10.1155/2012/393642
27. Matsumoto M, Fujimura Y, Suzuki N, et al. MRI of cervical intervertebral discs in asymptomatic subjects. *J Bone Joint Surg Br.* 1998;80(1):19–24. doi:10.1302/0301-620x.80b1.7929
28. Park JH, Jun SG, Jung JT, Lee SJ. Posterior percutaneous endoscopic cervical foraminotomy and discectomy with unilateral biportal endoscopy. *Orthopedics.* 2017;40(5):e779–e783. doi:10.3928/01477447-20170531-02
29. Zhang P, Jin Y, Zhu B, Zheng M, Ying X, Zheng Q. Unilateral biportal endoscopic foraminotomy and discectomy combined with piezosurgery for treating cervical spondylotic radiculopathy with neuropathic radicular pain. *Front Neurol.* 2023;14. doi:10.3389/fneur.2023.1100641
30. Ikuta K, Tono O, Tanaka T, et al. Surgical complications of microendoscopic procedures for lumbar spinal stenosis. *Minim Invasive Neurosurg.* 2007;50(3):145–149. doi:10.1055/s-2007-985152
31. Podichetty VK, Spears J, Isaacs RE, Booher J, Biscup RS. Complications associated with minimally invasive decompression for lumbar spinal stenosis. *J Spinal Disord Tech.* 2006;19(3):161–166. doi:10.1097/01.bsd.0000188663.46391.73
32. Sairyo K, Sakai T, Higashino K, Inoue M, Yasui N, Dezawa A. Complications of endoscopic lumbar decompression surgery. *Minim Invasive Neurosurg.* 2010;53(4):175–178. doi:10.1055/s-0030-1262814
33. Hwa Eum J, Hwa Heo D, Son SK, Park CK. Percutaneous biportal endoscopic decompression for lumbar spinal stenosis: a technical note and preliminary clinical results. *J Neurosurg Spine.* 2016;24(4):602–607. doi:10.3171/2015.7.SPINE15304
34. Joh JY, Choi G, Kong BJ, Park HS, Lee SH, Chang SH. Comparative study of neck pain in relation to increase of cervical epidural pressure during percutaneous endoscopic lumbar discectomy. *Spine.* 2009;34(19):2033–2038. doi:10.1097/BRS.0b013e3181b20250
35. Lin C-Y, Chang C-C, Tseng C, et al. Seizure after percutaneous endoscopic surgery-incidence, risk factors, prevention, and management. *World Neurosurg.* 2020;138:411–417. doi:10.1016/j.wneu.2020.03.121
36. Heo DH, Ha JS, Lee DC, Kim HS, Chung HJ. Repair of incidental durotomy using sutureless nonpenetrating clips via biportal endoscopic surgery. *Glob Spine J.* 2022;12(3):452–457. doi:10.1177/2192568220956606
37. Heo DH, Hong YH, Lee DC, Chung HJ, Park CK. Technique of biportal endoscopic transforaminal lumbar interbody fusion. *Neurospine.* 2020;17(Suppl 1):S129–S137. doi:10.14245/ns.2040178.089
38. Le Huec JC, AlEissa S, Bowey AJ, et al. Hemostats in spine surgery: literature review and expert panel recommendations. *Neurospine.* 2022;19(1):1–12. doi:10.14245/ns.2143196.598
39. Choi G, Kang H-Y, Modi HN, et al. Risk of developing seizure after percutaneous endoscopic lumbar discectomy. *J Spinal Disord Tech.* 2011;24(2):83–92. doi:10.1097/BSD.0b013e3181ddf124

Funding: The authors received no financial support for the research, authorship, and/or publication of this article.

Declaration of Conflicting Interests: The authors report no conflicts of interest in this work.

Corresponding Author: Dr Keyur K. Akbari, Spine Ortho Clinic, The Bays Hospital, Suite 10, 1st Floor, Vale St, Mornington, VIC 3931, Australia; keyur21088@yahoo.co.in

Published 11 November 2024

Copyright © 2025 ISASS. The IJSS is an open access journal following the Creative Commons Licensing Agreement CC BY-NC-ND. To learn more or order reprints, visit <http://ijssurgery.com>.