

INTERNATIONAL
JOURNAL
of
SPINE
SURGERY

Two-year clinical and radiographic success of minimally invasive lateral transpsoas approach for the treatment of degenerative lumbar conditions

Burak M. Ozgur, Vijay Agarwal, Erin Nail and Luiz Pimenta

Int J Spine Surg 2010, 4 (2) 41-46
doi: <https://doi.org/10.1016/j.esas.2010.03.005>
<https://www.ijssurgery.com/content/4/2/41>

This information is current as of May 17, 2025.

Email Alerts Receive free email-alerts when new articles cite this article. Sign up at:
<http://ijssurgery.com/alerts>

Minimally invasive surgery

Two-year clinical and radiographic success of minimally invasive lateral transpoas approach for the treatment of degenerative lumbar conditions

Burak M. Ozgur, MD ^{a,*}, Vijay Agarwal, MD ^a, Erin Nail, BS, NP ^{b,c},
Luiz Pimenta, MD, PhD ^d

^a Department of Neurosurgery, Cedars-Sinai Medical Center, Los Angeles, CA

^b Division of Neurosurgery, University of California, San Diego, San Diego, CA

^c Seattle Pacific University, Seattle, WA

^d Santa Rita Hospital, Sao Paulo, Brazil

Abstract

Background: The lateral transpoas approach to interbody fusion is a less disruptive but direct-visualization approach for anterior/ anterolateral fusion of the thoracolumbar spine. Several reports have detailed the technique, the safety of the approach, and the short term clinical benefits. However, no published studies to date have reported the long term clinical and radiographic success of the procedure.

Materials and methods: The current study is a retrospective chart review of prospectively collected clinical and radiographic outcomes in 62 patients having undergone the Anterolateral transpoas procedure at a single institution for anterior column stabilization as treatment for degenerative conditions, including degenerative disk disease, spondylolisthesis, scoliosis, and stenosis. Only patients who were a minimum of 2 years postoperative were included in this evaluation. Clinical outcomes measured included visual analog pain scales (VAS) and Oswestry disability index (ODI). Radiographic outcomes included identification of successful arthrodesis.

Results: Sixty-two patients were treated with lateral interbody fusion between 2003 and December 2006. Twenty-six patients (42%) were single-level, 13 (21%) 2-level, and 23 (37%) 3- or more levels. Forty-five (73%) included supplemental posterior pedicle fixation, 4 (6%) lateral fixation, and 13 (21%) were stand-alone. Pain scores (VAS) decreased significantly from preoperative to 2 years follow-up by 37% ($P < .0001$). Functional scores (ODI) decreased significantly by 39% from preoperative to 2 years follow-up ($P < .0001$). Clinical success by ODI-change definition was achieved in 71% of patients. Radiographic success was achieved in 91% of patients, with 1 patient with pseudarthrosis requiring posterior revision.

Conclusion: The lateral transpoas approach is similar to a traditional anterior lumbar interbody fusion, in that access is obtained through a retroperitoneal, direct-visualization exposure, and a large implant can be placed in the interspace to achieve disk height and alignment correction. The 2 years plus clinical and radiographic success rates are similar to or better than those reported for traditional anterior and posterior approach procedures, which, coupled with significant short-term benefits of minimal morbidity, make the lateral approach a safe and effective treatment option for anterior/anterolateral lumbar fusions.

© 2010 SAS - The International Society for the Advancement of Spine Surgery. Published by Elsevier Inc. All rights reserved.

Keywords: Minimally invasive; Lateral fusion; Lateral transpoas; Anterolateral

Lumbar interbody fusion has been recognized as an advantageous procedure in the management of degenerative conditions.^{1,2} Although interbody fusion has been successful with high patient satisfaction and fusion rates,^{3–7} traditional open approaches to the spine have reportedly led to

complications such as excessive blood loss, iatrogenic muscle and soft tissue injury, muscular denervation and loss of strength, and increased postoperative pain.^{8,9}

Minimally disruptive approaches to spinal fusion have been gaining popularity as surgeons seek to reduce approach-related morbidity, improve cosmesis, and enhance a speedy recovery and return to normal activity.^{8–17} In recent history, challenges have hindered wide-spread implementation of many minimally invasive techniques. Most techniques have been accomplished through the use of tubular

* Corresponding author: Burak M. Ozgur, MD, Director of Minimally Invasive Spine Surgery, Assistant Professor of Neurosurgery, Department of Neurosurgery, Cedars-Sinai Medical Center, 8631 W. Third Street, Suite 800E, Los Angeles, CA 90048.

E-mail address: Burak.Ozgur@cshs.org

exposures and endoscopic visualization. Working coaxially through tubular portals limits anatomical access and relies on 2-dimensional images for visualization, thus requiring thorough knowledge of the 3-dimensional (3-D) spinal anatomy with recognition of anatomical landmarks within limited fields of view. Additionally, tubular exposures can be technically challenging as they require working in a smaller window with longer instruments,⁹ which can be associated with a steep learning curve. Consequently, these limitations have been thought by some to result in having to compromise underlying surgical objectives for minimally invasive benefits.

Surgical approaches, however, need not use tubular exposures and endoscopic visualization to gain less invasive benefits. Traditional exposures have been reduced in size in recent years to “mini-open” access, retaining conventional surgical techniques such as direct visualization and the use of standard instruments and implants, and resulting in both lower postoperative morbidity and ultimate clinical success.^{17–30} The lateral transposas or extreme lateral interbody fusion approach is one such example. It is a variation on the mini-open anterior lumbar interbody fusion (ALIF) procedure—approaching the anterolateral spine through the retroperitoneal fat and psoas major muscle—and it provides the surgeon with a less invasive access to the anterior lumbar spine and direct visualization for disk space distraction and fusion. While this approach and its early outcomes have been well described,^{18,27,28,31–35} there is little reported on the long-term results of lateral interbody fusion in the literature.

Materials and methods

The current study is a retrospective chart review of prospectively collected clinical and radiographic outcomes in patients having undergone the anterolateral transposas approach procedure at a single academic institution for anterior column stabilization as treatment for degenerative conditions.

Patient selection and surgical indications

Patients were considered candidates for this surgery if they presented with axial low back pain or radiculopathy due to degenerative conditions, and if they failed at least 6 months of conservative, traditional nonoperative management. Indications are not dissimilar to those for traditional ALIF. Contraindications included severe central canal stenosis, rotatory scoliosis that precluded a lateral approach, and moderate to severe spondylolisthesis (\geq Grade 3). In some patients, discography was used as a tool to assist in level selection.

During preoperative consultation, all patients were informed of all surgical options. A complete discussion and description of the approach technique, as has been reported in detail in the literature,^{18,27,28} was described to all patients

interested in the procedure. Informed consent for surgery was attained for every patient.

Clinical outcomes

Institutional review board (IRB) approval was obtained to retrospectively review the charts of patients who underwent the anterolateral transposas procedure at a single academic institution between 2003 and December 2006. All patients who were a minimum 2 years post-surgery were included in the analysis.

Chart review included compilation of demographics (age, gender), symptoms and diagnosis, surgical details (levels treated, instrumentation used, blood loss, complications), hospital stay, additional procedures, results of physical exams, late-occurring complications and patient complaints, prospectively collected back and leg pain scores (visual analog scale, VAS) and functional outcome scores (Oswestry disability index, ODI, as well as radiographic fusion assessment). Radiographic review included assessment of fusion at 12 months, 24 months, or beyond. Fusion was defined as bridging trabecular bone and lack of lucencies on plain radiographs. Additionally, patients without symptomatic pseudarthrosis, regardless of appearance on radiographs, were classified as clinically fused.

Statistical methods

Differences in clinical outcomes scores from preoperative to 2 years postoperative time-points were tested using paired *t* tests. Influences of demographic and other descriptive characteristics on the outcomes were evaluated using *t* tests for continuous variables and χ^2 tests for categorical variables as appropriate. All hypothesis testing was performed with a level of significance of .05.

Results

Sixty-two consecutive patients met inclusion criteria for this study. Patients averaged 63.8 years of age (range, 31–88), and were 55% female. Primary diagnoses included 35.5% degenerative scoliosis, 32.2% DDD, 22.6% spondylolisthesis, and 9.7% stenosis. Presenting symptoms included 21% with isolated low back pain, 7% with isolated radicular pain, and 72% combined back and leg pain.

In total, 113 levels were treated. Twenty-six procedures (42%) were single-level, 13 (21%) 2-level, and 23 (37%) 3- or more levels. Forty-eight surgeries (77%) included the L4-5 level. Forty-five (73%) included supplemental posterior pedicle fixation, 4 (6%) lateral fixation, and 13 (21%) were standalone. Fifty-seven (92%) included the use of bone morphogenic protein (BMP), the remainder a mixture of allograft and autograft.

Mean operative time, estimated blood loss, and hospital stay were 240 minutes per patient (156 minutes per level), 183 cc per patient (91 cc per level), and 5 days (range, 1–18), respectively. Early in our experience, multi-level procedures (long-construct scoliosis cases typically) were

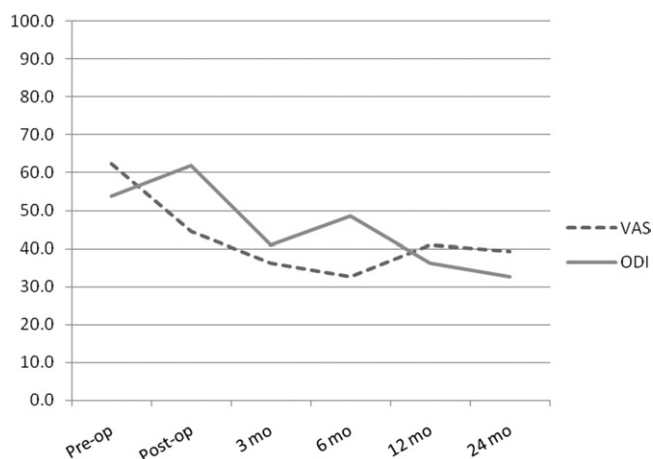


Fig. 1. Chart of average pain (VAS) and function (ODI) scores over time. Both pain and function were statistically significantly reduced at 2 years compared to preoperatively ($P < .0001$). The slight increase in VAS noted from 6 to 24 months was not statistically significant ($P = .6914$), and is presumed to be contributed to by adjacent segment issues and other longitudinal problems unrelated to the primary procedure.

staged, with an average 5 days between anterior reconstruction and posterior instrumentation. Excluding the staged procedures, hospital stays averaged 3.9 days. The majority of patients needed only Vicodin and NSAIDs for analgesia and ambulated on postoperative day 1.

There were no major and 12 (19%) minor complications. These included 3 wound-related events (psoas hematoma identified on postoperative imaging, but not requiring treatment; retroperitoneal dilated colon, not requiring intervention; and a superficial wound infection), 3 respiratory (1 asthma exacerbation; 2 pneumothorax: 1 in a T11-L4 case, and 1 in an L1-4 case following a staged posterior procedure for T12-L5 instrumentation, both identified on postoperative x-ray imaging, but inconsequential, not requiring intervention), 2 gastrointestinal (ileus), 2 cardiovascular (postoperative atrial fibrillation, anemia secondary to blood loss), 1 renal (urinary tract infection), and 1 pseudarthrosis.

Immediate postoperative hip flexion weakness was common, as was bilateral transient upper thigh numbness, as a consequence of the transpsoas approach. These were generally resolved within the first 6 weeks post-surgery. No new postoperative motor neural deficits were detected via standard-of-care physical exams, nor via patient complaint.

Clinical outcomes are charted over time in Fig. 1. Pain scores (VAS) decreased significantly from preoperative to 2 years follow-up by 37% ($P < .0001$). Functional scores (ODI) decreased by 39% from preoperative to 2 years follow-up ($P < .0001$). Clinical success, as defined by minimum 15-point decrease in ODI, was achieved in 71% of patients.

Diagnosis was statistically confounding in patient age ($P = .0133$), the number of levels treated ($P < .0001$), and length of hospital stay ($P = .0258$), all of which were higher in the subset of patients with scoliosis. There was a small but statistical difference in the change in VAS

scores due to diagnosis as well, with a slightly lower average improvement over the 2 years in scoliosis patients ($P = .0404$). The numbers in each group were too small to determine an effect of diagnosis on the ODI outcomes.

Radiographically, fusion success was achieved in 91% of patients. One patient had a pseudarthrosis requiring revision (a 98.4% nonrevision success rate). A representative example of radiographic outcomes, including demonstrative disk height and alignment correction as well as fusion, is shown in Fig. 2. There were no statistical differences in rates of fusion based on diagnosis ($P > .05$).

Discussion

The lateral transpsoas approach

The lateral transpsoas approach is a modification of the anterior retroperitoneal approach to the lumbar spine. The technique was first presented in 2001 by Pimenta,³¹ and has since been reported by several authors as resulting in excellent short-term outcomes.^{18,27,28,31–35} When compared with traditional open and minimally invasive anterior approaches to the lumbar spine, the lateral approach has several advantages. The lateral approach avoids many of the recognized complications of direct anterior approaches, such as vascular injury^{36,37} and retrograde ejaculation.^{38,39} The minimal complication rate reported herein supports prior reports on anterolateral fusion^{32–35} and the safety of the anterolateral approach. The results of the current study are also consistent with reported advantages of other minimally disruptive spinal procedures, including lower blood loss, less muscle atrophy, and superior postoperative trunk muscle strength which lead to a faster and less painful recovery period.^{8–17} Compared with other minimally disruptive techniques, the approach is a relatively straightforward procedure, with a comparatively short learning curve. It uses direct illuminated visualization, rather than endoscopes, allowing for full 3-D visual access as well as the use of standard instruments to complete the procedure effectively.

While it is an optimal choice for many patients, the anterolateral approach is not without restrictions. Patients with the occasional anatomical variance and those with extensive prior surgical scarring may not qualify. Anatomically, the iliac crest limits the potential exposure sites to levels above L5-S1. In addition, psoas traverse, though technically straightforward, must be done carefully so as not to injure the nerves of the lumbar plexus or cause significant trauma to the psoas muscle. Historically, lateral retroperitoneal approaches included mobilization and posterior retraction of the psoas muscle, but unacceptable rates of transient numbness along the genitofemoral nerve were documented.^{40,41} Use of discrete evoked threshold EMG monitoring is critical to the safe passage by the nerves within the psoas muscle. In addition, the preferentially anterior expan-

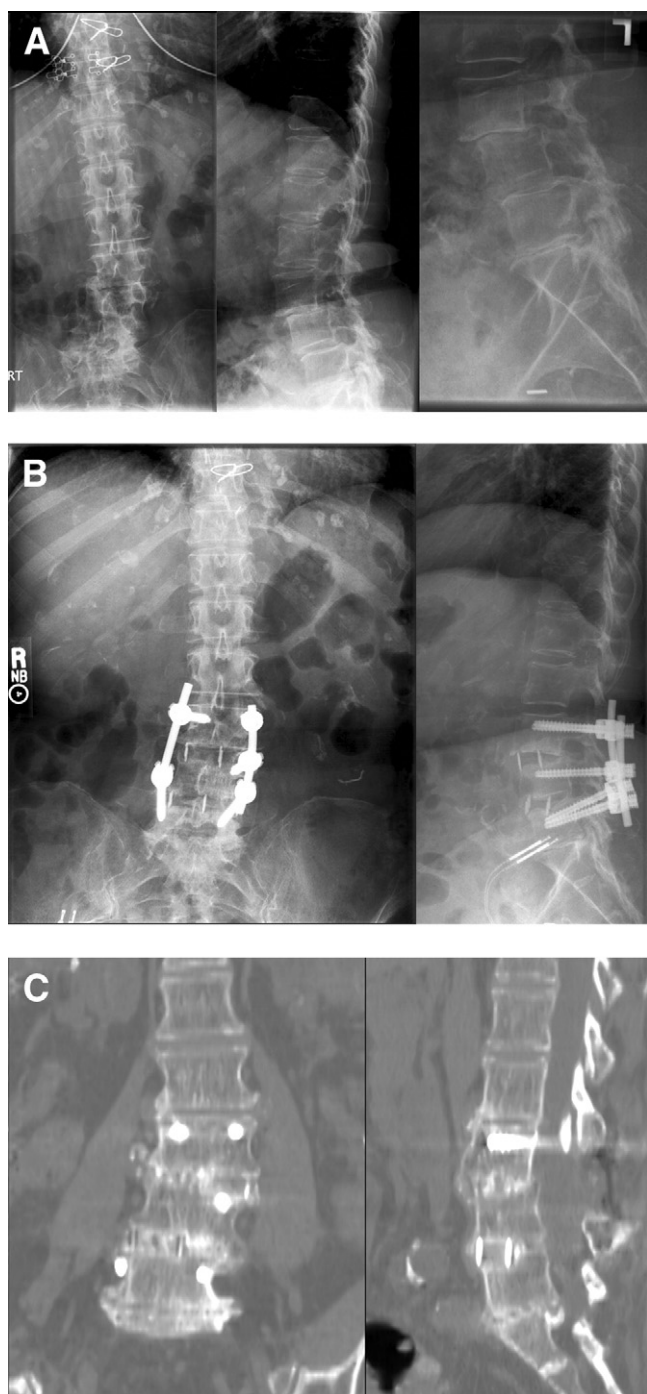


Fig. 2. Preoperative (*top*) radiographs, immediate postoperative (*middle*) radiographs, and 24-month (*bottom*) CT scans of a 68-year-old female anteriolateral fusion patient treated for degenerative spondylolisthesis and scoliosis. Note increase in disk height, correction of coronal and sagittal alignment, and maintenance of corrections as well as bridging bone in 24-month images.

sion of the retractor limits subsequent psoas trauma and lumbar plexus injury.

Despite the purported advantages of less invasive techniques, there has been little documentation of long-term success rates to date.

Clinical outcomes

The operative times and hospital stays reported herein were greater than has been typically reported for this approach. These patients were the surgeons' first of these procedures, and so perhaps represented a learning curve with the technique. With respect to OR time, repositioning the patients for posterior instrumentation does add to the length of the procedure. With respect to length of hospitalization, the average 3.9 days was at the time of the surgeons' early experience with this approach considered a significant decrease from what had been common for interbody fusion at our institution. As the surgeons have become more experienced with this technique and the institution becomes more comfortable with the early recovery of these patients, length of stay continues to decrease.

The pain and function scores in the current study (37% decrease in pain scores and 39% change in ODI scores) are comparable to prior results of interbody fusion. Some of the highest level-of-evidence studies in recent literature are those reported from Food and Drug Administration (FDA) investigational device exemption (IDE) studies. Kuslich et al reported a 42% reduction in pain and 31% improvement in functional outcome.⁴² Sasso et al saw an average 42% improvement in ODI scores.⁴³ The fusion controls from recent total disk replacement studies have further reported clinical success based on a minimum 15 point decrease in ODI score for each patient. ODI success was thus reported at rates between 50–55%.^{44,45} The same studies reported a 32–24% reduction in pain scores at 2 years. By the measure of the 15 point ODI change criterion, clinical success in the current study was achieved in 71% of patients. We attribute the higher ODI success rate in the current study to the inclusion of patients with radicular symptoms from degenerative stenosis, scoliosis, and spondylolisthesis, as opposed to prior studies on DDD and primarily low-back pain, resulting in a relatively higher preoperative baseline score as well as greater opportunity to provide relief through this procedure.

Fusion success

Radiographically, disk heights were restored and stability maintained by preserving ligamentous structures and inserting a large interbody implant, indirectly increasing foraminal volume and reducing radiculopathy. Sagittal balance was maintained or improved by placement of the implant in an anterior position. Coronal imbalances were corrected by ensuring full bilateral endplate coverage by the implant. Corrections were well-maintained through successful arthrodesis. The fusion rates reported in this series are within the ranges of those reported from other fusion studies with an overall fusion rate of 91%. The FDA studies reported fusion rates between 90% and 99% using cages^{42–49} and between 52–75% using allograft spacers.^{43,50}

The relationship between clinical and radiographic success has been debated. Patients who are asymptomatic but do not appear fully fused radiographically present a challenge in reporting success rates. Of the 12% of patients in this study who did not have bridging trabecular bone on plain radiographs, none had motion on flexion/extension films. One patient required posterior revision for pseudarthrosis. By a definition based on the requirement for revision surgery, the current study revision rate of 1.6% results in a nonrevision success rate of 98.4%. In contrast, the fusion cohort in the FDA study reported by Blumenthal et al resulted in a 9% revision rate for pseudarthrosis.⁴⁴ It was 5.4% in Zigler et al's report of circumferential fusion controls.⁴⁵ The lower revision rate in the current study is attributable, in the authors' opinion, to the differences between the procedures from a lateral and a direct anterior approach. Advantages include the ability to preserve the anterior longitudinal ligament and to place a large cage that sits on the ring apophysis bilaterally, both factors contributing to a more stable construct. Additionally, advances in grafting materials may also have contributed to this difference, as the current study used primarily BMP in the interspace, while the study by Blumenthal et al used threaded cylindrical cages (BAK) and autograft.

Limitations of the current study include its retrospective design. While surgical details and clinical outcomes questionnaires were prospectively collected, chart review is only as strong as the follow-up achieved. Longer-term outcomes were only available for a smaller segment of the original cohort. The authors believe the lack of full follow-up artificially skews the positive results of the procedure, since patients who are feeling well tend to decline continued evaluation, whereas those who are less than satisfied are more likely to return for continued care. Prospective multi-center studies with planned follow-up are underway and forthcoming publications may support or refute this assumption.

Fusion rates in the current study were evaluated by standing and flexion-extension radiographs, although it is increasingly common to assess fusion by thin-cut CT evaluation. Few of the patients in this series underwent CT evaluation for fusion; those who did demonstrated fusion, but the numbers were too small to be worthy of inclusion in this analysis. It has since become the authors' standard practice to obtain CTs for the evaluation of fusion between 6 and 12 months, and future reports will include this method of assessment.

Another confounding factor is the heterogeneous patient population. This study is one in a mix of patient demographics, pathologies, and treatment groups. Long-construct scoliosis cases may not be expected to have the same average results as short-construct spondylolisthesis, DDD, and other conditions. However, the average results here demonstrate that good outcomes may be generalized over a wide variety of patients.

Conclusion

The surgical results of this procedure have shown that anteriolateral fusion a safe and effective technique. It has demonstrated the benefits of a minimally disruptive procedure, with quick recovery and improvements in pain and function scales. As the first published report of 2-year outcomes following anteriolateral fusion has also demonstrated that the underlying objectives of surgery need not be compromised for the sake of less morbidity, given long term maintenance of clinical improvements and ultimate radiographic fusion.

References

1. McAfee PC, DeVine JG, Chaput CD, et al. The indications for interbody fusion cages in the treatment of spondylolisthesis: analysis of 120 cases. *Spine (Phila Pa 1976)* 2005;30(6 Suppl):S60–5.
2. Resnick DK, Choudhri TF, Dailey AT, et al. Guidelines for the performance of fusion procedures for degenerative disease of the lumbar spine. Part 2: assessment of functional outcome. *J Neurosurg Spine* 2005;2:639–46.
3. Brantigan JW, Steffee AD, Lewis ML, Quinn LM, Persenaire JM. Lumbar interbody fusion using the Brantigan I/F cage for posterior lumbar interbody fusion and the variable pedicle screw placement system: two-year results from a Food and Drug Administration investigational device exemption clinical trial. *Spine (Phila Pa 1976)* 2000; 25:1437–46.
4. Fritzell P, Hagg O, Wessberg P, Nordwall A. 2001 Volvo Award Winner in Clinical Studies: Lumbar fusion versus nonsurgical treatment for chronic low back pain: a multicenter randomized controlled trial from the Swedish Lumbar Spine Study Group. *Spine (Phila Pa 1976)* 2001;26:2521–32; discussion 2532–2524.
5. Kuslich SD, Ulstrom CL, Griffith SL, Ahern JW, Dowdle JD. The Bagby and Kuslich method of lumbar interbody fusion. History, techniques, and 2-year follow-up results of a United States prospective, multicenter trial. *Spine (Phila Pa 1976)* 1998;23:1267–78.
6. Slosar PJ, Reynolds JB, Schofferman J, Goldthwaite N, White AH, Keaney D. Patient satisfaction after circumferential lumbar fusion. *Spine (Phila Pa 1976)* 2000;25:722–6.
7. Whitecloud TS III, Castro FP Jr, Brinker MR, Hartzog CW Jr, Ricciardi JE, Hill C. Degenerative conditions of the lumbar spine treated with intervertebral titanium cages and posterior instrumentation for circumferential fusion. *J Spinal Disord* 1998;11:479–86.
8. Eck JC, Hodges S, Humphreys SC. Minimally invasive lumbar spinal fusion. *J Am Acad Orthop Surg* 2007;15:321–9.
9. Foley KT, Holly LT, Schwender JD. Minimally invasive lumbar fusion. *Spine (Phila Pa 1976)* 2003;28(15 Suppl):S26–35.
10. Fessler RG. Minimally invasive spine surgery. *Neurosurgery* 2002; 51(5 Suppl):Siii–v.
11. Goldstein JA, McAfee PC. Minimally invasive endoscopic surgery of the spine. *J South Orthop Assoc* 1996;5:251–62.
12. Khoo LT, Palmer S, Laich DT, Fessler RG. Minimally invasive percutaneous posterior lumbar interbody fusion. *Neurosurgery* 2002;51(5 Suppl):S161–6.
13. Lieberman IH, Willsher PC, Litwin DE, Salo PT, Kraetschmer BG. Transperitoneal laparoscopic exposure for lumbar interbody fusion. *Spine (Phila Pa 1976)* 2000;25(4):509–514; discussion 515.
14. Olsen D, McCord D, Law M. Laparoscopic discectomy with anterior interbody fusion of L5-S1. *Surg Endosc* 1996;10:1158–63.
15. Regan JJ, Aronoff RJ, Ohnmeiss DD, Sengupta DK. Laparoscopic approach to L4-L5 for interbody fusion using BAK cages: experience in the first 58 cases. *Spine (Phila Pa 1976)* 1999;24:2171–4.

16. Regan JJ, Yuan H, McAfee PC. Laparoscopic fusion of the lumbar spine: minimally invasive spine surgery. A prospective multicenter study evaluating open and laparoscopic lumbar fusion. *Spine (Phila Pa 1976)* 1999;24:402–11.
17. Zdeblick TA, David SM. A prospective comparison of surgical approach for anterior L4-L5 fusion: laparoscopic versus mini anterior lumbar interbody fusion. *Spine (Phila Pa 1976)* 2000;25:2682–7.
18. Billingham J, Akbarnia BA. Extreme lateral interbody fusion - XLIF. *Current Orthop Practice* 2009;20:238–51. 210.1097/BCO.1090b1013e3181a1032ead.
19. Dewald CJ, Millikan KW, Hammerberg KW, Doolas A, Dewald RL. An open, minimally invasive approach to the lumbar spine. *Am Surg* 1999;65:61–8.
20. Dhall SS, Wang MY, Mummaneni PV. Clinical and radiographic comparison of mini-open transforaminal lumbar interbody fusion with open transforaminal lumbar interbody fusion in 42 patients with long-term follow-up. *J Neurosurg Spine* 2008;9:560–5.
21. Fraser RD, Gogan WJ. A modified muscle-splitting approach to the lumbosacral spine. *Spine (Phila Pa 1976)* 1992;17:943–8.
22. Kossmann T, Jacobi D, Trentz O. The use of a retractor system (SynFrame) for open, minimal invasive reconstruction of the anterior column of the thoracic and lumbar spine. *Eur Spine J* 2001;10:396–402.
23. Lin RM, Huang KY, Lai KA. Mini-open anterior spine surgery for anterior lumbar diseases. *Eur Spine J* 2008;17:691–7.
24. Liu JC, Ondra SL, Angelos P, Ganju A, Landers ML. Is laparoscopic anterior lumbar interbody fusion a useful minimally invasive procedure? *Neurosurgery* 2002;51(5 Suppl):S155–8.
25. Mayer HM. A new microsurgical technique for minimally invasive anterior lumbar interbody fusion. *Spine (Phila Pa 1976)* 1997;22:691–9; discussion 700.
26. Mayer HM, Wiechert K. Microsurgical anterior approaches to the lumbar spine for interbody fusion and total disc replacement. *Neurosurgery* 2002;51(5 Suppl):S159–65.
27. Ozgur BM, Aryan HE, Pimenta L, Taylor WR. Extreme Lateral Interbody Fusion (XLIF): a novel surgical technique for anterior lumbar interbody fusion. *Spine J* 2006;6:435–43.
28. Rodgers WB, Cox CS, Gerber EJ. Experience and early results with a minimally invasive technique for anterior column support through eXtreme Lateral Interbody Fusion: XLIF. *US Musculoskeletal Disease* 2007;1:28–32.
29. Tsutsumimoto T, Shimogata M, Ohta H, Misawa H. Mini-open versus conventional open posterior lumbar interbody fusion for the treatment of lumbar degenerative spondylolisthesis: comparison of paraspinal muscle damage and slip reduction. *Spine (Phila Pa 1976)* 2009;34:1923–8.
30. Wolfla CE, Maiman DJ, Coufal FJ, Wallace JR. Retroperitoneal lateral lumbar interbody fusion with titanium threaded fusion cages. *J Neurosurg* 2002;96(1 Suppl):50–5.
31. Pimenta L. Lateral endoscopic transpoas retroperitoneal approach for lumbar spine surgery. Paper presented at: VIII Brazilian Spine Society Meeting; 2001; Belo Horizonte, Minas Gerais, Brazil.
32. Rodgers WB, Cox CS, Gerber EJ. Early complications of extreme lateral interbody fusion in the obese. *J Spinal Disord Tech* 2010 Jan 15.
33. Rodgers WB, Gerber EJ, Patterson JR. Intraoperative and early post-operative complications in extreme lateral interbody fusion (XLIF): An analysis of 600 cases. (In press).
34. Rodgers WB, Gerber EJ, Patterson JR. Grade 2 spondylolisthesis at L4-5 treated by XLIF: safety and mid-term results in the “worst case scenario.” (In press).
35. Rodgers WB, Cox CS, Gerber EJ. Minimally invasive treatment (XLIF) of adjacent segment disease after prior lumbar fusions. *Int J Min Inv Spinal Tech* 2009;3.
36. Baker JK, Reardon PR, Reardon MJ, Heggeness MH. Vascular injury in anterior lumbar surgery. *Spine (Phila Pa 1976)* 1993;18:2227–30.
37. Regan JJ, McAfee PC, Guyer RD, Aronoff RJ. Laparoscopic fusion of the lumbar spine in a multicenter series of the first 34 consecutive patients. *Surg Laparosc Endosc* 1996;6:459–68.
38. Christensen FB, Bunker CE. Retrograde ejaculation after retroperitoneal lower lumbar interbody fusion. *Int Orthop* 1997;21:176–80.
39. Flynn JC, Price CT. Sexual complications of anterior fusion of the lumbar spine. *Spine (Phila Pa 1976)* 1984;9:489–92.
40. Bergey D, Regan J. P50. Lateral endoscopic transpoas spinal fusion: review of technique and clinical outcomes in a consecutive series. *The Spine Journal* 2003;3(Suppl):166.
41. Nakamura H, Ishikawa T, Konishi S, Seki M, Yamano Y. Psoas strapping technique: a new technique for laparoscopic anterior lumbar interbody fusion. *J Am Coll Surg* 2000;191:686–8.
42. Kuslich SD, Ulstrom CL, Griffith SL, Ahern JW, Dowdle JD. The Bagby and Kuslich method of lumbar interbody fusion. History, techniques, and 2-year follow-up results of a United States prospective, multicenter trial. *Spine (Phila Pa 1976)* 1998;23:1267–78; discussion 1279.
43. Sasso RC, Kitchel SH, Dawson EG. A prospective, randomized controlled clinical trial of anterior lumbar interbody fusion using a titanium cylindrical threaded fusion device. *Spine (Phila Pa 1976)* 2004;29:113–22; discussion 121–12.
44. Blumenthal S, McAfee PC, Guyer RD, et al. A prospective, randomized, multicenter Food and Drug Administration investigational device exemptions study of lumbar total disc replacement with the CHARITE artificial disc versus lumbar fusion: part I: evaluation of clinical outcomes. *Spine (Phila Pa 1976)* 2005;30:1565–75; discussion E1387–1591.
45. Zigler J, Delamarter R, Spivak JM, et al. Results of the prospective, randomized, multicenter Food and Drug Administration investigational device exemption study of the ProDisc-L total disc replacement versus circumferential fusion for the treatment of 1-level degenerative disc disease. *Spine (Phila Pa 1976)* 2007;32:1155–62; discussion 1163.
46. Burkus JK, Heim SE, Gornet MF, Zdeblick TA. Is INFUSE bone graft superior to autograft bone? An integrated analysis of clinical trials using the LT-CAGE lumbar tapered fusion device. *J Spinal Disord Tech* 2003;16:113–22.
47. Burkus JK, Sandhu HS, Gornet MF, Longley MC. Use of rhBMP-2 in Combination with Structural Cortical Allografts: Clinical and Radiographic Outcomes in Anterior Lumbar Spinal Surgery. *J Bone Joint Surg* 2005;87:1205–12.
48. Kim JS, Kang BU, Lee SH, et al. Mini-transforaminal lumbar interbody fusion versus anterior lumbar interbody fusion augmented by percutaneous pedicle screw fixation: a comparison of surgical outcomes in adult low-grade isthmic spondylolisthesis. *J Spinal Disord Tech* 2009;22:114–21.
49. Arnold PM, Robbins S, Paullus W, Faust S, Holt R, McGuire R. Clinical outcomes of lumbar degenerative disc disease treated with posterior lumbar interbody fusion allograft spacer: a prospective, multicenter trial with 2-year follow-up. *Am J Orthop (Belle Mead NJ)* 2009;38:E115–22.
50. Resnick DK, Choudhri TF, Dailey AT, et al. Guidelines for the performance of fusion procedures for degenerative disease of the lumbar spine. Part 5: correlation between radiographic and functional outcome. *J Neurosurg Spine* 2005;2:658–61.