INTERNATIONAL JOURNAL of SPINE SURGERY

Clinical outcomes of degenerative lumbar spinal stenosis treated with lumbar decompression and the Cosmic "semi-rigid" posterior system

Tuncay Kaner, Mehdi Sasani, Tunc Oktenoglu, Ahmet Levent Aydin and Ali Fahir Ozer

Int J Spine Surg 2010, 4 (4) 99-106
doi: https://doi.org/10.1016/j.esas.2010.09.003
http://ijssurgery.com/content/4/4/99

The International Journal of Spine Surgery
2397 Waterbury Circle, Suite 1,
Aurora, IL 60504, Phone: +1-630-375-1432

Available online at www.sciencedirect.com
ScienceDirect
SAS Journal 4 (2010) 99-106
SAS Journal
www.sasjournal.com

Dynamic stabilization

Clinical outcomes of degenerative lumbar spinal stenosis treated with lumbar decompression and the Cosmic "semi-rigid" posterior system

Tuncay Kaner, MD [a,*], Mehdi Sasani, MD [b], Tunc Oktenoglu, MD [b], Ahmet Levent Aydin, MD [c], Ali Fahir Ozer, MD [b]

[a] *Neurosurgery Department, Pendik State Hospital, Istanbul, Turkey*
[b] *Neurosurgery Department, American Hospital, Istanbul, Turkey*
[c] *Neurosurgery Department, Istanbul Physical Therapy and Rehabilitation Training Hospital, Istanbul, Turkey*

Abstract

Background: Although some investigators believe that the rate of postoperative instability is low after lumbar spinal stenosis surgery, the majority believe that postoperative instability usually develops. Decompression alone and decompression with fusion have been widely used for years in the surgical treatment of lumbar spinal stenosis. Nevertheless, in recent years several biomechanical studies have shown that posterior dynamic transpedicular stabilization provides stabilization that is like the rigid stabilization systems of the spine. Recently, posterior transpedicular dynamic stabilization has been more commonly used as an alternative treatment option (rather than rigid stabilization with fusion) for the treatment of degenerative spines with chronic instability and for the prevention of possible instability after decompression in lumbar spinal stenosis surgery.

Methods: A total of 30 patients with degenerative lumbar spinal stenosis (19 women and 11 men) were included in the study group. The mean age was 67.3 years (range, 40–85 years). Along with lumbar decompression, a posterior dynamic transpedicular stabilization (dynamic transpedicular screw–rigid rod system) without fusion was performed in all patients. Clinical and radiologic results for patients were evaluated during follow-up visits at 3, 12, and 24 months postoperatively.

Results: The mean follow-up period was 42.93 months (range, 24–66 months). A clinical evaluation of patients showed that, compared with preoperative assessments, statistically significant improvements were observed in the Oswestry and visual analog scale scores in the last follow-up control. Compared with preoperative values, there were no statistically significant differences in radiologic evaluations, such as segmental lordosis angle (α) scores ($P = .125$) and intervertebral distance scores ($P = .249$). There were statistically significant differences between follow-up lumbar lordosis scores ($P = .048$). There were minor complications, including a subcutaneous wound infection in 2 cases, a dural tear in 2 cases, cerebrospinal fluid fistulas in 1 case, a urinary tract infection in 1 case, and urinary retention in 1 case. We observed L5 screw loosening in 1 of the 3-level decompression cases. No screw breakage was observed and no revision surgery was performed in any of these cases.

Conclusions: Posterior dynamic stabilization without fusion applied to lumbar decompression leads to better clinical and radiologic results in degenerative lumbar spinal stenosis. To avoid postoperative instability, especially in elderly patients who undergo degenerative lumbar spinal stenosis surgery with chronic instability, the application of decompression with posterior dynamic transpedicular stabilization is likely an important alternative surgical option to fusion, because it does not have fusion-related side effects, is easier to perform than fusion, requires a shorter operation time, and has low morbidity and complication rates.

Keywords: Lumbar spinal stenosis; Posterior dynamic stabilization; Microlumbar decompression; Spinal fusion; Spinal instability

Degenerative lumbar spinal stenosis is the most important cause of lower-back pain and neurologic dysfunction in the elderly.[1–6] With nonoperative treatments, 30% of patients with spinal stenosis show improvement whereas 60% remain unchanged. Surgical results have been more successful than medical treatments.[7] The expansion of the canal with laminectomy in lumbar stenosis was defined by Sarpyener for the first time.[8] In later years, particularly in elderly individuals, in whom disease is commonly observed, multiple-level decompressive lumbar surgeries have been widely used to treat spinal stenosis because of advanced degenerative disease. However, excellent results have not been observed.[1,9–12] Rates of good and satisfactory results

* Corresponding author: Tuncay Kaner, MD, Neurosurgery Department, Pendik State Hospital, Istanbul, Turkey; Tel: (90) 216 4644800; Fax: (90) 216 4644801.
E-mail address: tkaner2002@yahoo.com

1935-9810 © 2010 SAS - The International Society for the Advancement of Spine Surgery. Published by Elsevier Inc. All rights reserved.
doi:10.1016/j.esas.2010.09.003

ranged between 57% and 96%.[2,13–16] The frequency of lower-back pain and sciatica after lumbar spinal stenosis surgery is not low. It is believed that such complaints after decompressive surgery are due to post-decompression instability.[4,14,17–20]

Many researchers have reported the importance of posterior elements in axial loading, translation and shear, and rotational resistance.[21–25] Thus, removing the posterior elements leads to postoperative back pain and the compression of neural elements by causing instability. To prevent postoperative instability, fusion is added to the decompression process in degenerative lumbar spinal stenosis cases, and this is believed to be superior to decompression alone.[3,20,26–29] It is known that instrumentation applied in conjunction with fusion increases the rate of fusion.[30] Although fusion has been used in the treatment of degenerative spinal stenosis for years, especially in elderly patients who have high comorbidity, the complication rate is high because of long operation times.[31–33] Fusion carries the risk of adjacent segment degeneration, donor-site morbidity, and pseudarthrosis, especially in the elderly.[34–36] Even a successful fusion disrupts the normal sagittal balance and, after fusion, frequently causes back pain in patients while sitting. Only 30% of reported clinical results of circumferential fusion are excellent.[37,38] In addition, clinical studies have shown that there is no relationship between successful fusion and clinical results.[36]

Recently, posterior dynamic systems have been used in the treatment of degenerative diseases of the spine to reduce the side effects from fusion. The concept of dynamic stabilization is based on the principles of reducing the side effects on adjacent segments formed by fusion and control of movement by providing load transfer of spinal segments without fusion.[37,39] Because there are few studies in the literature on the use of posterior dynamic transpedicular stabilization to prevent possible spinal instability after degenerative lumbar spinal stenosis surgery,[31,33,40–44] more studies are needed to refine this concept.

The objective of this study is to discuss our clinical and radiologic results after performing lumbar decompression accompanied by posterior dynamic transpedicular stabilization (dynamic pedicular screw–rod) without fusion. Although it is a new concept, it has been used as an alternative treatment option to fusion for treating degenerative lumbar spinal stenosis cases.

Materials and methods

This prospective study included 30 patients who had degenerative lumbar spinal stenosis from 2004–2008. There were 19 female and 11 male patients, with a mean age of 67.3 years (range, 40–85 years). The inclusion criteria were the presentation of degenerative lumbar spinal stenosis symptoms for at least 1 year and a lack of response to nonoperative treatments. All cases had only degenerative lumbar spinal stenosis, having both central and lateral narrowing. Exclusion criteria included prior spinal surgery and fusion, congenital anomalies, severe systemic disease, degenerative spondylolisthesis, degenerative scoliosis, and active infection. All patients had leg pain or lower-back or hip pain due to a narrow spinal canal. All patients were diagnosed with preoperative lumbar magnetic resonance imaging (MRI); anterior-posterior, lateral, and standing lateral hyperflexion and hyperextension functional radiographs; and computed tomography. The main findings of MRI included secondary degenerative changes in spinal segments.

Clinical results were evaluated by use of lower-back and leg visual analog scale (VAS) and Oswestry scores. The segmental lordosis angle (α), lumbar lordosis (LL) angle, and intervertebral distance (intervertebral space ratio [IVS]) were used in the assessment of the patients' radiologic results. The segmental angle was measured according Cobb (Fig. 1).[45] Implant failures such as screw breakage or loosening were recorded. Postoperative clinical and radiologic results were evaluated and recorded at 3, 12, and 24 months.

We used Cosmic dynamic hinged screws (Ulrich GmbH & Co. KG, Ulm, Germany) with microlumbar decompression in all cases. In the sagittal plane, the motion of the dynamic pedicular screw is between the shaft and head of the screw. The hinge does not permit any motion in horizontal rotation and translation. The dynamic transpedicular screws were used in conjunction with rigid rods (Fig. 2).

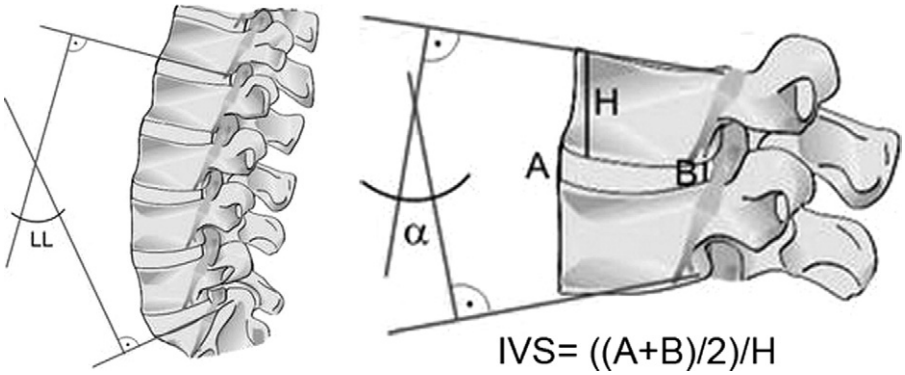

Fig. 1. Measurement of segmental lordosis angles (α), LL angle, and IVS.

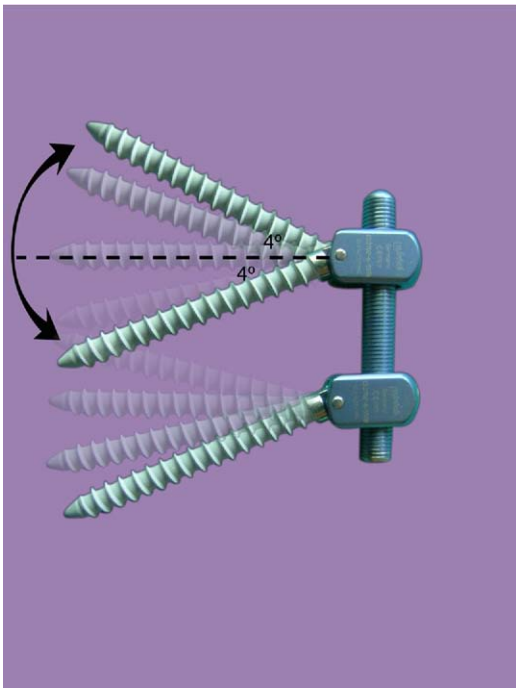

Fig. 2. Cosmic dynamic transpedicular screw. In the sagittal plane, the motion of the cosmic dynamic pedicular screw is approximately 4° between the shaft and head of the screw. The hinge does not permit any motion in horizontal rotation and translation.

Operative technique

All surgeries were carried out by the same 4 surgeons. All patients were operated on in the prone position and under general anesthesia. Patients were given preoperative prophylactic antibiotics. All operations were performed with the operation microscope and standard midline dorsal approach. The operational level was determined with the aid of intraoperative fluoroscopy. A total laminectomy to the stenotic spinal canal was used in 10 patients. The other patients received a laminotomy and medial facetectomy up to the pedicles with a high-speed drill from the right or left side, where the clinical radiculopathy was intense. Thus, by opening the lateral recess, the nerve root was relieved. The spinal canal was then enlarged by undercutting the thickened ligamentum flavum on both the right and left sides, and the microlumbar decompression process was completed. When it was necessary, a foraminotomy was performed while the isthmus was being protected. Then, under fluoroscopic control, hinged dynamic transpedicular screws were applied. Rigid rods were used in conjunction with dynamic screws. Patients were mobilized postoperatively the first day without any lumbar orthosis. After a brief postoperative rest period of 30 days, the patients were allowed to return to their daily activities without any restrictions. During all surgical procedures, we found that easier utilization of hinged dynamic pedicular screws and faster operative time resulted from application of all dynamic screws through lumbar paravertebral muscles under fluoroscopic control.

Statistical methods

In this study, NCSS (Number Cruncher Statistical System) 2007 and PASS (Power Analysis and Sample Size) 2008 Statistical Software (NCSS LLC, Kaysville, Utah) were used for statistical analyses of the data. On data analysis, mean, standard deviation, and median were used as descriptive statistics. Kolmogorov-Smirnov tests were conducted to evaluate whether the data distributions were normal. The repeated-measures test and post hoc Bonferroni test were used for evaluating normally distributed parameters. The Friedman test and Wilcoxon signed-rank test were used for evaluating non–normally distributed measurements. Data were considered significant at $P < .05$.

Results

The mean follow-up period was 42.93 months (range, 24–66 months). Single-level decompression was performed in 10 cases, 2-level decompressions in 14, and 3-level decompression in 6. A total lumbar laminectomy was performed in 10 cases, whereas bilateral decompression was performed in 20 cases through a unilateral approach. A clinical evaluation of the patients showed that compared with preoperative assessments, statistically significant improvements were observed in the Oswestry Disability Index and the back and leg pain VAS scores in the last follow-up control ($P = .0011$). The Oswestry scores obtained at 3, 12, and 24 months after surgery were significantly lower than those observed before surgery ($P = .001$, $P = .001$, and $P = .001$, respectively). Compared with the measurements obtained at 3 months postoperatively, the decreases observed at 12 months postoperatively were statistically significant ($P = .016$), whereas decreases at 24 months postoperatively were even more statistically significant ($P = .001$). Similarly, the measurements in the 24th postoperative month were lower than the measurements obtained in the 12th postoperative month; these differences were also highly statistically significant ($P = .001$). The differences between follow-up VAS measurements were also highly statistically significant ($P = .001$). Highly statistically significant decreases were observed for the VAS scores at 3, 12, and 24 months postoperatively ($P = .001$, $P = .001$, and $P = .001$, respectively) compared with the preoperative VAS measurements. Similarly, compared with the third month postoperative measurements, decreases in both the 12th and 24th postoperative months were also highly statistically significant ($P = .002$ and $P = .001$, respectively). Compared with the 12th postoperative month, the decreases observed at 24 months postoperatively were statistically significant ($P = .035$) (Table 1).

Compared with preoperative values, there were no statistically significant differences between follow-up visits in the radiologic evaluations, such as segmental lordosis angle (α) scores ($P = .125$) and IVS scores ($P = .249$). There were statistically significant differences between follow-up LL scores ($P = .048$). Compared with preoperative LL mea-

Table 1
Evaluation of Oswestry Disability Index and VAS measurements

	Oswestry* (mean ± SD)	VAS† [mean ± SD (median)]
Preoperative	63.77 ± 62	7.05 ± 0.80 (7)
POM 3	22.0 ± 9.89	2.33 ± 1.08 (2.5)
POM 12	15.78 ± 6.85	1.17 ± 0.98 (1)
POM 24	8.89 ± 4.5	0.78 ± 0.73 (1)
P value	.001‡	.001‡
Post hoc	Preoperative > POM 3 (.001‡)	Preoperative > POM 3 (.001‡)
	Preoperative > POM 12 (.001‡)	Preoperative > POM 12 (.001‡)
	Preoperative > POM 24 (.001‡)	Preoperative > POM 24 (.001‡)
	POM 3 > POM 12 (.016§)	POM 3 > POM 12 (.002‡)
	POM 3 > POM 24 (.001‡)	POM 3 > POM 24 (.001‡)
	POM 12 > POM 24 (.001‡)	POM 12 > POM 24 (.035§)

Abbreviation: POM, postoperative month.
* Repeated-measures test/post hoc Bonferroni test was used.
† Friedman test/post hoc Wilcoxon signed-rank test was used.
‡ $P < .01$.
§ $P < .05$.

surements, decreases observed in the early postoperative period were statistically significant ($P = .042$) (Table 2).

We observed minor complications, including a subcutaneous wound infection in 2 cases, a dural tear in 2 cases, cerebrospinal fluid fistulas in 1 case, a urinary tract infection in 1 case, and urinary retention in 1 case. L5 screw loosening was observed in 1 of our 3-level decompression cases. We did not observe screw breakage or perform revision surgery in any cases (Table 3).

Discussion

In this prospective study using a posterior dynamic transpedicular stabilization system, our goal was to maintain spinal stability in patients with degenerative lumbar spinal stenosis without performing fusion while preventing pain-causing abnormal movement due to segmental degeneration and possible translation in later years.

Degenerative lumbar spinal stenosis is a degenerative disorder of the spine seen in elderly individuals. Kirkaldy-Willis and Farfan[46] defined the pathology of discogenic pain and degenerative instability, and they stated that minimal changes in segmental stability may lead to major dysfunctions. Degenerative segmental instability develops as a result of disc degeneration and decreases in disc height, enlargement of the posterior facet joint by hypertrophy, ligament laxity, and increased movement. In an effort to keep the system intact, ligamentum flavum increases its volume and causes narrowing of the channel diameter; foraminal and central spinal stenosis usually develops as a result of such situations.[46,47]

The low-back pain described by Kirkaldy-Willis and Farfan[46] and others[48,49] depends on disc degeneration, which is the most important cause of primary instability. Therefore the pathogenesis of degenerative lumbar spinal stenosis, the underlying cause of foraminal or central degenerative spinal stenosis, which manifests itself with back pain or leg pain, is degenerative segmental instability. Determining the pathogenesis of degenerative spinal stenosis is important for determining the appropriate surgical treatment.

Multilevel decompressive lumbar surgeries have been widely applied to the treatment of spinal stenosis due to degenerative spinal disease over the years, but often, the

Table 2
Evaluation of LL, α, and IVS measurements

	LL* (mean ± SD)	Segmental lordosis angle (α)† (mean ± SD)	IVS* (mean ± SD)
Preoperative	49.5 ± 10.79	9.27 ± 5.54 (9.5)	0.26 ± 0.08
Early postoperative	42.06 ± 11.58	8.39 ± 5.54 (7)	0.27 ± 0.09
POM 3	45.22 ± 13.76	8.39 ± 4.69 (8,5)	0.25 ± 0.08
POM 12	46.61 ± 12.67	8.27 ± 3.81 (8)	0.26 ± 0.07
POM 24	48.72 ± 13.03	9.33 ± 3.92 (9)	0.25 ± 0.06
P value	.048‡	.125	.249
Post hoc	Preoperative > early postoperative (.042‡)	NS	NS

Abbreviations: POM, postoperative month; NS, not significant ($P > .05$).
* Repeated-measures test/post hoc Bonferroni test was used.
† Friedman test/post hoc Wilcoxon signed-rank test was used.
‡ $P < .05$.

Table 3
Complications

Complication	n
Subcutaneous wound infection	2
Dural tear	2
Cerebrospinal fluid fistula	1
Urinary tract infection	1
Urinary retention	1
L5 screw loosening	1

results have not been perfect.[1,9–12] Back pain and sciatica are frequently seen after lumbar spinal stenosis surgery. It is thought that complaints after decompressive surgery, including deterioration in the capsular ligament, loosening in the interspinous and supraspinous ligaments, and removal of the lamina, are due to secondary segmental instability, even when performed from 1 side with removal of at least a portion of the facet joints.[4,14,17–20] The biomechanical importance of the posterior elements was emphasized in some studies.[21–25] Adams and Hutton[22] determined the load magnitude on various structures of the spine preventing the sagittal translation as a percentage, as follows: intact facet capsules (39%), intact disc and annulus (29%), supraspinous and interspinous ligaments (19%), and ligamentum flavum (13%). In a study by Cusick et al,[25] degradation of the facet joint, posterior soft tissue, and ligament structure increased the stress on the disc, anterior and posterior longitudinal ligaments, and annulus. This situation may lead to pain with clinical and radiologic instability. As shown in these studies, removing the posterior elements may create instability and postoperative back pain and may lead to compression of neural elements accompanied by sciatica. Therefore, when the pathogenesis of spinal stenosis is a primary degenerative segmental instability, a resection of the posterior elements and decompression during surgery increase the instability. As a result, the existing instability increases, and unsuccessful clinical results with back pain and sciatica are observed. Therefore we believe that including posterior stabilization in the treatment of spinal stenosis with decompression is necessary so that segment stability is ensured and instability is controlled. As a result, failed back syndrome is prevented, and better clinical results are observed.

To prevent instability, fusion has been used in decompression surgeries in degenerative lumbar spinal stenosis cases for years; its importance is especially emphasized in multilevel laminectomies.[3,20,26,29] It is known that degenerative lumbar spinal stenosis is usually seen in elderly patients. Bone quality in this age group of patients is usually low because of osteopenia, and patients usually have comorbidity. Therefore a short duration of the operation and less invasive surgical procedure are important in terms of mortality and morbidity of the operation. Fusion surgery has long been the gold standard for treatment of painful spinal degenerative instability cases. However, because of long operation times and osteopenic bone structures, fusion surgery brings a high risk of pseudarthrosis and adjacent segment disease during the postoperative period. In addition, donor-site morbidity has been reported in about 39% of fusion cases, and donor-site pain may be present up to 1 year postoperatively.[31,34–36] Even in patients with advanced fusion, satisfactory clinical results range between 16% and 95%.[35]

Recently, some biomechanical studies have reported that dynamic stabilization (dynamic hinged transpedicular screw and rigid rod) provides stabilization that is similar to that of rigid systems.[21,50–53] Xu et al[53] reported that rigid and dynamic pedicle screws provided sufficient stability at a damaged segment during all loading situations. This study showed that the dynamic pedicle screws permitted slightly more motion than rigid pedicle screws. In a recent in vitro experiment, Schmoelz et al[51] showed that compared with the intact spinal segment, a stabilization device with hinged dynamic screws reduced the range of motion in flexion-extension and lateral bending after bisegmental decompression; Cosmic-MIA (Ulrich Medical, Ulm, Germany), in clinical use since 2002, was also used in that study. In another biomechanical study, Bozkuş et al[50] showed that dynamic screws allowed significantly greater motion than standard rigid screws in all directions of loading. In addition, hinged dynamic screws allowed less stress shielding than standard rigid screws.[50]

Dynamic stabilization systems have been developed to prevent the major disadvantages of rigid fixation, such as pseudarthrosis and adjacent segment degeneration.[33,54] Indications for a dynamic stabilization system are segmental hypermobility, segmental hypomobility, isolated segmental disc degeneration, and 1-level or multilevel spinal canal stenosis.[55]

The first known posterior dynamic system is the Graf ligamentoplasty system (SEM, CO, Mountrouge, France), and after several studies, its insufficiency has been understood. Kanayama et al[56] reported that spinal drift was not corrected with the Graf system. Then, the Dynesys Posterior Dynamic Stabilization System (Zimmer GmbH, Winterthur, Switzerland) was developed by considering the disadvantages of the Graf ligamentoplasty system. Dynesys is a semi-rigid fixation system that allows minimal extension and flexion with the help of a spacer located between 2 segmental rigid pedicle screws.[57] It has been used in the treatment of degenerative segmental diseases of the lumbar spine for over 10 years.

Schmoelz et al[58] in their in vitro study compared the Dynesys dynamic nonfusion system with an internal fixator and examined its effects on spine stability. As a result, they reported that Dynesys provided a robust stability in patients with degenerative spinal pathology and therefore can be considered as an alternative method to fusion surgery.

Stoll et al[41] reported significant improvements in pain and Oswestry scores in their lumbar instability series after a mean follow-up period of 38 months. In addition, they showed that the dynamic stabilization system is a less in-

vasive approach and is a safe and effective procedure in the treatment of degenerative spine instability.

In another study Schnake et al[31] performed interlaminar decompression and dynamic stabilization to treat patients with degenerative spondylolisthesis with spinal stenosis and reported 2-year results for 26 cases. They obtained clinical results similar to those in patients who underwent transpedicular rigid stabilization with fusion. Application of the dynamic system maintained sufficient stability and prevented the progression of instability. Moreover, because a bone graft is not required in this system, donor-site morbidity is avoided.

In a study by Putzier et al[59] a group of patients who only received nucleotomy were compared with patients who underwent nucleotomy with transpedicular dynamic stabilization. As a result, after a 34-month follow-up period, the authors obtained good clinical and radiologic results and reported that dynamic stabilization added to nucleotomy was useful in preventing the progress of initial disk degeneration by further stabilizing the movement of segments.

In a recent study Kaner et al[60] observed that performing a discectomy with posterior dynamic stabilization (dynamic pedicular screw–rigid rod) decreased the risk of recurrent disc herniations as well as decelerated the degeneration of disc tissue in Carragee type II, III, and IV groups, which experienced increased reherniation and persistent/continuous sciatica after limited lumbar microdiscectomy.

In the literature, reported clinical results about dynamic stabilization are contradictory. Korovessis et al[43] compared rigid, semirigid, and dynamic instrumentations in 3 groups of patients. After obtaining similar clinical and radiologic results in all 3 groups, they stated that it was difficult to recommend any 1 instrumentation over the others.

Grob et al[42] and Cakir et al[61] did not report positive results supporting the use of dynamic stabilization in degenerative diseases of the spine. They concluded that dynamic stabilization has no superiority over fusion. Despite these results, when one is comparing the complexity of dynamic and fusion surgeries, dynamic procedures should be preferred because of their simplicity. Furthermore, surgical indications for dynamic stabilization are defined as poor.

Stoll et al,[41] Schnake et al,[31] and Putzier et al[59] achieved good clinical outcomes; therefore they recommended dynamic stabilization as a safe and effective method of treatment for degenerative lumbar spinal stenosis with chronic instability. In the treatment of lumbar degenerative scoliosis, Di Silvestre et al[44] applied Dynesys and dynamic stabilization and reported improved clinical results after a mean follow-up period of 54 months. In their prospective study with 103 consecutive patients, Stoffel et al[62] used the current study's system and obtained a high rate of patient satisfaction and improved clinical results.

In our study we have obtained promising and improved clinical and radiologic results that corroborate the findings of Stoll et al,[41] Schnake et al,[31] Di Silvestre et al,[44] and Putzier et al.[59] Our results support the idea that dynamic stabilization is an effective and important alternative to fusion in the treatment of degenerative lumbar spinal stenosis. The dynamic pedicular screw–rigid rod system that we applied allows potential sagittal movement with the hinge between the screw head and shank. Mechanically, movement occurs between a longitudinally positioned rod and a sagittally positioned screw leg. The joint connection between the screw and rod reduces the stress on the system during flexion, and therefore implant failure is lower than with dynamic screw-rod systems. In this system some of the load is shared and transferred by the system; therefore there is a reduction in stress-shielding effects on the bone.[63,64] Reduced stiffness helps the load distribution, and adjacent disc distance degeneration slows down. We observed no obvious degeneration on adjacent levels by MRI comparison preoperatively and postoperatively at 2 years' follow-up; however, this observation does not mean that the system protects adjacent segments. In a recently published study, dynamic screws were used with dynamic rods in the treatment of lumbar degenerative disc disease, and good clinical results were achieved.[65]

Conclusion

The result of using a posterior dynamic transpedicular stabilization system (dynamic pedicular screw–rigid rod) in degenerative lumbar spinal stenosis is achieving improved clinical and radiologic results. Considering the side effects of fusion surgery such as longer operation times, pseudarthrosis, and prolonged donor pain periods, posterior dynamic stabilization should be regarded as an important alternative treatment option to fusion in degenerative lumbar spinal stenosis with chronic instability. In the future, dynamic systems can replace fusion systems in the treatment of degenerative diseases of the spine. Furthermore, there is a need for comparative studies regarding lumbar degenerative spinal stenosis. Studies comparing posterior dynamic and rigid systems should be performed particularly for patients having multilevel degenerative stenosis.

References

1. Fox MW, Onofrio BM, Hanssen AD. Clinical outcomes and radiological instability following decompressive lumbar laminectomy for degenerative spinal stenosis: a comparison of patients undergoing concomitant arthrodesis versus decompression alone. *J Neurosurg* 1996; 85:793–802.
2. Katz JN, Lipson SJ, Chang LC, Levine SA, Fossel AH, Liang MH. Seven- to 10-year outcome of decompressive surgery for degenerative lumbar spinal stenosis. *Spine* 1996;21:92–8.
3. Feffer HL, Wiesel SW, Cuckler JM, Rothman RH. Degenerative spondylolisthesis. To fuse or not to fuse. *Spine* 1985;10:287–91.
4. Grabias S. Current concepts review. The treatment of spinal stenosis. *J Bone Joint Surg Am* 1980;62:308–13.
5. Kirkaldy-Willis WH, Paine KW, Cauchoix J, McIvor G. Lumbar spinal stenosis. *Clinical Orthop Relat Res* 1974;99:30–50.
6. Spengler DM. Degenerative stenosis of the lumbar spine. *J Bone Joint Surg Am* 1987;69:305–8.

7. Benoist M. The natural history of lumbar degenerative spinal stenosis. *Joint Bone Spine* 2002;69:450–7.
8. Naderi S, Güçlü B, Yurtsever C, Berk H. Dr. Ahmet Münir Sarpyener: pioneer in definition of congenital spinal stenosis. *Spine (Phila Pa 1976)* 2007;32:606–8.
9. Hopp E, Tsou PM. Postdecompression lumbar instability. *Clin Orthop Relat Res* 1988;227:143–51.
10. Hazlett JW, Kinnard P. Lumbar apophyseal process excision and spinal instability. *Spine* 1982;7:171–6.
11. Jones RA, Thompson JL. The narrow lumbar canal: a clinical and radiological review. *J Bone Joint Surg Br* 1969;50:595–605.
12. Shenkin H, Hash CJ. Spondylolisthesis after multiple bilateral laminectomy and facetectomies for lumbar spondylosis. Follow-up review. *J Neurosurg* 1979;50:45–7.
13. Alexander E, Kelly DL, Davis CH, et al. Intact arch spondylolisthesis. A review of 50 cases and description of surgical treatment. *J Neurosurg* 1985;63:840–4.
14. Caputy AJ, Luessenhop AJ. Long-term evaluation of decompressive surgery for degenerative lumbar stenosis. *J Neurosurg* 1992;77:669–76.
15. Ganz JC. Lumbar spinal stenosis: postoperative results in terms of preoperative posture-related pain. *J Neurosurg* 1990;72:71–4.
16. Johnsson KE, Willner S, Pettersson H. Analysis of operated cases with lumbar renal stenosis. *Acta Orthop Scand* 1981;52:427–33.
17. Fager CA, Freidberg SR. Analysis of failures and poor results of lumbar spine surgery. *Spine* 1980;5:87–94.
18. Garfin SR, Glover M, Booth RE, Simeone FA, Rothman RH. Laminectomy: a review of the Pennsylvania Hospital experience. *J Spinal Disord* 1988;1:116–33.
19. Getty CJ. Lumbar spinal stenosis. The clinical spectrum and the results of operation. *J Bone Joint Surg Br* 1980;62:481–5.
20. Herkowitz HN, Kurtz LT. Degenerative lumbar spondylolisthesis with spinal stenosis. A prospective study comparing decompression with decompression and intertransverse process arthrodesis. *J Bone Joint Surg Am* 1991;73:802–8.
21. Posner I, White AA, Edwards WT, Hayes WC. A biomechanical analysis of the clinical stability of the lumbar and lumbosacral spine. *Spine* 1982;7:374–89.
22. Adams MA, Hutton WC. The mechanical function of the lumbar apophyseal joints. *Spine* 1983;8:327–30.
23. Adams MA, Hutton WC, Stott JR. The resistance to flexion of the lumbar intervertebral joint. *Spine* 1980;5:245–53.
24. Lorenz M, Patwardhand A, Vanderby R. Load bearing characteristics of lumbar facets in normal and surgically altered spinal segments. *Spine* 1983;8:122–30.
25. Cusick JF, Yoganandan N, Pintar FA, Reinartz JM. Biomechanics of sequential posterior lumbar surgical alterations. *J Neurosurg* 1992;76: 805–11.
26. Stauffer RN, Coventry MB. Postoperative lumbar-spine fusion. Analysis of Mayo Clinic series. *J Bone Joint Surg Am* 1972;54:1195–204.
27. Zdeblick TA. A prospective, randomized study of lumbar fusion. Preliminary results. *Spine* 1993;18:983–91.
28. Nasca RJ. Rationale for spinal fusion in lumbar spinal stenosis. *Spine* 1989;14:451–4.
29. Natelson SE. The injudicious laminectomy. *Spine* 1986;11:966–9.
30. Mardjedko SM, Connoly PJ, Shott S. Degenerative lumbar spondylolisthesis. A meta analysis of literature 1970-1993. *Spine* 1994;19: 2256S–65S.
31. Schnake KJ, Schaeren S, Jeanneret B. Dynamic stabilization in addition to decompression for lumbar spinal stenosis with degenerative spondylolisthesis. *Spine* 2006;31:442–9.
32. Katz JN, Lipson SJ, Lew RA, et al. Lumbar laminectomy alone or with instrumented or noninstrumented arthrodesis in degenerative lumbar spinal stenosis. Patient selection, costs, and surgical outcomes. *Spine* 1997;22:1123–31.
33. Schaeren S, Broger I, Jeanneret B. Minimum four-year follow-up of spinal stenosis with degenerative spondylolisthesis treated with decompression and dynamic stabilization. *Spine* 2008;33:E636–42.
34. Banwart JC, Asher MA, Hassanein RS. Iliac crest bone graft harvest donor site morbidity. a statistical evaluation. *Spine* 1995;20:1055–60.
35. Younger EM, Chapman MW. Morbidity at bone graft donor sites. *J Orthop Trauma* 1989;3:192–5.
36. Turner JA, Ersek M, Herron L, et al. Patient outcomes after lumbar spinal fusions. *JAMA* 1992;268:907–11.
37. Mulholland RC, Sengupta DK. Rationale, principles and experimental evaluation of the concept of soft stabilization. *Eur Spine J* 2002;11: 198–205.
38. Gibson JN, Grant IC, Waddell G. The Cochrane review of surgery for lumbar disc prolapse and degenerative lumbar spondylosis. *Spine* 1999;24:1820–32.
39. Sengupta DK. Dynamic stabilization devices in the treatment of low back pain. *Neurol India* 2005;53:466–74.
40. Würgler-Hauri CC, Kalbarczyk A, Wiesli M, Landolt H, Fandino J. Dynamic Neutralization of the lumbar spine after microsurgical decompression in acquired lumbar spinal stenosis and segmental instability. *Spine* 2008;33:E66–77.
41. Stoll TM, Dubois G, Schwarzenbach O. The dynamic neutralization system for the spine. A multi-center study of a novel non-fusion system. *Eur Spine J* 2002;11:170–8.
42. Grob D, Benini A, Junge A, Mannion A. Clinical experience with the Dynesys semirigid fixation system for the lumbar spine. Surgical and patient-oriented outcome in 50 cases after an average of two years. *Spine* 2005;30:324–31.
43. Korovessis P, Papazisis Z, Koureas G, Lambiris E. Rigid, semirigid versus dynamic instrumentation for degenerative lumbar spinal stenosis. A correlative radiological and clinical analysis of short-term results. *Spine* 2004;29:735–42.
44. Di Silvestre M, Lolli F, Bakaloidis G, Parisini P. Dynamic stabilization for degenerative lumbar scoliosis in elderly patients. *Spine* 2010;35: 227–34.
45. Fernand R, Fox DE. Evaluation of lumbar lordosis. A prospective and retrospective study. *Spine* 1985;10:799–803.
46. Kirkaldy-Willis WH, Farfan HF. Instability of the lumbar spine. *Clinical Orthop* 1982;165:110–23.
47. Herzog RJ. Magnetic resonance imaging of the spine. In: Frymoyer JW, ed. *The Adult Spine*. New York: Raven Press; 1991:457–510.
48. Herkowitz HN, El-Kommas H. Clinical evaluation and differential diagnosis. In: Rothman RH, Simeone FA, eds. *The Spine*. Philadelphia: WB Saunders; 1993:827–57.
49. Morgan FP, King T. Primary instability of lumbar vertebraeas a common cause of low back pain. *J Bone Joint Surg Br* 1957;39:6–22.
50. Bozkuş H, Senoğlu M, Baek S, et al. Dynamic lumbar pedicle screw-rod stabilization: in vitro biomechanical comparison with standard rigid pedicle screw-rod stabilization. *J Neurosurg Spine* 2010;12: 183–9.
51. Schmoelz W, Onder U, Martin A, von Strempel A. Non-fusion instrumentation of the lumbar spine with a hinged pedicle screw rod system: an in vitro experiment. *Eur Spine J* 2009;18:1478–85.
52. Scifert JL, Sairyo K, Goel VK, et al. Stability analysis of an enhanced load sharing posterior fixation device and its equivalent conventional device in a calf spine model. *Spine (Phila Pa 1976)* 1999;24:2206–13.
53. Xu HZ, Wang XY, Chi YL, et al. Biomechanical evaluation of a dynamic pedicle screw fixation device. *Clin Biomech (Bristol, Avon)* 2006;21:330–6.
54. Fraudiger S, Dubois G, Lorrain M. Dynamic neutralization of the lumbar spine confirmed on a new lumbar spine Simulator in vitro. *Arch Orthop Trauma Surg* 1999;119:127–32.
55. Dubois G, Germay B, Prere J, Schwarzenbach O, Stoll TM. Dynamic stabilization: treatment of mobile vertebral instability. In: Kaech DL, Jinkins JR, eds. *Spinal Restabilization Procedures*. Amsterdam: Elsevier; 2002:345–54.
56. Kanayama M, Hashimoto T, Shigenobu K, Oha F, Ishida T, Yamane S. Non-fusion surgery for degenerative spondylolisthesis using artifi-

cial ligament stabilization: surgical indication and clinical results. *Spine* 2005;30:588–92.
57. Bothmann M, Kast E, Boldt GJ, Oberle J. Dynesys fixation for lumbar spine degeneration. *Neurosurg Rev* 2008;31:189–96.
58. Schmoelz W, Huber JF, Nydegger T, et al. Dynamic stabilization of the lumbar spine and its effects on adjacent segments: an in vitro experiment. *J Spinal Disord Tech* 2003;16:418–23.
59. Putzier M, Schneider SV, Funk JF, Tohtz SW, Perka C. The surgical treatment of the lumbar disc prolapse. Nucleotomy with additional transpedicular dynamic stabilization versus nucleotomy alone. *Spine* 2005;30:E109–14.
60. Kaner T, Sasani M, Oktenoglu T, Ozer AF, Cosar M. Clinical outcomes after posterior dynamic transpedicular stabilization with limited lumbar discectomy: Carragee system classification of lumbar disc herniations. *SAS J* 2010;4:92–7.
61. Cakir B, Ulmar B, Koepp H, Huch K, Puhl W, Richter M. Posterior dynamic stabilization as an alternative for dorso-ventral fusion in spinal stenosis with degenerative instability. *Z Orthop Ihre Grenzgeb* 2003;141:418–24.
62. Stoffel M, Behr M, Reinke A, Stüer C, Ringel F, Meyer B. Pedicle screw-based dynamic stabilization of the thoracolumbar spine with the Cosmic-system: a prospective observation. *Acta Neurochir (Wien)* 2010;152:835–43.
63. Strempel A, Neekritz A, Muelenaere P, et al. Dynamic versus rigid spinal implants. In: Gunzburg R, Szpalski M, eds. *Lumbar Spinal Stenosis*. Philadelphia: Lippincott-Williams and Wilkins; 2000:275–85.
64. Sasani M, Aydin AL, Oktenoglu T, et al. The combined use of a posterior dynamic transpedicular stabilization system and a prosthetic disc nucleus device in treating lumbar degenerative disc disease with disc herniations. *SAS J* 2008;2:62–8.
65. Kaner T, Sasani M, Oktenoglu T, Cosar M, Ozer AF. Utilizing dynamic rods with dynamic screws in the surgical treatment of chronic instability: a prospective clinical study. *Turkish Neurosurgery* 2009; 19:319–26.