

Do presence and location of annular tear influence clinical outcome after lumbar total disc arthroplasty? A prospective 1-year follow-up study

James J. Yue, Connor Telles, Thomas P. Schlösser, Shawn Hermenau, Ravi Ramachandran and William D. Long III

Int J Spine Surg 2012, 6 () 13-17

doi: <https://doi.org/10.1016/j.ijsp.2011.09.001>

<https://www.ijssurgery.com/content/6/13>

This information is current as of May 2, 2025.

Email Alerts Receive free email-alerts when new articles cite this article. Sign up at:
<http://ijssurgery.com/alerts>

Do presence and location of annular tear influence clinical outcome after lumbar total disc arthroplasty? A prospective 1-year follow-up study

James J. Yue, MD ^{a,*}, Connor Telles, MD ^a, Thomas P. Schlösser ^{a,b},
Shawn Hermenau, MD ^a, Ravi Ramachandran, MD ^a, William D. Long III, MD ^a

^a Department of Orthopaedic Surgery and Rehabilitation, Yale University School of Medicine/New Haven Hospital, New Haven, CT

^b Department of Orthopedics, University Medical Center Utrecht, Utrecht, the Netherlands

Abstract

Background: Lumbar total disc arthroplasty is often performed in patients with axial back pain. There are multiple etiologies for axial back pain, including disc degeneration and annular tears. The location of these annular tears can vary, producing differing preoperative symptomatology. Intraoperatively, disruptions in the annulus are identifiable, and it has been suggested that patients with discrete annular tears may have better clinical outcomes after surgery. The purpose of this study was to investigate whether the presence and location of annular tears have an effect on clinical outcomes after lumbar total disc arthroplasty.

Methods: Patients undergoing a single-level anterior disc replacement from L3-S1 at a single site by a single surgeon were evaluated preoperatively for the presence or absence of annular tears with magnetic resonance imaging. All patients were part of either the ProDisc (n = 41) (Synthes, Paoli, Pennsylvania) or Activ-L (n = 19) (Aesculap [B. Braun Melsungen AG], Tuttlingen, Germany) lumbar prospective clinical trials. In those patients with annular tears, the location of the tear (central, paracentral, or lateral) was documented. Patients were assessed at 6 and 12 months after lumbar total disc arthroplasty with the Oswestry Disability Index (ODI), visual analog scale (VAS) score for back pain, VAS score for leg pain, and radiographic imaging. All radiographic evaluations were conducted by an attending neuroradiologist and an attending spinal surgeon, and reliability testing was performed. An analysis of variance was performed among the 3 anatomic locations of annular tears.

Results: A total of 60 patients were included and had complete 12-month follow-up. The prevalence of annular tears among all patients was 42% (n = 25). Outcome data in patients without annular tears were as follows: ODI, 66% preoperatively and 26% postoperatively; VAS score for back pain, 8.0 preoperatively and 2.6 postoperatively; and VAS score for leg pain, 2.9 preoperatively and 1.2 postoperatively. Among those patients with tears, the prevalence of central tears was 80%, the prevalence of paracentral tears was 12%, and the prevalence of lateral tears was 8%. Outcome data in patients with central tears were as follows: ODI, 66% preoperatively and 26% postoperatively; VAS score for back pain, 7.8 preoperatively and 2.6 postoperatively; and VAS score for leg pain, 5.2 preoperatively and 0.5 postoperatively. Outcome data in patients with paracentral tears were as follows: ODI, 86% preoperatively and 59% postoperatively; VAS score for back pain, 8.8 preoperatively and 3.3 postoperatively; and VAS score for leg pain, 5.0 preoperatively and 5.4 postoperatively. Outcome data in patients with lateral tears were as follows: ODI, 6.5 preoperatively and 2.6 postoperatively; VAS score for back pain, 9.2 preoperatively and 0.2 postoperatively; and VAS score for leg pain, 1.4 preoperatively and 0.7 postoperatively. In those patients with paracentral tears, there was a significantly higher incidence of postoperative radicular symptoms both from an intensity standpoint and from a duration standpoint. Other complications did not vary among those patients with or without annular tears.

Conclusions: Although patients with annular tears and patients without annular tears improve after lumbar artificial disc replacement, those with central annular tears or without tears have significantly lower disability scores than those with paracentral tears or lateral tears, whose outcome scores showed significantly less improvement ($P \leq .03$). In particular, patients with central tears have less postoperative leg pain than those with paracentral annular tears. In this study the presence or absence of an annular tear on magnetic resonance imaging was not a significant predictive factor for clinical outcome. Further investigation regarding the effects of paracentral annular tears and surgical techniques should be explored.

© 2012 ISASS - International Society for the Advancement of Spine Surgery. Published by Elsevier Inc. All rights reserved.

Keywords: Lumbar disc arthroplasty; Annular tear; High intensity zone (HIZ)

The Food and Drug Administration device/drug status of Activ-L is investigational/not approved.

* Corresponding author: James J. Yue, MD, Department of Orthopaedic Surgery and Rehabilitation, Yale University School of Medicine, 800

Howard Ave, PO Box 208071, New Haven, CT 06520; Tel: 203-785-2579; Fax: 203-785-7132.

E-mail address: james.yue@yale.edu

Axial back pain is often a consequence of disc injury rather than musculotendinous or ligamentous strain, and it is often debilitating to patients. Experimental evidence suggests that disc injury results not necessarily from an acute traumatic etiology but rather results from an internal disruption of the annular lamellae as a result of a chronic degenerative process. Violations of disc integrity can be seen on magnetic resonance imaging (MRI) as separations in the annulus or at the vertebral insertions. Annular tears are most easily assessed during discography, where contrast can egress from the nucleus beyond the annular boundary. Annular tears have been seen in over one-third of asymptomatic patients, so their presence alone does not necessitate intervention. Significant controversy exists between the diagnostic imaging evidence and the clinical manifestation of such disc degeneration. Chemical and structural changes leading to an annular tear can cause pain through the stimulation of sinuvertebral nerves innervating the outer one-third of the annulus or chemical irritation of adjacent nerve roots.^{1,2}

Disc arthroplasty has been shown to be an effective treatment for discogenic lower-back pain in patients with degenerative disease.^{3–6} Preoperative MRI is used to evaluate the level of degeneration and relative health of the discs, potentially also identifying any annular tears as high-intensity zones (HIZs) on T2-weighted imaging. The role of MRI in predicting clinical outcome has been identified for nonsurgical treatment of diseases of the lumbar spine.^{7,8} The goal of this prospective study is to evaluate (1) the prognostic value of the presence of an annular tear on MRI in patients undergoing lumbar total disc replacements and (2) the prognostic value of its location (if there is an annular tear).

Methods

Patient evaluation

Prospective data were collected for single-level lumbar total disc replacements performed at Yale New Haven Hospital, New Haven, Connecticut, from July 2003 through July 2008. All patients had back pain at a single level of the lumbar spine, with or without leg pain. After a minimum of

6 months of unresponsiveness to adequate conservative treatment, patients underwent randomization. Patients participating in the ProDisc-L (Synthes, Paoli, Pennsylvania) trial were randomized to lumbar total disc replacement or fusion. Patients participating in the Activ-L (Aesculap [B. Braun Melsungen AG], Tuttlingen, Germany) trial were randomized to ProDisc or Activ-L lumbar total disc replacement. Exclusion criteria were as follows: at least 3 mm of translation or at least 5° of angulation, presence of osteophytes, disc height at least 2 mm smaller compared with adjacent level, herniated nucleus pulposus, or facet joint degeneration. Inclusion criteria were age between 18 and 60 years, willingness and physical ability to participate in the study for a minimum of 1 year of follow-up, Oswestry Disability Index (ODI) greater than 40%, visual analog scale (VAS) score for back pain greater than 40 mm (on a 100-mm VAS), and anterior accessibility of the lumbar spine. MRI evaluation for the presence and location of annular tears was conducted preoperatively by an attending neuroradiologist and an attending spinal surgeon. The presence of an annular tear was dichotomized into absent or present. An annular tear was defined as a fissure or focal hyperintensity within the posterior part of the annulus fibrosus without focal extrusion on T2-weighted imaging. When an annular tear was present, its location (central, lateral, or paracentral) was noted by the same experienced clinicians (Fig. 1). Localization of tears was defined in the same way disc herniations are defined (ie, lateral location is anatomically extraforaminal). Reliability testing showed high agreement between the observers (94% concordance, $\kappa = 0.89$).

Clinical outcome

Disability and pain scores were acquired with the ODI and VAS for back pain at 3 time points: preoperatively and at 6 and 12 months postoperatively. Patients participating in the Activ-L trial had VAS scores for leg pain compiled at the same time. Only cases with complete 1-year follow-up were used for this study. In addition to questionnaires, patients underwent clinical and radiographic evaluation at each clinical visit and complications were noted. Intraoper-

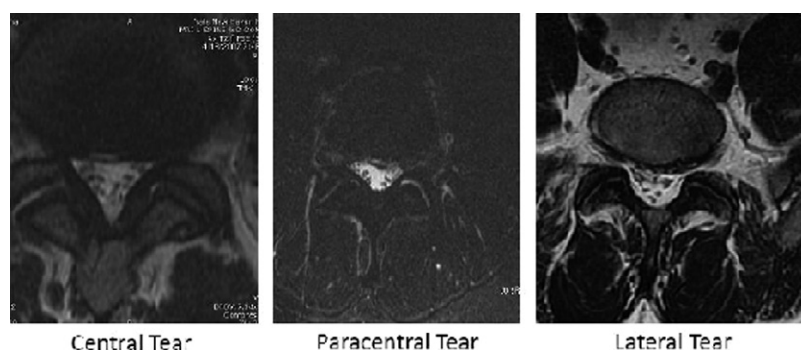


Fig. 1. Examples of 3 different anatomic locations of annular tears on MRI: central, paracentral, and lateral. The location of annular tears was defined in the same way herniations of the intervertebral disc are defined.

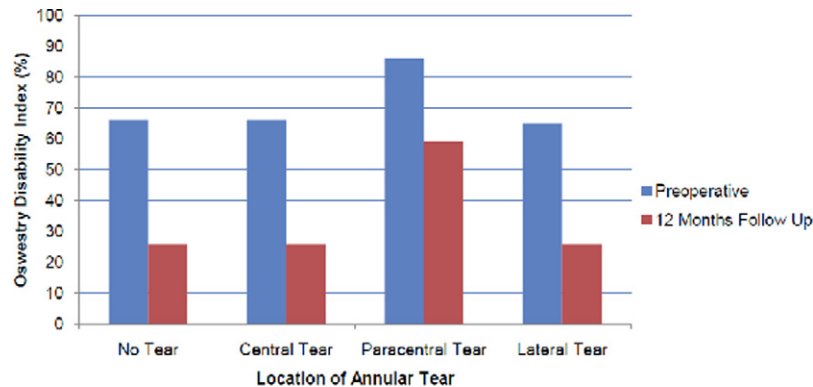


Fig. 2. Mean ODI scores (shown as percentages) in patients with annular tears (divided into 3 cohorts based on tear location) and patients without annular tears. Data were prospectively compiled before and 12 months after total lumbar disc replacement.

ative complications, duration of the procedure, and blood loss were also noted. All procedures were performed by the senior author. Bias regarding the primary outcome measurements was avoided with patients' responses on questionnaires. Data were analyzed by an independent examiner who was not involved in the surgical procedures or postoperative follow-up.

Statistical analysis

Data collection was performed with Excel 2007 for Windows (Microsoft, Redmond, Washington). Statistical analysis was performed with SPSS for Windows, version 17.0 (SPSS, Inc., Chicago, Illinois). For each cohort, analyses of differences in continuous data over time were performed with paired *t*-tests. Analysis of variance was used for analysis between the cohorts. Fisher's Least Significant Difference (LSD) post hoc tests were used for analysis of clinical outcome on different locations. Bonferroni correction was used to test the possible presence of a type I error. A *P* value of .05 was considered statistically significant.

Results

Demographic

During the research period, 68 patients were randomized to lumbar total disc replacement. Eight patients did not fulfill all follow-up criteria because of distant places of domicile. Preoperative radiographic evaluation of included patients resulted in 35 patients without annular tears and 25 patients with disruption on MRI. Of the patients without annular tears, 25 (71%) were men, as compared with 13 (52%) with annular violation. The mean age in the no-tear cohort was 39 years (SD, 7 years), and that in the tear cohort was 36 years (SD, 8 years). Of the observed annular tears, 80% were centrally localized, 12% laterally, and 8% paracentrally. There were no patients with multiple tears in different locations. ProDisc total disc replacement was performed in 24 patients (69%) without annular tears and 17 patients (68%) with tears on MRI. In the tear group, 15 patients (75%) with central tears, 1 (33%) with a paracentral

tear, and 1 (50%) with a lateral tear received ProDisc implants. Sixty-three percent of all procedures were performed at the lumbosacral level. All other procedures were performed at lumbar level L4-5. An artificial disc was used at L5-S1 in 20 patients (57%) without annular tears and 18 patients (72%) with annular tears. The frequencies of operative level L5-S1 by subcohort were 15 (75%) in central-tear patients, 2 (67%) in paracentral-tear patients, and 1 (50%) in lateral-tear patients.

Clinical outcomes

In both patients with annular tears and those without annular tears, mean ODI and VAS scores decreased over time with statistical significance ($P < .001$) (Figs. 2–4). ODI scores decreased from 66% to 26% in patients without annular tears ($P < .001$) and from 68% to 30% in patients with annular tears ($P < .001$). In the subcohorts of patients with central, paracentral, and lateral tears, the ODI scores decreased from 66% to 26% ($P < .001$), from 86% to 59% ($P = .101$), and from 65% to 26% ($P = .016$), respectively. VAS scores for back pain showed a statistically significant decrease over time both in patients with annular tears and in those without annular tears, from 8.0 to 2.6 ($P < .001$) and from 8.1 to 2.5, respectively. In the central-tear subcohort, the decrease in VAS scores for back pain, from 7.8 to 2.6, was significant ($P < .001$). In patients with tears in the lateral or paracentral locations, the decrease was not statistically significant over time. Over time, the decrease in mean VAS scores for leg pain was statistically significant for the tear cohort and central-tear subcohort, from 4.4 to 1.5 ($P = .024$) and 5.2 to 0.5 ($P = .003$), respectively.

Analyses with analysis of variance resulted in no statistically significant differences between the cohort with annular tears and the cohort without annular tears. No differences were seen for either mean clinical outcome scores at 12 months' follow-up ($P \geq .109$) or mean decrease over time ($P \geq .238$). LSD post hoc tests showed that patients with paracentral tears had significantly higher ODI scores at 12 months postoperatively

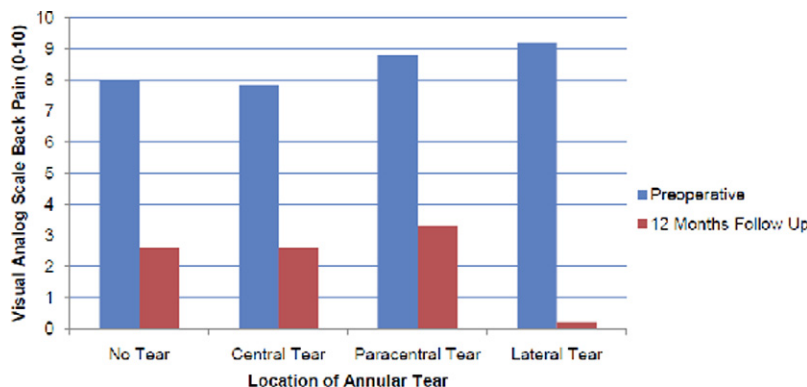


Fig. 3. Mean VAS scores for back pain in patients with annular tears (divided into 3 cohorts based on tear location) and patients without annular tears. Data were prospectively compiled before and 12 months after total lumbar disc replacement.

than central-tear patients and patients without annular tears ($P = .022$ and $P = .019$, respectively). Bonferroni post hoc tests did not show significant differences in ODI scores between these patients with annular tears at different locations ($P = .113$ and $P = .130$, respectively). LSD post hoc tests showed that patients with paracentral annular tears had significantly higher VAS scores for back pain at 12 months postoperatively compared with patients with centrally localized annular tears ($P = .019$) and with patients without tears ($P = .030$). Bonferroni post hoc tests did not show significant differences in VAS scores between these patients with annular tears at different locations ($P = .183$ and $P = .115$, respectively). No significant differences in clinical outcome scores were seen between patients with lateral tears and other patients.

In those patients with paracentral tears, there was a higher incidence of postoperative radicular symptoms both from an intensity standpoint and from a duration standpoint. No cases of loosening, mechanical failure, infection, or fusion at the affected segment occurred in this series. Furthermore, no intraoperative complications or neurovascular complications were identified during follow-up.

Discussion

Carragee and Kim⁹ showed that the morphometric features of disc herniation and the spinal canal on MRI are powerful predictors of clinical outcome after surgical treatment of disc herniations. In this prospective study, the presence of annular tears on MRI examination had no prognostic value for clinical outcome after treatment of degenerative disc disease with artificial disc replacement. However, patients with paracentral localization of annular tears had worse outcomes than patients with central annular tears or patients without annular tears. Paracentral localization of annular tears on MRI cannot be generalized as a negative prognostic factor for clinical outcome after lumbar total disc replacement, however, when accounting for Bonferroni correction.

Lumbar disc arthroplasty has emerged as an alternative to lumbar fusion in the treatment of degenerative disc disease and discogenic back pain. Although the effectiveness of lumbar total disc replacement is still being evaluated, it is important to define the predicting and complicating factors for the patient's clinical course. The indications for these procedures include degenerative changes in the vertebral disc, which—by defini-

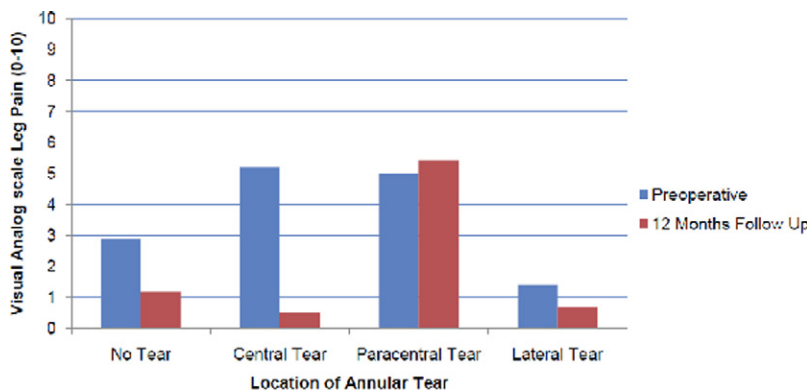


Fig. 4. Mean VAS scores for leg pain in patients with annular tears (divided into 3 cohorts based on tear location) and patients without annular tears. Data were prospectively compiled before and 12 months after total lumbar disc replacement.

tion—include annular tears. The sole presence of an annular tear is not an indication for disc replacement. In our study an annular tear was seen in 25 patients (41%) with complete follow-up. A particular difficulty for this type of study is the relative ubiquity of tears in the general population. Ernst et al.¹⁰ reported 11 annular tears in 30 asymptomatic volunteers (36.7%), whereas 7 years earlier, Stadnik et al.¹¹ found annular tears in 20 of 36 asymptomatic volunteers (56%) at the same medical center. In this study reliability testing for observing annular tears on MRI showed high agreement. This corresponds to the interobserver and intraobserver agreement reported by Arana et al.,¹² who showed almost perfect agreement for diagnosis of annular tears by MRI.

There is a general paucity of information regarding the natural history of annular tears. Disruption of the normal annular lamellae or internal disc architecture results in annular tears on MRI examination. The disc is able to leak out nuclear material from this violation and cause chemical irritation or mass effect on the adjacent nerve root, resulting in radiculopathy. The extrusion of nuclear material results in a poor capacity for the annulus to repair itself and thus continues to manifest as chronic back pain.^{13,14}

Conversely, there has been documented correlation of annular tears eliciting pain during discography in symptomatic patients with positive predictive values over 85%.^{15,16} Therefore the tear may not necessarily be considered an acute abnormality and more likely represents a phase in the internal degeneration of a disc, as described by Kirkaldy-Willis et al.¹⁷ Our study suggests that the presence or absence of tears does not predict clinical outcome after treatment of degenerative disc disease. Munter et al.¹⁴ looked at annular tears on serial MRI scans to determine whether there was any ability to date annular tears and to describe the natural radiologic course. They reported that MRI findings of annular tears do not change over time and, therefore, no conclusion can be made regarding the chronicity of the lesion.

The diagnostic value of HIZs on T2-weighted MRI is still being evaluated for reliably identifying annular tears. Annular tears are most easily assessed during discography, where contrast can egress from the nucleus beyond the annular boundary. Discography, however, remains an invasive procedure. Lam et al.¹⁸ showed significant correlation between lumbar disc HIZs with pain reproduction during discography and implied tear as a pain indicator. Peng et al.¹⁶ reported similar results, with all 17 discs with HIZs showing painful reproduction and abnormal morphology on discography. Earlier reports are conflicting, however, because Carragee et al.¹⁹ found that the same percentage of asymptomatic and symptomatic discs with HIZs were painful during discogram. This led the authors to conclude that HIZs do not reliably indicate the presence of symptomatic disc disruption.¹⁹ The current study did not investigate correlations between HIZs and preoperative discography results when analyzing the outcomes of disc replacement.

In conclusion, patients with or without annular tears improve after lumbar anterior disc replacement. In addition, patients with central annular tears or without tears have significantly lower disability scores than those with paracentral tears, whose outcome scores were significantly worse ($P \leq .03$). In particular, patients with central tears improve more with less postoperative leg pain

than patients with paracentral annular tears. Further investigation regarding the effects of paracentral annular tears and surgical techniques should be explored.

References

1. Roberts S, Beard HK, O'Brien JP. Biochemical changes of intervertebral discs in patients with spondylolisthesis or with tears of the posterior annulus fibrosus. *Ann Rheum Dis* 1982;41:78–85.
2. Roberts S, Caterson B, Menage J, et al. Matrix metalloproteinases and aggrecanase: their role in disorders of the human intervertebral disc. *Spine (Phila Pa 1976)* 2000;25:3005–13.
3. Zigler J, Delamarter R, Spivak JM, et al. Results of the prospective, randomized, multicenter food and drug administration investigational device exemption study of the ProDisc-L total disc replacement versus circumferential fusion for the treatment of 1-level degenerative disc disease. *Spine (Phila Pa 1976)* 2007;32:1155–62; discussion 1163.
4. Tropiano P, Huang RC, Girardi FP, Cammisia FP, Marnay T. Lumbar total disc replacement. Seven to eleven-year follow-up. *J Bone Joint Surg Am* 2005;87:490–6.
5. Tropiano P, Huang RC, Girardi FP, et al. Lumbar total disc replacement. Surgical technique. *J Bone Joint Surg Am* 2006;88(Suppl 1, Pt 1):50–64.
6. Zindrick MR, Tzermianios MN, Voronov LI, et al. An evidence-based medicine approach in determining factors that may affect outcome in lumbar total disc replacement. *Spine (Phila Pa 1976)* 2008;33:1262–9.
7. Choi SJ, Song JS, Kim C, et al. The use of magnetic resonance imaging to predict the clinical outcome of non-surgical treatment for lumbar intervertebral disc herniation. *Korean J Radiol* 2007;8:156–63.
8. Modic MT, Obuchowski NA, Ross JS, et al. Acute low back pain and radiculopathy: MR imaging findings and their prognostic role and effect on outcome. *Radiology* 2005;237:597–604.
9. Carragee EJ, Kim DH. A prospective analysis of magnetic resonance imaging findings in patients with sciatica and lumbar disc herniation. Correlation of outcomes with disc fragment and canal morphology. *Spine (Phila Pa 1976)* 1997;22:1650–60.
10. Ernst CW, Stadnik TW, Peeters E, Breucq C, Osteaux MJ. Prevalence of annular tears and disc herniations on MR images of the cervical spine in symptom free volunteers. *Eur J Radiol* 2005;55:409–14.
11. Stadnik TW, Lee RR, Coen HL, Neirynck EC, Buisseret TS, Osteaux MJ. Annular tears and disk herniation: prevalence and contrast enhancement on MR images in the absence of low back pain or sciatica. *Radiology* 1998;206:49–55.
12. Arana E, Royuela A, Kovacs FM, et al. Lumbar spine: agreement in the interpretation of 1.5-T MR images by using the Nordic Modic Consensus Group classification form. *Radiology* 2010;254:809–17.
13. Sharma A, Pilgram T, Wippold FJ II. Association between annular tears and disk degeneration: a longitudinal study. *AJNR Am J Neuroradiol* 2009;30:500–6.
14. Munter FM, Wasserman BA, Wu HM, Yousem DM. Serial MR imaging of annular tears in lumbar intervertebral disks. *AJNR Am J Neuroradiol* 2002;23:1105–9.
15. Aprill C, Bogduk N. High-intensity zone: a diagnostic sign of painful lumbar disc on magnetic resonance imaging. *Br J Radiol* 1992;65:361–9.
16. Peng B, Hou S, Wu W, Zhang C, Yang Y. The pathogenesis and clinical significance of a high-intensity zone (HIZ) of lumbar intervertebral disc on MR imaging in the patient with discogenic low back pain. *Eur Spine J* 2006;15:583–7.
17. Kirkaldy-Willis WH, Wedge JH, Yong-Hing K, et al. Pathology and pathogenesis of lumbar spondylosis and stenosis. *Spine (Phila Pa 1976)* 1978;3:319–28.
18. Lam KS, Carlin D, Mulholland RC. Lumbar disc high-intensity zone: the value and significance of provocative discography in the determination of the discogenic pain source. *Eur Spine J* 2000;9:36–41.
19. Carragee EJ, Paragioudakis SJ, Khurana S. Lumbar high-intensity zone and discography in subjects without low back problems. *Spine (Phila Pa 1976)* 2000;25:2987–92.