

INTERNATIONAL
JOURNAL
of
SPINE
SURGERY

Kinematic analysis following implantation of the PRESTIGE LP

Izabela Kowalczyk, Navjot Chaudhary and Neil Duggal

Int J Spine Surg 2013, 7 () e118-e122

doi: <https://doi.org/10.1016/j.ijsp.2013.10.003>

<https://www.ijssurgery.com/content/7/e118>

This information is current as of May 17, 2025.

Email Alerts Receive free email-alerts when new articles cite this article. Sign up at:
<http://ijssurgery.com/alerts>

Kinematic analysis following implantation of the PRESTIGE LP

Izabela Kowalczyk, BHSc^{a,b}, Navjot Chaudhary, MD^c, Neil Duggal, MD, MSc, FRCS(C)^{b,c,*}

^a Department of Medical Biophysics, University of Western Ontario, London, Ontario, Canada

^b Centre for Functional and Metabolic Mapping, Robarts Research Institute, University of Western Ontario, London, Ontario, Canada

^c Division of Neurosurgery, London Health Sciences Center, London, Ontario, Canada

Abstract

Background: The clinical success of cervical arthroplasty hinges on the ability to preserve or improve the biomechanics of the functional spinal unit. The purpose of this study was to conduct a radiologic assessment of kinematic parameters preimplantation and postimplantation of the PRESTIGE LP Cervical Disc System (Medtronic, Memphis, Tennessee).

Methods: A total of 120 radiographs of 20 patients following single-level implantation of the PRESTIGE LP were retrospectively reviewed. Static and dynamic radiologic assessments were performed before surgery and at 1 year postoperation. Kinematic parameters including range of motion (ROM), horizontal translation, center of rotation (COR X, Y), anterior disc height and posterior disc height, and disc angle and shell angle were assessed for each spinal level using quantitative motion analysis software. Clinical outcomes were assessed using the short form health survey physical component scores and mental component scores.

Results: The mean physical component scores and mental component scores of the short form health survey (SF-36) improved significantly following surgery. At 1 year postoperation, ROM, translation, and COR X were preserved. The COR Y shifted superiorly from 3.17 ± 2.08 mm preoperation to 0.98 ± 2.23 mm postoperation ($P < .001$). The anterior disc height and posterior disc height were significantly increased following surgery (3.97 ± 1.01 to 4.78 ± 1.11 mm and 3.04 ± 0.69 to 3.66 ± 0.61 mm, respectively; $P < .01$). The preoperative disc angle was $3.32^\circ \pm 2.92^\circ$ and the postoperative shell angle was $1.11^\circ \pm 4.29^\circ$, with a mean change of $-2.22^\circ \pm 4.63^\circ$ ($P < .05$).

Conclusions: The PRESTIGE LP maintained preoperative ROM, translation, and COR X values. The postoperative COR Y value changed significantly by shifting superiorly, accompanied by an increase in DH. There was a loss of lordosis at the level of surgery, with the PRESTIGE LP endplates having an almost parallel endplate configuration.

© 2013 ISASS – The International Society for the Advancement of Spine Surgery. Published by Elsevier Inc. All rights reserved.

Keywords: Cervical arthroplasty; Cervical disc prosthesis; PRESTIGE LP; Total disc replacement; Kinematics; Range of motion

Introduction

Anterior cervical discectomy and fusion (ACDF) is the most common surgical procedure for symptomatic cervical spondylosis. Although fusion rates approach 95%, kinematics at adjacent segments may be altered.^{1,2} The proposed underlying mechanism for the accelerated adjacent segment disease (ASD) is increased motion and intradiscal pressure at adjacent levels, thereby disrupting nutrient diffusion.^{3–8} Hilibrand et al.⁶ found that 2.9% of ACDF patients developed symptomatic ASD per year. Goffin et al.⁵ reported 92% of fusion patients had radiologic ASD at a

5-year follow-up. As a result, cervical arthroplasty has emerged as an alternative to fusion.

The PRESTIGE LP (Medtronic Sofamor Danek, Memphis, Tennessee) is a fifth generation artificial disc in the PRESTIGE family and has several features that distinguish it from its predecessors.⁹ The PRESTIGE LP is manufactured from a unique titanium ceramic composite that is highly durable and imaging friendly on magnetic resonance imaging. In this study, our objective was to determine whether the PRESTIGE LP preserves preoperative kinematic parameters. Quantitative motion analysis (QMA) software (Medical Metrics, Inc., Houston, Texas) was used to evaluate the in vivo biomechanical effect of the PRESTIGE LP.

Materials and methods

A total of 22 patients with cervical spondylosis, presenting with radiculopathy or myelopathy or both were recruited

* Corresponding author: Neil Duggal, MD, MSc, FRCS(C), Division of Neurosurgery, Clinical Neurological Sciences, University Hospital, London Health Sciences Center, 339 Windermere Rd, London, Ontario, Canada N6A 5A5. Tel.: +1-519-663-2926; fax: +1-519-663-2947.

E-mail address: Neil.Duggal@lhsc.on.ca

consecutively and underwent single-level anterior cervical discectomy followed by implantation of the PRESTIGE LP. Exclusion criteria included radiographic instability, active infection, inability to visualize the affected disc space on optimized lateral fluoroscopy, kyphotic alignment, and less than 2 degrees of motion at the segment of question on dynamic radiographs. Patients with previous cervical spine surgery and follow up of less than 12 months were also excluded from the study ($n = 2$). Nerve root compression was verified preoperatively using clinical assessment and magnetic resonance imaging. Static and dynamic digital radiographs were obtained preoperatively and at 12 months postoperation. Radiographic technique has been described previously.¹⁰ The PRESTIGE LP was inserted by a technique described by Mummaneni et al.⁹ The Short Form Health Survey (SF-36) questionnaire was used to determine the general health outcome of the patient population. Clinical evaluation included the physical health component score (PCS) and the mental health component score (MCS). This study was approved by the Health Sciences Research Ethics Board at the University of the Western Ontario. Informed consent was obtained from all patients.

Preoperative and postoperative standing lateral (neutral, flexion, and extension) radiographs of the cervical spine were analyzed using QMA software (Medical Metrics, Inc., Houston, Texas). This technique has been previously described.⁹ This validated radiographic motion analysis software uses advanced pattern recognition algorithms to generate accurate measurements of range of motion (ROM), translation, center of rotation in the X and Y direction (COR X, Y), anterior disc height and posterior disc height (ADH and PDH, respectively), and disc angle and shell angle (DA and SA, respectively). The COR is the point about which the superior vertebra rotates with respect to the inferior vertebra. It was obtained for the index spinal levels and reported as (X, Y) normalized from the midline of the superior endplate of the inferior vertebral body.^{10,15}

Statistical analysis

ROM, translation, COR X and Y, ADH, PDH, DA, and SA were compared longitudinally using a paired 2-tailed Student's *t* test with the significance set at the 0.05 level. All data is represented as the mean \pm the standard deviation.

Results

Patient population

A total of 120 radiographs in 20 patients (12 men and 8 women) with a mean age of 45.4 years (range: 28–58 years) were analyzed. All patients had a single-level arthroplasty: 1 at C3-4; 3 at C4-5; 13 at C5-6; and 3 at C6-7 disc level. The mean preoperative PCS and MCS were 40 ± 15 and 56 ± 17 , respectively. Both scores improved significantly following surgery (PCS: 71 ± 20 , $P < .001$; MCS: 84 ± 12 , $P < .001$). The follow-up time was a minimum of 12 months. There were no explanations or complications. There were no cases of migration or subsidence of the prosthesis or osteolysis.

Kinematic parameters

Kinematic analysis demonstrated no significant change from preoperative to postoperative ROM ($7.22^\circ \pm 3.54^\circ$ to $9.67^\circ \pm 5.23^\circ$; $P = .10$), translation (0.79 ± 0.45 to 0.93 ± 0.44 mm; $P = .33$), and COR X (-0.93 ± 0.95 to -0.65 ± 1.14 mm; $P = .32$). The COR Y was significantly shifted superiorly, from a preoperative location of 3.17 ± 2.08 to 0.98 ± 2.23 mm postoperation ($P < .001$; Fig. 1). At 1 year, both the ADH and PDH were significantly increased (3.97 ± 1.01 to 4.78 ± 1.11 mm and 3.04 ± 0.69 to 3.66 ± 0.61 mm, respectively; $P < .01$; Fig. 2).

Alignment

The preoperative DA was $3.32^\circ \pm 2.92^\circ$ and the postoperative SA was $1.11^\circ \pm 4.29^\circ$, with a mean change of

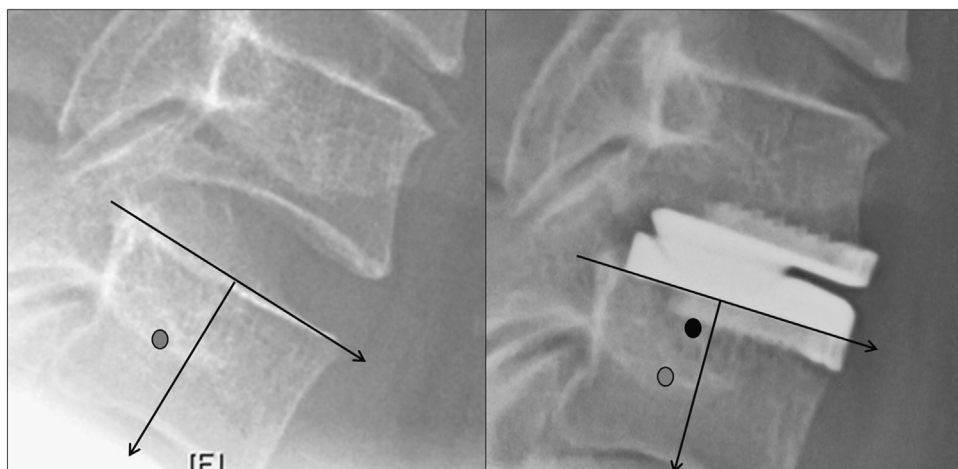


Fig. 1. There were no significant changes in the COR X values preoperatively (left) compared with postoperatively (right). However, there was a significant change in COR Y values postoperatively (dark circle), suggesting the ball-in-trough design of the PRESTIGE LP shifted the COR superiorly toward the disc space.

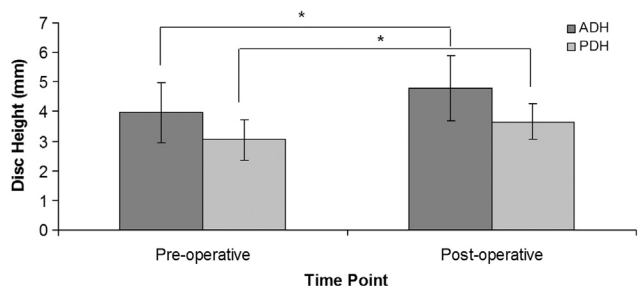


Fig. 2. The mean ADH and PDH values in the PRESTIGE LP Cervical Disc. Bars represent the standard deviations. Asterisk (*) represents a significance level of $P < .05$.

$-2.22^\circ \pm 4.63^\circ$ ($P < .05$; Fig. 3). These results suggest that implantation of the PRESTIGE LP significantly reduced segmental lordosis at the index level.

Discussion

The clinical success of cervical arthroplasty hinges on the ability to preserve biomechanics of the functional spinal unit (FSU). The present in vivo study demonstrated that PRESTIGE LP is able to maintain preoperative physiological motion. There were no significant changes in ROM, translation, or COR X after implantation of the PRESTIGE LP. There was, however, a significant change in COR Y values, suggesting the ball-in-trough design of the PRESTIGE LP shifted the COR superiorly toward the disc space. Like other cervical disc replacements, the disc space height increased following cervical arthroplasty. The SA was virtually parallel, but decreased from the preoperative lordotic DA.

The first PRESTIGE implant was the Bristol-Cummins disc developed in 1989.⁴ Between 1991 and 1996, 22 joints

were implanted in 20 patients.⁴ In 1996, 18 of these patients were re-examined, and all but 2 were mobile at the implanted level.⁴ In this historical cohort, 1 device was removed owing to a hardware failure (screw breakage and minor back-out).⁴ In a recent multicenter study, Mummaneni et al.¹¹ prospectively randomized 541 participants to the PRESTIGE ST (fourth generation) and ACDF. At the 12- and 24-month follow-up, they found PRESTIGE ST patients had clinical improvement, higher rate of neurological success, lower rate of secondary revision and supplemental fixation, returned to work 16 days sooner, lower rates of adjacent-segment operation, and no cases of implant failure or migration.¹¹ The PRESTIGE LP is the fifth generation artificial disc and differs from its predecessors. The acute fixation is completed with a set of rails that are placed directly on the intervertebral disc as opposed to securing the implant to the intervertebral bodies with screws. The ball-in-trough design allows for anterior-posterior translation independent of flexion-extension motion.

The authors found no significant changes in ROM or translation after anterior cervical discectomy with implantation of the PRESTIGE LP. Rousseau et al.¹² used SpineView Software (Surgiview, Paris, France) to investigate the intervertebral sagittal ROM and COR in 26 PRESTIGE LP and 35 ProDisc-C (Synthes, West Chester, Pennsylvania) patients in reference to the measurements of 200 healthy cervical discs in vivo. They reported ROM was significantly reduced with both types of arthroplasty when compared with the normal control group. Our results suggest a trend toward increased motion following arthroplasty. It is important to note that the preoperative ROM in our study represented the ROM of a degenerated cervical disc and

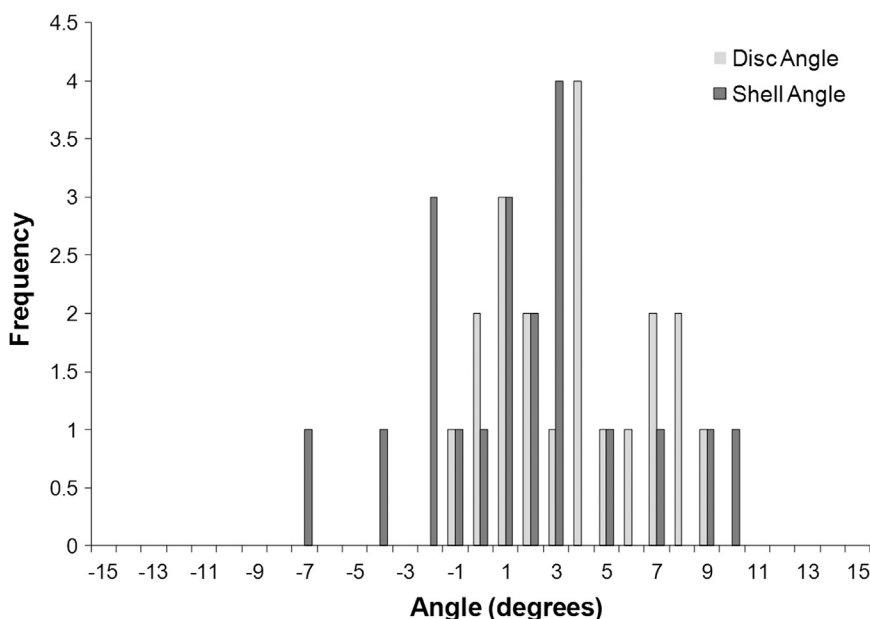


Fig. 3. A histogram of the DA and SA in the PRESTIGE LP Cervical Disc. The mean preoperative DA was $3.32^\circ \pm 2.92^\circ$. After the insertion of the PRESTIGE LP disc, the mean SA was $1.11^\circ \pm 4.29^\circ$.

may not correspond with healthy volunteers. In another study, Chang et al.³ tested 18 cadaveric human cervical spines for different modes of motion (extension, flexion, lateral bending, and axial rotation) up to 2 Nm in 3 groups (PRESTIGE II, ProDisc-C, and ACDF). At the surgically treated segment, the ROM was significantly increased for both types of cervical discs compared with the fusion group.³ Similar to our results, Robertson and Metclaf¹³ followed up with 17 patients who received the PRESTIGE I device and reported that rotation, translation, and angulation were maintained at the treated segment at 3 and 4 years postoperation. In another study, Porchet and Metcalf randomized 55 patients to PRESTIGE II and ACDF groups and found that the PRESTIGE II maintained motion at the treated level and adjacent segments at 24 months following surgery.¹⁴ In addition, it has been demonstrated that the PRESTIGE ST has the ability to maintain physiological, segmental motion at the surgical level up to 24 months postoperation.¹¹ Segmental lordosis following arthroplasty is affected by the design of the artificial disc.

Our study was unique in examining COR following insertion of the PRESTIGE LP. The design of the PRESTIGE LP incorporates a “ball-and-trough” design, where the ball is incorporated into the superior endplate. The COR Y shifted superiorly by 1.87 ± 2.07 mm following insertion of the PRESTIGE LP (Fig. 1). The clinical consequences of shifting the COR remains controversial. From an engineering and biomechanical perspective, the superior shift of the COR may affect facet degeneration, quality of motion as well as wear characteristics. In the cadaver study Rousseau et al.¹² found that although the COR remained within normal range in most cases, it tended to be located more anterior or superior or both than normal with both types of prosthesis. In the PRESTIGE LP group ($n = 14$), the COR X was within normal range for 8 cases and displaced anteriorly in 6 cases.¹² This suggests the device was not inserted posterior enough in its final placement.¹² The COR Y was within normal range for 10 patients and shifted superiorly in 4 cases.¹² The ball-and-trough design should allow for pure translation, instead of rotatory translation as seen in a ball-and-socket design. Incorporation of translation into the design should provide a mobile COR, allowing the postoperative COR to mimic the preoperative state. Our results would suggest that despite the role of the facets and soft tissues in guiding the intervertebral kinematics, the influence of the articulating geometry of the bearing surface should not be underestimated.¹²

Insertion of the PRESTIGE LP had a significant effect on disc height. All 20 devices used in our series had a 5-mm device height. At the surgical level, disc height in the neutral position was significantly increased both anteriorly and posteriorly (Fig. 2). The preoperative discs had decreased height secondary to desiccation, herniation, or bulging. The postoperative increase in disc height may in fact be a closer approximation of the properties of a healthy native disc. The effect of disc height on alignment was

demonstrated by Johnson et al.⁷ who studied 13 patients with a mean preoperative DA of 1° and noted that the preoperative symptomatic disc was kyphotic because of a loss of ADH. Further studies will be needed to further examine the ideal disc height required to restore normal kinematics to the index and adjacent levels following cervical arthroplasty.

Maintaining alignment of the spine is integral to any surgical procedure, whether it is a fusion or arthroplasty. We found a preoperative DA of $3.32^\circ \pm 2.92^\circ$ and a postoperative SA of $1.11^\circ \pm 4.29^\circ$, with a mean change of $2.22^\circ \pm 4.63^\circ$ (Fig. 3). The endplate alignment of a disc replacement can be influenced by a number of factors including the angle of disc insertion as well as the extent of bone removal and endplate preparation. Pickett et al.¹⁵ studied the Bryan disc and found that both, the endplate angle of the treated disc space and the angle of the FSU, became kyphotic after insertion of the Bryan prosthesis. Anakwenze et al.¹⁶ reported an increase in the operative level and total cervical lordosis following ProDisc-C insertion. Similarly, Ahn et al.¹⁷ show that ProDisc-C replacement corrected segmental degenerative kyphosis at the surgical level. Du et al.¹⁸ reported that the insertion of the Discover disc increased the FSU and global ROM angles at the index segments. However, incorporation of lordosis into the endplates of a ball-and-socket design articulation simply only recenters motion. For instance, if the surgical level has a 0° disc space angle, adding a device with 6° endplates will result in the development of kyphosis in the endplates, not correction of the disc space angle to 6° . Studies have also illustrated a loss of lordosis at the operative level at the early follow-up period followed by an increase in lordosis at the late (> 2 years) follow-up periods.^{17–19} This might be owing to patients not cooperating in the flexion-extension radiographs to their full ability because of postoperative pain.^{17–20} Our study suggests that device endplate angle was almost parallel. Given that PRESTIGE LP has a ball-and-trough design, it does not have any design features that would allow it to provide, preserve, or restore lordosis. In fact, parallel endplates is the preferred endplate configuration to maximize ROM. Peng et al.²¹ recently analyzed 40 patients with 59 PRESTIGE LP discs and found that global alignment was maintained up to 2 years postoperation. Lazaro et al.²⁰ showed the ProDisc-C maintained the ROM at the implanted level with a slightly lordotic SA of $1.1^\circ \pm 3.6^\circ$ with 15% of patients demonstrating worsening kyphosis and 15% showing hyperlordosis. In another study, Oh et al.²² compared 10 Bryan disc patients with 15 PRESTIGE LP patients. Postoperative cervical (C2-7) curvature was more lordotic in the PRESTIGE LP patients. The PRESTIGE LP was able to restore global cervical curvature and potentially protect the adjacent levels. Interestingly, we found a loss of 2° of lordosis at the surgical level after placement of the PRESTIGE LP. Harrison et al.²³ studied 252 subjects who were asymptomatic and found that the average lordosis

between cervical vertebrae was between 6° and 7°. These results would suggest that to restore sagittal alignment, as performed in fusion surgery, ideally a disc replacement should introduce or maintain approximately 6° of lordosis at the index level.

The objective of our study was to examine the biomechanical properties of the PRESTIGE LP. Only the index level was measured to determine the effect of the prosthesis on the kinematic parameters and alignment. Others have reported the clinical results and adjacent-level parameters following PRESTIGE LP insertion.^{3,13} Robertson and Metcalf¹³ examined the clinical effect of arthroplasty in 17 patients who received the PRESTIGE I and found good improvement at 3- and 4-year follow-ups using the Neck Disability Index and Short Form Health Survey questionnaires. DiAngelo et al.²⁴ reported that the PRESTIGE LP did not change the motions patterns at the index or adjacent levels.

The current study is limited by a short follow-up time of 1 year and a small sample size of 20 patients. In previous studies, we have demonstrated that the kinematic parameters of a cervical disc replacement are reliable and static after a 1-year follow-up period.²⁰ Our study also carries the inherent limitations of the QMA software, addressing only flexion/extension ROM and does not characterize the biomechanical behavior of the PRESTIGE LP in axial rotation or lateral bending. Furthermore, although QMA software has demonstrated good reliability and accuracy, the analysis may be limited by patient factors including cervical pain, out-of-plane motion, and patient body habitus.⁹

Conclusion

The PRESTIGE LP maintains preoperative ROM, translation, and COR X at the index level. Postoperatively, COR Y changed significantly compared with preoperative values and was shifted superiorly. The superior location of COR Y may be explained by device design, as the ball is located on the superior rather than the inferior endplate. As expected, the ADH and PDH increased postoperatively, more closely approximating the properties of a healthy native disc. There was a 2° loss of lordosis at the surgical level.

References

1. Baskin DS, Ryan P, Sonntag V, Westmark R, Widmayer MA. A prospective, randomized, controlled cervical fusion study using recombinant human bone morphogenetic protein-2 with CORNERSTONE-SR allograft ring and the ATLANTIS anterior cervical plate. *Spine* 2003;28:1219–25.
2. Boakye M, Mummaneni PV, Garrett M, Rodts G, Haid R. Anterior cervical discectomy and fusion involving a polyetheretherketone spacer and bone morphogenetic protein. *J Neurosurg Spine* 2005;2: 521–5.
3. Chang U, Kim DH, Lee MC, Willenberg R, Kim SH, Lim J. Changes in adjacent-level disc pressure and facet joint force after cervical

arthroplasty compared with cervical discectomy and fusion. *J Neurosurg Spine* 2007;7:33–9.

4. Cummins BH, Robertson JT, Gill SS. Surgical experience with an implanted artificial cervical joint. *J Neurosurg* 1998;88:943–8.
5. Goffin J, van Loon J, Van Calenbergh F, Plets C. Long-term results after anterior cervical fusion and osteosynthetic stabilization for fractures and/or dislocations of the cervical spine. *J Spinal Disord* 1995;8:500–8.
6. Hilibrand AS, Carlson GD, Palumbo MA, Jones PK, Bohlman HH. Radiculopathy and myelopathy segments adjacent to the site of a previous anterior cervical arthrodesis. *J Bone Joint Surg Am* 1999;81:519–28.
7. Johnson JP, Laurysen C, Cambron HO, et al. Sagittal alignment and the Bryan cervical artificial disc. *Neurosurg Focus* 2004;17:E14.
8. Kaiser MG, Haid Jr. RW, Subach BR, Barnes B, Rodts Jr. GE. Anterior cervical plating enhances arthrodesis after discectomy and fusion with cortical allograft. *Neurosurgery* 2002;50:229–38.
9. Mummaneni PV, Robinson JC, Haid RW. Cervical arthroplasty with the PRESTIGE LP cervical disc. *Neurosurgery* 2007;60:310–5.
10. Pickett GE, Rouleau JP, Duggal N. Kinematic analysis of the cervical spine following implantation of an artificial cervical disc. *Spine* 2005;30:1949–54.
11. Mummaneni PV, Burkus JK, Haid RW, Traynelis VC, Zdeblick TA. Clinical and radiographic analysis of cervical disc arthroplasty compared with allograft fusion: A randomized controlled clinical trial. *J Neurosurg Spine* 2007;6:198–209.
12. Rousseau M, Cottin P, Levante S, Nogier A, Lazennec JY, Skalli W. In vivo kinematics of two types of ball-and-socket cervical disc replacements in the sagittal plane. *Spine* 2008;33:E6.
13. Robertson JT, Metcalf N. Long-term outcome after implantation of the Prestige I disc in an end-stage indication 4-year results from a pilot study. *Neurosurg Focus* 2004;17:E10.
14. Porchet F, Metcalf NH. Clinical outcomes with the Prestige II cervical disc: Preliminary results from a prospective randomized clinical trial. *Neurosurg Focus* 2004;17:E6.
15. Pickett GE, Mitsis DK, Sekhon LH, Sears WR, Duggal N. Effects of a cervical disc prosthesis on segmental and cervical spine alignment. *Neurosurg Focus* 2004;17:E5.
16. Anakwenze OA, Auerbach JD, Milby AH, Lonner BS, Balderston RA. Sagittal cervical alignment after cervical disc arthroplasty and anterior cervical discectomy and fusion. *Spine* 2009;34:2001–7.
17. Ahn PG, Kim KN, Moon SW, Kim KS. Changes in cervical range of motion and sagittal alignment in early and late phases after total disc replacement: Radiographic follow-up exceeding 2 years. *J Neurosurg Spine* 2009;11:688–95.
18. Du J, Li M, Liu H, Meng H, He Q, Luo Z. Early follow-up outcomes after treatment of degenerative disc disease with the Discover cervical disc prosthesis. *Spine J* 2011;11:281–9.
19. Barrey C, Champain S, Campana S, Ramadan A, Perrin G, Skalli W. Sagittal alignment and kinematics at instrumental and adjacent levels after total disc replacement in the cervical spine. *Eur Spine J* 2012;21: 1648–59.
20. Lazaro BCR, Yucesoy K, Yuksel KZ, et al. Effect of arthroplasty design on cervical spine kinematics: Analysis of the Bryan Disc, ProDisc-C, and Synergy Disc. *Neurosurg Focus* 2010;28:E6.
21. Peng CW, Yue WM, Basit A, et al. Intermediate results of the Prestige LP cervical disc replacement: Clinical and radiological analysis with minimum two-year follow-up. *Spine* 2011;36:E105.
22. Oh HM, Park HS, Rhee DY, et al. Preliminary radiological outcomes of cervical arthroplasty with Bryan and Prestige LP cervical disc prosthesis. *Korean J Spine* 2008;5:124–9.
23. Harrison DD, Harrison DE, Janik TJ, et al. Modeling of the sagittal cervical spine as a method to discriminate hypolordosis: Results of elliptical and circular modeling in 72 asymptomatic subjects, 52 acute neck pain subjects, and 70 chronic neck pain subjects. *Spine* 2004;29:2485–92.
24. DiAngelo DJ, Robertson JT, Metcalf NH, McVay BJ, Davis RC. Biomechanical testing of an artificial cervical joint and an anterior cervical plate. *J Spinal Disord Tech* 2003;16:314–23.