

Pedicle Reduction Osteotomy in the Upper Cervical Spine: Technique, Case Report and Review of the Literature

Nicholas Post, Qais Naziri, Colin S. Cooper, Robert Pivec and Carl B. Paulino

Int J Spine Surg 2015, 9 ()

doi: <https://doi.org/10.14444/2057>

<https://www.ijssurgery.com/content/9/57>

This information is current as of May 17, 2025.

Email Alerts Receive free email-alerts when new articles cite this article. Sign up at:
<http://ijssurgery.com/alerts>

Pedicle Reduction Osteotomy in the Upper Cervical Spine: Technique, Case Report and Review of the Literature

Nicholas Post, MD, Qais Naziri, MD, Colin S. Cooper, MD, Robert Pivec, MD, Carl B. Paulino, MD
SUNY Downstate Medical Center, New York, NY

Abstract

Objective

To present a case report of the correction of a degenerative cervical 45-degree kyphosis centered at C4 with a single stage PSO.

Summary of Background Data

Correction of a fixed cervical kyphosis is a surgical challenge that is frequently managed with a combination of anterior and posterior surgical procedures. An alternative the three stage operation is a single stage pedicle subtraction osteotomy (PSO). A PSO releases the posterior, middle and anterior columns of the spine by resecting the facet joints, pedicles, and a portion of the vertebral body at the apex of a kyphosis through a posterior approach.

Methods

This was a case report of a patient who had degenerative cervical 45 degree kyphosis and was corrected with a single stage pedicle subtraction osteotomy. We did a literature review to provide information on current techniques to treat these patients.

Results

With careful resection of the lateral mass and decompression of the vertebral artery by removal of the posterior margin of the foramen transversarium the upper cervical pedicles can be accessed and a PSO can be performed. The vertebral arteries were not obstructed or kinked with posterior reduction of the PSO in this case.

Conclusions

A closing wedge PSO is a useful tool for correcting fixed kyphotic deformities in the upper cervical spine. Further studies are necessary to evaluate the long-term outcomes in these patients.

KEYWORDS: PEDICLE REDUCTION OSTEOTOMY, CERVICAL SPINE, SURGICAL TECHNIQUE
VOLUME 9 ARTICLE 57 DOI: 10.14444/2057

Introduction

Correction of a fixed cervical kyphosis is a surgical challenge that is frequently managed with a combination of anterior and posterior surgical procedures. Stand alone posterior correction is often limited to flexible kyphotic deformities that can be reduced in a closed fashion prior to instrumented stabilization.¹ Unlike flexible deformities, fixed kyphotic deformities are treated through multistage anterior-posterior surgeries.²⁻⁴ Immobile posterior facet joints prohibit sagittal correction through a single anterior approach. Likewise, extensive spondylosis of the disc spaces limit correction from a single stage posterior approach. Therefore a multistage posterior, anterior, posterior surgery may be required to restore normal

cervical lordosis. While effective, this multistage approach is labor intensive and exposes to the patient to complications arising from both anterior and posterior operations as well as prolonged anesthesia times.¹

An alternative to this three stage operation is a single stage pedicle subtraction osteotomy (PSO). A PSO releases the posterior, middle and anterior columns of the spine by resecting the facet joints, pedicles, and a portion of the vertebral body at the apex of a kyphosis through a posterior approach. This permits restoration of normal anatomic alignment and stabilization in a single stage. The technique of cervical PSO has only been described at the cervicothoracic junction and reports of PSOs in the upper cervical spine have not been described.⁵

We present the correction of a degenerative cervical 45 degree kyphosis centered at C4 with a single stage PSO. The techniques employed in this case are discussed with attention to strategies used to decompress the vertebral artery and exiting nerve roots prior to PSO reduction. In select patients a single stage PSO is a surgical alternative to treat a fixed kyphosis of the upper cervical spine.

Discussion

Review of Literature

Most of the published reports about osteotomies address their use in the thoracic and lumbar spines.

Smith-Peterson first described an extension osteotomy to correct flexion deformities of the lumbar spine in patients with rheumatoid arthritis in 1945.⁶ This Smith-Peterson osteotomy (SPO) involves removing the laminae and facet joints to decompress the nerve roots prior to applying an extension force to distract the anterior column through the disc space while simultaneously compressing the posterior column along the osteotomy. In contrast to a PSO, Smith-Peterson's osteotomy (SPO) does not involve resection of the pedicle or lateral wall of the vertebral body.

Thomassen described the PSO in 1985 to treat thoracolumbar kyphotic deformities in patients with ankylosing spondylitis.⁷ In addition to resecting the laminae and facet joints as in the SPO, the pedicles and a wedge of the vertebral body are also removed with a PSO. Once bone work is complete the extension force is applied to close the wedge defect in the vertebral body. A PSO, therefore, corrects the kyphosis by compressing the middle and posterior columns while leaving the height of the anterior column unchanged.

PSOs have several advantages over SPOs. First, the amount of sagittal correction with a PSO is greater than with a SPO. SPOs average only 10.7 degrees of sagittal correction per segment while PSOs average 33 degrees of correction per segment.⁸ Second, follow-up anterior stabilization is required less often with PSOs. 87 percent of patients who had SPOs required anterior arthrodesis compared to 39 percent for patients with PSOs.⁸ This is due to the fact that a

PSO results in apposition of bone surfaces of the anterior and middle columns, unlike the SPO.

PSOs also have several major drawbacks. The resection of the vertebral body in a PSO is associated with significant blood loss. Also, if the left and right portions of the vertebral resection are not symmetric, a coronal deformity can result when the osteotomy is closed.⁹ Yet, in spite of these risks, PSOs have been found to provide better correction of kyphosis with shorter operating times and less blood loss compared to circumferential fusion in the thoracic and lumbar spines.¹⁰

In 1958 Urist published the first report of modified SPO of the cervical spine to correct a flexion deformity in a patient with ankylosing spondylitis.¹¹ This initial description of a cervical extension osteotomy with distraction of the anterior column has been followed-up by several case series. Law briefly described two cases of extension osteotomies at C3-4 in 1959 using a similar technique.¹² McMaster published 15 cases in 1997,¹³ Belanger et al. published 26 cases,¹⁴ and Simmons published the largest series of 114 patients in 2006.¹⁵ All of these case series employed a technique similar to that first described by Urist; that is a modified extension osteotomy with distraction of the anterior column. Tokala et al. first described use of a PSO as defined by Thomassen at C7 in eight patients in 2007.¹⁶ Deviren et al. published a series of 11 cases of Thomassen's PSO at the cervicothoracic junction in 2011.⁵ With the exception the brief report by Law, these case series focus on extension osteotomies at the C7 level and no case series discussed the unique challenges of performing a PSO in the upper cervical spine.

Simmons cited three reasons for performing an extension osteotomy at the C7 level.¹⁷ First the diameter of the spinal canal is larger at C7 than in the mid cervical spine. Second, iatrogenic injury to the spinal cord at the C7 level would preserve upper extremity function. And finally, the vertebral artery, which enters the foramen transversarium at C6, is avoided in the C7 osteotomy.

Mummaneni et al. modified this osteotomy technique described by Simmons to perform an C6 exten-

sion osteotomy in a case report.¹⁸ Due to concerns about injury and kinking of the vertebral artery an anterior procedure was performed to open the disc space and release the vertebral artery from the foramen transversaria prior to the posterior extension osteotomy. Unlike a PSO, this cervical extension osteotomy achieves most of the deformity correction through distraction of the anterior column and does not require extensive resection of the lateral pedicle and vertebral body that could jeopardize the vertebral artery.

Technique

Preoperative planning must take into account the location and course of the vertebral arteries, the degree and locations of any stenosis of the cervical spinal canal as well as the apex of the cervical kyphosis.

The greatest concern in planning a high cervical PSO is iatrogenic injury to the spinal cord, nerve roots and vertebral arteries. Flexion-extension films help define the apex of the kyphosis and determine if the kyphosis is amenable to closed reduction. Any patients who demonstrate severe spinal cord compression with associated signal change might not be appropriate candidates for this approach. Although not utilized in this example, dedicated pre-operative imaging of the vertebral arteries would be beneficial when selecting patients best suited for this technique; patients with a single vertebral artery might not be ideal candidates. Study of pre-operative CT imaging helps define the location of the vertebral artery in the foramen transversarium and its relationship to the pedicles as well as their respective size.

The lateral aspect of the cervical pedicle comprises the medial wall of the foramen transversarium. This medial portion of the foramen transversarium must be removed along with the lateral vertebral body to perform a closing wedge osteotomy in the upper cervical spine. This resection of the lateral cervical vertebra can not be performed safely unless the entire segment of the vertebral artery is freed from the transverse foramen. Additionally, any impingement of the vertebral artery by residual bone of the foramen transversarium may lead to compromise of the vertebral artery and possible stroke during closure of the osteotomy.

The nerve roots and spinal cord also must be thoroughly decompressed to safely perform a closing wedge PSO in the upper cervical spine. A generous laminectomy including one level above and below the location of the PSO is performed as well as foramenotomies to decompress the nerve roots both above and below the pedicle to be resected. In adequate foramenotomies may lead to impingement of the nerve roots during osteotomy closure and post-operative neuropraxia, particularly at C5.

Once the patient is intubated base line motor and sensory evoked potential monitoring is obtained. The head is then secured in Mayfield cranial fixation and the patient is positioned prone on chest rolls. Lateral C-arm fluoroscopy is brought into the field and closed reduction of the deformity is attempted with x-ray guidance. Post-positioning potentials are obtained and any deviations from the baseline values are addressed and the head is then secured in place.

The posterior elements of the cervical spine are then exposed in routine fashion and plans are made to place segmental instrumentation two levels above and two levels below the C4 apex of the kyphosis. Using anatomic landmarks the C2 pedicle screws are placed and the holes for the lateral mass screws at C3, C5 and C6 are made and tapped but the lateral mass screws are not yet placed. A wide cervical laminectomy extending from C3 to C5 (one level above and below the apex of the kyphosis) is then performed with a round cutting burr on a high speed drill and the cervical lamina are removed en-block. The facet joints at the adjacent levels are also decoricated with the drill in attempts to free the adjacent segments to obtain optimal correction.

Once the spinal cord is decompressed the C4 lateral mass is removed bilaterally with a round cutting burr. While removing the lateral mass of C4 portions of the lateral masses of C3 and C5 are also removed to help define and decompress the exiting C4 and C5 nerve roots using a technique similar to that described by Vallo Benjamin.¹⁹ Decompression of the exiting roots is an important step to prevent unwanted injury during reduction of the PSO. Prior to closing the PSO, all neural elements must be free of compression.

While drilling out the nerve roots and lateral masses care is paid to the locations of the cortical and cancellous bone. The cortical bone covering the nerve roots and vertebral arteries is revealed by carefully drilling away the cancellous bone and the cancellous bone is followed into the pedicle as it joins the superomedial portion of the lateral mass. Fluoroscopy may also be used to determine the trajectories and borders of the pedicles. Once the pedicle is identified by hollowing the lateral mass with the drill the remaining thin layer of cortical bone is removed with small up-going curettes and Kerrison rongeurs are used expose the length of the vertebral artery as it passes through the foramen transversarium of the lateral mass. It is important to completely free the vertebral artery any source of compression prior to osteotomy closure.

Now a small hand drill is used to create a path through the C4 pedicle into the vertebral body using lateral fluoroscopic guidance. This hole is then enlarged with taps included in the set for lateral mass instrumentation, a technique similar to that described by Deviren et al.⁵ We were able to safely enlarge the pedicle tract by sequentially use of larger taps. Use of the taps permitted resection of the pedicle and vertebral body without the need to make multiple passes with instruments around the spinal cord and nerves, hopefully decreasing the risk of iatrogenic injury. Then small straight and down-going curettes as well as micro-pituitaries are used to further hollow out the pedicle and upper portion of the vertebral body using x-ray guidance. The posterior wall of the vertebral body is then resected into the cavity created in the vertebral body using downward angled curettes and the cortical bone fragments are then removed with pituitaries. Next, probably the most difficult aspect of the procedure was removal of the lateral wall of the vertebral body. The vertebral artery is then separated from the lateral wall of the pedicle and the lateral cortical margin of the pedicle and vertebral body is removed with small Kerrison rongeurs and pituitaries.

With the bone work complete, the lateral mass screws are placed into the prepared holes and plans are made to close the PSO. The bracket securing the Mayfield head holder to the bed is loosened and a

gentle lordotic force is applied to the spine. At the same time downward force is applied to the remaining lateral masses at C3 and C5 bilaterally. In this fashion the anterior margin of the C4 vertebral body is fractured and the PSO is closed using x-ray guidance. The Mayfield head holder is once again secured to the bed and rods are then secured to the screw heads to maintain the correction. During this procedure the vertebral artery did not significantly restrict access to the C4 pedicle, and it was not kinked, injured, or obstructed by the posterior reduction. While closing the osteotomy attention must be paid to the vertebral artery and neural elements to ensure they are not compressed and continuous neuromonitoring is used to detect potential problems during osteotomy closure.

No rods were used to stabilize the spine during reduction. First, due to the small working area, any instrumentation present during osteotomy closure would have obstructed our view of the nerves and vertebral artery. Second, unlike the lumbar and thoracic spine we had control over the translation forces by use of the Mayfield head holder. In retrospect, however, better correction might have been obtained if pedicle screws were placed in the lower cervical spine or if the instrumentation was extended into the thoracic region. The addition of pedicle screws would have permitted use of larger compressive forces along the rod to increase lordosis. However we were able to perform almost 40 degrees of correction with gentle lordotic force via manual manipulation with the Mayfield and manual force on the adjacent facet joints.

Next lateral mass screws were placed in the prepared holes in routine fashion followed by rods and a posterolateral fusion is performed. Once the PSO was closed, any evidence of the bone work in the vertebral body was difficult to detect on x-ray and the paths through the pedicles into the vertebral bodies could no longer be palpated with ball tip probes. Prior to wound closure the course of the C4 and C5 nerve roots was inspected as was the thecal sac to ensure to they were free from compression. Interestingly the vertebral artery was under less tension and displayed more redundancy once the spine was in a lordotic position. Neuromonitoring potentials remained

at base line through out the procedure and no intra-operative complications were noted. See Figure 1 for an illustration of PSO.

Conclusion

Tethering of the vertebral artery in the foramen transversarium and the intimate relationship of the vertebral artery to the pedicle in the upper cervical spine present a unique challenge when performing a pedicle reduction osteotomy. With careful resection of the lateral mass and decompression of the vertebral artery by removal of the posterior margin of the foramen transversarium the upper cervical pedicles can be accessed and a PSO can be performed. The vertebral arteries were not obstructed or kinked with posterior reduction of the PSO in this case. A closing wedge PSO is a useful tool for correcting fixed kyphotic deformities in the upper cervical spine.

References

1. Han K, Lu C, Li J, et al. Surgical treatment of

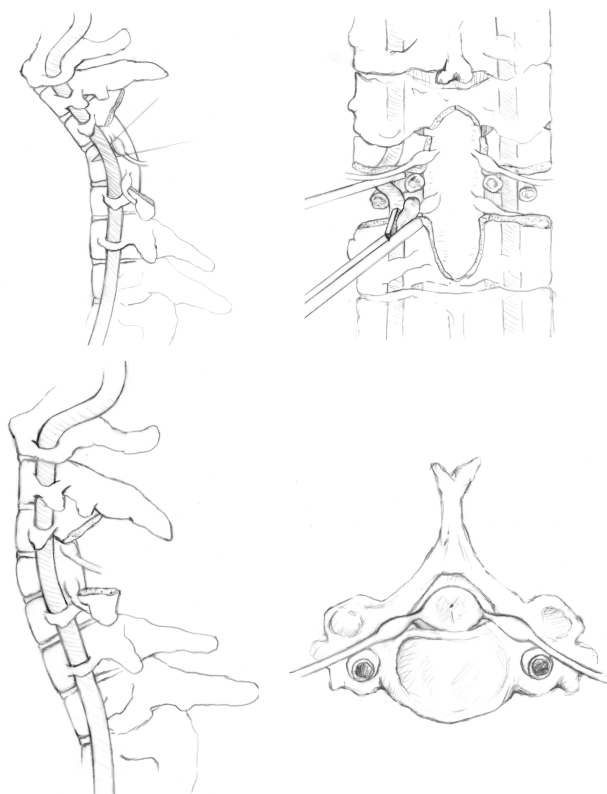


Fig. 1. Illustration of cervical posterior subtraction osteotomy (SPO).

2. Mummaneni PV, Dhall SS, Rodts GE, Haid RW. Circumferential fusion for cervical kyphotic deformity. *J Neurosurg Spine*. 2008;9:515-21.
3. Nottmeier EW, Deen HG, Patel N, Birch B. Cervical kyphotic deformity correction using 360-degree reconstruction. *J Spinal Disord Tech*. 2009;22:385-91.
4. Sin AH, Acharya R, Smith DR, Nanda A. Adopting 540-degree fusion to correct cervical kyphosis. *Surg Neurol*. 2004;61:515-22; discussion 22.
5. Deviren V, Scheer JK, Ames CP. Technique of cervicothoracic junction pedicle subtraction osteotomy for cervical sagittal imbalance: report of 11 cases. *J Neurosurg Spine*. 15:174-81.
6. Smith-Peterson MN LC, Aufranc OE. Osteotomy of the Spine for Correction of flexion Deformity in Rheumatoid Arthritis. *J Bone Joint Surg Am*. 1945;27:1-11.
7. Thomasen E. Vertebral osteotomy for correction of kyphosis in ankylosing spondylitis. *Clin Orthop Relat Res*. 1985:142-52.
8. Cho KJ, Bridwell KH, Lenke LG, Berra A, Baldus C. Comparison of Smith-Petersen versus pedicle subtraction osteotomy for the correction of fixed sagittal imbalance. *Spine (Phila Pa 1976)*. 2005;30:2030-7; discussion 8.
9. Gill JB, Levin A, Burd T, Longley M. Corrective osteotomies in spine surgery. *J Bone Joint Surg Am*. 2008;90:2509-20.
10. Suk SI, Kim JH, Lee SM, Chung ER, Lee JH. Anterior-posterior surgery versus posterior closing wedge osteotomy in posttraumatic kyphosis with neurologic compromised osteoporotic fracture. *Spine (Phila Pa 1976)*. 2003;28:2170-5.
11. Urist MR. Osteotomy of the cervical spine; report of a case of ankylosing rheumatoid spondylitis. *J Bone Joint Surg Am*. 1958;40-A:833-43.
12. Law WA. Osteotomy of the cervical spine. *J Bone Joint Surg Br*. 1959;41-B:640-1.
13. McMaster MJ. Osteotomy of the cervical spine in ankylosing spondylitis. *J Bone Joint Surg Br*. 1997;79:197-203.
14. Belanger TA, Milam RA, Roh JS, Bohlman HH. Cervicothoracic extension osteotomy for chin-on-chest deformity in ankylosing spondylitis. *J Bone Joint Surg Am*. 2005;87:1732-8.

15. Simmons ED, DiStefano RJ, Zheng Y, Simmons EH. Thirty-six years experience of cervical extension osteotomy in ankylosing spondylitis: techniques and outcomes. *Spine (Phila Pa 1976)*. 2006;31:3006-12.
16. Tokala DP, Lam KS, Freeman BJ, Webb JK. C7 decancellation closing wedge osteotomy for the correction of fixed cervico-thoracic kyphosis. *Eur Spine J*. 2007;16:1471-8.
17. Simmons EH. The surgical correction of flexion deformity of the cervical spine in ankylosing spondylitis. *Clin Orthop Relat Res*. 1972;86:132-43.
18. Mummaneni PV, Mummaneni VP, Haid RW, Jr., Rodts GE, Jr., Sasso RC. Cervical osteotomy for the correction of chin-on-chest deformity in ankylosing spondylitis. Technical note. *Neurosurg Focus*. 2003;14:e9.
19. Russell SM, Benjamin V. Posterior surgical approach to the cervical neural foramen for intervertebral disc disease. *Neurosurgery*. 2004;54:662-5; discussion 5-6.

Disclosures

Carl B Paulino has been paid to speak for DePuy Spine, Inc. All other authors declare no relevant disclosures.

Corresponding Author

Qais Naziri, MD, SUNY Downstate Medical Center, Department of Orthopaedic Surgery, 450 Clarkson Avenue, MSC 30, Brooklyn, NY 11203. qnaziri@gmail.com.

Published 27 October 2015.

This manuscript is generously published free of charge by ISASS, the International Society for the Advancement of Spine Surgery. Copyright © 2015 ISASS. To see more or order reprints or permissions, see <http://ijssurgery.com>.