

## Thoracic epidural spinal angiolipoma with coexisting lumbar spinal stenosis: Case report and review of the literature

Mario Benvenuti-Regato, Rafael De la Garza-Ramos and Enrique Caro-Osorio

*Int J Spine Surg* 2015, 9 ()  
doi: <https://doi.org/10.14444/2067>  
<http://ijssurgery.com/content/9/67>

This information is current as of April 19, 2024.

---

**Email Alerts** Receive free email-alerts when new articles cite this article. Sign up at:  
<http://ijssurgery.com/alerts>

# Thoracic epidural spinal angioliopoma with coexisting lumbar spinal stenosis: Case report and review of the literature

Mario Benvenuti-Regato, MD,<sup>1,2</sup> Rafael De la Garza-Ramos, MD,<sup>1,2</sup> Enrique Caro-Osorio, MD<sup>1,2</sup>

<sup>1</sup>Tecnológico de Monterrey, School of Medicine and Health Sciences, Monterrey, México <sup>2</sup>Neurology and Neurosurgery Institute, Centro Médico Hospital Zambrano Hellion, TecSalud, Monterrey, México

## Abstract

### Background

Spinal angioliopomas (SALs) are uncommon benign lesions that may present insidiously with back pain or acutely with weakness due to tumor bleeding/thrombosis. Given their rarity, these lesions are often overlooked in the differential diagnosis of epidural masses. The purpose of this article is to report the case of an epidural SAL and to conduct a literature review on the topic.

### Methods

A case report and review of the literature using the PubMed/Medline databases. All case reports and case series were reviewed up to June 2015.

### Results

A 65-year old female presented with neurogenic claudication and magnetic resonance imaging (MRI) revealed lumbar spinal stenosis. Following decompressive surgery, she experienced symptom resolution, but three months postoperatively she presented to the emergency department with acute paraparesis. A thoracic MRI revealed a lesion located between T8 and T10 causing severe spinal cord compression. Following emergent laminectomy and en bloc resection, the patient regained function and the lesion was diagnosed as SAL. Our literature review revealed 178 reported cases, with a female and thoracic predominance. The majority of patients underwent surgical treatment, achieving a gross total resection in most cases. Similarly, complete symptom resolution was the most common outcome.

### Conclusion

Spinal angioliopomas are uncommon spinal tumors. However, they may be treated as any other space-occupying lesion, and surgical resection allows for complete symptom recovery in most patients.

KEYWORDS: SPINAL ANGIOLIOPOMA, EPIDURAL SPINAL ANGIOLIOPOMA, SPINAL TUMOR, SPINE SURGERY

VOLUME 9 ARTICLE 67 DOI: 10.14444/2067

## Introduction

Spinal angioliopomas (SAL) are uncommon benign tumors composed of mature adipocytes and abnormal blood vessels. They comprise approximately 1.2% of all spinal axis tumors, and 3% of all spinal epidural neoplasms.<sup>1</sup> Given their rarity, these lesions are often overlooked in the differential diagnosis of space-occupying lesions within the spinal canal. Though they most commonly have an insidious course, in some cases the initial manifestation is acute paraplegia.<sup>2-6</sup>

Nonetheless, piecemeal excision is achieved in most of these cases, and spinal cord decompression leads

to symptom recovery in the majority of patients.<sup>1</sup>

Thus, the purpose of this article is to report on a case of epidural SAL with co-existing lumbar spinal stenosis and to conduct a literature review on the topic.

## Case Report

A 65-year old female with body mass index of 29 kg/m<sup>2</sup> presented with a 6-week history of lower extremity dysesthesia and neurogenic claudication. On physical examination, she had a positive straight leg test at 30 degrees, and reflexes were diminished in both lower extremities; she was neurologically intact.

Magnetic resonance imaging (MRI) revealed significant lumbar spinal stenosis at L4/L5 and L5/S1 (Fig-

ure 1). Following failure of conservative therapy, she underwent an uneventful L4-S1 bilateral laminoforaminotomy.

The patient experienced significant relief of her symptoms, but three months later she presented to the emergency department with acute onset of severe back pain and history of recent fall due to leg weakness. On physical examination she was hyper-reflexic on both lower extremities, and her lower extremity strength was 3/5. A new MRI revealed a space-occupying lesion in the epidural space, causing significant compression on the spinal cord at the levels of T8 – T10 (Figure 2). Additionally, the lesion extended through the intervertebral foramen at T9/T10. The patient underwent an emergent posterior laminectomy and en bloc resection of a soft, reddish-

brown tumor (Figure 3), followed by instrumentation from T7 – T11. Following surgery, histopathological analysis was consistent with angiolipoma (Figure 4). Although the tumor extended through an intervertebral foramen, pathological analysis of surrounding soft tissues revealed no infiltration. The patient underwent an uneventful recovery, and is symptom-free and without evidence of tumor recurrence 6 months after surgery.

## Literature Review

A digital search of the PubMed/Medline databases was performed using the algorithm [“(spine” OR “spinal”) AND “angiolipoma”] up to June 2015. Article titles and abstracts were then individually screened to identify potential articles of interest, and

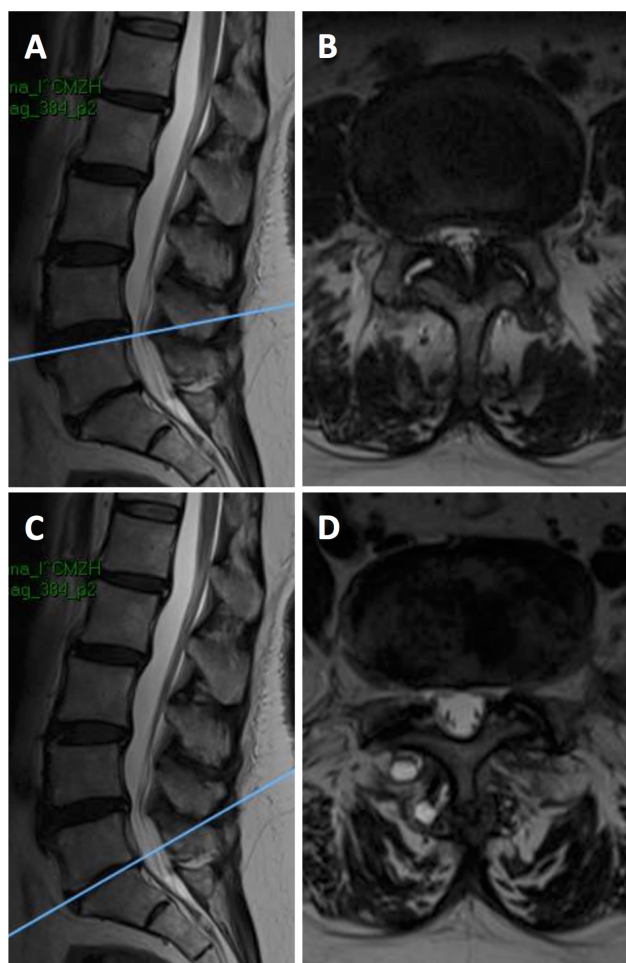


Fig. 1. Magnetic resonance image showing lumbar spinal stenosis. Sagittal (A) and axial (B) T2-weighted images showing lumbar spinal stenosis at L4/L5 secondary to ligamentum flavum hypertrophy and bilateral facet arthropathy. Sagittal (C) and axial (D) T2-weighted images showing foraminal stenosis on the left secondary to facet arthropathy at L5/S1.

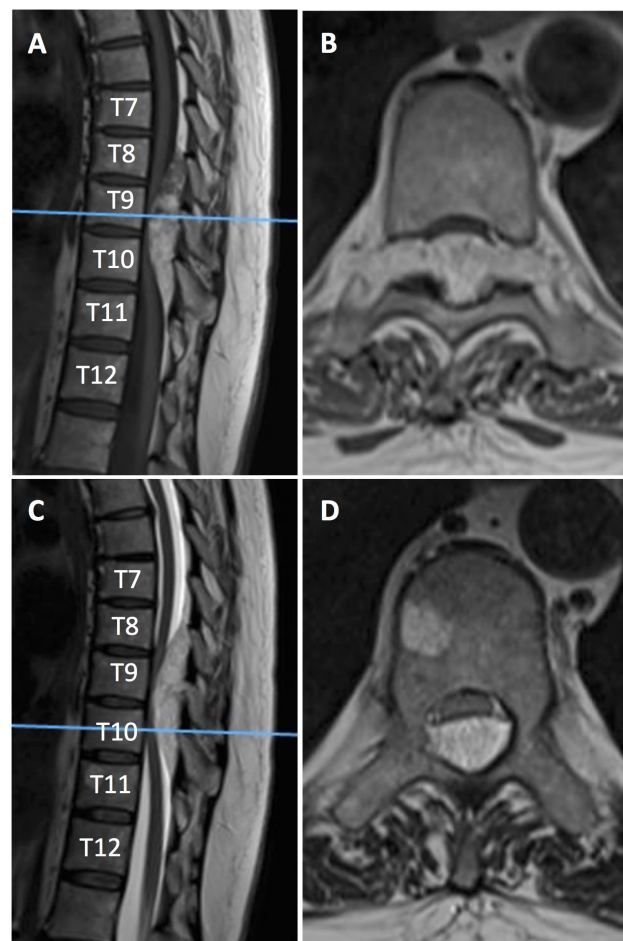


Fig. 2. Magnetic resonance image showing an epidural lesion extending from T8 – T10. Sagittal (A) and axial (B) T1-weighted images showing the dumbbell-shaped hyperintense lesion extending multiple levels and through the foramen at T9/T10. Additionally, the lesion shows hypointense regions, corresponding to the vascular component of the tumor. Sagittal (C) and axial (D) T2-weighted images showing severe spinal stenosis with spinal cord compression.



selected manuscripts were recorded in a digital database. Article references were also utilized to identify other case reports/case series to reduce publication bias.

A total of 107 articles reporting on 177 patients (108 articles and 178 patients with the present case) with epidural SALs were identified (Table 1).<sup>1-107</sup> The average age for all patients (including the present case)

was  $46 \pm 16$  years, with a range of 17 months to 85 years. From the total group, 105 (59%) patients were female. The most common presenting symptom was paraparesis in 54 (30.3%) patients, followed by thoracic/low back pain in 43 (24.2%) patients. The range of time with symptoms before presentation was from a few minutes (acute onset) to 30 years in one patient.<sup>105</sup>

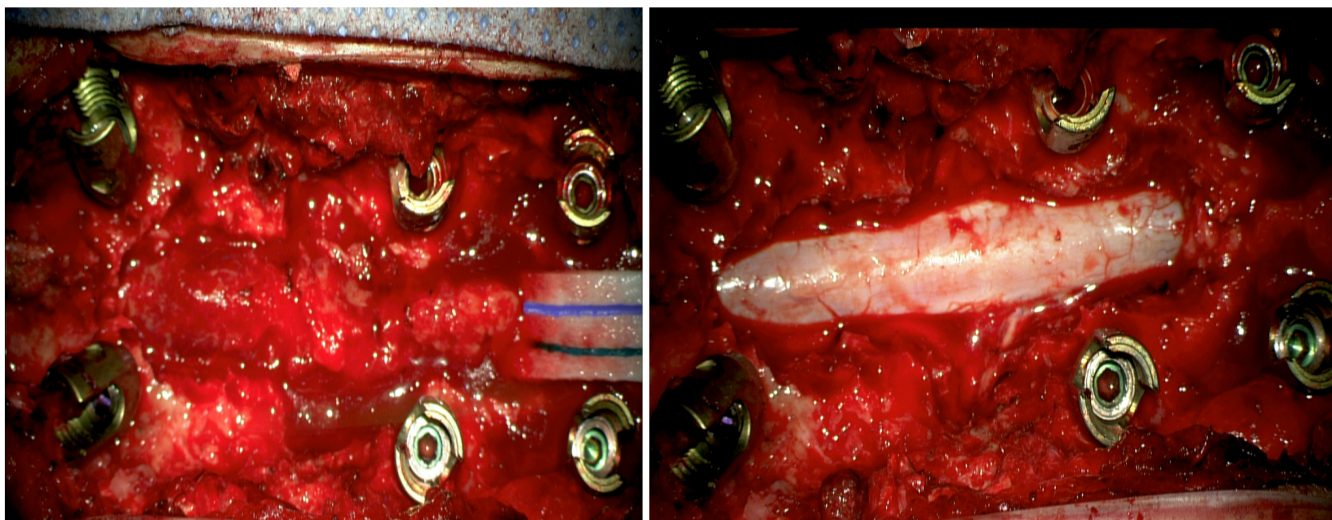


Fig. 3. Intraoperative photographs showing a reddish-brown lesion overlying the thecal sac (Left) which was removed en bloc following laminectomy (Right).

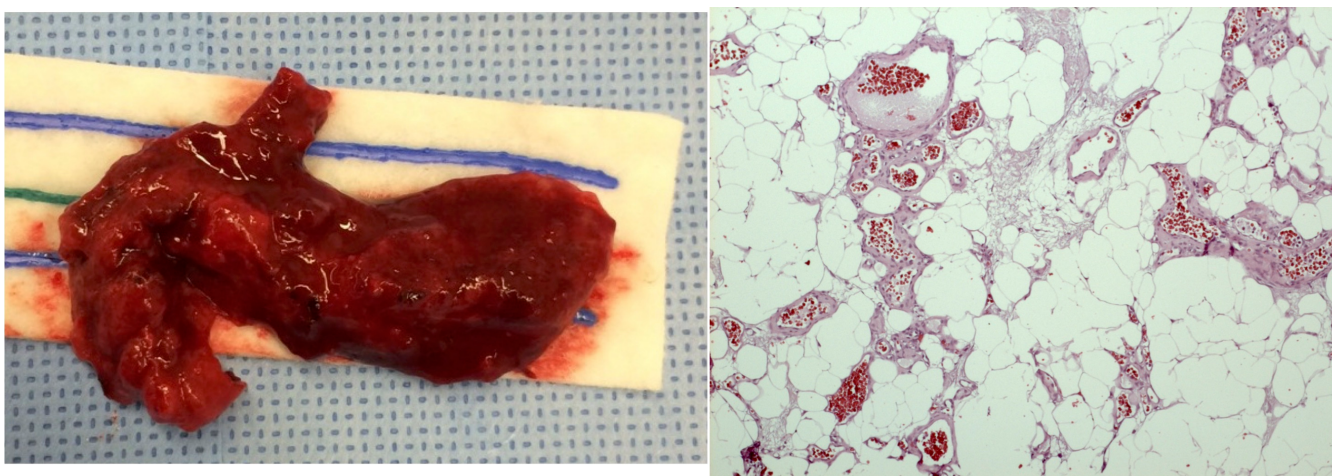


Fig. 4. Tumor specimen consisting of a soft, reddish-brown mass (Left). Histological slide showing mature adipocytes and blood vessels of various sizes, some filled with thrombin (Right).



Table 1. Review of published cases on epidural spinal angioliopoma.

Author	Year	Age, sex	First symptom	Level	Axial location	Infiltrating	Treatment	Outcome
Berenbruch	1890	16/M	Paraparesis	Thoracic	Not available	N	Surgery	
Liebscher	1901	51/F	Numbness	T7-T8	Anterior	N	No surgery	
Frazier and Allen	1918	55/F		Thoracic	Unknown	N	Unknown	Unknown
Balado and Morea	1928	20/F	Paraparesis	Midthoracic	Unknown	N	No surgery	
Kasper and Cowan	1929	6/M	Bleeding to lumbar puncture	C2-T1 and L3-S3	Unknown	N	No surgery	
Petit-Dutaillis and Christoph	1931	43/F	Paraplegia	T6-T10	Unknown	N	Surgery	Recovery
Ehni and Love	1945	30/F	Paraplegia	T6-T8	Posterior	N	Surgery	Recovery
Ehni and Love	1945	67/M	Paraparesis	T8-T9	Posterior	N	Surgery	Recovery
Bucy and Ritchey	1947	33/M	Paraparesis	C6-T5	Posterolateral	N	Surgery + RT	Improved
Taylor et al.	1951	51/F	Paraparesis	T3-T6	Posterior	N	Surgery	Improved
Taylor et al.	1951	44/F	Paraparesis	T10-L1	Posterior	Y	Surgery	Improved
Moscattelli and Merigliano	1958	51/M		T4-T7	Posterior	N	Unknown	Unknown
Maier	1962	1.5/F	Paraparesis	T7	Anterior	Y	Surgery	Recovery
Gonzalez-Crusi et al.	1966	20/F	LBP	L1-L4	Anterior	Y	Surgery + RT	Recovery
Gagliardi and Gambacorta	1968	30/M	Paraparesis	T3-T4	Posterior	N	Unknown	Unknown
Lo Re and Michelacci	1969	16/M	Congenital	Cauda	Posterior	N	Surgery	Recovery
Lo Re and Michelacci	1969	35/F		Lumbar	Posterior	N	Surgery	Recovery
Warot and Petit	1969	57/F	Paraparesis	T4-T6	Posterior	N	Unknown	Unknown
Pearson et al.	1970	17/F	Back pain	T2-T5	Anterior	Y	Surgery	Improved
Pearson et al.	1970	22/M	Back pain	T3-T9	Anterior	Y	Surgery	Improved
Pearson et al.	1970	44/F	Numbness	T7-T10	Posterior	N	Surgery	Recovery
Henry et al.	1971	63/M	Paraparesis	Cervicothoracic	Posterior	N	No surgery	Death due to other causes
Giuffrè	1971	36/F		T4-T8	Unknown	N	Unknown	Unknown
Bender et al.	1974	50/F	Paraparesis	T6-T8	Posterior	N	Surgery	Recovery and late recurrence

Bender et al.	1974	58/M	Paraparesis	T7-T10	Posterior	N	Surgery	Improved
Scanarini and Carteri	1974	57/F	Paraplegia	T7	Posterior	N	Surgery	Recovery
Obrador et al.	1977	43/F	Leg pain	T7-T9	Posterior	N	Surgery	Recovery
Occhiogrosso & Vailati	1977	34/F	Numbness	T6-T8	Posterior	N	Surgery	Recovery
Cull et al.	1978	50/F	Paraparesis	T8-T9	Posterior	N	Surgery	Recovery
Cull et al.	1978	45/F	Paraparesis	T6-T8	Posterior	N	Surgery	Improved
Shuangshoti and Hongsagrabhas	1979	45/M		T10-T11	Posterior	N	Surgery	Recovery
Schiffer et al.	1980	48/F	Numbness	T10-L1	Anterior	Y	Surgery	Recovery
Goyal	1980	67/F	Paraparesis		Posterolateral	N	Surgery	Dead
Miki et al.	1981	46/F	Numbness	T3-T5	Posterior	N	Surgery	Recovery
Padovani et al.	1982	50/M	Paraparesis	T4-T6	Posterolateral	N	Surgery	Recovery
Padovani et al.	1982	52/M	Paraparesis	T4-T6	Posterior	Y	Surgery	Improved
Hanakita and Koyama	1982	42/M	Gait disturbance	T4-T5	Posterior	N	Surgery	Recovery
Pasquier et al.	1984	48/F		T8-T10	Posterior	N	Surgery	Improved
Butti et al.	1984	44/M	Paresthesia right arm	C6-C7	Posterior	N	Surgery	Recovery
Butti et al.	1984	50/F	Numbness in legs	L4-L5	Posterior	N	Surgery	Recovery
Bardosi et al.	1985	46/M	LBP	T11-L2	Posterior	N	Surgery	Recovery
Von Hanwehr et al.	1985	35/M	Numbness of right foot	T6	Anterior	Y	Surgery	Recovery
Haddad et al.	1986	34/M	Numbness of legs	T5-T6	Posterior	Y	Surgery	Improved
Haddad et al.	1986	22/M	Back pain	T7-T8	Posterior	N	Surgery	Recovery
Griebel et al.	1986	53/F	Paraparesis	T5-T6	Posterior	N	Surgery	Recovery
Nishiura et al.	1986	42/M	Numbness in legs	T3-T6	Posterior	N	Surgery	Improved
Nishiura et al.	1986	24/M	LBP	L5-S1	Anterolateral	N	Surgery	Recovery
Nishiura et al.	1986	45/M	Numbness in legs	T3-T6	Posterior	N	Surgery	Improved
Matsushima et al.	1987	41/F	Paraparesis	T9-T10	Posterior	N	Surgery	Recovery
Rivkind et al.	1986	52/M	Paraparesis	T7	Anterolateral	N	Surgery	Recovery

Poon et al.	1988	65/F	Back pain	T8-T9	Posterior	N	Surgery	Recovery
Parizel	1989	37/F		T4-T8	Unknown	N	Surgery	
Anson et al.	1990	58/F	Back pain	T2-T6	Posterolateral	N	Surgery + RT	Recovery
Anson et al.	1990	65/F	Paraparesis	T1-T8	Posterior	N	Surgery	Unchanged
Kuroda et al.	1990	73/F	Numbness in left leg	T4	Posterior	Y	Surgery	Improved
Weill et al.	1991	46/F	Paraparesis	T7-T10	Posterior	N	Surgery	Recovery
Mascalchi et al.	1991	42/F	Numbness of left toe	T5-T6	Posterior	N	Surgery	Recovery
Rubin et al.	1992	58/M	Paraparesis	T8-T10	Posterior	N	Surgery	Improved
Stranjalis et al.	1992	68/F	Paraparesis	T5-T6	Posterior	Y	Surgery	Improved
Pagni and Canavero	1992	56/F	LBP	L3	Anterior	N	Surgery	Recovery
Pagni and Canavero	1992	59/F	LBP	L4-L5	Anterior	N	Surgery	Recovery
Mimata	1992	60/M		T5-T8	Unknown	N	Surgery	Recovery
Yamashita et al.	1993	57/M	Gait disturbance	T3-T9	Posterior	N	Surgery	Recovery
Shibata	1993	38/F	Paraparesis	T4-T6	Unknown	N	Surgery	Recovery
Preul et al.	1993	45/F	Numbness in legs	T7-T11	Posterior	N	Surgery	Recovery
Preul et al.	1993	58/M	Back pain	T3	Posterior	Y	Surgery	Unchanged
Michilli et al.	1993	12/M	LBP	T5-T10	Posterior	N	Surgery	Recovery
Sakaki et al.	1993	67/M	Leg pain	T12-L1	Lateral	N	Surgery	Recovery
Fernandez et al.	1994	14/F	Paraplegia	T5	Posterior	N	Surgery	Improved
Fernandez et al.	1994	28/M	Paraplegia	C7-T4	Posterior	N	Surgery	Unchanged
Turanzas et al.	1994	25/M	Paraparesis	T6-T8	Anterior	Y	Surgery	Improved
Balbo	1995	41/M	Paraparesis	T6-T7	Posterior	N	Surgery	Recovery
Bouramas	1995	27/F	Numbness in legs	T2-T8	Posterior	N	Surgery	Recovery
O'Donovan	1996	54/M	Back pain	T3-T9	Posterior	N	Surgery	Recovery
Trabulo et al.	1996	26/F	Back pain	T2-T9	Posterior	N	Surgery	Recovery
Trabulo et al.	1996	72/M	Paraparesis	T6	Posterior	Y	Surgery	Recovery



Provenzale & McLendon	1996	38/F	LBP	Lumbar	Posterior	N	Surgery	Unknown
Provenzale & McLendon	1996	61/F	Paraparesis	Thoracic (2 tumors)	Posterior	N	Surgery	Unknown
Provenzale & McLendon	1996	42/F	Back pain	Thoracic	Posterior	N	Surgery	Unknown
Krishnan et al.	1996	55/F	Paraparesis	T6-T9	Posterior	N	Surgery	Recovery
Boockvar et al.	1997	34/F	Back pain	T3-T9	Posterior	N	Surgery	Recovery
Shuangshoti & Lerdlum	1997	21/M	Paraparesis	T1-T2	Posterior	N	Surgery	Recovery
Sakaida	1998	72/M	Numbness in legs	T3-T5	Anterior	Y	Surgery	Recovery
Labram et al.	1999	40/F	Back pain	C6-T3	Posterolateral	N	Surgery	Recovery
Labram et al.	1999	68/F	Back pain	T5-T10	Posterior	N	Surgery	Recovery
Labram et al.	1999	17/M	Back pain	C5-T3	Circumferential	N	Surgery	Recovery
Turgut	1999	54/F	Paraparesis	T4-T9	Posterior	N	Surgery	Recovery
Kujas	1999	67/F	Paraparesis	T6	Anterior	N	Surgery	Worsened
Oge et al.	1999	72/M	Paraparesis	T2-T5	Posterior	N	Surgery	Recovery
El Abbadi	1999	38	Paraparesis	T10-T11	Posterior	N	Surgery	Recovery
Bailey et al.	2000	44/F	Numbness in legs	T3-T8	Posterior	N	Surgery	Recovery
Al-Anazi et al.	2000	38/F	Numbness of both legs	T5-T9	Posterior	N	Surgery	Recovery
Andaluz et al.	2000	24/F	Paraparesis	T7-T10	Posterior	N	Surgery + embolization	Recovery
Andaluz et al.	2000	39/F	Numbness in legs	T6-T8	Posterior	N	Surgery	Recovery
Andaluz et al.	2000	59/F	Paraparesis	T4-T6	Posterior	N	Surgery	Recovery
Andaluz et al.	2000	69/M	Paraparesis	T3-T4	Posterior	N	Surgery	Recovery
Akhaddar et al.	2000	47/F	Numbness in legs	T4-T6	Posterior	N	Surgery	Recovery
Akhaddar et al.	2000	46/F	Paraparesis	T7-T9	Posterior	N	Surgery	Recovery
Akhaddar et al.	2000	38/F	Numbness in legs	T3-T5	Posterior	N	Surgery	Recovery
Akhaddar et al.	2000	46/F	Paraparesis	T3-T4	Posterior	N	Surgery	Recovery
Akhaddar et al.	2000	12/F	Paraparesis	T7-T8	Posterior	N	Surgery	Improved
Akhaddar et al.	2000	64/F	Leg pain	T2-T4	Posterolateral	N	Surgery	Recovery

Akhaddar et al.	2000	58/M	Numbness in legs	T3-T6	Posterior	N	Surgery	Recovery
Akhaddar et al.	2000	47/M	Back pain	T3-T6	Posterior	N	Surgery	Improved
Amlashi et al.	2001	36/F	LBP	T2-T6	Posterior	N	Surgery	Improved
Fourney et al.	2001	46/F	Numbness in legs	T6-T8	Posterior	N	Surgery	Recovery
Garg et al.	2002	12/F	Paraparesis	T1-T11	Posterolateral	N	Surgery	Improved
Gelabert et al.	2002	4/M	Paraparesis	T2-T5	Posterior	N	Surgery	Recovery
Pinto et al.	2002	85/M	Leg pain	L1-L2	Posterior	N	Surgery	Improved
Samdani et al.	2004	49/F	LBP	T6-T8	Posterior	N	Surgery	Recovery
Aversa do Souto et al.	2003	46/F	LBP	L4-L5	Anterior	N	Surgery	Recovery
Rocchi et al.	2004	60/M	Leg pain	L3-L4	Anterior	N	Surgery	Recovery
Rocchi et al.	2004	54/F	Leg pain	L3	Anterior	N	Surgery	Recovery
Rabin et al.	2004	47/M	Numbness in legs	T9	Anterior	Y	Embolization + Surgery	Recovery
Petrella et al.	2005	16/M	LBP	T4-T8	Posterior	N	Surgery	Recovery
Cubillos et al.	2005	40/F	Numbness in legs	T4-T7	Posterior	N	Surgery	Recovery
Konya et al.	2006	60/F	LBP	L5	Posterolateral	N	Surgery	Recovery
Dogan et al.	2006	50/F	Leg pain	L4-L5	Posterior	N	Surgery	Recovery
Dogan et al.	2006	36/M	LBP	L2	Posterior	N	Surgery	Recovery
Raghavendra et al	2007	14/F	Subarachnoid hemorrhage and acute back pain	T1-T9	Posterior	N	No surgery	Unchanged
Guzey et al.	2007	41/F	LBP and leg pain	L2-L3	Posterolateral	Y	Surgery	Recovery
Akhaddar et al.	2008	47/M	Paraparesis	T2-T3	Posterior	N	Surgery	Recovery
Nanassis et al.	2008	47/F	LBP and leg pain	L2-L3	Posterior	N	Surgery	Recovery
Farooq et al.	2008	57/F	LBP and numbness in legs	T5-T8	Posterior	N	Surgery	Recovery
Yen et al.	2008	71/M	Back pain and progressive paraparesis	T5-T6	Posterior	Y	Surgery	Recovery
Hungs et al.	2008	52/F	Back pain and leg pain	T2-T5	Posterior	N	Surgery	Recovery
Park et al.	2008	74/M	LBP	L5-S1	Lateral	N	Surgery	Recovery
Gelabert-Gonzalez et al.	2009	16/M	LBP	L5-S1	Posterior	N	Surgery	Recovery

Gelabert-Gonzalez et al.	2009	45/F	Paraparesis and numbness	L5-S1	Posterior	N	Surgery	Improved
Dufrenot et al.	2010	44/F					Surgery	Recovery
Sankaran et al.	2010	77/M	Post-traumatic bleeding and acute paraparesis	T8-T10	Posterior	N	Surgery	Recovery
Haji et al.	2011	65/F	Numbness in legs	T5-T7	Posterior	N	Surgery	Improved
Diyora et al.	2011	20/M	Back pain and paraparesis	T5-T8	Posterior	N	Surgery	Recovery
Tsutsumi et al.	2011	31/F	Paraplegia	T3-T4	Posterolateral	N	Surgery	Recovery
Chotai et al.	2011	68/M	Back pain and numbness in legs	T9-T11	Posterior	N	Surgery	Recovery
Han et al.	2012	58/M	Leg dysesthesia and paraparesis	T4-T5	Posterolateral	Y	Surgery	Recovery
Ghanta et al.	2012	56/M	Leg numbness and gait disturbance	T4-T5	Posterior	N	Surgery	Improved
Fujiwara et al.	2013	64/F	Leg dysesthesia	T5-T8	Posterior	N	Surgery	Recovery
Fujiwara et al.	2013	65/M	Leg dysesthesia and gait disturbance	T5-T7	Posterior	N	Surgery	Recovery
Reyes et al.	2013	68/M	LBP	T10-L1	Posterior	N	Surgery	Recovery
Si et al.	2014	50/M	NR	L3-L4	Posterior	N	Surgery	
Si et al.	2014	53/M	NR	T4-T7	Posterior	N	Surgery	Improved
Si et al.	2014	58/M	NR	T9-T10	Posterior	N	Surgery	Recovery
Si et al.	2014	41/F	NR	T5-T6	Posterior	N	Surgery	
Si et al.	2014	19/F	NR	C3-C6	Posterior	N	Surgery	
Si et al.	2014	26/F	NR	C4-C6	Posterolateral	N	Surgery	
Si et al.	2014	63/F	NR	T7-T10	Posterior	N	Surgery	Improved
Si et al.	2014	62/F	NR	T8-T10	Posterior	N	Surgery	Recovery
Si et al.	2014	74/F	NR	L4-L5	Lateral	N	Surgery	Recovery
Si et al.	2014	55/M	NR	T3-T5	Lateral	N	Surgery	Recovery
Si et al.	2014	62/M	NR	L4-L5	Posterior	Y	Surgery	Recovery
Si et al.	2014	61/M	NR	T11-L3	Posterior	Y	Surgery	
Si et al.	2014	43/F	NR	T7-T9	Posterolateral	N	Surgery	Improved
Si et al.	2014	57/M	NR	T5-T8	Posterior	N	Surgery	



Si et al.	2014	69/F	NR	T4-T6	Posterolateral	N	Surgery	Unchanged
Si et al.	2014	62/M	NR	T4-T6	Posterior	N	Surgery	Improved
Si et al.	2014	47/F	NR	T2-T3	Posterior	Y	Surgery	Improved
Si et al.	2014	50/F	NR	T2-T4	Posterolateral	N	Surgery	
Si et al.	2014	37/M	NR	T4-T7	Posterior	N	Surgery	
Si et al.	2014	51/F	NR	T4-T5	Posterior	N	Surgery	
Si et al.	2014	59/F	NR	T8-T11			Surgery	
Ramdasi et al.	2014	58/M	Paraplegia	C7-T1			Surgery	Recovery
Wang et al.	2014	47/F	Paraparesis	T3-T10	Posterior	N	Surgery	Improved
Wang et al.	2014	36/M	Leg pain	L3-S2	Posterior	N	Surgery	Recovery
Wang et al.	2014	46/F	Back pain	T2-T4	Lateral	Y	Surgery	Recovery
Wang et al.	2014	50/M	Back pain	T1-T3	Posterior	N	Surgery	Recovery
Wang et al.	2014	47/F	Numbness in legs	L2-L4	Posterior	N	Surgery	Improved
Wang et al.	2014	46/M	Paraparesis	T11-T12	Posterior	N	Surgery	Recovery
Wang et al.	2014	54/M	Leg pain	L3-L4	Posterolateral	Y	Surgery	Improved
Wang et al.	2014	44/F	Numbness in legs	T8-T11	Posterior	N	Surgery	Recovery
Wang et al.	2014	55/F	Leg pain	L5-S1	Posterior	N	Surgery	Improved
Wang et al.	2014	47/M	LBP	L2-L3	Posterior	N	Surgery	Improved
Wang et al.	2014	49/F	LBP	L2-L3	Posterior	N	Surgery	Recovery
Wang et al.	2014	55/F	Numbness in legs	T6-T8	Posterior	N	Surgery	Improved
da Costa et al.	2014	43/M	Paraplegia	T9-T10	Posterior	N	Surgery	Improved
Nakao et al.	2014	32/F	Leg numbness and paraparesis	T1-T6	Posterior	N	Surgery	Recovery
Nadi et al.	2015	50/F	Back pain and paraparesis	T6-T9	Posterolateral	Y	Surgery	Improved
Present case	2015	65/F	LBP and paraparesis	T8-T10	Posterolateral	N	Surgery	Recovery

M: male; F: female; LBP: low back pain; NR: not reported; N: no; Y: yes; RT: radiotherapy.

The majority of tumors were located in the thoracic spine (131 patients; 73.6%), followed by the lumbosacral spine in 30 patients (16.9%), cervicothoracic and thoraco-lumbar in 6 patients each (6.8% combined) and the cervical spine in only 4 cases (2.3%).<sup>10,35,105</sup> Tumors were most commonly located posteriorly in the axial plane. Based on the classification by Lin & Lin,<sup>108</sup> only 25 (14%) tumors were found to be infiltrating in nature. The majority of patients underwent surgery, and experienced complete symptom recovery. Recurrences were uncommon, and have been reported in only two occasions (1.1%).<sup>23,69</sup>

## Discussion

Angiolipomas are histologically benign tumors that most commonly occur in subcutaneous tissue in the forearms, trunk, neck, and proximal upper extremities.<sup>109</sup> Occurrence within the spinal canal is uncommon, but when it occurs it is most commonly in the epidural space.<sup>1</sup> Histologically, these lesions consist of “mature adipocytes and branching capillary-sized vessels, which usually contain fibrin thrombi.”<sup>109</sup> Some studies have also performed immunohistochemical staining, showing positivity for CD31, Factor XIIIa, and Factor VIII.<sup>84</sup> Some believe SALs originate from pluripotential mesenchymal stem cells,<sup>12</sup> but others argue they most likely represent a “congenital malformation or a benign hamartoma”<sup>71</sup> or that they arise from primitive mesenchyme.<sup>70</sup>

SALs resemble other space-occupying lesions in terms of symptoms, and most patients present with a history of thoracic/low back pain and progressive lower extremity weakness. However, paraparesis or paraplegia may also occur acutely, particularly in the setting of tumor bleeding or thrombosis.<sup>2-6,65,96</sup> A presumed diagnosis can be usually made by MRI, although the ultimate diagnosis is made with biopsy. Lesions typically appear hyperintense on non-contrast T1-weighted images due to their fatty content.<sup>110</sup> Additionally, there may be hypointense regions on T1-weighted images, which represent the vascular component of the tumor. Thus, these regions will be enhancing after contrast administration.<sup>110</sup> Computed tomography scans are less frequently utilized, but may show tumor calcification,<sup>63,73</sup> vertebral body trabeculation,<sup>14,72</sup> and/or ver-

tebral body erosion.<sup>73</sup> Though most SALs are found in the epidural space (as mentioned previously), there have been several reports of intradural (including intramedullary) locations.<sup>111-116</sup>

Historically, SALs have been classified as non-infiltrating and infiltrating,<sup>108</sup> with the latter referring to tumoral infiltration into the vertebral body and/or adjacent soft tissues. In the present review, only 13.4% of tumors were found to be infiltrating in nature. More recently, Si et al. proposed another classification system based on tumor characteristics observed on MRI. This group of authors described three tumor types: Type IA (intraspinous tumor without lipomatosis), Type IB (intraspinous tumor with lipomatosis above and below the tumor) and Type II (dumbbell-shaped tumor).<sup>105</sup> The rationale behind this classification was that Type IB tumors occur more frequently in obese patients and are more challenging from a surgical standpoint owing to the extensive associated epidural lipomatosis.<sup>105</sup> In contrast, Type IA tumors are more easily resectable, and Type II represent the most complex type of tumor that may warrant additional internal fixation.<sup>105</sup>

Treatment of SALs is surgical, which was performed in 168 out of 178 patients (94.4%) in the present review. Additionally, adjuvant radiation therapy was used in three cases (1.7%) due to suspicion of malignancy.<sup>13,17,46</sup> Gross total resection was achieved in most cases, but in a subset of patients (particularly those with infiltrating tumors) only subtotal resection was achieved.<sup>69</sup> Of seven reported cases of intradural/intramedullary SALs, complete excision was only achieved in one,<sup>113</sup> and most patients only experienced partial improvement in symptoms. When examining global outcomes, we found that the majority of patients experience complete symptom resolution, even for patients presenting acutely with paraplegia.

The case described in this article represented a distinctive challenge given the initial presentation with neurogenic claudication and concomitant finding of lumbar spinal stenosis. Additionally, the acute presentation of paraparesis suggested tumoral thrombosis or bleeding, as it has been reported in other cases.<sup>65,96</sup> Fortunately, following decompression and piecemeal excision, the patient was able to regain full

strength postoperatively.

While screening the entire spinal column (with MRI) in cases of suspected lumbar spinal stenosis is not common practice, there may be several indications for cervico-thoracic spine screening. Paraparesis without other signs/symptoms of cauda equina syndrome is rarely due to lumbar stenosis, and may be due to myelopathy and/or other neurological diseases. Patients who present with signs/symptoms of stenosis but with other concomitant findings such as hyperreflexia or spastic gait may require cervico-thoracic spine screening to rule-out spinal cord compression or disease. Lastly, though occurrence of multiple SALs in the same patient has been reported, it is unusual (only 2 cases in the present literature review).<sup>10,63</sup> Each case should be individualized, and a thorough history and physical exam should dictate whether a patient requires cervical, thoracic, and/or lumbar spine imaging.

## Conclusion

SALs are infrequent entities that mimic other space-occupying lesions within the spinal canal. Though not common, they should be included in the differential diagnoses of epidural tumors, given the excellent outcome that may be achieved in most patients.

## References

1. Gelabert-Gonzalez M, Garcia-Allut A. Spinal extradural angioliopoma: report of two cases and review of the literature. *Eur Spine J*. Mar 2009;18(3):324-335.
2. Akhaddar A, Albouzidi A, Elmostarchid B, Gazaz M, Boucetta M. Sudden onset of paraplegia caused by hemorrhagic spinal epidural angioliopoma. A case report. *Eur Spine J*. Sep 2008;17 Suppl 2:S296-298.
3. Raghavendra S, Krishnamoorthy T, Ashalatha R, Kesavadas C. Spinal angioliopoma with acute sub-arachnoid hemorrhage. *J Clin Neurosci*. Oct 2007;14(10):992-994.
4. Ramdasi RV, Avinasha KM, Mahore A, Kawale J. Spinal angioliopoma manifesting with apoplexy. *BMJ Case Rep*. 2014;2014.
5. Tsutsumi S, Nonaka Y, Abe Y, Yasumoto Y, Ito M. Spinal angioliopoma in a pregnant woman presenting with acute epidural hemorrhage. *J Clin Neurosci*. Jun 2011;18(6):849-851.
6. Fernández JJ, Abad RM, Ribas T, et al. Spinal angioliopoma causing acute paraplegia. Report of two cases. *Neurocirugia*. 1994(5):242-245.
7. Barenbruch K. En fall von multiplen angioliopomen kombiniert mit einem angiom des rückenmarks. *Tubingen*. 1890.
8. Liebscher C. Angioliopom des Wirbelkanals mit Kompression des Rückenmarks. *Pag Med Wochenschr*. 1901(26):189-191.
9. Frazier CH, Allen AR. *Surgery of the spine and spinal cord*. Appleton, New York 1918.
10. Kasper JA, Cowan A. Extradural lipoma of the spinal canal. *Arch Pathol (Chic)*. 1929(8):800-802.
11. Petit-Dutaillis D, Christoph J. Spinal cord compression due to a giant extradural angioliopoma: Surgical removal. *Rev Neurol (Paris)*. 1931(2):824-827.
12. Ehni G, Love JG. Intraspinal lipomas: report of cases, review of literature, and clinical and pathological study. *Arch Neurol Psychiatry*. 1945;53:1-28.
13. Bucy PC, Ritchey H. Klippel-Feil's syndrome associated with compression of the spinal cord by an extradural hemangioliopoma. *J Neurosurg*. Sep 1947;4(5):476-481.
14. Taylor J, Harries BJ, Schurr PH. Extrathecal haemangioliopomas of the spinal canal. *Br J Surg*. Jul 1951;39(153):1-7.
15. Moscatelli G, Merigliano D. [Histogenetic and nosographic aspects of extradural lipoma: a case report]. *Riv Neurol*. Nov-Dec 1958;28(6):667-676.
16. Maier HC. Extradural and intrathoracic lipoma causing spinal cord compression. Successful treatment by surgical excision. *JAMA*. Aug 18 1962;181:610-612.
17. Gonzalez-Crussi F, Enneking WF, Aream VM. Infiltrating angioliopoma. *J Bone Joint Surg Am*. Sep 1966;48(6):1111-1124.
18. Gagliardi FM, Gambacorta D. Extradural thoracic angioliopoma. *Gazz Int Med Chir*. 1968(73):5602.
19. Lo Re F, Michelacci M. [Clinical and surgical findings on various lumbo-sacral abnormalities associated with angioliopoma]. *Arch Putti Chir Organi Mov*. 1969;24:70-85.
20. Warot P, Petit H, Christiaens JL, Caron JC,



- Delobelle-Deroide A. [Extra-dural dorsal angioli-poma: unusual case of medullary compression]. *Lille Med.* Mar 1969;14(3):311-315.
21. Pearson J, Stellar S, Feigin I. Angiomyolipoma: long-term cure following radical approach to malignant-appearing benign intraspinal tumor. Report of three cases. *J Neurosurg.* Oct 1970;33(4):466-470.
22. Henry P, Vital C, Vallat JM. Anatomoclinical study of an extradural angioli-poma associated with intramedullary glioblastoma. *Rev Neurol (Paris).* 1971(124):385-391.
23. Bender JL, Van Landingham JH, Manno NJ. Epidural lipoma producing spinal cord compression. Report of two cases. *J Neurosurg.* Jul 1974;41(1):100-103.
24. Scanarini M, Carteri A. Intrarachidian lipomas. Observations on 4 cases and pathogenetic considerations. *J Neurosurg Sci.* Apr-Jun 1974;18(2):136-141.
25. Giuffr  R. Spinal lipomas. In: Vinken AJ, Bryn GN, eds. *Handbook of clinical neurology.* Vol 20. North-Holland, Amsterdam 1976:389-414.
26. Obrador S, Villarejo F, Deblas A. [Extradural angioli-poma: uncommon cause of spinal pressure]. *Rev Clin Esp.* Sep 30 1977;146(6):395-396.
27. Occhiogrosso M, Vailati G. Medullar compression due to epidural angioli-poma: Report of a case. *Acta Neurol (Napoli).* 1977(32):850-853.
28. Cull DJ, Erdohazi M, Symon L. Extradural haemangioli-poma in the spinal canal. Two cases presenting during pregnancy. *Acta Neurochir (Wien).* 1978;45(1-2):187-193.
29. Shuangshoti S, Hongsaprabhas C. Intraspinal epidural angioli-poma. *J Med Assoc Thai.* Aug 1979;62(8):457-460.
30. Goyal RN. Epidural lipoma causing compression of the spinal cord. *Surg Neurol.* Jul 1980;14(1):77-79.
31. Schiffer J, Gilboa Y, Ariazoroff A. Epidural angioli-poma producing compression of the cauda equina. *Neurochirurgia (Stuttg).* May 1980;23(3):117-120.
32. Miki T, Oka M, Shima M, Hirofuji E, Tanaka S. Spinal angioli-poma. A case report. *Acta Neurochir (Wien).* 1981;58(1-2):115-119.
33. Hanakita J, Koyama T. [Spinal epidural heman-gioli-poma - a case report (author's transl)]. *No Shinkei Geka.* Mar 1982;10(3):313-316.
34. Padovani R, Tognetti F, Speranza S, Pozzati E. Spinal extrathecal hemangioli-pomas: report of two cases and review of the literature. *Neurosurgery.* Nov 1982;11(5):674-677.
35. Butti G, Gaetani P, Scelsi M, Pezzotta S. Extradural spinal lipomas. Report of two cases and review of the literature. *Neurochirurgia (Stuttg).* Jan 1984;27(1):28-30.
36. Pasquier B, Vasdev A, Gasnier F, et al. [Epidural angioli-poma: a rare and curable cause of spinal cord compression]. *Ann Pathol.* Dec 1984;4(5):365-369.
37. Bardosi A, Schaake T, Friede RL, Roessmann U. Extradural spinal angioli-poma with secretory activity. An ultrastructural, clinico-pathological study. *Virchows Arch A Pathol Anat Histopathol.* 1985;406(2):253-259.
38. von Hanwehr R, Apuzzo ML, Ahmadi J, Chandrasoma P. Thoracic spinal angiomyoli-poma: case report and literature review. *Neurosurgery.* Mar 1985;16(3):406-411.
39. Griebel RW, Khan M, Rozdilsky B. Spinal extradural angioli-poma. A case report and literature review. *Spine (Phila Pa 1976).* Jan-Feb 1986;11(1):47-48.
40. Haddad FS, Abla A, Allam CK. Extradural spinal angioli-poma. *Surg Neurol.* Nov 1986;26(5):473-486.
41. Nishiura I, Kubo Y, Koyama T. Spinal haemangioli-poma. Three case reports. *Neurochirurgia (Stuttg).* Mar 1986;29(2):63-66.
42. Rivkind A, Margulies JY, Lebensart P, Sherman Y, Robin GC. Anterior approach for removal of spinal angioli-poma. A case report. *Spine (Phila Pa 1976).* Jul-Aug 1986;11(6):623-625.
43. Matsushima K, Shinohara Y, Yamamoto M, Tanigaki T, Ikeda A, Satoh O. Spinal extradural angioli-poma: MR and CT diagnosis. *J Comput Assist Tomogr.* Nov-Dec 1987;11(6):1104-1106.
44. Poon TP, Behbahani M, Matoso IM, Katz MA, Pearl M. Epidural angioli-poma with spinal cord compression. *J Natl Med Assoc.* Mar 1988;80(3):347-349.
45. Parizel PM, Baleriaux D, Rodesch G, et al. Gd-DTPA-enhanced MR imaging of spinal tumors. *AJR Am J Roentgenol.* May 1989;152(5):1087-1096.
46. Anson JA, Cybulski GR, Reyes M. Spinal extradural angioli-poma: a report of two cases and review of the literature. *Surg Neurol.* Sep 1990;34(3):173-178.

47. Kuroda S, Abe H, Akino M, Iwasaki Y, Nagashima K. Infiltrating spinal angioliopoma causing myelopathy: case report. *Neurosurgery*. Aug 1990;27(2):315-318.
48. Mascacchi M, Arnetoli G, Dal Pozzo G, Canavero S, Pagni CA. Spinal epidural angioliopoma: MR findings. *AJNR Am J Neuroradiol*. Jul-Aug 1991;12(4):744-745.
49. Weill A, del Carpio-O'Donovan R, Tampieri D, Melanson D, Ethier R. Spinal angioliopomas: CT and MR aspects. *J Comput Assist Tomogr*. Jan-Feb 1991;15(1):83-85.
50. Mimata C, Wada H, Sano Y, Saitou Y, Kitamura I, Ushio Y. [Spinal extradural angioliopoma: a case report]. *No Shinkei Geka*. Oct 1992;20(10):1085-1089.
51. Pagni CA, Canavero S. Spinal epidural angioliopoma: rare or unreported? *Neurosurgery*. Oct 1992;31(4):758-764; discussion 764.
52. Rubin G, Gornish M, Sandbank J, Shevach I, Rappaport ZH. Spinal extradural angioliopoma. Case report and review of the literature. *Spine (Phila Pa 1976)*. Jun 1992;17(6):719-724.
53. Stranjalis G, Jamjoom A, Torrens MJ. MRI in the diagnosis of spinal extradural angioliopoma. *Br J Neurosurg*. 1992;6(5):481-483.
54. Michilli R, Tzonos P, Iglesias-Rozas JR. Spinal extradural angioliopoma: case report and literature review. *Neurochirurgia (Stuttg)*. Mar 1993;36(2):63-65.
55. Sakaki T, Fujita T, Yoshimine T, Taneda M, Hayakawa T. [Spinal extradural angioliopoma: a case report]. *No Shinkei Geka*. Oct 1993;21(10):959-962.
56. Shibata Y, Sugimoto K, Matsuki T, Nose T. Thoracic epidural angioliopoma--case report. *Neurol Med Chir (Tokyo)*. May 1993;33(5):316-319.
57. Yamashita K, Fuji T, Nakai T, Hamada H, Kotoh K. Extradural spinal angioliopoma: report of a case studied with MRI. *Surg Neurol*. Jan 1993;39(1):49-52.
58. Turanzas FS, Domínguez J, Eyerbe P, Dhimes P. Infiltrating spinal angioliopoma: Case report. *Neurocirugia*. 1994(5):246-249.
59. Balbo RJ, Araujo JF, Melro CA, Iafigliola MG, Valvassore FR. [Thoracic epidural angioliopoma. Report of a case]. *Arq Neuropsiquiatr*. Sep 1995;53(3-B):659-661.
60. Bouramas D, Korres DS, Roussos L, Mantzilas T, Anagnostopoulos D. Spinal extradural angioliopoma. *J Spinal Disord*. Aug 1995;8(4):324-327.
61. Krishnan VB, Law AJ, Kenwright DN. Spinal extradural angioliopoma. *Aust N Z J Surg*. Mar 1996;66(3):194-196.
62. O'Donovan NA, Naik K, Maloney WJ, Llewellyn CG. Spinal angioliopoma mimicking extradural lipomatosis. *Can Assoc Radiol J*. Feb 1996;47(1):51-53.
63. Provenzale JM, McLendon RE. Spinal angioliopomas: MR features. *AJNR Am J Neuroradiol*. Apr 1996;17(4):713-719.
64. Trabulo A, Cerqueira L, Monteiro J, Roque P, Reis FC, Coelho MR. Spinal angioliopomas revisited: two case reports. *Acta Neurochir (Wien)*. 1996;138(11):1311-1319.
65. Boockvar JA, Black K, Malik S, Stanek A, Tracey KJ. Subacute paraparesis induced by venous thrombosis of a spinal angioliopoma: a case report. *Spine (Phila Pa 1976)*. Oct 1 1997;22(19):2304-2308.
66. Shuangshoti S, Lerdlum S. Concurrent occurrence of solitary spinal epidural osteochondroma and angioliopoma. *Clin Neuropathol*. Mar-Apr 1997;16(2):107-110.
67. Sakaida H, Waga S, Kojima T, Kubo Y, Matsubara T, Yamamoto J. Thoracic spinal angiomyoliopoma with extracanal extension to the thoracic cavity. A case report. *Spine (Phila Pa 1976)*. Feb 1 1998;23(3):391-394.
68. El Abbadi N, El Mostarchid B, Bellakhdar F. Thoracic epidural spinal angioliopoma: case report. *Pan Arab J Neurosurg*. 1999;3:49-51.
69. Kujas M, Lopes M, Lalam TF, Fohanno D, Poirier J. Infiltrating extradural spinal angioliopoma. *Clin Neuropathol*. Mar-Apr 1999;18(2):93-98.
70. Labram EK, el-Shunnar K, Hilton DA, Robertson NJ. Revisited: spinal angioliopoma--three additional cases. *Br J Neurosurg*. Feb 1999;13(1):25-29.
71. Oge HK, Soylemezoglu F, Rousan N, Ozcan OE. Spinal angioliopoma: case report and review of literature. *J Spinal Disord*. Aug 1999;12(4):353-356.
72. Turgut M. Spinal angioliopomas: report of a case and review of the cases published since the discovery of the tumour in 1890. *Br J Neurosurg*. Feb 1999;13(1):30-40.
73. Akhaddar A, Gazzaz M, Derraz S, et al. [Spinal epidural angioliopomas: a rare cause of spinal cord compression. A report of 8 cases and review of the literature]. *Neurochirurgie*. Dec 2000;46(6):523-533.

74. al-Anazi A, Ammar A, Shannon P, al-Mulhim F. Spinal extradural angioliopoma. *Br J Neurosurg*. Oct 2000;14(5):471-472.
75. Andaluz N, Balko G, Bui H, Zuccarello M. Angioliopomas of the central nervous system. *J Neurooncol*. Sep 2000;49(3):219-230.
76. Bailey D, Andrews J, Mazur E, Cleary J. Dorsal thoracic cord compression from a spinal angioliopoma: case report and brief comment. *Conn Med*. May 2000;64(5):267-269.
77. Amlashi SF, Morandi X, Chabert E, Riffaud L, Haegelen C, Rolland Y. Spinal epidural angioliopoma. *J Neuroradiol*. Dec 2001;28(4):253-256.
78. Fourny DR, Tong KA, Macaulay RJ, Griebel RW. Spinal angioliopoma. *Can J Neurol Sci*. Feb 2001;28(1):82-88.
79. Gelabert-Gonzalez M, Agulleiro-Diaz J, Reyes-Santias RM. Spinal extradural angioliopoma, with a literature review. *Childs Nerv Syst*. Dec 2002;18(12):725-728.
80. Pinto-Rafael JI, Vazquez-Barquero A, Martin-Laez R, et al. [Spinal angioliopoma: case report]. *Neurocirugia (Astur)*. Aug 2002;13(4):321-325.
81. Aversa do Souto A, Dominues FS, Chimelli L, Lemos AM. Lumbosacral angioliopoma: case report. *Arq Neuropsiquiatr*. 2003(61):269-273.
82. Rabin D, Hon BA, Pelz DM, Ang LC, Lee DH, Duggal N. Infiltrating spinal angioliopoma: a case report and review of the literature. *J Spinal Disord Tech*. Oct 2004;17(5):456-461.
83. Rocchi G, Caroli E, Frati A, Cimatti M, Savlati M. Lumbar spinal angioliopomas: report of two cases and review of the literature. *Spinal Cord*. May 2004;42(5):313-316.
84. Samdani AF, Garonzik IM, Jallo G, Eberhart CG, Zahos P. Spinal angioliopoma: case report and review of the literature. *Acta Neurochir (Wien)*. Mar 2004;146(3):299-302; discussion 302.
85. Cubillos A, Acevedo H, Castillo M, et al. Spinal extradural angioliopoma: report of one case presenting during pregnancy. *Rev Chil Neurocirug*. 2005(24):42-46.
86. Petrella G, Tamburrini G, Lauriola L, Di Rocco C. Spinal epidural angioliopoma complicated by an intratumoral abscess. Case report. *J Neurosurg*. Aug 2005;103(2 Suppl):166-169.
87. Dogan S, Arslan E, Sahin S, Aksoy K, Aker S. Lumbar spinal extradural angioliopomas. Two case reports. *Neurol Med Chir (Tokyo)*. Mar 2006;46(3):157-160.
88. Konya D, Ozgen S, Kurtkaya O, Pamir NM. Lumbar spinal angioliopoma: case report and review of the literature. *Eur Spine J*. Jun 2006;15(6):1025-1028.
89. Guzey FK, Bas NS, Ozkan N, Karabulut C, Bas SC, Turgut H. Lumbar extradural infiltrating angioliopoma: a case report and review of 17 previously reported cases with infiltrating spinal angioliopomas. *Spine J*. Nov-Dec 2007;7(6):739-744.
90. Farooq MU, Samaraweera R, Heilman T, Chang HT. Spinal cavernous angioliopoma. *Arch Neurol*. Jul 2008;65(7):981-982.
91. Hungs M, Pare LS. Spinal angioliopoma: case report and literature review. *J Spinal Cord Med*. 2008;31(3):315-318.
92. Nanassis K, Tsitsopoulos P, Marinopoulos D, Mintelis A, Tsitsopoulos P. Lumbar spinal epidural angioliopoma. *J Clin Neurosci*. Apr 2008;15(4):460-463.
93. Park JH, Jeon SR, Rhim SC, Roh SW. Lumbar spinal extradural angioliopoma: case report and review of the literature. *J Korean Neurosurg Soc*. Oct 2008;44(4):265-267.
94. Yen HL, Tsai SC, Liu SM. Infiltrating spinal angioliopoma. *J Clin Neurosci*. Oct 2008;15(10):1170-1173.
95. Dufrenot L, Pele E, Cursolle JC, Coindre JM, Lepreux S. [Spinal epidural angioliopoma: a case report]. *Ann Pathol*. Feb 2010;30(1):30-32.
96. Sankaran V, Carey M, Shad A. Traumatic bleeding of spinal angioliopoma presenting with subacute paraparesis--a case report and histopathological aspects. *Br J Neurosurg*. Dec 2010;24(6):714-715.
97. Chotai S, Hur JS, Moon HJ, Kwon TH, Park YK, Kim JH. Spinal angioliopoma--case report. *Neurol Med Chir (Tokyo)*. 2011;51(7):539-542.
98. Diyora B, Nayak N, Kukreja S, Kamble H, Sharma A. Thoracic epidural angioliopoma with bilateral multilevel extraspinal extensions: a rare entity. *Neurol India*. Jan-Feb 2011;59(1):134-136.
99. Haji FA, Patel YK, Ang LC, Megyesi JF. A case of mistaken identity: spinal epidural angioliopoma. *Can J Neurol Sci*. Mar 2011;38(2):357-359.
100. Ghanta RK, Koti K, Dandamudi S. Spinal



- epidural angioliopoma: A rare cause of spinal cord compression. *J Neurosci Rural Pract. Sep* 2012;3(3):341-343.
101. Han SR, Yee GT, Choi CY, Lee CH. Infiltrating spinal angioliopoma. *J Korean Neurosurg Soc.* Aug 2012;52(2):161-163.
102. Fujiwara H, Kaito T, Takenaka S, Makino T, Yonenobu K. Thoracic spinal epidural angioliopoma: report of two cases and review of the literature. *Turk Neurosurg.* 2013;23(2):271-277.
103. da Costa MD, Paz Dde A, Rodrigues TP, et al. Hemorrhagic onset of spinal angioliopoma. *J Neurosurg Spine.* Dec 2014;21(6):913-915.
104. Nakao Y, Shimokawa N, Tsukazaki Y, Terada A, Nakajo K, Fu Y. Radical excision combined with instrumented fixation in the management of thoracic epidural angioliopoma: a case report. *J Med Case Rep.* 2014;8:377.
105. Si Y, Wang Z, Pan Y, Lin G, Yu T. Spinal angioliopoma: etiology, imaging findings, classification, treatment, and prognosis. *Eur Spine J.* Feb 2014;23(2):417-425.
106. Wang B, Yang Z, Yang J, Wang G, Xu Y, Liu P. Spinal angioliopoma: experience of twelve patients and literature. *Neurol India.* Jul-Aug 2014;62(4):367-370.
107. Nadi MM, Nadi AM, Zabara MY, Ahmad TM. Management of infiltrating spinal epidural angioliopoma. *Neurosciences (Riyadh).* Apr 2015;20(2):159-163.
108. Lin JJ, Lin F. Two entities in angioliopoma. A study of 459 cases of lipoma with review of literature on infiltrating angioliopoma. *Cancer.* Sep 1974;34(3):720-727.
109. Kitagawa Y, Miyamoto M, Konno S, et al. Subcutaneous angioliopoma: magnetic resonance imaging features with histological correlation. *J Nippon Med Sch.* 2014;81(5):313-319.
110. Hu S, Hu CH, Hu XY, et al. MRI features of spinal epidural angioliopomas. *Korean J Radiol.* Sep-Oct 2013;14(5):810-817.
111. Garg A, Gupta V, Gaikwad S, et al. Spinal angioliopoma: report of three cases and review of MRI features. *Australas Radiol.* Mar 2002;46(1):84-90.
112. Klisch J, Spreer J, Bloss HG, Baborie A, Hubbe U. Radiological and histological findings in spinal intramedullary angioliopoma. *Neuroradiology.* Aug 1999;41(8):584-587.
113. Maggi G, Aliberti F, Colucci MR, Petrone G, Dorato P, De Giorgi AM. Spinal intramedullary angioliopoma. *Childs Nerv Syst.* Jun 1996;12(6):346-349.
114. Palkovic S, Wassmann H, Bonse R, Kashab M. Angioliopoma of the spinal cord. Magnetic resonance imaging and microsurgical management. *Surg Neurol.* Mar 1988;29(3):243-245.
115. Prasad GL, Sinha S. Spinal intradural subpial angioliopoma: Case report and review of literature. *Surg Neurol Int.* 2014;5:164.
116. Preul MC, Leblanc R, Tampieri D, Robitaille Y, Pokrupa R. Spinal angioliopomas. Report of three cases. *J Neurosurg.* Feb 1993;78(2):280-286.

## Disclosures

The authors have no conflict of interests or funding sources to declare.

## Corresponding Author

Enrique Caro-Osorio, M.D. Neurology and Neurosurgery Institute, Centro Médico Hospital Zambrano Hellion, TecSalud, Batallón de San Patricio #112, 8th Floor, Monterrey, México 66278. [ecaro@itesm.mx](mailto:ecaro@itesm.mx).

Published 2 December 2015.

This manuscript is generously published free of charge by ISASS, the International Society for the Advancement of Spine Surgery. Copyright © 2015 ISASS. To see more or order reprints or permissions, see <http://ijssurgery.com>.