

Occipitocervical Fusion and Posterior Fossa Decompression in Neglected Jefferson Fracture-Dislocation of Atlas Associated With Odontoid Peg Fracture: A Case Report

Karya T. Biakto, Jainal Arifin, Jansen Lee and Michael Benjamin

Int J Spine Surg published online 1 February 2019
<https://www.ijssurgery.com/content/early/2019/02/01/6001>

This information is current as of May 11, 2025.

Email Alerts Receive free email-alerts when new articles cite this article. Sign up at:
<http://ijssurgery.com/alerts>

Occipitocervical Fusion and Posterior Fossa Decompression in Neglected Jefferson Fracture-Dislocation of Atlas Associated With Odontoid Peg Fracture: A Case Report

KARYA T. BIAKTO, PHD, JAINAL ARIFIN, MD, JANSEN LEE, MD, MICHAEL BENJAMIN, MD
Department of Orthopaedic and Traumatology, Wahidin Sudirohusodo General Hospital, University of Hasanuddin, Makassar, Indonesia

ABSTRACT

Background: Only a few cases of traumatic atlantoaxial fracture-dislocation have been reported, and neglected cases are seldom found because of the fatal nature of this condition.

Methods: We reported a neglected case of Jefferson fracture-dislocation associated with type II displaced odontoid peg fracture which was nonambulatory and myelopathic. A surgical plan involving posterior fossa decompression and laminectomy of the posterior arch of atlas following posterior spinal instrumentation was then conducted.

Results: Patient experienced marked neurologic recovery and was able to stand and walk with assistance during the early postoperative period.

Conclusions: This procedure may be an effective alternative treatment in neglected cases.

Cervical Spine

Keywords: neglected, Jefferson fracture-dislocation, odontoid peg fracture, posterior fossa decompression, occipitocervical fusion

INTRODUCTION

The presentation of concomitant atlantoaxial fracture dislocation and odontoid peg fracture is rare, with an estimated frequency of less than 2% among upper cervical spine injury cases. The resulting instability further increases the fatal nature of this injury.¹ Atlantoaxial fracture-dislocation may cause cervical cord injury and death in the immediate postinjury period or in a delayed fashion.^{2,3} The survival rate of these cases can only be increased through early diagnosis, immediate immobilization, meticulous monitoring, and early reduction and fixation of the fracture.³

Neglected spinal injuries are frequently encountered in underdeveloped countries for many reasons, such as a patient's belief in medical treatment, poverty, unequal rights in health care access, delay in diagnosis, and inadequate medical facilities, but unfortunately, published cases are seldom found.⁴ Such conditions cannot be treated with conventional surgical techniques and require a tailored surgical plan.⁵ Reports on neglected concomitant atlantoaxial fracture dislocation and odontoid peg fracture

are infrequently published, and as such we would like to present our findings and treatment plan for this particular case.

CASE PRESENTATION

History

A 17-year-old male patient presented with neck pain, quadriparesis, and signs of myelopathy during the past 6 months. Bowel and bladder functions remained intact. The patient had a traumatic event when the motorcycle he was riding crashed into a tree. However, he was still able to walk with assistance during the immediate posttraumatic period, with only complaints of slight weakness and numbness at all 4 limbs and with moderate neck pain. He was then brought to a local health care facility but unfortunately refused further treatment and opted to be treated by a local "bone-setter." The patient's condition soon deteriorated, and he had remained nonambulatory for the past 4 months after receiving numerous nonmedical treatments by a local "bone-setter" and refusing surgical referral

by a neurologist who had found the spinal cord compression caused by the cervical fracture after performing magnetic resonance imaging (MRI). The patient was then willingly referred to a spine surgeon after exhausting all nonoperative measures.

Examination

The patient initially presented in our department with a hard collar on for support and was nonambulatory. Physical examination revealed a hump at the occiput region, with a slight torticollis posture of the neck. Neurologic evaluation revealed hypoesthesia at the C3 dermatomal level and below, with a motoric power at left-sided limbs of 3/5 and at right-sided limbs of 2/5 (American Spinal Injury Association [ASIA] Impairment Grade C). There was also spasticity and exaggerated deep tendon reflexes in all extremities. The clinical picture of the patient performing handgrip of the right hand preoperatively was as depicted in Figure 1.

Cervical spine radiographs (Figure 2) and computed tomography (CT) scan (Figure 3) revealed Jefferson fracture-dislocation with anterior subluxation of atlas and odontoid process type II fracture (Anderson and D'Alonzo Classification).⁶ Overall, this combined injury produced angular flexion deformity of the upper cervical spine. The entire cervical spine showed osteopenia with marked compensatory lordosis. Some callus formation was also evident at the injury site. MRI revealed severe compression of the spinal cord, with myelomalacia at the craniovertebral segment of the cord (Figure 4).

Operative Findings

Surgery was performed using a posterior approach, with the midline incision made from the suboccipital area to the spinous process of C5. Posterior spinal instrumentation with occipitocervical fusion to the level of C4 was done using a combination of lateral mass and pedicle screws followed by posterior fossa decompression using a craniotome and laminectomy of C1. The patient was then placed on a Philadelphia collar neck postoperatively. Intraoperative findings are depicted in Figure 5, and postoperative radiograph is shown in Figure 6.

Postoperative Period

There was progressive neurologic improvement during the early postoperative period. On day 5, the

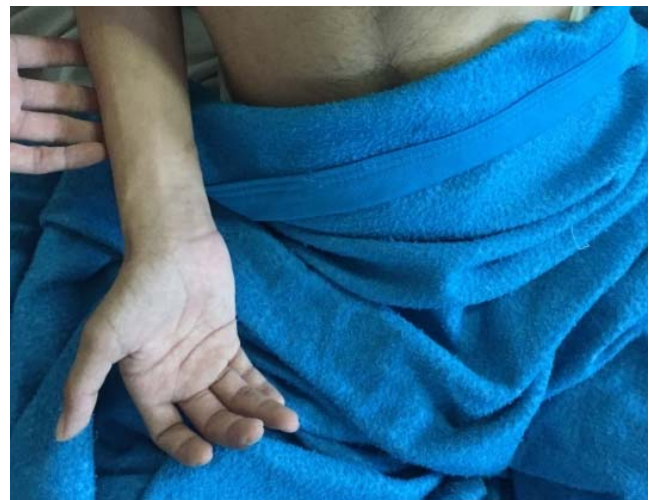

Figure 1. Clinical picture of maximum handgrip ability of the right hand.

muscle strength of all 4 extremities had improved, especially on the right hand, with a motoric power of 3/5, and on day 10 the patient was able to sit independently and walk with assistance. Patient was discharged at day 14, with uneventful healing of the incision and minimal postoperative pain. At 2 months of follow-up, patient was able to walk and bathe independently, with motoric a power of 4/5 on all the extremities (ASIA Impairment Grade D). The neck range of motion, however, was markedly reduced. The clinical improvements were as depicted in Figure 7.

DISCUSSION

Neglected cases involving both Jefferson fracture-dislocation and odontoid peg fracture are rare. A large retrospective epidemiologic study conducted in 2000 for a period of 14 years revealed that 116 of 784 cases of cervical spinal injuries were upper cervical spinal injuries, and only 2 of them were a combination of these injuries.⁷ Most cases that are found are lethal, or the patient only survives for few hours,⁸ although successfully treated cases had also been documented.⁹ For the past 30 years, only 15 clinical cases have been described, with 7 cases presenting with no neurologic deficits and only 1 case with spastic tetraparesis.¹⁰

Odontoid process plays a vital role in maintaining the inherent stability of the C1 to C2 joint. Fracture of this anatomic structure often leads to nonunion or fibrous union due to the poor vascularity of this region because it is enveloped in synovium, or, in certain neglected cases, results in cervical cord compression with instability. Therefore, surgical

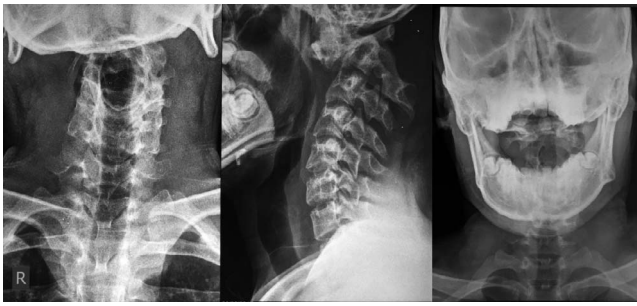

Figure 2. Radiograph of the cervical spine: Antero-posterior, lateral, and open mouth position.

intervention remains the most viable option in achieving fracture union.^{3,5} To date, there is still no known consensus for the treatment algorithm of Jefferson fracture-dislocation associated with an odontoid fracture, and thus several authors have employed different management protocol and surgical technique in handling these cases.¹¹

In acute cases, closed reduction of the dislocation can be performed with skull traction followed by

halo-vest immobilization. Surgery is only required if closed reduction attempts have failed.^{11,12} However, the treatment plan for neglected cases needs to be tailored according to several factors, including the patient's age, time lapse from initial injury, preexisting medical morbidity, severity of injury, stability of the C1 to C2 articulation, ease of reduction, and most importantly, the medical facility's capabilities, because these cases are frequently found in under-developed countries.¹³

Fracture reduction in delayed cases is often impossible because several changes have occurred since the initiating injury: (1) the anterior tissues over the craniovertebral area became contracted and shortened, (2) the C1 to C2 kyphotic deformity caused contracture of the muscles of the neck (such as longus colli and longus capitis) along with contracture of the joint capsules and the anterior longitudinal ligaments, and (3) the C1 to C2 articular surfaces gradually became arthritic and bony bridges eventually formed around the dens

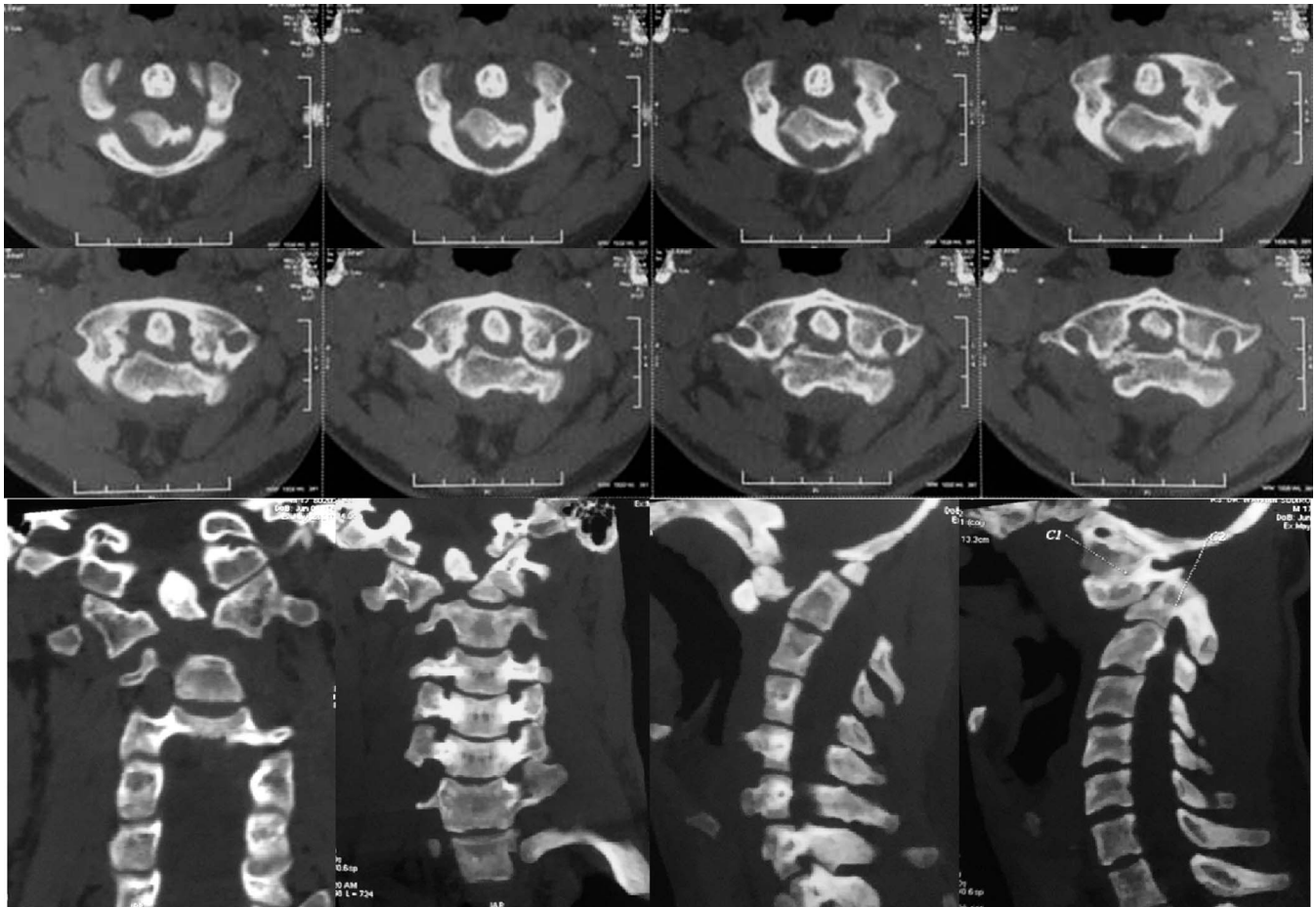


Figure 3. Computed tomography scan of the cervical spine: axial, coronal, and sagittal section.

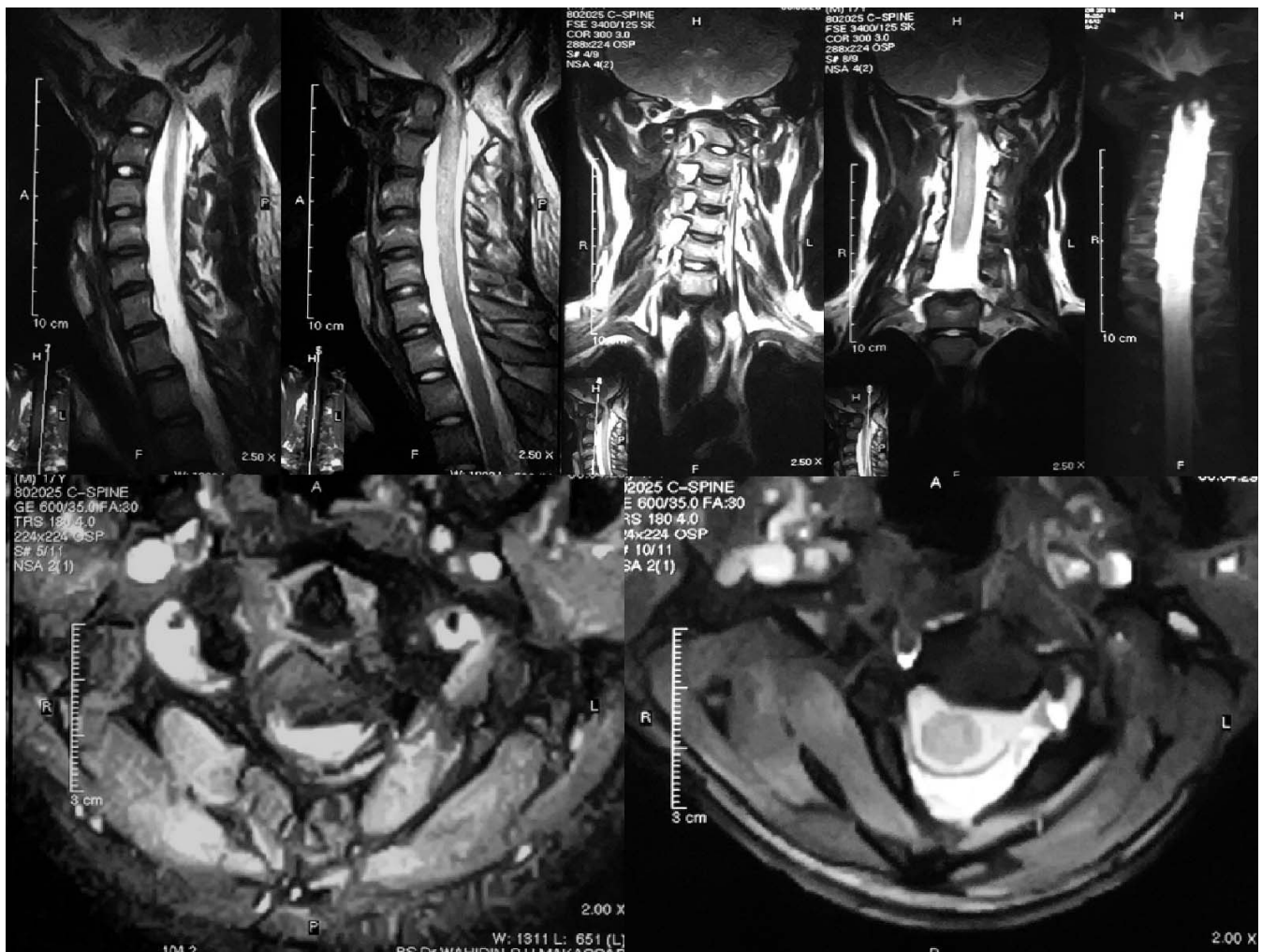


Figure 4. Magnetic resonance imaging of the cervical spine: reduced thickness of cord along with hyperintense signal on T2 in cord at the level C1-vertebra–myelomalacia.

and body of the axis, further impeding the reduction maneuver.⁵

Traditionally, this irreducible condition was treated with transoral odontoidectomy followed by posterior fusion. This procedure, however, has the risk of incidental dural insult, which may lead to

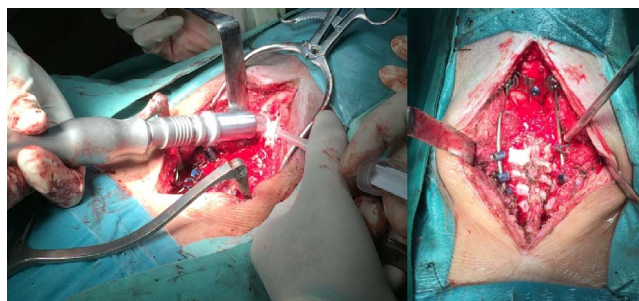


Figure 5. Intraoperative pictures showing suboccipital craniotomy using craniotome (right) followed by occipitocervical fusion and laminectomy of the atlas (left).

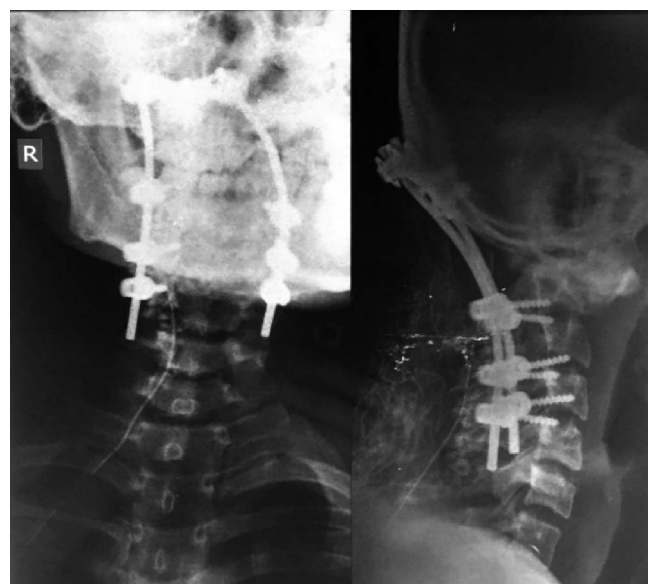


Figure 6. Radiograph of cervical spine after occipitocervical fusion.



Figure 7. Ability to perform handgrip by day 5 (top); ability to sit independently with extended knee, and assisted walking (bottom) by day 10.

meningitis.¹⁴ Most surgeons preferred posterior fixation following anterior release, although other options, including posterior occipitocervical fusion and posterior transarticular fusion with C1 to C2 pedicle screws fixation, is still possible.^{5,10}

We have opted to use the posterior approach because it has multiple advantages: (1) it allows access to the posterior joint when the dislocation is posterior and allows for screw fixation of C1 to C2, and (2) if intraoperative problems are encountered, occipitocervical fixation remains a viable option. This approach, however, does not provide good exposure of the articular processes, and muscle layers must be detached and reflected laterally, which further increases the risk of venous bleeding.¹

Our surgical plan includes posterior fossa decompression and C1 arch laminectomy following posterior spinal instrumentation using a combination of pedicle and lateral mass screws. This management plan, which was usually used in cases of Chiari malformation,¹⁵ tumor decompression,¹⁶ and atlantoaxial subluxation of a chondroplastic patient with narrow foramen magnum,¹⁷ proved to be a good option in managing this particular

combination of injury compared with the more complicated ventral procedures.¹⁸

With ease of access to the injury site and increased stability with maximum fixation, this operative technique may be a reasonable option in handling complicated neglected cases of combined Jefferson fracture dislocation and odontoid peg fracture.

REFERENCES

1. Moreau PE, Nguyen V, Atallah A, Kassab G, Thiong'o MW, Laporte C. Traumatic atlantoaxial dislocation with odontoid fracture: a case report. *Orthop Traumatol Surg Res.* 2012;98(5):613–617.
2. Colsen K. Antlanto-axial fracture dislocation. *J Bone Joint Surg Br.* 1949;31B(3):395–398.
3. Desai AA, Trivedi A, Chandrakar BL, Soni R. Old and neglected odontoid fracture with C1-C2 dislocation: an approach. *J Spinal Surg.* 2015;2(1):27–29.
4. Sengupta DK. Neglected spinal injuries. *Clin Orthop Relat Res.* 2005;(431):93–103.
5. Aggarwal RA, Rargod AK, Chaudhary KS. Irreducible atlanto-axial dislocation in neglected odontoid fracture treated with single stage anterior release and posterior instrumented fusion. *Asian Spine J.* 2016;10(2):349–354.
6. Anderson LD, D'Alonzo RT. Fractures of the odontoid process of the axis. *J Bone Joint Surg Am.* 1974;56(8):1663–1674.
7. Gleizes V, Jacquot FP, Signoret F, Feron JM. Combined injuries in the upper cervical spine: clinical and epidemiological data over a 14-year period. *Eur Spine J.* 2000;9(5):386–392.
8. Alker GJ Jr, Oh YS, Leslie EV. High cervical spine and craniocervical junction injuries in fatal traffic accidents: a radiological study. *Orthop Clin North Am.* 1978;9(4):1003–1010.
9. Cooper Z, Gross JA, Lacey JM, Traven N, Mirza SK, Arbabi S. Identifying survivors with traumatic craniocervical dissociation: a retrospective study. *J Surg Res.* 2010;60(1):3–8.
10. Brefschneider H, Meyner T, Schneiders W. Traumatic posterolateral atlantoaxial dislocation with type ii odontoid fracture: case report. *Trauma Acute Care.* 2016;1(3):26.
11. Riouallon G, Pascal-Moussellard H. Atlanto-axial dislocation complicating a type II odontoid fracture: reduction and final fixation: case report. *Orthop Traumatol Surg Res.* 2014;100(3):341–345.
12. Lenehan B, Guerin S, Street J, Poynton A. Lateral C1-C2 dislocation complicating a type II odontoid fracture. *J Clin Neurosci.* 2010;17(7):947–949.
13. Padalkar P. Chronic neglected irreducible atlantoaxial rotatory subluxation in adolescence. *J Craniovertebr Junction Spine.* 2016;7(3):184–188.
14. Jain VK, Behari S, Banerji D, Bhargava V, Chhabra DK. Transoral decompression for craniocervical osseous anomalies: perioperative management dilemmas. *Neurol India.* 1999;47(3):188–195.
15. Hwang SW, Hellman CB, Reisenburger RI, Kryzanski J. C1-C2 arthrodesis after transoral odontoidectomy and suboc-

capital craniectomy for ventral brain stem compression in Chiari I patients. *Eur Spine J.* 2008;17(9):1211–1217.

16. Chatlet A, Jaiwal AK, Jain M, Behari S. Congenital irreducible atlantoaxial dislocation associated with cervical intramedullary astrocytoma causing progressive spastic quadriplegia. *Neurol India.* 2008;56(4):477–479.

17. Rahimizadeh A, Souflani HF, Hassani V, Rahimizadeh A. Atlantoaxial subluxation due to an os odontoideum in an achondroplastic adult: report of a case and review of the literature. *Case Rep Orthop.* 2015;2015:142586.

18. Rahimizadeh A, Soufiani H, Rahimizadeh A. Management of irreducible atlantoaxial dislocation with horizontal screw-rod construct and technical note. *World Spinal Column J.* 2015;6(2):55–64.

Disclosures and COI: None of the authors received payments or other benefits or a commitment or agreement to provide such benefits from a commercial entity. No commercial entity paid or directed, or agreed to pay or direct, any benefits to

any research fund, foundation, educational institution, or other charitable or nonprofit organization with which the authors are affiliated or associated.

Corresponding Author: Jansen Lee, MD, Department of Orthopaedic and Traumatology, Wahidin Sudirohusodo General Hospital at University of Hasanuddin, Jalan Perintis Kemerdekaan Km.11 – Tamalanrea, Makassar, South Sulawesi, Indonesia, 90245. Phone: (62) 8126343585; Email: lee.jansen.88@gmail.com.

Published 0 Month 2019

This manuscript is generously published free of charge by ISASS, the International Society for the Advancement of Spine Surgery. Copyright © 2018 ISASS. To see more or order reprints or permissions, see <http://ijssurgery.com>.