

The Effect of Alendronate on Subsidence After Lateral Transpsoas Interbody Fusion: A Preliminary Report

Rahul G. Samtani, James T. Bernatz, Rachel Harrison, Siddharth Roy, Sachin Gupta and Joseph R. O'Brien

Int J Spine Surg published online 9 July 2019
<https://www.ijssurgery.com/content/early/2019/07/09/6039>

This information is current as of May 12, 2025.

Email Alerts Receive free email-alerts when new articles cite this article. Sign up at:
<http://ijssurgery.com/alerts>

The Effect of Alendronate on Subsidence After Lateral Transpsoas Interbody Fusion: A Preliminary Report

RAHUL G. SAMTANI, MD,¹ JAMES T. BERNATZ, MD,¹ RACHEL HARRISON, MD,² SIDDHARTH ROY,²
SACHIN GUPTA,² JOSEPH R. O'BRIEN, MD, MPH²

¹Department of Orthopaedic Surgery, University of Wisconsin, Madison, Wisconsin, ²Department of Orthopaedic Surgery, George Washington University, Washington, DC

ABSTRACT

Background: Success after lateral transpsoas interbody fusion (LLIF) partially depends on avoidance of subsidence to maintain spinal alignment, disc space height, and indirect neural decompression. Techniques for preventing subsidence have focused largely on surgical and biomechanical properties of spinal reconstruction; however, medical management may also affect subsidence rates as well. The purpose of this study is to examine the effect of alendronate on minimally invasive LLIF patients with regard to radiographic and catastrophic subsidence.

Methods: We followed 26 patients who had LLIF at the L4-5 level (13 on alendronate, 13 control) and 22 patients at the L3-4 level (10 on alendronate, 12 control). Radiographs were reviewed to obtain measurements of subsidence at the 4 corners of the cage at 3 follow-up time points (2–3, 5–8, and 10–12 months). A Tobit mixed model was used to confirm the results.

Results: We found no relationship between alendronate and subsidence for L3-4 fusion. At L4-5 we observed increased subsidence in the control group compared to the alendronate group (difference = 0.07 cm, 95% confidence interval [CI]: -0.01, 0.16, $P = .08$). There was a decrease in subsidence noted for the alendronate group for each time period (differences: 2–3: -0.06 cm, 95% CI: -.28, .15], $P = .27$; 5–8: -0.14 cm, 95% CI: -0.36, .08, $P = 0.10$; 10–12: -0.21 cm, 95% CI: -0.48, .04, $P = .05$).

Conclusions: A clear reduction in subsidence was found with the use of postoperative alendronate in patients undergoing L4-5 LLIF. Alendronate had a significant decrease in subsidence at L4-5 after 10–12 months as compared to the control group. Additionally, no patients treated with alendronate had catastrophic subsidence. These data suggest the need for further study of alendronate in the prevention of subsidence after LLIF.

Level of Evidence: 3.

Lumbar Spine

Keywords: LLIF, alendronate, subsidence

INTRODUCTION

Spinal stenosis and scoliosis affects the same population affected by osteoporosis.^{1,2} Typically, surgery is a definitive treatment for those who have not had success with nonsurgical treatments. In the case of simple stenosis, surgical laminectomy is effective. However, in the setting of instability (spondylolisthesis or scoliosis) or severe neuroforaminal stenosis, fusion may be required.³

Traditional spinal fusion techniques require a long convalescence. Minimally invasive lateral transpsoas interbody fusion (LLIF) can be performed as an alternative by experienced surgeons.⁴ Incisions less than 4 cm are used with a muscle sparing approach. Success with this technique has spurred its adoption in some spinal centers.⁵ The technique places a large cage in between the

vertebrae to realign the spine and enlarge the neuroforamina.⁶ Bone graft inside the cage enables fusion of the treated vertebral segments.

Success of the LLIF procedure depends on avoidance of subsidence of the cages into the vertebral endplate to maintain the alignment and neural decompression while the spine fusion occurs.⁷ This effect is termed indirect spinal decompression.⁸

Techniques for preventing subsidence have focused largely on surgical and biomechanical properties of the spinal reconstruction.⁷ However, medical management may also affect subsidence rates as well.

Recent studies have shown that alendronate use is safe for patients with osteoporosis while they are healing from spinal arthrodesis or fracture heal-

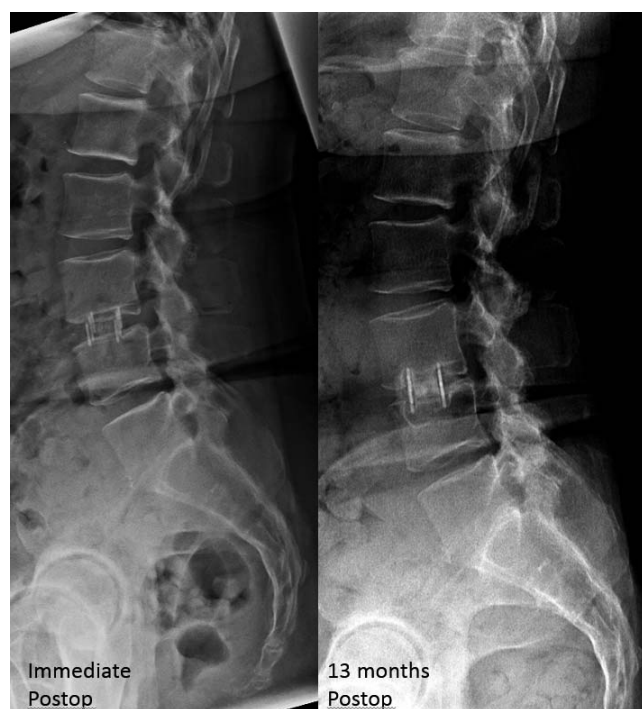

Figure 1. X-rays from a subject in the control group immediately postoperative and at final follow-up, noting significant subsidence of cage.

ing.^{9,10} Additionally, a recent prospective, randomized trial followed osteoporotic patients after traditional open spinal surgery.⁹ Patients diagnosed with osteoporosis were eligible for enrollment in the study. Treatment was randomized to either vitamin D/calcium supplementation or bisphosphonate treatment for 3 months postoperative. Both treatments were standard of care for patients with osteoporosis. Additionally, many patients with osteoporosis take alendronate currently. The study demonstrated a significant increase in fusion rates and decrease in subsidence in patients treated with alendronate in a transforaminal lumbar interbody fusion model.

After the publication of the above study, patients treated in our medical center with LLIF surgery were placed on alendronate for 3 months postoperatively. This study proposed the following by examining patients treated with alendronate after LLIF surgery to (1) determine if there is a difference in subsidence and (2) to determine if there is a difference in catastrophic failure requiring reoperation (Figures 1 and 2).

MATERIALS AND METHODS

The institutional review board at our medical center approved this study.

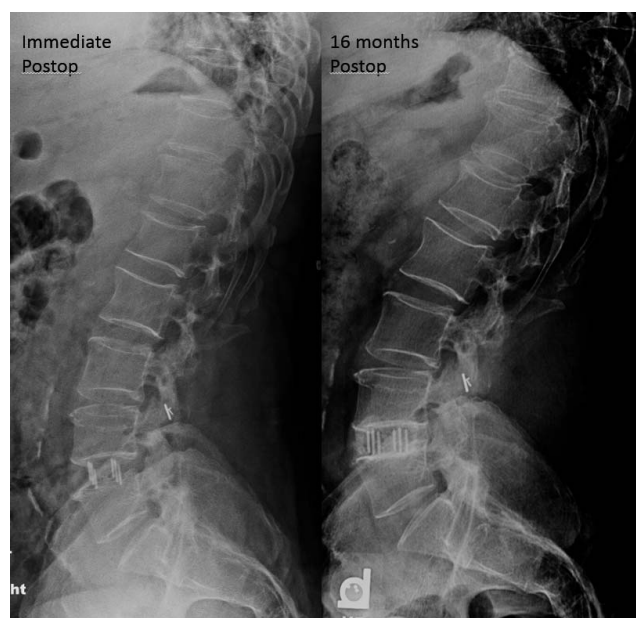

Figure 2. X-rays from a subject in the alendronate group immediately postoperative and at final follow-up, noting no subsidence of cage.

A retrospective review of a database of patients between June 2010 and March 2012 who underwent lateral transpsoas interbody fusion (XLIF, NuVasive) was performed. One surgeon at an academic, tertiary hospital performed all of the operations. The control group is a cohort with patients who underwent LLIF prior to the start of the alendronate regimen. The patients in the study were consecutive patients.

For the operative procedure, the patient underwent general anesthesia using succinylcholine. Neuromonitoring leads were placed into the appropriate muscle bodies by the operative surgeon and connected to the neuromonitoring system and ensured 4/4 twitches to be present. The patient was placed in the lateral decubitus position, and a retroperitoneal approach was made to the spine. The appropriate disc space was identified using fluoroscopy. A knife was used to incise the annulus, and a subtotal discectomy was performed using a combination of curettes, pituitary rongeurs, and Kerrison punches. The disc space was sequentially dilated, and a cage size was selected of the appropriate height and maximum width possible. The polyether ether ketone (PEEK) cage was packed with allograft cellular bone matrix containing mesenchymal stem cells and osteoprogenitor cells combined with DBM (Osteocel Plus, NuVasive) alone or that in addition to a small bone morphogenic protein 2 [rhBMP-2] (Infuse, Med-

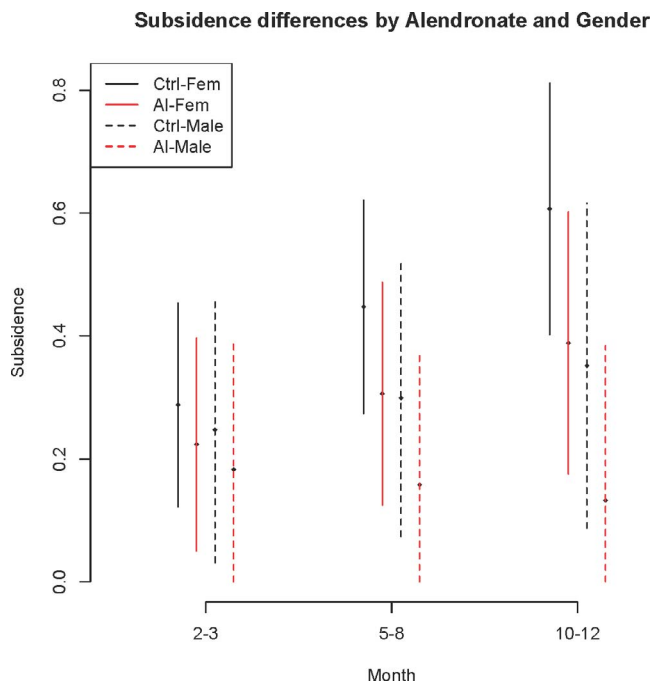


Figure 3. Subsidence differences by alendronate and gender.

tronic) kit (4.2 mg) per level. All patients received the same mixture of bone graft material at each level.

Data collected in the retrospective chart review included diagnosis, cage width, alendronate use, and follow-up time. Surgical indications in this cohort included scoliosis, spondylosis, spondylolisthesis, and lumbar stenosis. PEEK implant cages of various heights were implanted depending on disc space dilation, and maximum width cage was used, either 18 or 22 mm.

We modeled the total subsidence over 4 cage corners (AS, AI, PS, PI) using a linear mixed model that included terms for alendronate, gender, time trend, and the interaction of alendronate and gender by time trend. The subject correlations were incorporated using random slope and intercept terms. Since the L4-5 group had many patients with no subsidence, we checked for sensitivity to modeling assumptions using a Tobit mixed model.

We compared the alendronate group to the control group for differences in change of subsidence per time period and for the average subsidence differences at each of the 3 individual time periods. We performed a similar comparison between males and females. L4-5 had 13 subjects in the control group (9 female, 4 male) and 13 subjects in the alendronate group (8 female, 5 male). L3-4 had 12 subjects in the control group (7 female,

5 male) and 10 subjects in the alendronate group (6 female, 4 male). These measurements were performed by 1 observer (RS), not the surgeon. All model assumptions were evaluated using residual plots, and all analysis was performed on the R statistical software.

Patients were similar in regard to demographics in both groups.

RESULTS

L3-4 Disc Space

There was no evidence of significant association between alendronate and subsidence in this group. We observed a significant increase in subsidence over time for the L3-4 group also (0.09 cm, 95% CI: 0.04, 0.14, $P < .0001$). There is a decrease for the alendronate group relative to controls (−0.05 cm, 95% CI: −0.15, 0.05, $P = .32$) and a small increase for males relative to females (0.02 cm, 95% CI: −0.08, 0.11, $P = .74$).

L4-5 Disc Space

There is a significant increase in subsidence at each time point (0.08 cm, 95% CI: 0.03, .13, $P = .002$). We observed that the increase in subsidence is larger for the control group compared to the alendronate group (difference = 0.07 cm, 95% CI: −0.01, 0.16, $P = .08$) and that females have a larger increase in subsidence per time point compared to males (difference = 0.10 cm, 95% CI: .02, 0.20, $P = .02$).

There is a decrease in subsidence noted for the alendronate group for each time period, and this is significant in the final 10–12-month period (Figures 3 and 4) (differences: 2–3: −0.06 cm, 95% CI: −.28, .15, $P = .27$; 5–8: −0.14 cm, 95% CI: −0.36, .08, $P = .10$; 10–12: −0.21 cm, 95% CI: −0.48, .04, $P = .05$).

Similarly, the decrease in subsidence for males relative to females is small initially but is significant at the final period (2–3: −0.04 cm, 95% CI: −0.26, 0.18, $P = .36$; 5–8: −0.15 cm, 95% CI: −0.38, 0.09, $P = .10$; 10–12: −0.26 cm, 95% CI: −0.53, 0.02, $P = .03$).

Tobit Results

Results were similar qualitatively: increasing average time trend ($P = .015$), a decrease in subsidence for alendronate group ($P = .13$), and male group ($P = .14$).

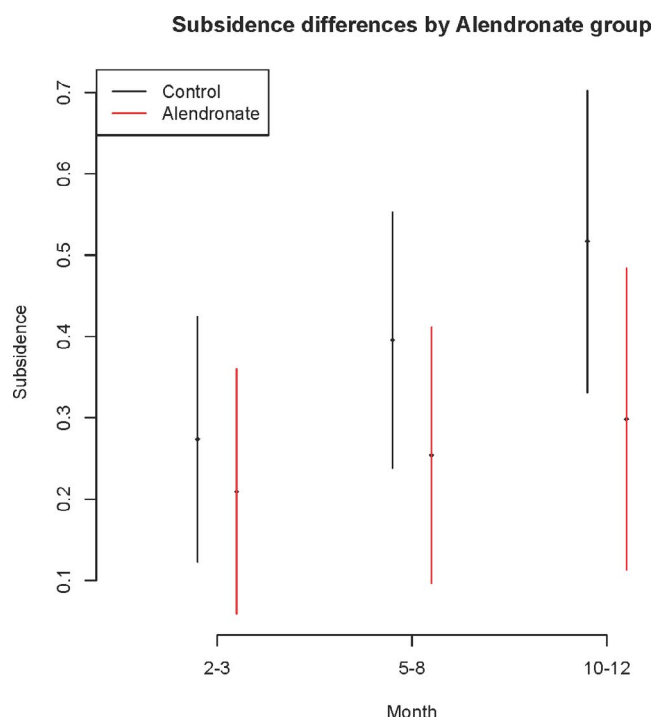


Figure 4. Subsidence difference in control and alendronate groups.

DISCUSSION

Osteoporosis is a disease that affects over 40 million Americans.¹¹ Typical manifestations of osteoporosis include an increased risk for fragility fracture and an association with spinal deformity.^{1,2}

Treatment of osteoporosis can include hormone replacement, nutritional supplementation with vitamin D and calcium, antiresorptive therapy (bisphosphonates), or anabolic agents (teriparatide).^{1,4,11}

Osteoporosis comes in 2 forms: postmenopausal (type I) and senile (type II).¹¹ Postmenopausal osteoporosis is characterized by a large drop in bone mineral density that coincides with a drop in estrogen and progesterone levels in women after menopause. There is a concomitant drop in cancellous bone density. Senile osteoporosis typically affects men more than women and occurs during the seventh decade of life. It is characterized by a loss of cortical and cancellous bone density. Regardless of etiology, osteoporosis is measured by dual X-ray absorptiometry scanning. Scores are compared to either age-matched (z score) or youthful controls (t score). Osteoporosis is defined by a bone densitometry t score of -2.5 standard deviations from the mean.¹¹

Degenerative disease of the lumbar spine, including stenosis and scoliosis, is another result of the aging spine that often simultaneously affects the same osteoporotic population. In the general population, the prevalence of spondylosis ranges from 20% to 25% and increases with age greater than 50 years.¹² In 1 study, the incidence of degenerative scoliosis was found to be 36% in patients with osteoporosis, 6 times higher than the matched controls without osteoporosis.¹³ As a result of the study, they postulated that osteoporosis was the cause of the deformity. Later studies showed that there is no direct causal relationship between osteoporosis and scoliosis but that they commonly occur in the same cohort as a result of aging and health status.^{2,14}

Many of these patients with osteoporosis and spondylosis fail nonoperative management but have a high risk of morbidity with the traditional posterior spinal decompression and fusion or combined anterior/posterior reconstruction. A traditional posterior spinal fusion or anterior/posterior spinal fusion results in significant blood loss, pain, and longer time to ambulation, prolonging the overall recovery.¹⁵ The minimally invasive approach used in this study has gained increasing popularity with recent studies showing symptomatic relief and lower complication rates than traditional approaches.¹⁶ The LLIF approach is an effective technique that can be used safely by an experienced surgeon for patients with symptomatic degenerative disease or scoliosis of the lumbar spine.¹⁷

The technique increases the disc space height, providing an indirect neural decompression and eventually fusion.⁸ A recent study by Phillips et al⁵ had an 85% patient satisfaction rate with a substantially lower complication rate (24%) than traditional procedures (66%).

Like any procedure, there are modes of failure; for this procedure, some of these include subsidence of the interbody cage, vertebral body fracture, and failure of fusion.¹⁸ Subsidence can be a result of bone quality, implant material or size, or surgical technique. To prevent subsidence, the bone-implant interface has to have sufficient strength to withstand the loading of the lumbar spine.¹⁹

Hou and Luo¹⁹ examined the anatomic structure of lumbar end plates and any differences in failure to load. The end plate is thickest and most dense in the periphery, particularly near the posterolateral corner near the pedicles, and weakest centrally. The

authors also found that the failure loads tend to increase in both the superior and the inferior lumbar end plates from the L1 to the L5 segment, proximal to distal levels. The inferior end plates in the lumbar spine were significantly stronger than the superior end plates.²⁰ This information may help guide the optimum placement of the interbody cage in order to minimize subsidence.

Hou and Luo¹⁹ also found that a decrease in bone mineral density led to lower failure load, which indicates that patients with osteoporosis have a higher risk of subsidence. However, this study also showed that the failure load distribution did not change, with the posterolateral portion being the strongest area. In patients with known osteoporosis undergoing spinal fusion, placement of the interbody cage more posteriorly may be considered. Closkey et al¹⁸ looked at the optimum implant size to prevent subsidence and found that at least 30% to 40% coverage was needed to withstand physiologic loads, but the larger the coverage, the better. As for implant type, PEEK implants are thought to have a similar modulus of elasticity as bone and are therefore considered favorable.⁷

Research on the use of bisphosphonates in spinal fusion has conflicting findings. The use of alendronate after LLIF was evaluated in this study to determine if it would improve outcomes by decreasing subsidence. Alendronate is a bisphosphonate frequently used in the treatment of osteoporosis. It inhibits osteoclast-mediated bone resorption and has been shown to increase vertebral strength and to prevent vertebral compression fractures.⁹ The use of alendronate after lumbar fusion is thought to prevent subsidence by decreasing bone resorption of the end plates around the interbody cage.¹⁰

Imai et al²¹ used a quantitative computed tomography-based model to assess vertebral strength in postmenopausal women and noted that after 3 months of alendronate treatment, they had a 10.2% increase in vertebral strength. Having increased vertebral strength is beneficial in preventing subsidence of interbody cages but does not necessarily imply that alendronate is necessary postoperatively. It may be more important in this case as a preoperative intervention if possible.

There are also concerns about the postoperative effect of alendronate on spinal fusion rate. Naghama et al⁹ found favorable outcomes with the use of alendronate and posterior spinal fusion with interbody cages. Radiographic results showed that

alendronate enhanced bridging bone formation and increased fusion rates. The authors also found that cage subsidence and subsequent vertebral fractures were prevented by the use of alendronate.

Our study had similar findings with regard to subsidence, showing a decreased tendency for subsidence with the use of alendronate. This was most likely prevented by decreased end plate bone resorption around the implants in the immediate postoperative period. The ideal use of alendronate with regard to spinal fusion surgery would be in osteoporotic patients preoperatively and postoperatively and possibly in all LLIF postoperatively where there is concern for subsidence. A larger, randomized prospective controlled trial would need to be performed to make the above conclusion. The study would ideally include a longer follow-up, clinical outcome scores, and an evaluation of fusion rates.

It is also noted that in this study, we found a significant decrease in subsidence at the L4-5 level with alendronate but not at the L3-4 level. This may be attributed to the fact that the L4 vertebra has the highest compression strength, over 8000 N, as opposed to just over 5500 N for L5.^{22,23} So the L4 vertebra at the caudal position may absorb more force at baseline, demonstrating less subsidence at the L3-4 level in our study, and with the decreased compression strength of the L5 vertebra, it may be more susceptible to the subsidence that occurred in the control group. Therefore, the alendronate may have helped to improve the L5 vertebra compression strength.

Another important finding pertains to catastrophic subsidence after stand-alone LLIF. All LLIF cages on the market are currently indicated with supplemental transpedicular screw fixation. However, many surgeons perform stand-alone LLIF with good results.^{6,24} Catastrophic subsidence occurs when vertebral end plate fracture results in loss of indirect decompression and requires reoperation to relieve the patient's pain. In this study, no patient treated with alendronate had catastrophic subsidence, while 3 in the control group did. While this finding was not statistically significant, it implies a possible relationship that may be investigated in future prospective studies.

Some of the limitations of this study include sample size and evaluation of subsidence by 1 viewer. However, this study does provide some preliminary information about success of medical

adjuvant therapy for prevention of subsidence after LLIF. Further studies with a larger, randomized population need to be performed before changing the practice patterns.

CONCLUSIONS

A clear reduction in subsidence was found with the use of postoperative alendronate in patients undergoing L4-5 LLIF. Alendronate had a significant decrease in subsidence at L4-5 after 10–12 months as compared to the control group. Additionally, no patients treated with alendronate had catastrophic subsidence. These data suggest the need for further study on the role of alendronate in the prevention of subsidence after LLIF.

ACKNOWLEDGMENTS

We would like to thank Dr Munish Gupta for his constructive feedback.

REFERENCES

1. Epstein JA, Epstein BS, Jones MD. Symptomatic lumbar scoliosis with degenerative changes in the elderly. *Spine (Phila Pa 1976)*. 1979;4(6):542–547.
2. Robin GC, Span Y, Steinberg R, Makin M, Menczel J. Scoliosis in the elderly: a follow-up study. *Spine (Phila Pa 1976)*. 1982;7(4):355–359.
3. Meals C, Yu W, Haines C, O'Brien J. Degenerative scoliosis and stenosis—surgical management. *Semin Spine Surg*. 2013;25(4):263–273.
4. Rodgers WB, Gerber EJ, Rodgers JA. Lumbar fusion in octogenarians: the promise of minimally invasive surgery. *Spine (Phila Pa 1976)*. 2010;35(suppl 26):S355–S360. <https://doi.org/10.1097/BRS.0b013e3182023796>.
5. Phillips FM, Isaacs RE, Rodgers WB, et al. Adult degenerative scoliosis treated with XLIF: clinical and radiographical results of a prospective multicenter study with 24-month follow-up. *Spine (Phila Pa 1976)*. 2013;38(21):1853–1861. <https://doi.org/10.1097/BRS.0b013e3182a43f0b>.
6. Ozgur BM, Aryan HE, Pimenta L, Taylor WR. Extreme lateral interbody fusion (XLIF): a novel surgical technique for anterior lumbar interbody fusion. *Spine J*. 2006;6(4):435–443. <https://doi.org/10.1016/j.spinee.2005.08.012>.
7. Le TV, Baaj AA, Dakwar E, et al. Subsidence of polyetheretherketone intervertebral cages in minimally invasive lateral retroperitoneal transpsoas lumbar interbody fusion. *Spine (Phila Pa 1976)*. 2012;37(14):1268–1273. <https://doi.org/10.1097/BRS.0b013e3182458b2f>.
8. Oliveira L, Marchi L, Coutinho E, Abdala N, Pimienta L. The use of rh-bMP2 in Standalone eXtreme Lateral interbody Fusion (XLiF®): clinical and radiological results after 24 months follow-up. *WScJ*. 1(January 2010):19–25.
9. Nagahama K, Kanayama M, Togawa D, Hashimoto T, Minami A. Does alendronate disturb the healing process of posterior lumbar interbody fusion? A prospective randomized trial: clinical article. *J Neurosurg: Spine*. 2011;14(4):500–507. <https://doi.org/10.3171/2010.11.SPINE10245>.
10. Nakao S, Minamide A, Kawakami M, Boden SD, Yoshida M. The influence of alendronate on spine fusion in an osteoporotic animal model. *Spine*. 2011;36(18):1446–1452. <https://doi.org/10.1097/BRS.0b013e3181f49c47>.
11. Melton LJ III. How many women have osteoporosis now? *J Bone Miner Res*. 1995;10(2):175–177. <https://doi.org/10.1002/jbmr.5650100202>.
12. Kalichman L, Cole R, Kim DH, et al. Spinal stenosis prevalence and association with symptoms: the Framingham Study. *Spine J*. 2009;9(7):545–550. <https://doi.org/10.1016/j.spinee.2009.03.005>.
13. Vanderpool DW, James JIP, Wynne-Davies R. Scoliosis in the elderly. *J Bone Joint Surg Am*. 1969;51(3):446–455.
14. Thevenon A, Pollez B, Cantegrit F, Tison-Muchery F, Marchandise X, Duquesnoy B. Relationship between kyphosis, scoliosis, and osteoporosis in the elderly population. *Spine (Phila Pa 1976)*. 1987;12(8):744–745.
15. Bergin PF, O'Brien JR, Matteini LE, Yu WD, Kebaish KM. The use of spinal osteotomy in the treatment of spinal deformity. *Orthopedics*. 2010;33(8):586–594. <https://doi.org/10.3928/01477447-20100625-22>.
16. Isaacs RE, Hyde J, Goodrich JA, Rodgers WB, Phillips FM. A prospective, nonrandomized, multicenter evaluation of extreme lateral interbody fusion for the treatment of adult degenerative scoliosis: perioperative outcomes and complications. *Spine (Phila Pa 1976)*. 2010;35(suppl 26):S322–S330. <https://doi.org/10.1097/BRS.0b013e3182022e04>.
17. Eck JC, Hodges S, Humphreys SC. Minimally invasive lumbar spinal fusion. *J Am Acad Orthop Surg*. 2007;15(6):321–329.
18. Closkey RF, Parsons JR, Lee CK, Blacksin MF, Zimmerman MC. Mechanics of interbody spinal fusion. Analysis of critical bone graft area. *Spine (Phila Pa 1976)*. 1993;18(8):1011–1015.
19. Hou Y, Luo Z. A study on the structural properties of the lumbar endplate: histological structure, the effect of bone density, and spinal level. *Spine (Phila Pa 1976)*. 2009;34(12):E427–E433. <https://doi.org/10.1097/BRS.0b013e3181a2ea0a>.
20. Grant JP, Oxland TR, Dvorak MF. Mapping the structural properties of the lumbosacral vertebral endplates. *Spine (Phila Pa 1976)*. 2001;26(8):889–896.
21. Imai K, Ohnishi I, Matsumoto T, Yamamoto S, Nakamura K. Assessment of vertebral fracture risk and therapeutic effects of alendronate in postmenopausal women using a quantitative computed tomography-based nonlinear finite element method. *Osteoporos Int*. 2009;20(5):801–810. <https://doi.org/10.1007/s00198-008-0750-8>.
22. Bell GH, Dunbar O, Beck JS, Gibb A. Variations in strength of vertebrae with age and their relation to osteoporosis. *Calc Tis Res*. 1967;1(1):75–86. <https://doi.org/10.1007/BF02008077>.
23. Herkowitz HN. *The Spine*. Philadelphia, Pa: Saunders/Elsevier; 2011. Available at: <http://www.clinicalkey.com/dura/browse/bookChapter/3-s2.0-C20091590144>. Accessed March 23, 2014.
24. Oliveira L, Marchi L, Coutinho E, Pimenta L. A radiographic assessment of the ability of the extreme lateral

interbody fusion procedure to indirectly decompress the neural elements. *Spine (Phila Pa 1976)*. 2010;35(suppl 26):S331–S337. <https://doi.org/10.1097/BRS.0b013e3182022db0>.

Disclosures and COI: Authors Samtani, Bernatz, Harrison, Roy, and Gupta report no conflicts of interest. Dr O'Brien has the following disclosures (available on AAOS website):

Alphatec Spine: Stock or stock options

Globus: IP royalties

Globus Medical: Paid consultant; research support

K2M: Stock or stock options

Medtronic: Paid consultant; research support

Nuvasive: IP royalties

Regeneration Technologies, Inc; IP royalties; paid consultant; research support; stock or stock options

Spinicity/ISD: Stock or stock options

Corresponding Author: James Bernatz, MD, 1685 Highland Avenue, MFCB, 6th Floor, Madison, WI 53705. Phone: (608) 263-3178; Email: jbernatz@uwhealth.org.

Published 0 Month 2019

This manuscript is generously published free of charge by ISASS, the International Society for the Advancement of Spine Surgery. Copyright © 2019 ISASS. To see more or order reprints or permissions, see <http://ijssurgery.com>.