

## Iatrogenic Cervical Nerve Root Injury After Spine Surgery: How Nerve Surgeons Can Assist Spine Surgeons

Mohammadreza Emamhadi, Mohammad Haghani Dogahe and Amirreza Emamhadi

*Int J Spine Surg* published online 28 June 2022  
<https://www.ijssurgery.com/content/early/2022/06/26/8323>

This information is current as of May 17, 2025.

---

**Email Alerts** Receive free email-alerts when new articles cite this article. Sign up at:  
<http://ijssurgery.com/alerts>

# Iatrogenic Cervical Nerve Root Injury After Spine Surgery: How Nerve Surgeons Can Assist Spine Surgeons

MOHAMMADREZA EMAMHADI, MD<sup>1,2</sup>; MOHAMMAD HAGHANI DOGAHE, MD<sup>2</sup>; AND AMIRREZA EMAMHADI, MD<sup>2</sup>

<sup>1</sup>Department of Neurosurgery, Guilan University of Medical Sciences, Rasht, Iran; <sup>2</sup>Brachial Plexus and Peripheral Nerve Injury Center, Rasht, Iran

## ABSTRACT

**Background:** Iatrogenic cervical nerve root injury may occur during cervical spine surgeries, which leads to upper limb palsy. The question of how a permanent iatrogenic upper limb palsy would be managed remains unclear. Recent developments of nerve transfer have led to a considerable interest in its applications. This study outlines a new reconstructive approach for upper limb palsy following cervical spine surgery using nerve transfer.

**Methods:** In an attempt to reconstruct iatrogenic upper limb palsy, we performed nerve transfer in 4 patients with permanently lost functions. Medical Research Council Scale for Muscle Strength was used to assess muscle strength. Electromyography was performed to assess the reinnervation of the target muscles.

**Results:** All patients underwent surgery between 7 and 12 months after primary injury. Spinal accessory nerve to suprascapular nerve transfer with or without transferring the long head of triceps branch of the radial nerve to anterior branch of the axillary nerve was used to reconstruct shoulder abduction in 2 patients. Double fascicular nerve transfer (a fascicle of the ulnar nerve to biceps branch and a fascicle of the median nerve to brachialis branch of the musculocutaneous nerve) was used to reconstruct elbow flexion in 3 patients. One patient had lost both his elbow flexion and shoulder abduction. After a mean of 10 months of follow-up, all patients improved to a muscle strength of M4 without donor deficit.

**Conclusion:** In our view, these results represent an excellent initial step toward the treatment of iatrogenic nerve root injury after spine surgery.

**Level of Evidence:** 4.

Complications

Keywords: cervical spine, surgery, complication, C5 palsy, reconstructive surgery, nerve transfer

## INTRODUCTION

Although generally successful, both anterior and posterior cervical spine surgery may also lead to life-changing neurological complications. Evidence suggests that more than 38.8% of neurological complications arising from the C5 segment, and after that, C8, C7, C6, or multisegment involvement may occur, respectively.<sup>1</sup>

C5 root is at higher risk of iatrogenic injury due to its direct and short course as it exits the spinal cord.<sup>2</sup> Deterioration in muscle power of the deltoid with or without the involvement of the biceps muscle is a dominant sign but may also have sensory changes and radicular pain.<sup>3</sup> Of note, due to the close proximity between C5 and C6 roots (upper trunk), iatrogenic injuries are sometimes simultaneous. C6 root injury may result in weakness of elbow flexion, forearm supination, and wrist extension.<sup>4,5</sup>

Injury to C7-T1 or C8 and T1 roots is a rare entity in spine surgery in which shoulder and elbow motions are normal. However, marked weakness of the hand may occur.<sup>6</sup>

The literature emphasizes that such weaknesses are usually transient, and most patients will achieve a full

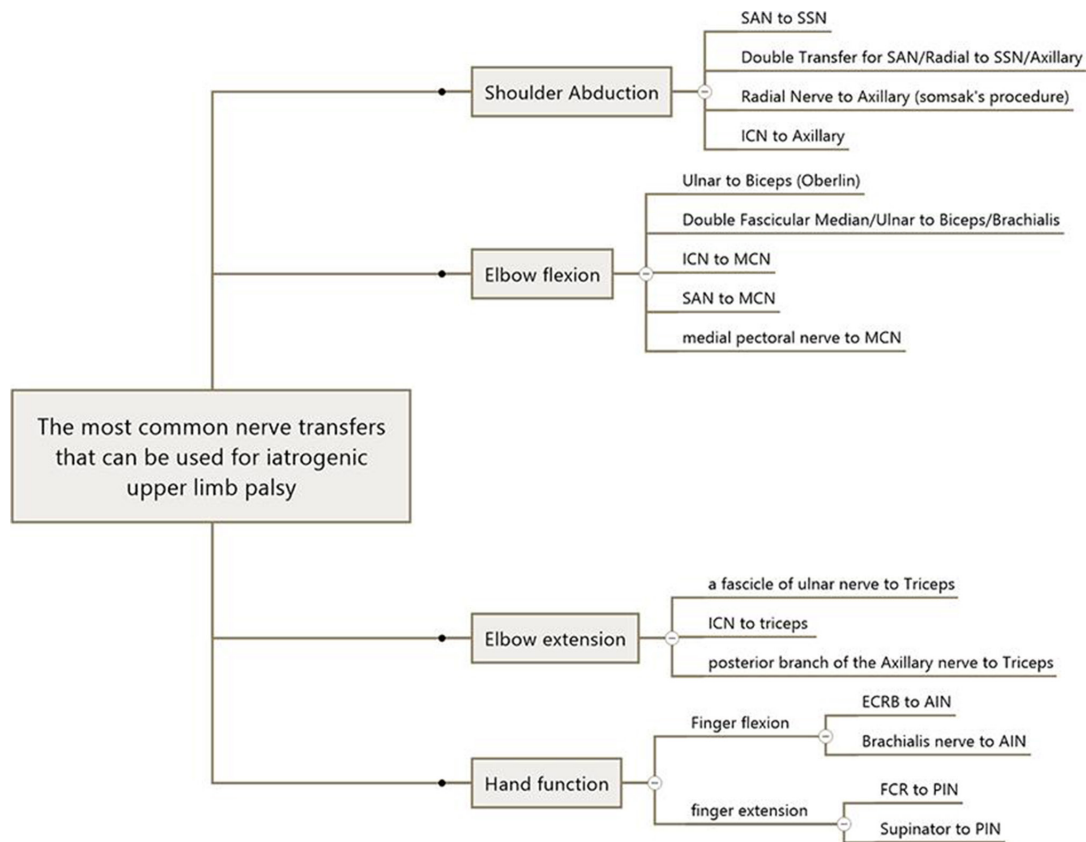
recovery within 2 years. Nevertheless, the question regarding management of a permanent iatrogenic upper limb palsy remains debated.<sup>7</sup>

In permanent neurological deficits or progressive muscle atrophy, reconstructive surgery by nerve transfer would be considered based on the neurological examination.<sup>8,9</sup> In the setting of the iatrogenic cervical nerve root injuries, restoration of the elbow flexion and the shoulder function has higher priority to control antigravity movements.<sup>9</sup>

In this study, we report the use of nerve transfers to restore lost functions in 4 cases with different nerve root injuries. In addition, we have addressed the question of how nerve transfer can help patients with iatrogenic cervical root palsy. In this regard, a variety of nerve transfers based on the pattern of paralysis are introduced (Figure 1).

## METHODS

Four patients with upper limb palsy after cervical spine surgery were referred to our center. All patients underwent clinical assessment for muscle strength of the upper limb according to Medical Research



**Figure 1.** The most common nerve transfers that can be performed to treat patients with permanent upper limb palsy after cervical spine surgery. SAN, spinal accessory nerve; SSN, suprascapular nerve; ICN, intercostal nerve; MCN, musculocutaneous nerve; ECRB, extensor carpi radialis brevis branch of radial nerve; AIN, anterior interosseous nerve; FCR, flexor carpi radialis branch of median nerve; PIN, posterior interosseous nerve. Supinator, supinator branch of radial nerve. Brachialis nerve, a branch of the musculocutaneous nerve that innervates brachialis muscle.

Council (MRC) Scale for Muscle Strength to recognize the extent and degree of injury. Preoperative physical examination revealed no muscle function in the territory of the injured nerve roots, and electromyography findings showed no muscle reinnervation.

Surgery was recommended for patients who had no signs of clinical recovery or poor reinnervation on electromyography despite at least 7 months of physiotherapy. Distal nerve transfer was performed to regain lost functions based on motor deficits in the upper extremity. Subsequently, physiotherapy continued for the patient 1 month after surgery.

## RESULTS

A total of 5 nerve transfers were performed in 4 patients. Of the 4 patients, 3 were men and 1 was a woman, ranging between 28 and 42 years of age (mean, 36.5). The causes of injury were posterior laminectomy in 3 cases and anterior decompression in 1 case.

The indications for primary surgery were cervical spinal instability due to traumatic injuries in 2 patients and cervical canal stenosis in 1 patient who underwent

posterior laminectomy and in 1 patient whom underwent anterior discectomy for disc herniation. All patients had intact upper limb function before the surgery, so we considered the deficits to be complications of the surgery.

One patient had lost his shoulder abduction above 30°, suggestive of intact suprascapular nerve (SSN) (case 1). Two patients (cases 2 and 3) were referred with loss of elbow flexion as a complication of posterior laminectomy. The fourth patient suffered from loss of both shoulder abduction and elbow flexion after posterior laminectomy (case 4). The Table demonstrates demographics, surgical information, and outcome data for the patients.

Restoration of shoulder abduction was achieved by nerve transfer. In this regard, 1 patient underwent long head of triceps branch of the radial nerve transfer to the anterior branch of the axillary nerve (case 1), and 1 patient underwent both long head of triceps branch of the radial nerve transfer to the anterior branch of the axillary nerve and spinal accessory nerve (SAN) transfer to the SSN (case 4) (Figure 2).

**Table.** Clinical findings and nerve transfers of the patients with iatrogenic cervical spine surgery.

Case	Age, y/ Gender	Cause	Preoperative Loss of Function	Time From Injury to Surgery, mo	Surgery (Nerve Transfer)	Postoperative Muscle Force	Postoperative Follow-Up, mo
1	40/M	Anterior discectomy	Shoulder abduction after 30°	7	LHT to ant AxN	M4	9
2	36/F	Posterior laminectomy	Elbow flexion	9	Double fascicular nerve transfer	M4	7
3	28/M	Posterior laminectomy	Elbow flexion	9	Double fascicular nerve transfer	M4	12
4	42/M	Posterior laminectomy	Shoulder abduction and elbow flexion	12	Spinal accessory nerve to suprascapular nerve LHT to anterior AxN Double fascicular nerve transfer	M4	12

Abbreviations: Ant AxN, anterior branch of axillary nerve; LHT, long head of triceps branch of radial nerve.

Note: **Double fascicular nerve transfer**, an ulnar nerve fascicle to the biceps motor branch and a fascicle of median nerve to brachialis motor branch of musculocutaneous nerve.

In case of lost elbow flexion, double fascicular nerve transfer (a fascicle of ulnar nerve transfer to biceps branch and a fascicle of median nerve transfer to brachialis branch of the musculocutaneous nerve) was done (cases 2, 3, and 4). After a mean of 10 months follow-up, the patients who underwent an operation for lost shoulder abduction (cases 1 and 4) both achieved MRC grade 4/5 for shoulder abduction. Moreover, all the patients who underwent reconstructive surgery for lost elbow flexion (cases 2, 3, and 4) regained biceps and brachialis muscle strength MRC grade 4/5 (Figure 3).

## DISCUSSION

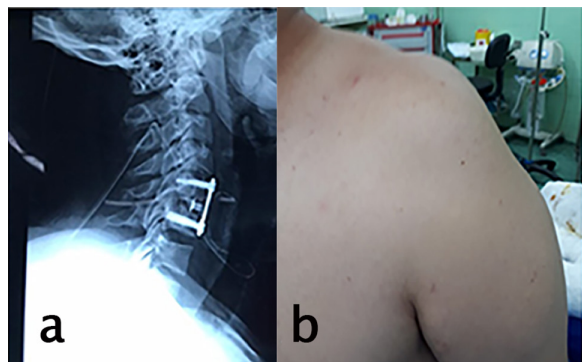
In cases of iatrogenic cervical nerve root injury, nerve grafting is impossible. In such cases, nerve transfer can provide a solution to have an active shoulder abduction and elbow flexion.<sup>10</sup> The originality of this study is to explore the availability of nerve transfer in iatrogenic cervical nerve root injuries. Our results offer compelling evidence for the application of nerve transfer in iatrogenic nerve root palsies. Considering most of the iatrogenic nerve root injuries occur in midcervical roots, including C5 and C6, reconstruction of shoulder

abduction and elbow flexion has higher priority in the setting of iatrogenic nerve root palsy.

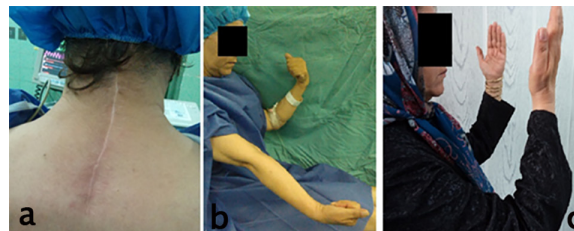### Reconstruction of Shoulder Abduction

Shoulder abduction is initiated by supraspinatus. After 15°, the supraspinatus muscle helps the deltoid with the abduction of the arm up to 90°. <sup>11</sup> For restoration of shoulder function, donor nerves that have been used include the SAN, intercostal nerves and triceps branches, thoracodorsal nerve, phrenic nerve, and medial pectoral nerve. <sup>9,12,13</sup> The 2 most commonly used nerve transfers to restore the shoulder abduction are SAN transfer to the SSN and the long head of the triceps branch transfer to the axillary nerve.

To the best of our knowledge, Afshari et al reported the only case regarding the use of nerve transfer in iatrogenic nerve root injuries. <sup>8</sup> Their case was a 46-year-old man who underwent C3-C4 and C4-C5 right-sided foraminotomies due to the right foraminal stenosis. Postoperatively, the patient developed severe weakness in the right arm and shoulder and altered sensation in the shoulder area. Nerve transfer was considered 6 months after spinal surgery because of permanent neurological deficits. The medial head of the triceps nerve branch of the radial nerve was transferred to the axillary nerve to reinnervate deltoid and teres minor. At 5-month



**Figure 2.** (a) Lateral neck x-ray images after anterior decompression for cervical disc herniation; (b) deltoid muscle atrophy after surgery.



**Figure 3.** (a), (b) Preoperative examination showed loss of right elbow flexion after posterior laminectomy for the cervical spinal canal stenosis, (c) postoperative examination after double fascicular nerve transfer.

follow-up, full forward flexion and lateral elevation of the shoulder were reported. The results of this article strengthened our confidence in applying for nerve transfer in patients with iatrogenic cervical nerve root injuries. The SAN is a vital donor, which can be used for transferring to SSN. Moreover, it can be transferred with an interpositional nerve graft to the musculocutaneous or the axillary nerve.

Leechavengvongs et al published results of nerve transfer to deltoid muscle using the nerve to the long head of the triceps in 7 patients with brachial plexus injuries. Recovery in all of their patients (deltoid muscle MRC grade 4) showed that the aforementioned technique is a promising option to restore shoulder function.<sup>13</sup> Considering that the triceps action is synergistic with shoulder abduction, using 1 branch of triceps muscle (long head or medial head) is an excellent choice as a donor nerve. Among the 3 heads of the triceps muscle, the branch to the long head of the triceps has the largest diameter and highest number of motor axons. On the other hand, this branch has the least importance for elbow extension.<sup>14</sup> We used double nerve transfers for shoulder function (SAN to SSN and radial to axillary nerve) in 1 case because of loss of function in both supraspinatus and deltoid. Concomitant reconstruction of both the axillary nerve and SSN improves the shoulder function.

### Reconstruction of Elbow Flexion

In the absence of elbow flexion after cervical spine surgery, the donor nerves that can be transferred include the intercostal nerve, ulnar nerve (Oberlin procedure), SAN, and medial pectoral nerve.<sup>15-18</sup> We performed a double fascicular nerve transfer (a fascicle of the ulnar nerve to the biceps branch and a fascicle of the median nerve to the brachialis branch of the musculocutaneous nerve) to restore elbow flexion in 3 patients with iatrogenic cervical nerve root injury.

Comparing the results of published literature using the abovementioned potential donor nerves demonstrates that using the ulnar nerve (Oberlin procedure) is associated with better outcomes.<sup>19</sup> Satisfactory outcomes of the Oberlin procedure in patients with acute flaccid myelitis<sup>20</sup> and transverse myelitis<sup>21</sup> support the idea that this procedure can also be helpful in iatrogenic cervical nerve root injuries.

Advantages of using the ulnar nerve as a donor include a better and quicker recovery of elbow flexion and less invasive surgery, which make it the donor of choice for biceps reinnervation comparing other nerve transfers.<sup>5,22</sup> However, Martins et al showed that using an ulnar transfer alone (Oberlin procedure) provides

outcomes equivalent to double fascicular nerve transfer, we considered double fascicular nerve transfer for our patient.<sup>23</sup> Our results demonstrated the effectiveness of double fascicular nerve transfer in reconstructing upper limb palsy. More studies are necessary to compare double fascicular nerve transfer and Oberlin procedure in the setting of iatrogenic nerve root palsy.

### Reconstruction of Elbow Extension

Loss of elbow extension is rarely seen as a consequence of spine surgery. Elbow extension has been given a lower priority comparing shoulder abduction and elbow flexion because the passive elbow extension is achieved by gravity. To restore elbow extension, the potential donor nerves include the intercostal nerves, posterior branch of the axillary nerve, and ulnar nerve fascicle.<sup>24,25</sup> We recommend transferring a fascicle of the ulnar nerve to the long head of triceps branches of the radial nerve to restore elbow extension.

### Reconstruction of Hand Function

Hand function may be impaired in C7-T1 nerve root injuries but is rarely seen as a complication of cervical spine surgery; if so, this condition can also be restored by nerve transfer (Figure 1). In our study, an improvement in the lost functions of the upper extremity due to spine surgery supports the efficacy of nerve transfer for the treatment of iatrogenic nerve root injuries. Despite the effectiveness, the timing of the nerve transfer reconstruction is still challenging. Generally, a significant motor deficit with repeated clinical examinations and no recovery in neurophysiological studies indicates that surgical intervention should be considered. In cases without useful muscle function, motor nerve transfer is recommended 6 to 12 months after the injury to promote muscle function.<sup>8,9</sup>

## CONCLUSION

This study shows preliminary success of nerve transfer as a possible solution for patients with postoperative root injury after cervical operations. Further studies are needed to establish the long-term outcomes of different potential nerve transfers in this field.

## REFERENCES

1. Hasegawa K, Homma T, Chiba Y. Upper extremity palsy following cervical decompression surgery results from a transient spinal cord lesion. *Spine*. 2007;32(6):E197-202. doi:10.1097/01.brs.0000257576.84646.49

2. Uematsu Y, Tokuhashi Y, Matsuzaki H. Radiculopathy after laminoplasty of the cervical spine. *Spine*. 1998;23(19):2057–2062. doi:10.1097/00007632-199810010-00004
3. Pan F-M, Wang S-J, Ma B, Wu D-S. C5 nerve root palsy after posterior cervical spine surgery. *J Orthop Surg*. 2017;25(1):2309499016684502. doi:10.1177/2309499016684502
4. Emamhadi M, Haghani Dogahe M, Gohritz A. Nerve transfers in tetraplegia: a review and practical guide. *J Neurosurg Sci*. 2021;65(4):431–441. doi:10.23736/S0390-5616.21.05312-1
5. Ali ZS, Heuer GG, Faught RWF, et al. Upper brachial plexus injury in adults: comparative effectiveness of different repair techniques. *J Neurosurg*. 2015;122(1):195–201. doi:10.3171/2014.9.JNS132823
6. Goubier J-N, Teboul F. Management of hand palsies in isolated C7 to T1 or C8, T1 root avulsions. *Tech Hand Up Extrem Surg*. 2008;12(3):156–160. doi:10.1097/BTH.0b013e318172d72b
7. Guzman JZ, Baird EO, Fields AC, et al. C5 nerve root palsy following decompression of the cervical spine: a systematic evaluation of the literature. *Bone Joint J*. 2014;96-B(7):950–955. doi:10.1302/0301-620X.96B7.33665
8. Afshari FT, Hossain T, Miller C, Power DM. Salvage of cervical motor radiculopathy using peripheral nerve transfer reconstruction. *Br J Neurosurg*. 2019;33(3):315–319. doi:10.1080/02688697.2018.1472211
9. Ray WZ, Chang J, Hawasli A, Wilson TJ, Yang L. Motor nerve transfers: a comprehensive review. *Neurosurgery*. 2016;78(1):1–26. doi:10.1227/NEU.0000000000001029
10. Noaman HH, Shiha AE, Bahm J. Oberlin's ulnar nerve transfer to the biceps motor nerve in obstetric brachial plexus palsy: indications, and good and bad results. *Microsurgery*. 2004;24(3):182–187. doi:10.1002/micr.20037
11. Lam JH, Bordoni B. Anatomy, shoulder and upper limb, arm abductor muscles. In: *StatPearls*. Treasure Island (FL): StatPearls Publishing; 2021.
12. Hu S, Chu B, Song J, Chen L. Anatomic study of the intercostal nerve transfer to the suprascapular nerve and a case report. *J Hand Surg Eur Vol*. 2014;39(2):194–198. doi:10.1177/1753193413475963
13. Leechavengvongs S, Witoonchart K, Uerpairojit C, Thuvasethakul P. Nerve transfer to deltoid muscle using the nerve to the long head of the triceps, part II: a report of 7 cases. *J Hand Surg Am*. 2003;28(4):633–638. doi:10.1016/s0363-5023(03)00199-0
14. Lee J-Y, Kircher MF, Spinner RJ, Bishop AT, Shin AY. Factors affecting outcome of triceps motor branch transfer for isolated axillary nerve injury. *J Hand Surg Am*. 2012;37(11):2350–2356. doi:10.1016/j.jhsa.2012.07.030
15. Wellons JC, Tubbs RS, Pugh JA, Bradley NJ, Law CR, Grabb PA. Medial pectoral nerve to musculocutaneous nerve neurotization for the treatment of persistent birth-related brachial plexus palsy: an 11-year institutional experience. *J Neurosurg Pediatr*. 2009;3(5):348–353. doi:10.3171/2008.11.PEDS08166
16. Merrell GA, Barrie KA, Katz DL, Wolfe SW. Results of nerve transfer techniques for restoration of shoulder and elbow function in the context of a meta-analysis of the English literature. *J Hand Surg Am*. 2001;26(2):303–314. doi:10.1053/jhsu.2001.21518
17. Cho ÁB, Ferreira CHV, Towata F, Almeida GC, Sorrenti L, Kiyohara LY. Feasibility of the oberlin procedure in late presentation cases of C5-C6 and C5-C7 brachial plexus injuries in adults. *Hand (NY)*. 2022;17(2):214–218. doi:10.1177/1558944720918325
18. Chepla KJ, Bafus BT. Transfer of a radial nerve branch to the brachialis nerve for restoration of elbow flexion. *Tech Hand Up Extrem Surg*. 2018;22(2):65–67. doi:10.1097/BTH.0000000000000186
19. Emamhadi M, Behzadnia H, Zamanidou M, et al. Intercostal or ulnar nerve: which donor nerve is to be used for reanimation of elbow flexion? *Musculoskelet Surg*. 2021;105(2):183–188. doi:10.1007/s12306-020-00653-z
20. Heise CO, de Oliveira AJ, Bhering T, et al. Nerve transfers for acute flaccid myelitis: a case series. *Childs Nerv Syst*. 2021;37(1):211–215. doi:10.1007/s00381-020-04773-6
21. Dorsi MJ, Belzberg AJ. Nerve transfers for restoration of upper extremity motor function in a child with upper extremity motor deficits due to transverse myelitis: case report. *Microsurgery*. 2012;32(1):64–67. doi:10.1002/micr.20939
22. Nagano Y, Kawamura D, Terkawi A, Urita A, Matsui Y, Iwasaki N. Minimum ten-year outcomes of partial ulnar nerve transfer for restoration of elbow flexion in patients with upper brachial plexus injury. *J Hand Surg Asian Pac Vol*. 2019;24(3):283–288. doi:10.1142/S2424835519500358
23. Martins RS, Siqueira MG, Heise CO, Foroni L, Teixeira MJ. A prospective study comparing single and double fascicular transfer to restore elbow flexion after brachial plexus injury. *Neurosurgery*. 2013;72(5):709–714. doi:10.1227/NEU.0b013e318285c3f6
24. Palazzi S, Palazzi JL, Caceres JP. Neurotization with the brachialis muscle motor nerve. *Microsurgery*. 2006;26(4):330–333. doi:10.1002/micr.20247
25. Klika BJ, Spinner RJ, Bishop AT, Kircher MF, Shin AY. Posterior branch of the axillary nerve transfer to the lateral triceps branch for restoration of elbow extension: case report. *J Hand Surg Am*. 2013;38(6):1145–1149. doi:10.1016/j.jhsa.2013.03.044

**Funding:** The authors received no financial support for the research, authorship, and/or publication of this article.

**Declaration of Conflicting Interests:** The authors report no conflicts of interest in this work.

**Patient consent for publication:** Patients provided consent for publication of their identifiable details in relation to this study.

**Ethics Approval:** The study was approved by the institutional review board of the Guilan University of Medical Sciences Department of Neurosurgery.

**Corresponding Author:** Mohammadreza Emamhadi, Department of Neurosurgery, Guilan University of Medical Sciences, Farhang Square, Poursina Hospital, Poursina, Rasht, Iran; emamhadi42@yahoo.com

Published 24 June 2022

This manuscript is generously published free of charge by ISASS, the International Society for the Advancement of Spine Surgery. Copyright © 2022 ISASS. To see more or order reprints or permissions, see <http://ijssurgery.com>.