

Biomechanical Comparison Between Posterior Long-Segment Fixation, Short-Segment Fixation, and Short-Segment Fixation With Intermediate Screws for the Treatment of Thoracolumbar Burst Fracture: A Finite Element Analysis

Worawat Limthongkul, Nutthee Wannaratsiri, Chamaiporn Sukjamsri, Chi-na Benyajati, Pimpa Limthongkul, Teerachat Tanasansomboon, Wicharn Yingsakmongkol and Weerasak Singhatanadgige

Int J Spine Surg published online 23 January 2023
<https://www.ijssurgery.com/content/early/2023/01/22/8441>

This information is current as of May 17, 2025.

Email Alerts Receive free email-alerts when new articles cite this article. Sign up at:
<http://ijssurgery.com/alerts>

Biomechanical Comparison Between Posterior Long-Segment Fixation, Short-Segment Fixation, and Short-Segment Fixation With Intermediate Screws for the Treatment of Thoracolumbar Burst Fracture: A Finite Element Analysis

WORAWAT LIMTHONGKUL, MD^{1,2}; NUTTHEE WANNARATSIRI, MD³; CHAMAIPORN SUKJAMSRI, PhD⁴; CHI-NA BENYAJATI, PhD⁵; PIMPA LIMTHONGKUL, PhD⁵; TEERACHAT TANASANSOMBOON, MD^{2,6,7}; WICHARN YINGSAKMONGKOL, MD^{1,2}; AND WEERASAK SINGHATANADGIGE, MD, MS^{1,2}

¹Department of Orthopedics, Faculty of Medicine, Chulalongkorn University and King Chulalongkorn Memorial Hospital, Bangkok, Thailand; ²Center of Excellence in Biomechanics and Innovative Spine Surgery, Faculty of Medicine, Chulalongkorn University, Bangkok, Thailand; ³Department of Orthopedics, Chakri Naruebodindra Medical Institute, Samut Prakan, Thailand; ⁴Department of Biomedical Engineering, Faculty of Engineering, Srinakharinwirot University, Nakhon Nayok, Thailand; ⁵National Metal and Materials Technology Center, Pathumthani, Thailand; ⁶Board of Governors Regenerative Medicine Institute, Cedars-Sinai Medical Center, Los Angeles, CA, USA; ⁷Department of Orthopedic Surgery, Cedars-Sinai Medical Center, Los Angeles, CA, USA

ABSTRACT

Background: Posterior long-segment (LS) fixation, short-segment (SS) fixation, and short segment fixation with intermediate screws (SI) have shown good outcomes for the treatment of thoracolumbar burst fractures. However, limited data compared the biomechanical properties between LS fixation and SI. The purpose of this study was to compare the von Mises stresses on the pedicular screw system and bone between posterior LS fixation, SS fixation, and SI for the treatment of thoracolumbar burst fracture.

Materials and Methods: The finite element model of thoracolumbar spines from T11 to L3 was created based on the computed tomography image of a patient with a burst fracture of the L1 vertebral body. The models of pedicular screws, rods, and locking nuts were constructed based on information from the manufacturer. Three models with different fixation configurations—that is, LS, SS, and SI—were established. The axial load was applied to the superior surface of the model. The inferior surface was fixed. The stress on each screw, rod, and vertebral body was analyzed.

Results: The motion of the spine in SS (0.5 mm) and SI (0.9 mm) was higher than in LS (0.2 mm). In all models, the lowest pedicle screws are the most stressed. The stress along the connecting rods was comparable between SI and LS (50 MPa). At the fracture level, stress was found at the pedicles and vertebral bodies in SI. There was relatively little stress around the fractured vertebral body in LS and SS.

Conclusions: Posterior SI preserves more spinal motion than the LS. In addition, it provides favorable biomechanical properties than the SS. The stress that occurred around the pedicle screws in SI was the least among the 3 constructs, which might reduce complications such as implant failure. SI produces more stress in the fractured vertebral body than LS and SS, which could potentially aid in bone healing according to the Wolff law.

Clinical Relevance: SI has proved to be a biomechanically favorable construct and helps preserve the spinal motion segment. It could be an alternative surgical option for treating patients who present with thoracolumbar burst fractures.

Level of Evidence: 5.

Biomechanics

Keywords: thoracolumbar, burst fracture, short-segment, long-segment, intermediate screw

INTRODUCTION

Thoracolumbar junction is the most common site of spine injury. The incidence of these injuries is still rising according to an increasing number of high-energy traumas.¹ Although common, definitive treatment of thoracolumbar burst fracture is still controversial. In patients with stable thoracolumbar

burst fracture without neurological deficits, conservative treatment has shown an improvement in pain, functional outcome, fewer complications, length of hospital stay, and treatment cost.^{2,3} While operative treatment for unstable fracture has shown earlier improved pain, improved functional outcome, better kyphosis correction, and better neurologic recovery, the ideal surgical procedure is still disputed.^{2,3}

Many operative techniques have been described for adequate treatment of thoracolumbar burst fracture, including anterior stabilization, posterior stabilization, and combined anterior-posterior stabilization with or without fusion. As for posterior stabilization, long-segment (LS) fixation has shown better surgical and radiographic outcomes than short-segment (SS) fixation.⁴⁻⁷ However, decreased spinal range of motion from the LS fixation may lead to unfavorable results.⁸

Recently, posterior short-segment fixation with intermediate screws (SI) has been introduced, showing good biomechanical stability, kyphosis correction, and motion preservation.⁹⁻¹² Nevertheless, there are limited data comparing the biomechanical properties between LS and SI. Our study compared biomechanical parameters between posterior LS fixation, SS fixation, and SI for the treatment of thoracolumbar burst fracture by using the finite element model analysis.¹³⁻¹⁶

METHODS

This research was financially supported by a grant from Ratchadapiseksompotch Fund, Faculty of Medicine, Chulalongkorn University, Bangkok, Thailand (Grant number RA57/030). Written informed consent was waived.

Finite Element Models Generation

A model of thoracolumbar spines from T11 to L3 was created based on computed tomography images of a patient with a burst fracture of the L1 vertebral body with a McCormack score <7, according to McCormack's load sharing classification of spine fractures, using a 3-dimensional image processing software, Mimics (Materialise, 2018). The finite element model was then developed from the 3-dimensional model obtained from the computed tomography image with the meshing software, HyperMesh (Altair Engineering, USA). The finite element volume meshes, which consisted of 4-node tetrahedral elements, were generated with mesh positions to allow for force transmission and simulation of contacts between vertebral bodies and intervertebral discs inside the model. The material and anatomical properties of the vertebral bodies, intervertebral disc, and ligaments were based on the previous literature.^{14,16} The models of pedicular screws, rods, and locking nuts were constructed based on the information from the manufacturer (Medtronic, MN, USA). A finite element solver, Marc Mentat (MSC Software, USA), was used to perform all the finite element analyses in this study.

Finite Element Models Validation

The finite element models of thoracolumbar spines were tested for biomechanical properties and compared with the solid model of the thoracolumbar spine. The models of pedicular screws, rods, and locking nuts were tested for biomechanical properties and compared with the actual pedicular screws, rods, and locking nuts from the manufacturer (Medtronic, MN, USA).

Instrumentations

Three types of construct models, including LS, SS, and SI, were created and attached to the burst fracture model. The diameter of the screw was 6.5 mm, and the total length of the screw was 45 mm. The LS consisted of pedicular screws at T11 to L3, except at the L1 level. The SS consisted of pedicular screws at T12 to L2, except at the L1 level, and SI consisted of pedicular screws from T12 to L2.

Biomechanical Testing

The inferior surface of the L3 vertebral body was constrained to the surface to prevent movement in all degrees of freedom. The other vertebral bodies had no restrictions in all directions. A compressive load of 1000 N was applied to the superior surface of the T11 vertebral body, representing the physiologic load supported by the spine of a 70-kg man in a standing position.¹⁷ The highest stress and stress distribution on each pedicular screw, connecting rod, vertebral body, and pedicle were analyzed. The sagittal range of motion of the whole model was recorded.

RESULTS

Motion

Both SS and SI showed a higher sagittal range of motion than LS. Total displacement in the sagittal plane of the spine model was 0.2 mm for LS, 0.5 mm for SS fixation, and 0.9 mm for SI (Figure 1).

Stress on Pedicle Screws and Rods

The stresses that occurred along the connecting rods (Figure 2) were found to be the highest in LS and SI (50 MPa) when compared with SS (30 MPa). While the highest stress on pedicle screws was found at the lowest pedicle screw level in every model (Figures 3–7), a small difference in stress concentration on pedicle screws was found.

Stress on Bone

The highest stress on the vertebral body was observed at the lowest level in both LS and SS. The magnitude of

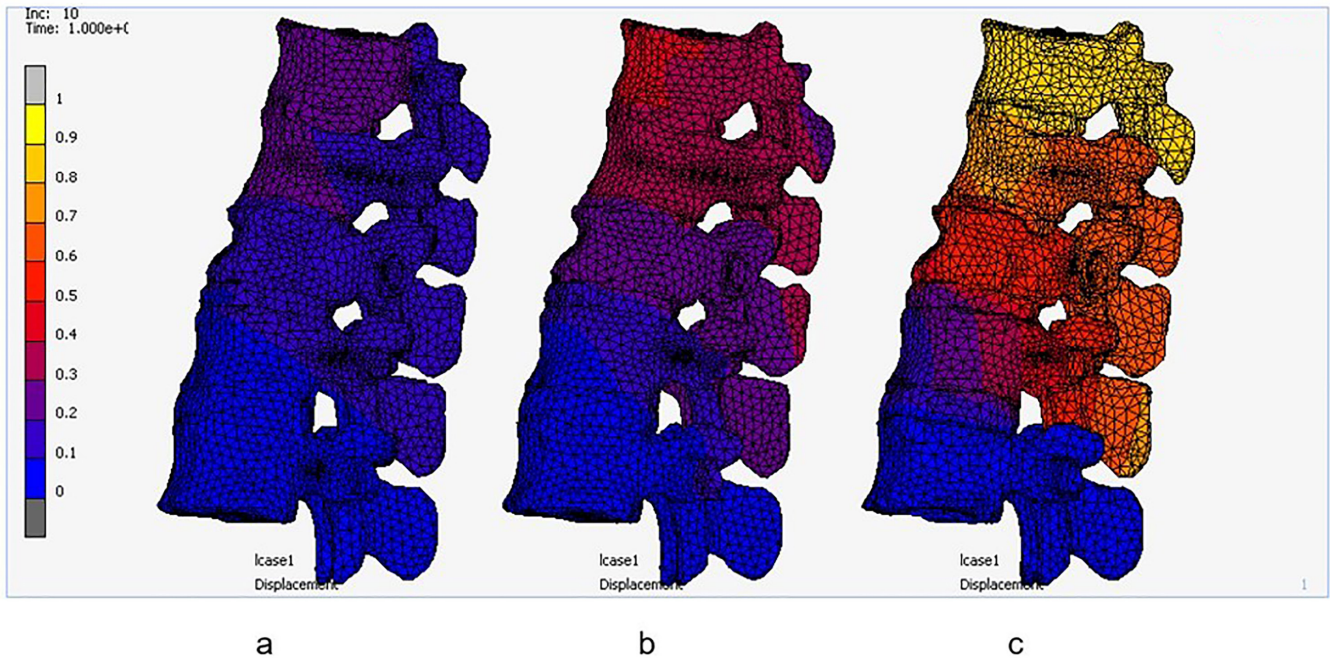


Figure 1. Total displacement after applying load (mm). (a) Long-segment fixation, (b) short-segment fixation, and (c) short-segment fixation with intermediate screws.

the resulting von Mises stress on the pedicle of LS fixation (31.56 MPa) and SS fixation (42.16 MPa) was approximately 3 to 4 times that of the resulting stress on the pedicle of SI (10.67 MPa).

vertebral body in LS and SS, whereas a noticeable amount of stress was predicted at the pedicle and the fractured vertebral body in SI.

There were some differences in the amount of stress that occurred at the fracture level (Figure 8). There was relatively little stress that occurred around the fractured

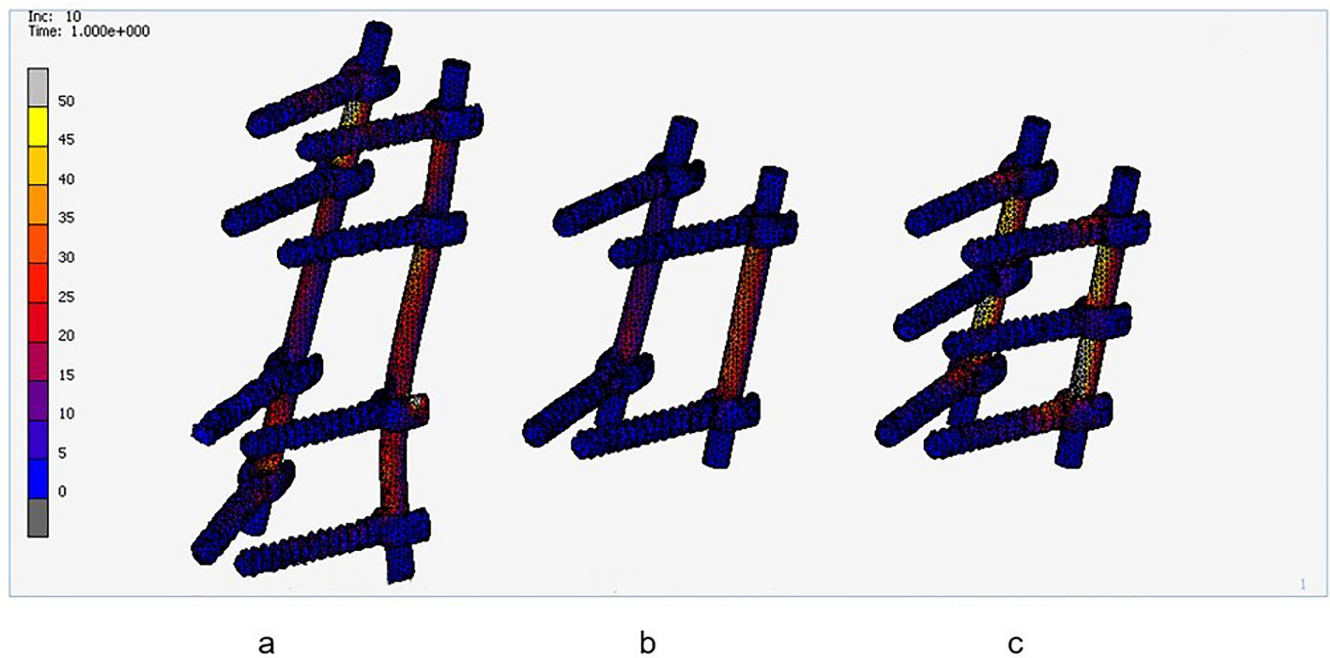


Figure 2. Stress in the rods after applying load (MPa). (a) Long-segment fixation, (b) short-segment fixation, and (c) short-segment fixation with intermediate screws.

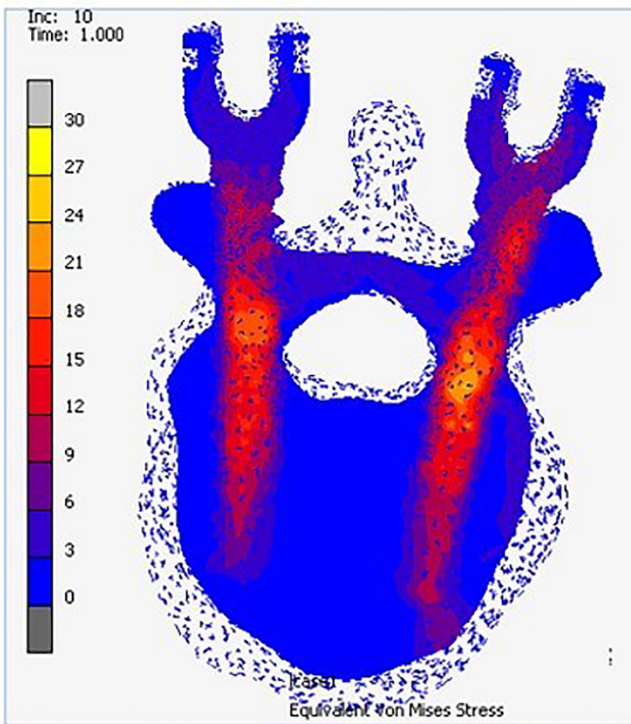


Figure 3. Stress in the T11 vertebral body after applying load (MPa) in long-segment fixation.

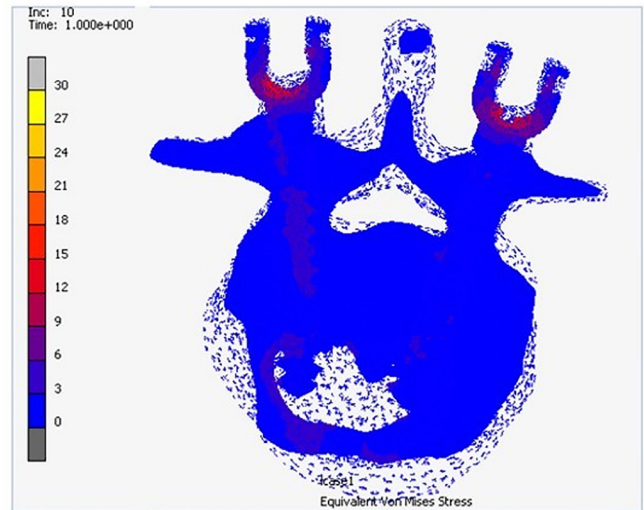


Figure 5. Stress in the L1 vertebral body after applying load (MPa) in short-segment fixation with intermediate screws.

DISCUSSION

Spinal fusion was associated with decreased spinal range of motion.⁸ The number of fusion levels was also associated with an increased risk of adjacent segment

disease.¹⁸ Lazaro et al reported a significantly restricted range of motion during extension and lateral bending after LS than the most rigid SS construct in their study.⁴ Altay et al suggested SS in patients who needed more spinal mobility.⁵ Kim et al discovered that SI is comparable with or better than LS and has the added benefit of preserving an extra mobile segment.¹² However, the study comparing the biomechanical properties between LS, SS, and SI is still limited. In our study, the models of SS and SI showed a greater range of motion than LS

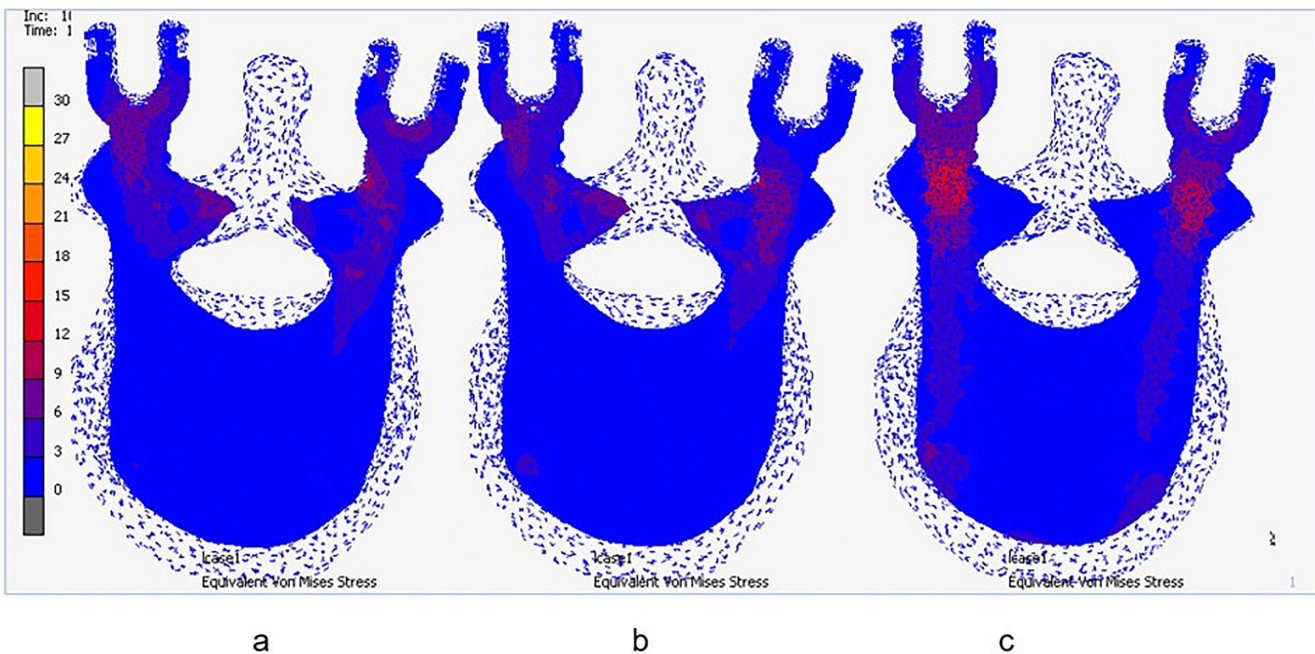


Figure 4. Stress in the T12 vertebral body after applying load (MPa). (a) Long-segment fixation, (b) short-segment fixation, and (c) short-segment fixation with intermediate screws.

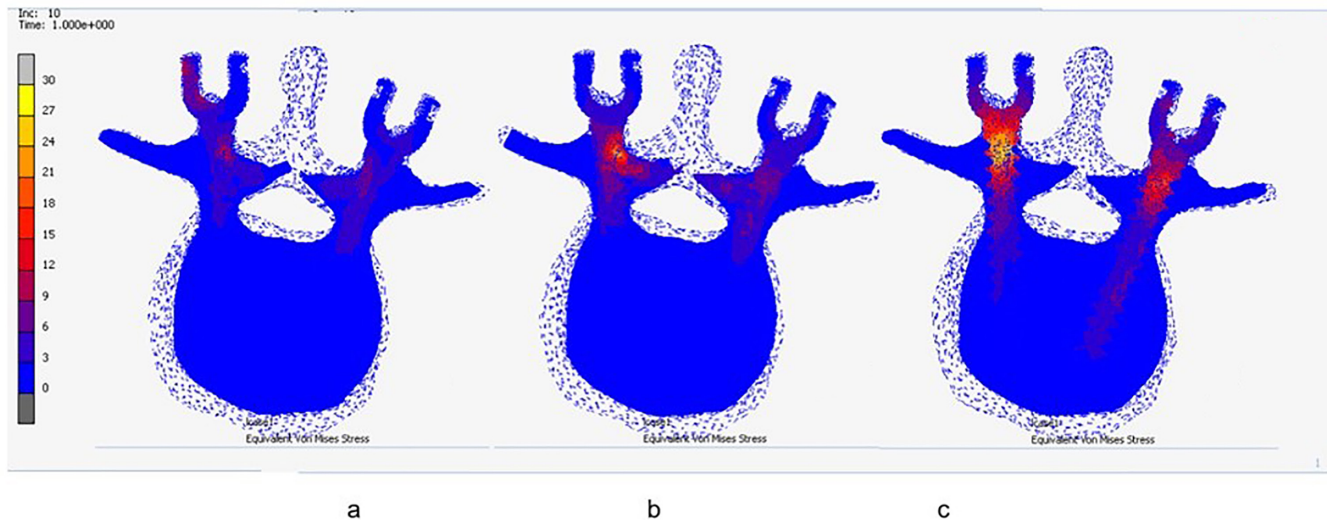


Figure 6. Stress in the L2 vertebral body after applying load (MPa). (a) Long-segment fixation, (b) short-segment fixation, and (c) short-segment fixation with intermediate screws.

under the same axial load, which could confirm that SS and SI could preserve more spinal motion than LS.

Instrumentation failure could be found after operative treatment for thoracolumbar burst fracture, especially when using posterior SS in unstable fractures. While screw bending, breakage, loosening, and backing out were the common failures of pedicle screws,^{19–21} fatigue failure was a common mode of failure for connecting rods.²² Mahar et al reported improved biomechanical stability of the construct after fixation with screws at the fracture level.⁹ Eno et al also reported a decrease in implant failure rates and reoperation rates after performing the SI compared with the SS.¹¹ In our

study, SI showed better biomechanical properties than the other fixations. The stress that occurred around the connecting rods showed no difference between LS and SI. Additionally, there was little difference in the amount of stress that occurred around the pedicular screws of the 3 models. The highest amount of stress would occur at the lowest pedicular screws. Pedicles at T12 to L5 levels could accommodate screws of 7 mm diameter.²³ Increasing the diameter of screws, withstanding higher stress, and increasing pull-out strength could also decrease the rate of instrument failure.²²

One of the complications of a thoracolumbar burst fracture that could cause pain, sagittal collapse, and neurological deficits was kyphotic deformity.²⁴ The best treatment is prevention of this complication. Altay et al reported better correction values of the Sagittal Index and canal compromise after LS when compared with SS.⁵ Tezeren et al also reported correction loss of $>10^\circ$ with a 55% implant failure rate in the SS group, whereas none of the patients had a correction loss $>10^\circ$ and there was no failure in the LS group.⁶ Sapkas et al used radiographic measurements to compare LS and SS and found better kyphotic correction in LS.⁷ Farrokhi et al reported better kyphotic correction, fewer instrument failures, and no additional complications after adding the intermediate screws when compared with SS.¹⁰ The stress on the pedicles of LS and SS was approximately 3 to 4 times higher when compared with SI. Thus, using SI may reduce the correction loss and failure rates after operative treatment in patients with thoracolumbar burst fracture. Additionally, several studies have investigated the relationship between bone fracture healing and bone mechanoregulation.^{25–27} Stresses at the fracture level,

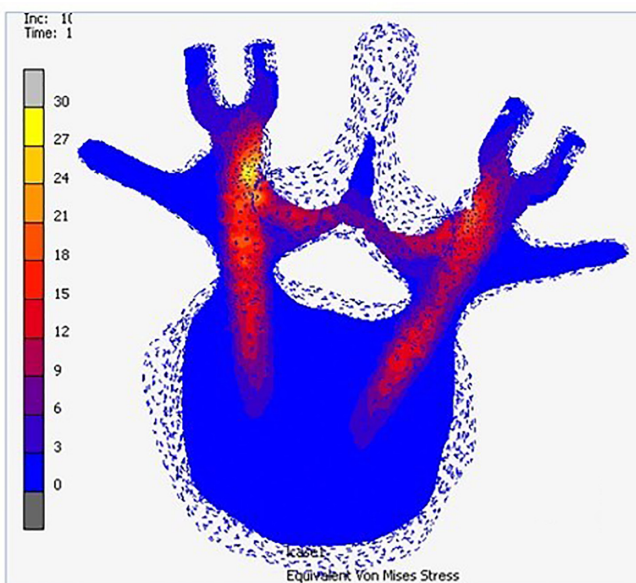


Figure 7. Stress in the L3 vertebral body after applying load (MPa) in long-segment fixation.

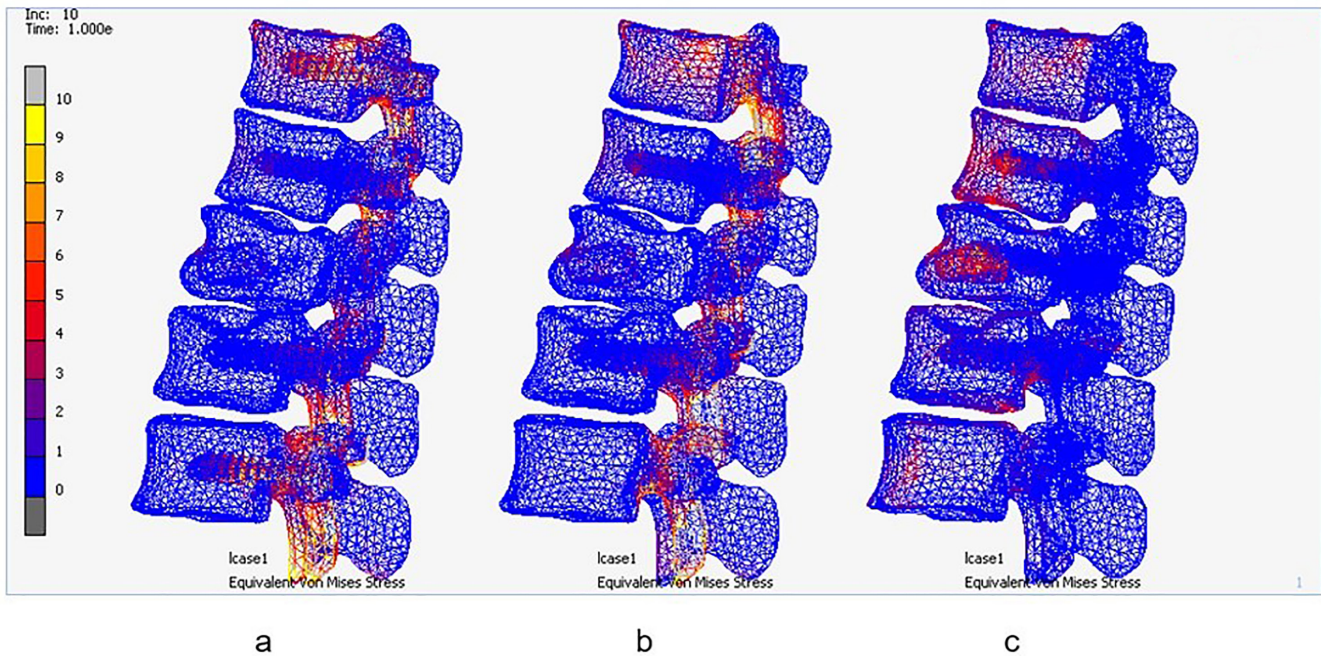


Figure 8. Stress in the bones after applying load (MPa). (a) Long-segment fixation, (b) short-segment fixation, and (c) short-segment fixation with intermediate screws.

which occurred around the pedicles and vertebral body in SI, were higher than those of LS and SS. This phenomenon would potentially aid in bone healing process according to the Wolff law.

According to this study, an operative treatment with SI in a patient with thoracolumbar burst fracture whose McCormack score is <7 would result in a stable fixation with a good spinal range of motion and low correction loss and failure rates. Nonetheless, there were some limitations to this study. First, the study design was a descriptive study. Second, the differences between the models could not be compared significantly. Third, the load applied to the models was a 1-time load that represented a normal physiologic load. The spine would be subjected to a larger and more repetitive load in everyday life than in this study. Furthermore, the sagittal motion of the models was measured after the axial load was applied, and the maximal range of motion of the models was not estimated. Last, this study compared only pedicle screw fixation systems. Other instrument systems and constructs should also be considered and studied. Further research is needed to compare and determine the best treatment for thoracolumbar burst fracture.

CONCLUSIONS

Posterior SI preserves more spinal motion than LS. In addition, it provides more favorable biomechanical

properties than SS. The stress that occurred around the pedicle screws in SI was the least among the 3 constructs, which might reduce complications such as implant failure. SI produces more stress in the fractured vertebral body than LS and SS, which could potentially aid in bone healing according to the Wolff law.

ACKNOWLEDGMENTS

The authors thank Thanachaporn Kittipibul, MD, and the Clinical Research Center at Chulalongkorn University for their support of this study.

REFERENCES

1. Reinhold M, Knop C, Beisse R, et al. Operative treatment of 733 patients with acute thoracolumbar spinal injuries: comprehensive results from the second, prospective, Internet-based multicenter study of the spine Study group of the German association of trauma surgery. *Eur Spine J.* 2010;19(10):1657–1676. doi:10.1007/s00586-010-1451-5
2. Yi L, Jingping B, Gele J, et al. Operative versus non-operative treatment for thoracolumbar burst fractures without neurological deficit. *Cochrane Database Syst Rev.* 2006;18(4):CD005079.
3. Gnanenthiran SR, Adie S, Harris IA. Nonoperative versus operative treatment for thoracolumbar burst fractures without neurologic deficit: a meta-analysis. *Clin Orthop Relat Res.* 2012;470(2):567–577. doi:10.1007/s11999-011-2157-7
4. Lazaro BCR, Deniz FE, Brasiliense LBC, et al. Biomechanics of thoracic short versus long fixation after 3-column injury. *J Neurosurg Spine.* 2011;14(2):226–234. doi:10.3171/2010.10.SPINE09785

5. Altay M, Ozkurt B, Aktekin CN, Ozturk AM, Dogan O, Tabak AY. Treatment of unstable thoracolumbar junction burst fractures with short- or long-segment posterior fixation in magerl type A fractures. *Eur Spine J*. 2007;16(8):1145–1155. doi:10.1007/s00586-007-0310-5
6. Tezeren G, Kuru I. Posterior fixation of thoracolumbar burst fracture: short-segment pedicle fixation versus long-segment instrumentation. *J Spinal Disord Tech*. 2005;18(6):485–488. doi:10.1097/01.bsd.0000149874.61397.38
7. Sapkas G, Kateros K, Papadakis SA, Brilakis E, Macheras G, Katonis P. Treatment of unstable thoracolumbar burst fractures by indirect reduction and posterior stabilization: short-segment versus long-segment stabilization. *Open Orthop J*. 2010;4:7–13. doi:10.2174/1874325001004010007
8. Leferink VJM, Nijboer JMM, Zimmerman KW, Veldhuis EFM, tenVergert EM, ten DHJ. Thoracolumbar spinal fractures: segmental range of motion after dorsal spondylodesis in 82 patients: a prospective study. *Eur Spine J*. 2002;11(1):2–7. doi:10.1007/s005860100331
9. Mahar A, Kim C, Wedemeyer M, et al. Short-Segment fixation of lumbar burst fractures using pedicle fixation at the level of the fracture. *Spine (Phila Pa 1976)*. 2007;32(14):1503–1507. doi:10.1097/BRS.0b013e318067dd24
10. Farrokhi M-R, Razmkon A, Maghami Z, Nikoo Z. Inclusion of the fracture level in short segment fixation of thoracolumbar fractures. *Eur Spine J*. 2010;19(10):1651–1656. doi:10.1007/s00586-010-1449-z
11. Eno J-JT, Chen JL, Mitsunaga MM. Short same-segment fixation of thoracolumbar burst fractures. *Hawaii J Med Public Health*. 2012;71(1):19–22.
12. Kim HS, Lee SY, Nanda A, et al. Comparison of surgical outcomes in thoracolumbar fractures operated with posterior constructs having varying fixation length with selective anterior fusion. *Yonsei Med J*. 2009;50(4):546–554. doi:10.3349/ymj.2009.50.4.546
13. Wilcox RK, Allen DJ, Hall RM, Limb D, Barton DC, Dickson RA. A dynamic investigation of the burst fracture process using a combined experimental and finite element approach. *Eur Spine J*. 2004;13(6):481–488. doi:10.1007/s00586-003-0625-9
14. Park WM, Park Y-S, Kim K, Kim YH. Biomechanical comparison of instrumentation techniques in treatment of thoracolumbar burst fractures: a finite element analysis. *J Orthop Sci*. 2009;14(4):443–449. doi:10.1007/s00776-009-1341-z
15. Kurutz M. Finite element modelling of human lumbar spine. In: Moratal D, ed. *Finite Element Analysis*. Sciyo; 2010:209–236.
16. Zhong Z-C, Wei S-H, Wang J-P, Feng C-K, Chen C-S, Yu C. Finite element analysis of the lumbar spine with a new cage using a topology optimization method. *Med Eng Phys*. 2006;28(1):90–98. doi:10.1016/j.medengphys.2005.03.007
17. Nachemson A. The load on lumbar disks in different positions of the body. *Clin Orthop Relat Res*. 1966;45:107–122. doi:10.1097/00003086-196600450-00014
18. Lawrence BD, Wang J, Arnold PM, Hermsmeyer J, Norvell DC, Brodke DS. Predicting the risk of adjacent segment pathology after lumbar fusion: a systematic review. *Spine (Phila Pa 1976)*. 2012;37(22 Suppl):S123–32. doi:10.1097/BRS.0b013e31826d60d8
19. Benson DR, Burkus JK, Montesano PX, Sutherland TB, McLain RF. Unstable thoracolumbar and lumbar burst fractures treated with the AO fixateur interne. *J Spinal Disord*. 1992;5(3):335–343. doi:10.1097/00002517-199209000-00012
20. Soshi S, Shiba R, Kondo H, Murota K. An experimental study on transpedicular screw fixation in relation to osteoporosis of the lumbar spine. *Spine*. 1991;16(11):1335–1341. doi:10.1097/00007632-199111000-00015
21. Wittenberg RH, Shea M, Swartz DE, Lee KS, White AA III, Hayes WC. Importance of bone mineral density in instrumented spine fusions. *Spine*. 1991;16(6):647–652. doi:10.1097/00007632-199106000-00009
22. Goel VK, Ebraheim NA, Biyani A, Rengachary S, Faizan A. Role of mechanical factors in the evaluation of pedicle screw type spinal fixation devices. *Neurol India*. 2005;53(4):399–407. doi:10.4103/0028-3886.22604
23. Bernard TN, Seibert CE. Pedicle diameter determined by computed tomography. its relevance to pedicle screw fixation in the lumbar spine. *Spine (Phila Pa 1976)*. 1992;17:S160–S163. doi:10.1097/00007632-199206001-00017
24. Vaccaro AR, Silber JS. Post-Traumatic spinal deformity. *Spine (Phila Pa 1976)*. 2001;26(24 Suppl):S111–8. doi:10.1097/00007632-200112151-00019
25. Ghiasi MS, Chen J, Vaziri A, Rodriguez EK, Nazarian A. Bone fracture healing in mechanobiological modeling: a review of principles and methods. *Bone Rep*. 2017;6:87–100. doi:10.1016/j.bonr.2017.03.002
26. Chen JH, Liu C, You L, Simmons CA. Boning up on Wolff's law: mechanical regulation of the cells that make and maintain bone. *J Biomech*. 2010;43(1):108–118. doi:10.1016/j.jbiomech.2009.09.016
27. Huang C, Ogawa R. Mechanotransduction in bone repair and regeneration. *FASEB J*. 2010;24(10):3625–3632. doi:10.1096/fj.10-157370

Funding: This research was financially supported by a grant from the Ratchadapiseksompotch Fund, Faculty of Medicine, Chulalongkorn University, Bangkok, Thailand (Grant number RA57/030).

Declaration of Conflicting Interests: The authors report no conflicts of interest in this work.

Ethics Approval: The Human Investigation Committee of Faculty of Medicine, Chulalongkorn University Institutional Review Board (IRB) approved this study (IRB number 062/58). Written informed consent was waived.

Corresponding Author: Weerasak Singhatanadgige, Department of Orthopedics, Faculty of Medicine, Chulalongkorn University and King Chulalongkorn Memorial Hospital, 1873 Rama IV Rd, Pathumwan, Bangkok 10330, Thailand; dr.weerasaks@gmail.com

This manuscript is generously published free of charge by ISASS, the International Society for the Advancement of Spine Surgery. Copyright © 2023 ISASS. To see more or order reprints or permissions, see <http://ijssurgery.com>.